

Center for Reconstructive Urethral Surgery



GUIDO BARBAGLI M.D.

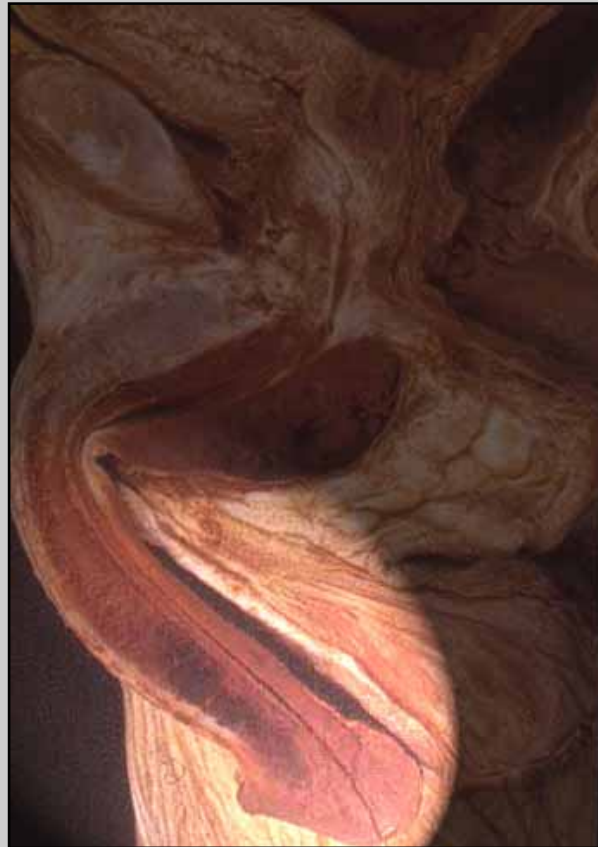
Arezzo - ITALY

e-mail: info@urethralcenter.it

Website: www.urethralcenter.it

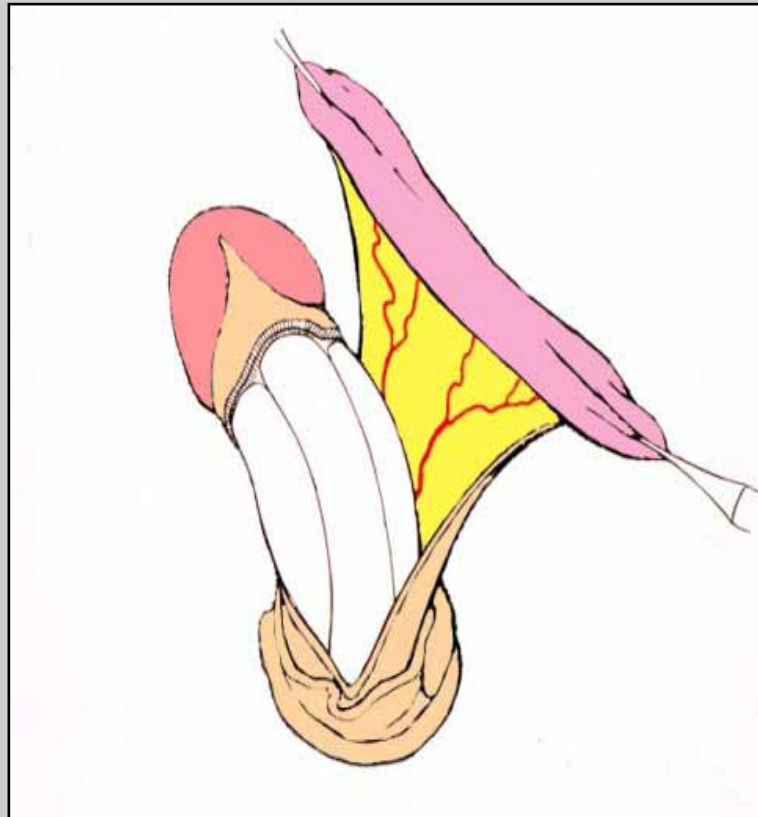
One-stage urethroplasty using penile skin flap

One-stage urethroplasty using penile skin flap



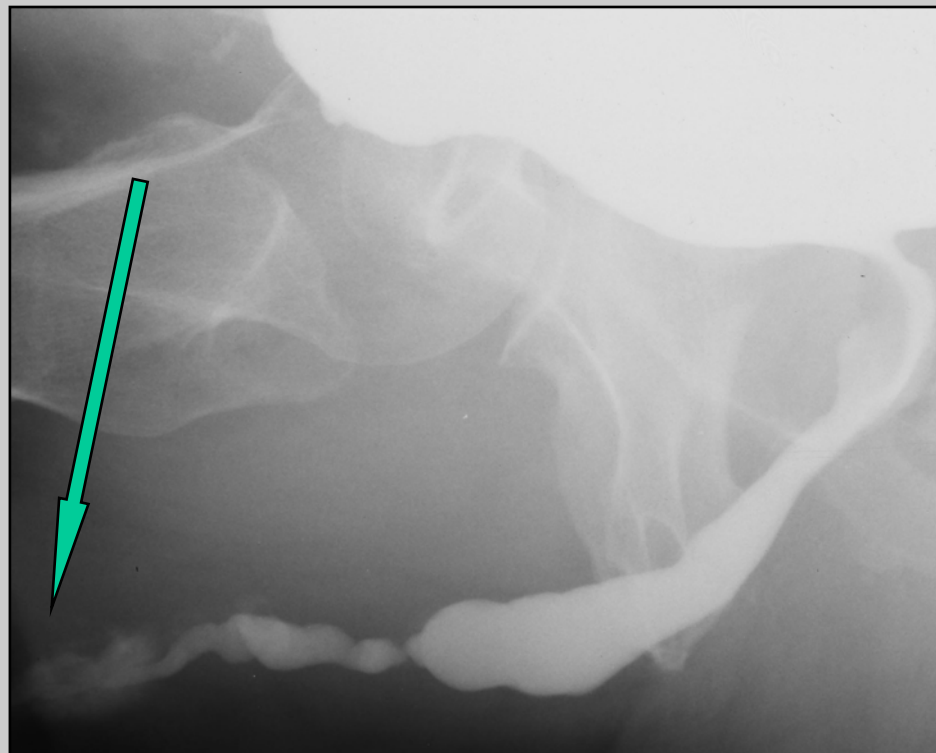
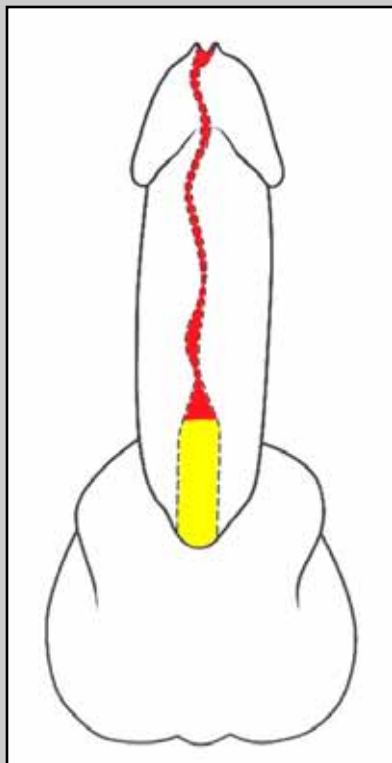
Penile urethra

One-stage urethroplasty using penile skin flap



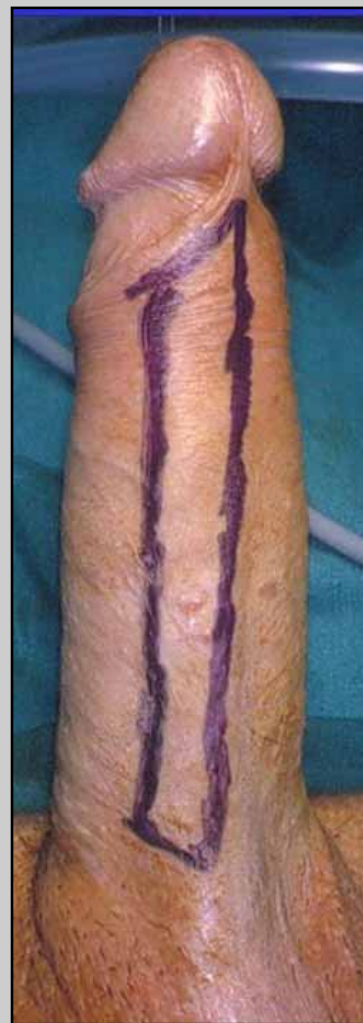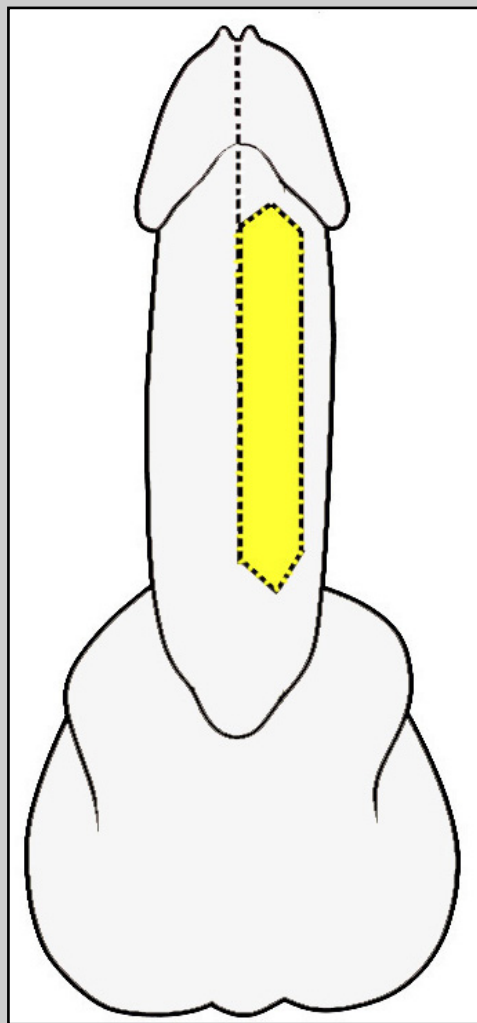
Surgical techniques: step by step

Jordan's flap

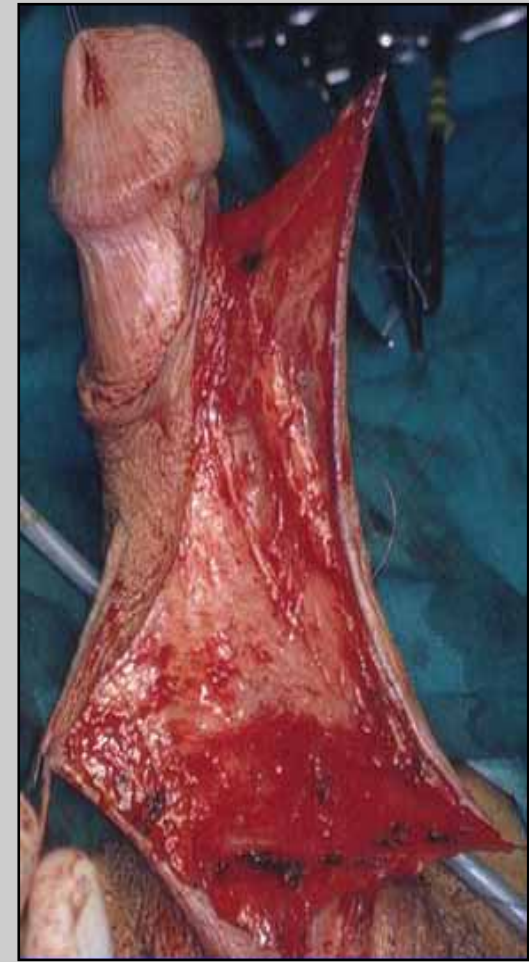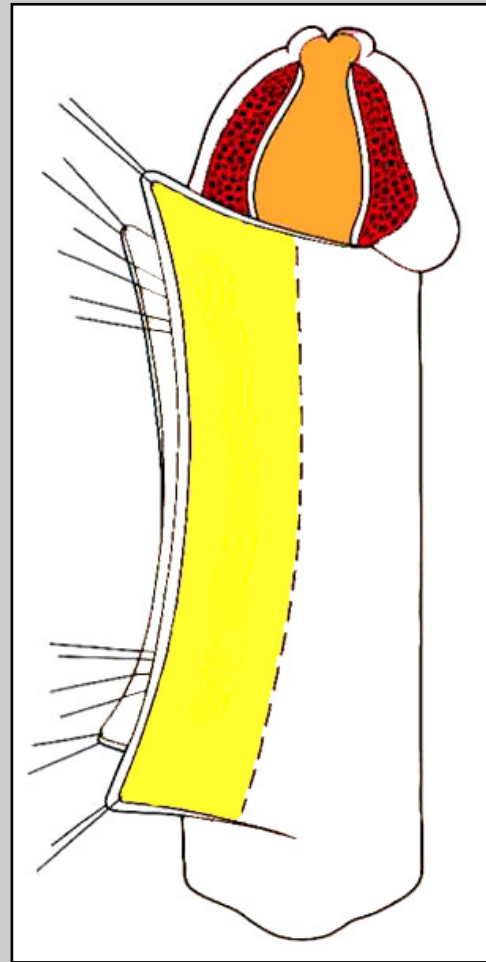
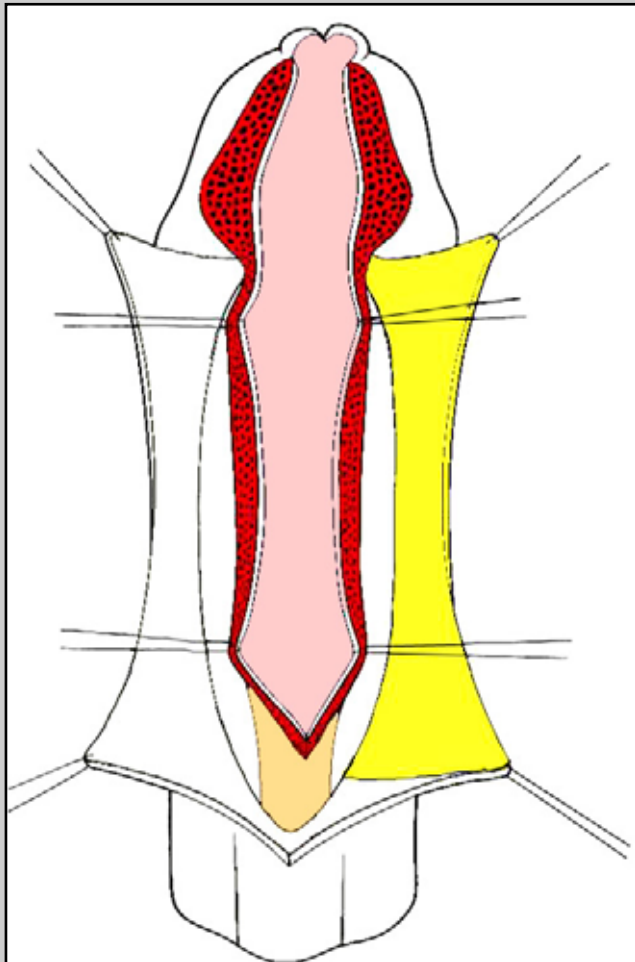


Penile urethral stricture involving external urinary meatus

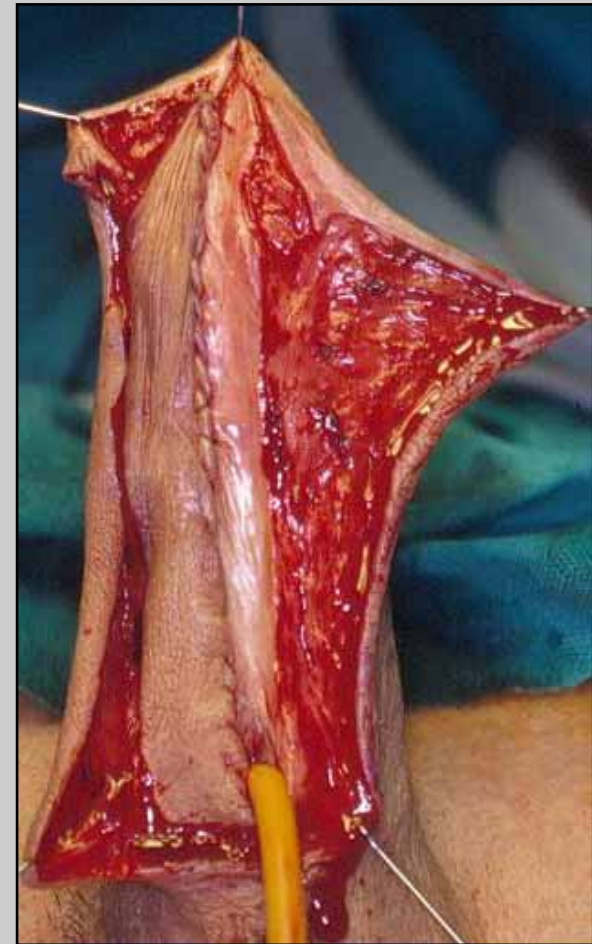
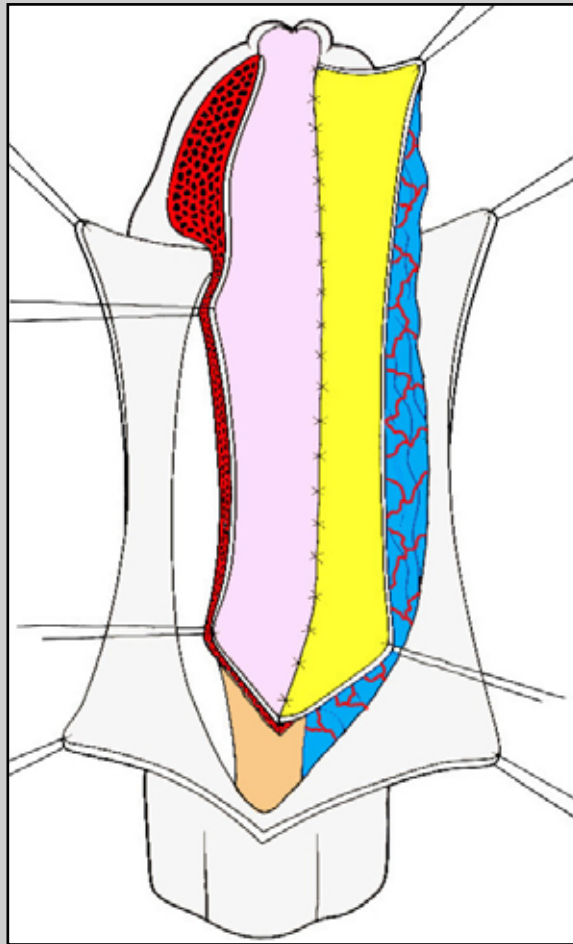
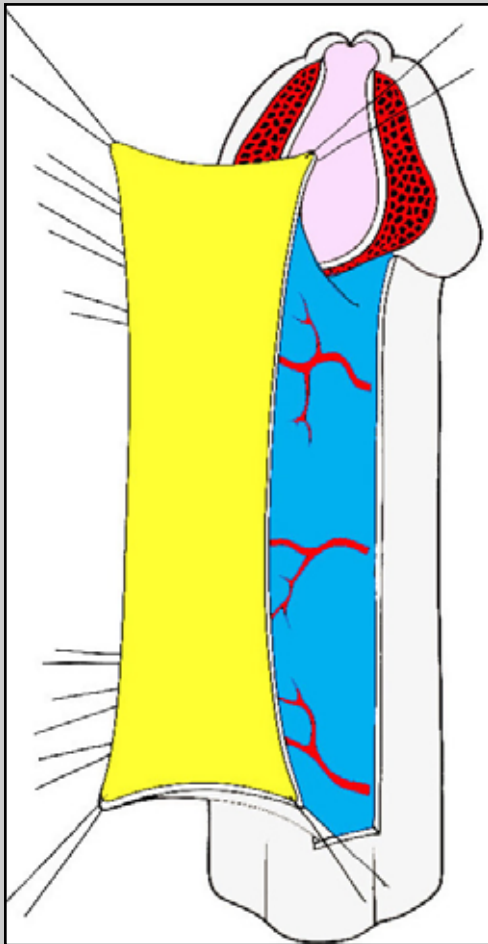
Jordan's flap



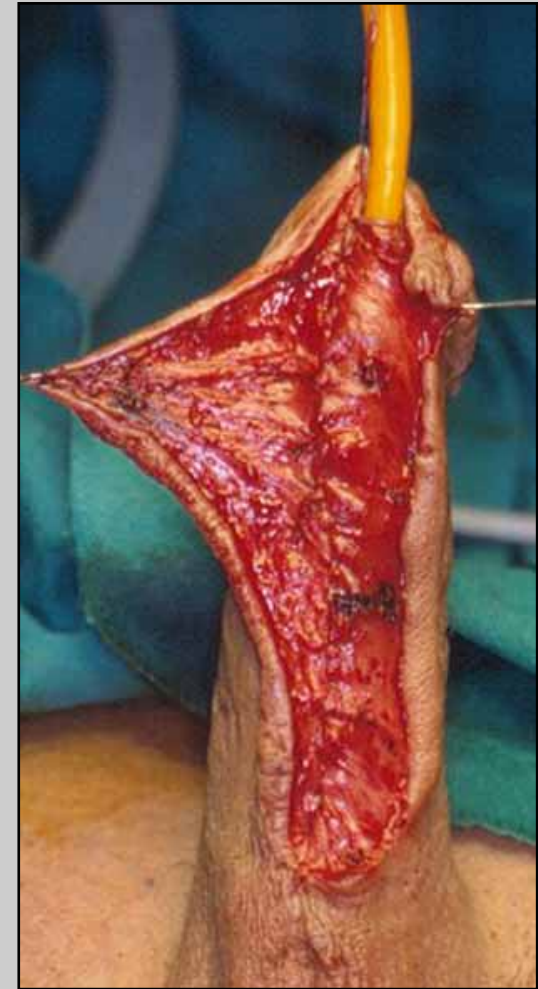
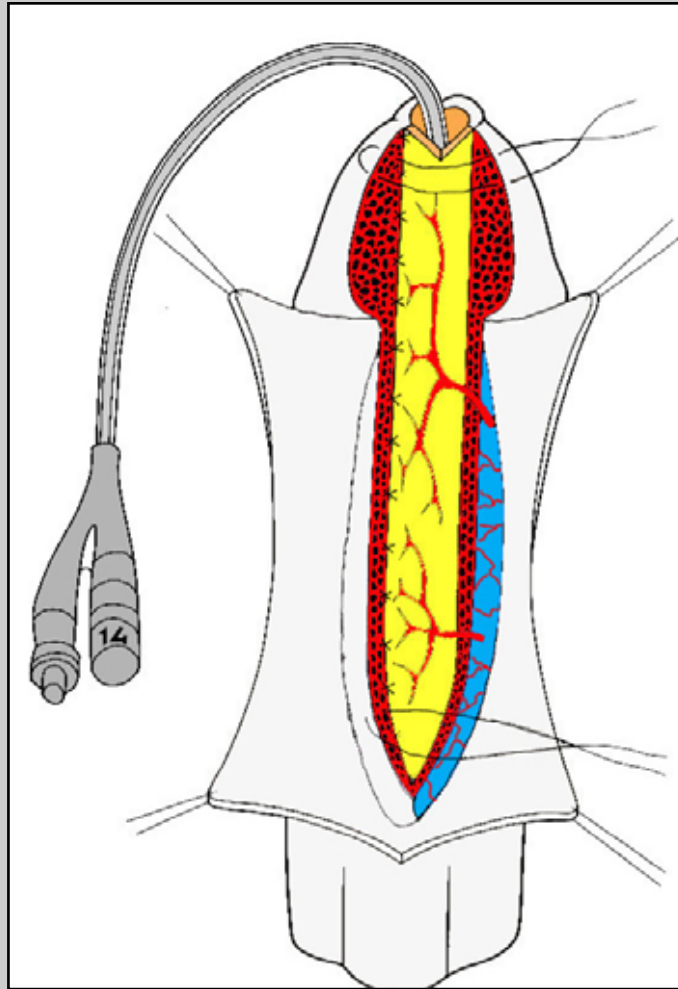
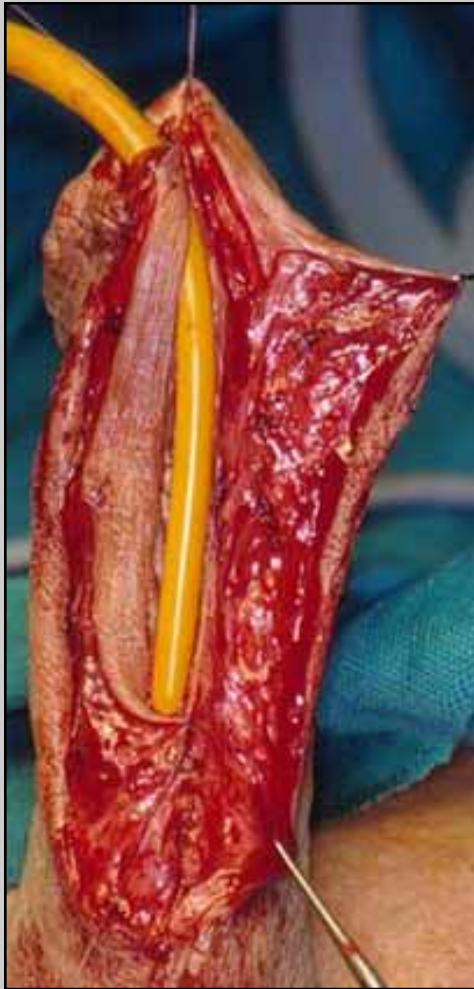
Jordan's flap



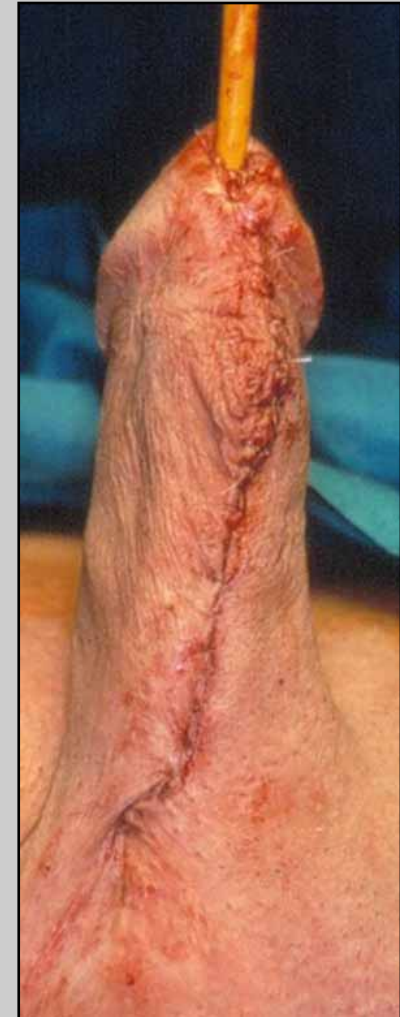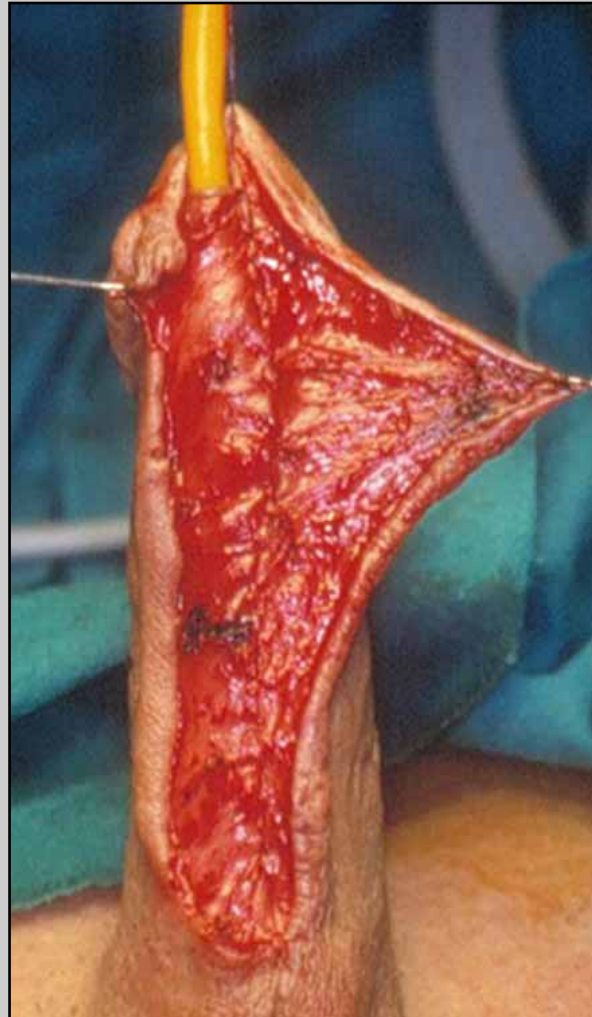
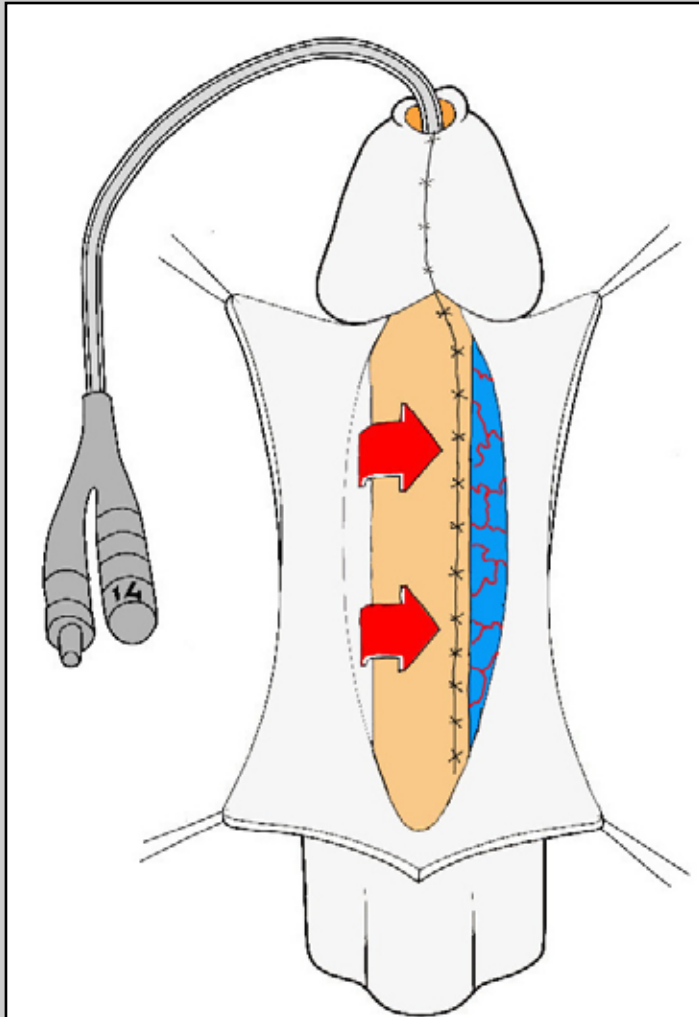
Jordan's flap



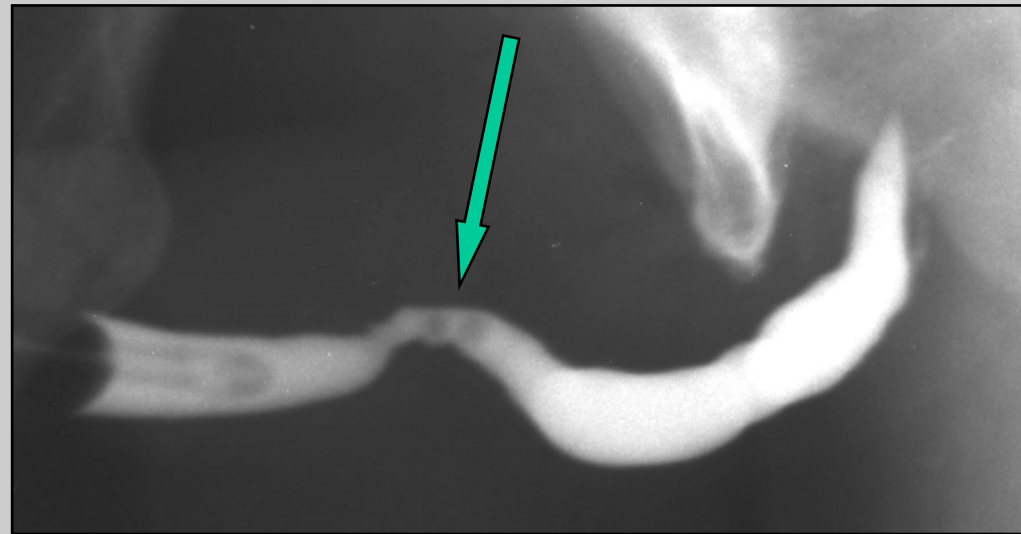
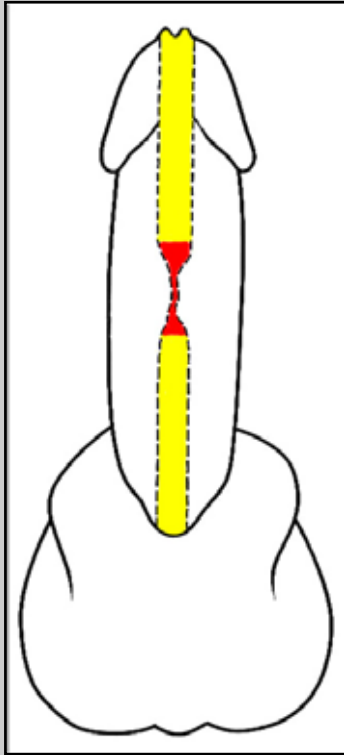
Jordan's flap



Jordan's flap

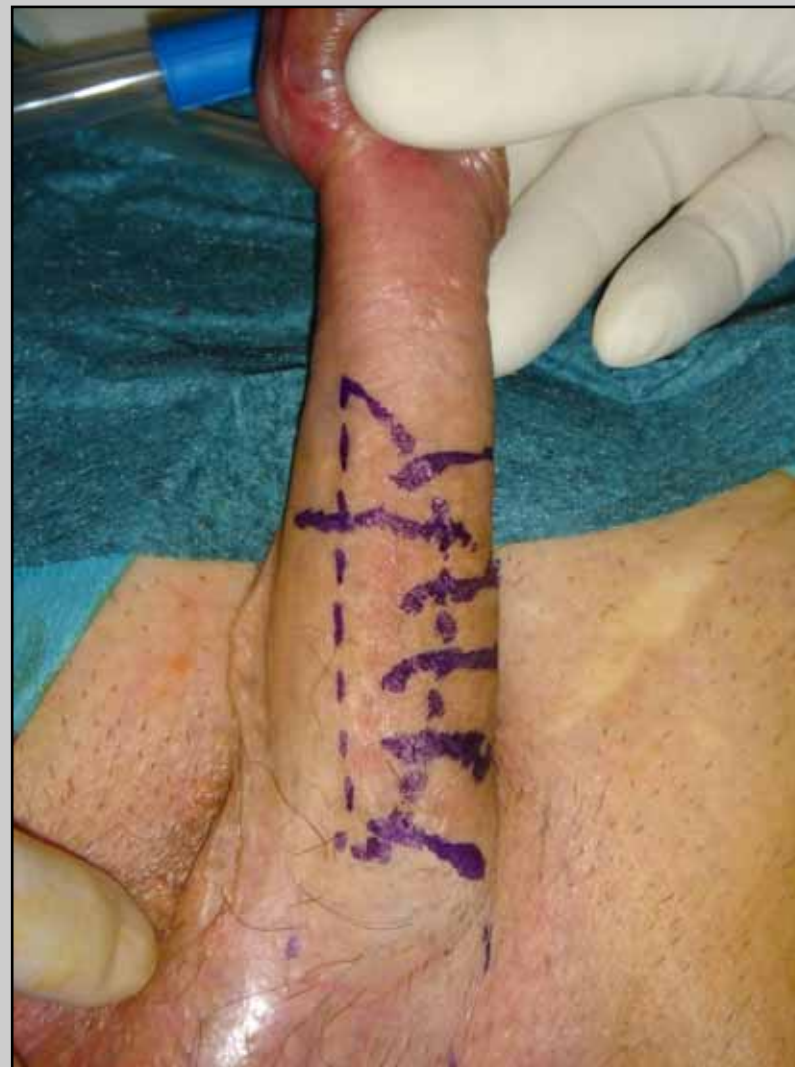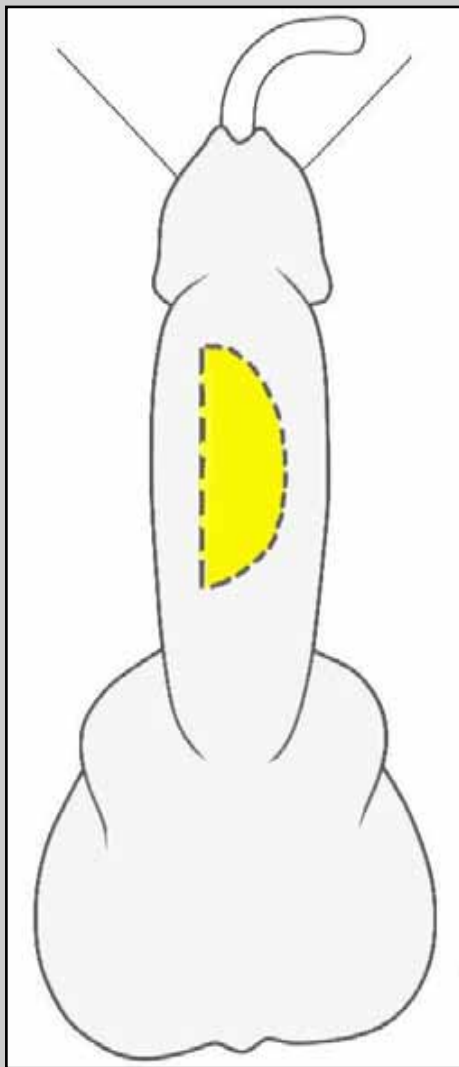


Modified Orandi's flap

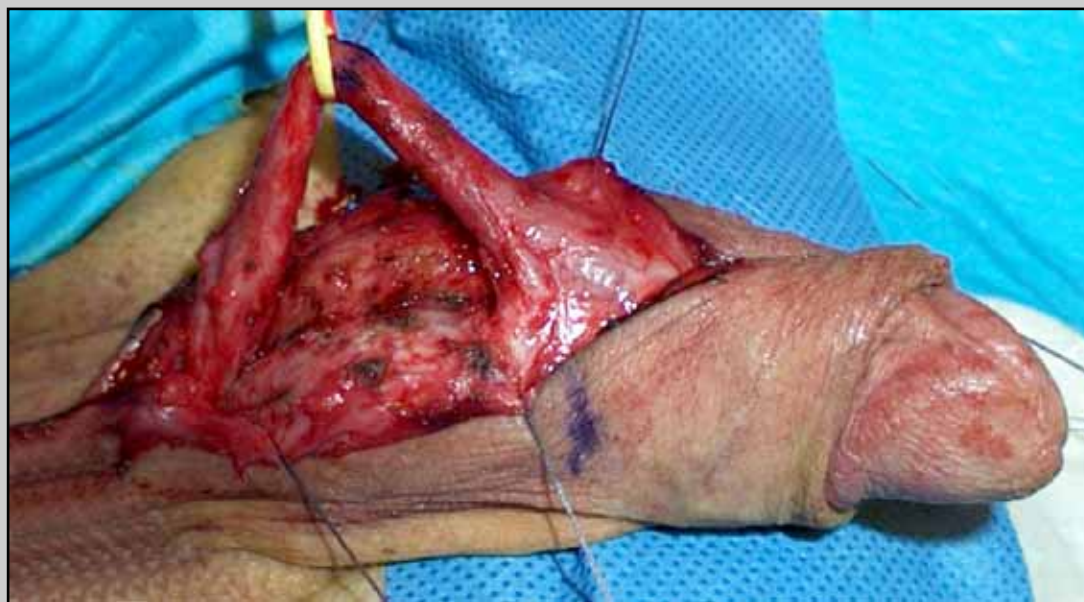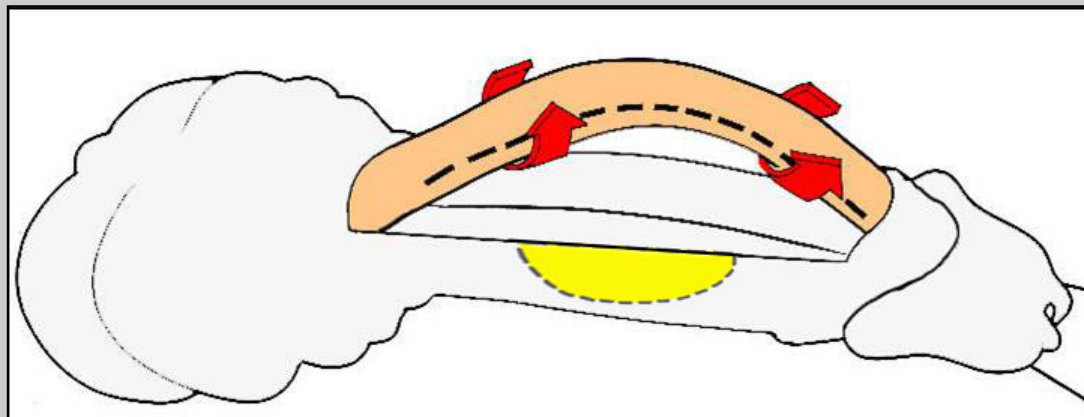


Penile urethral stricture in the middle tract of the shaft

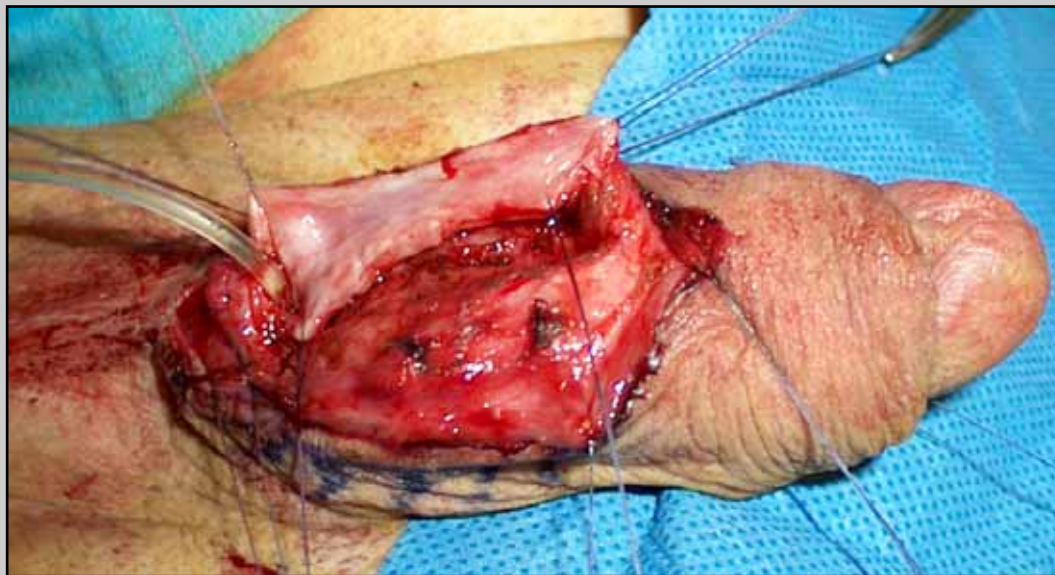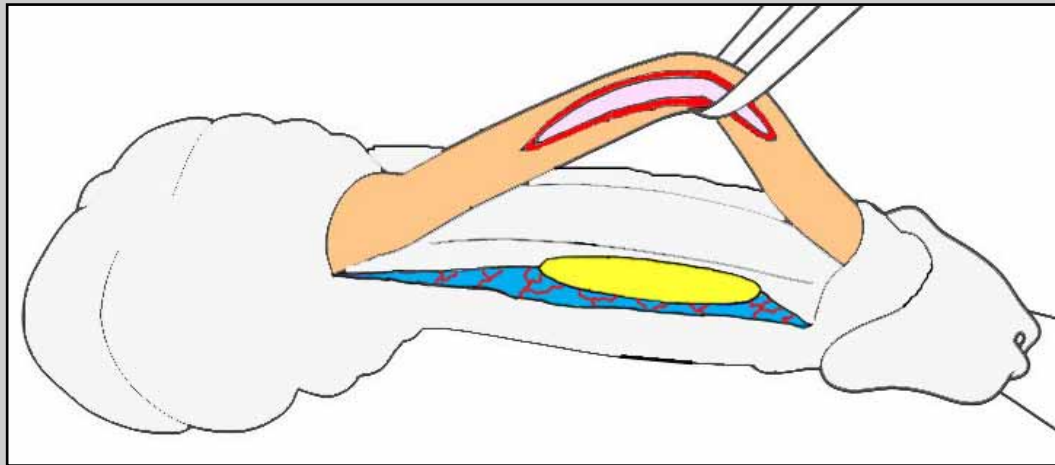
Modified Orandi's flap



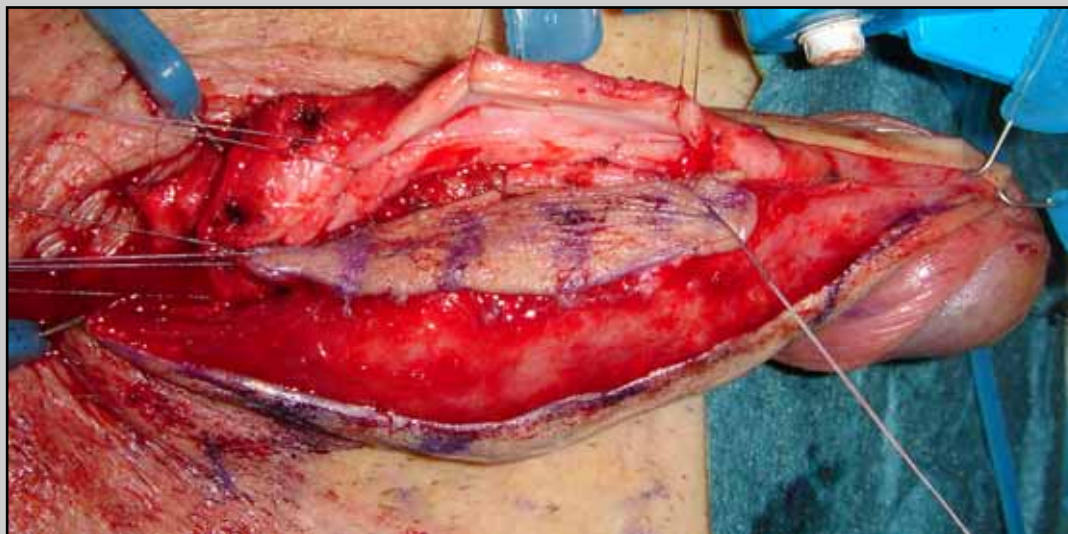
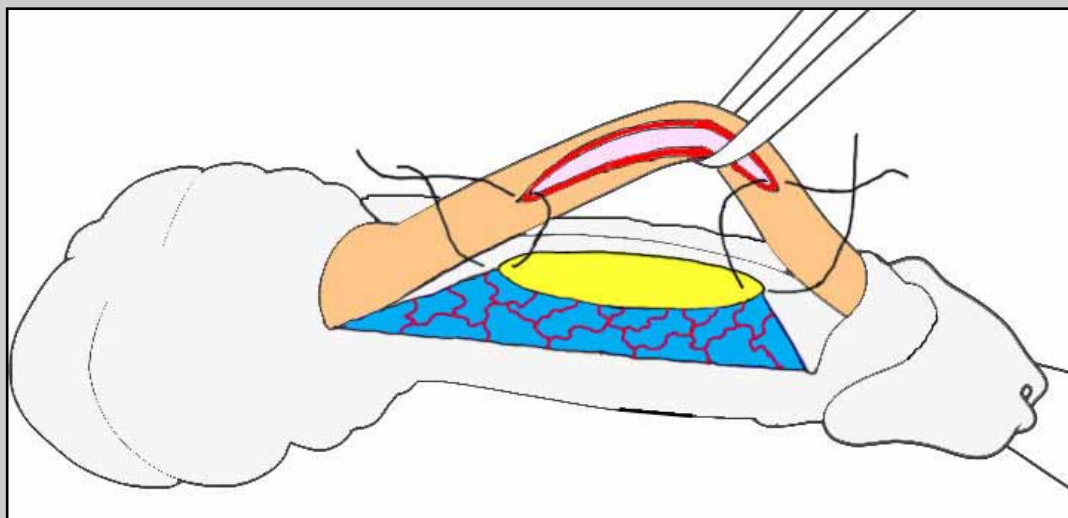
Modified Orandi's flap



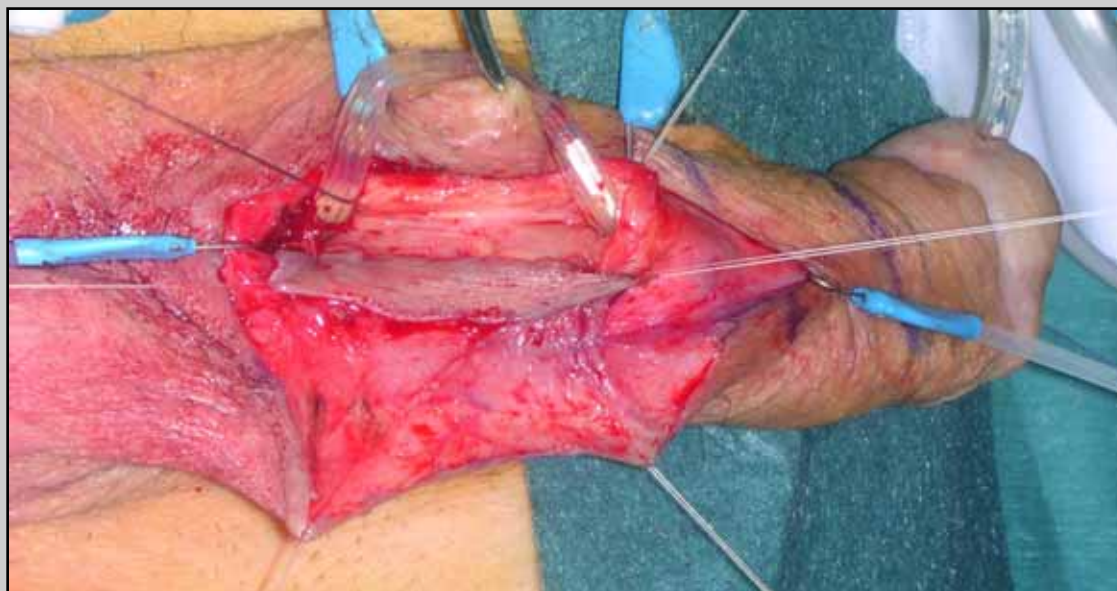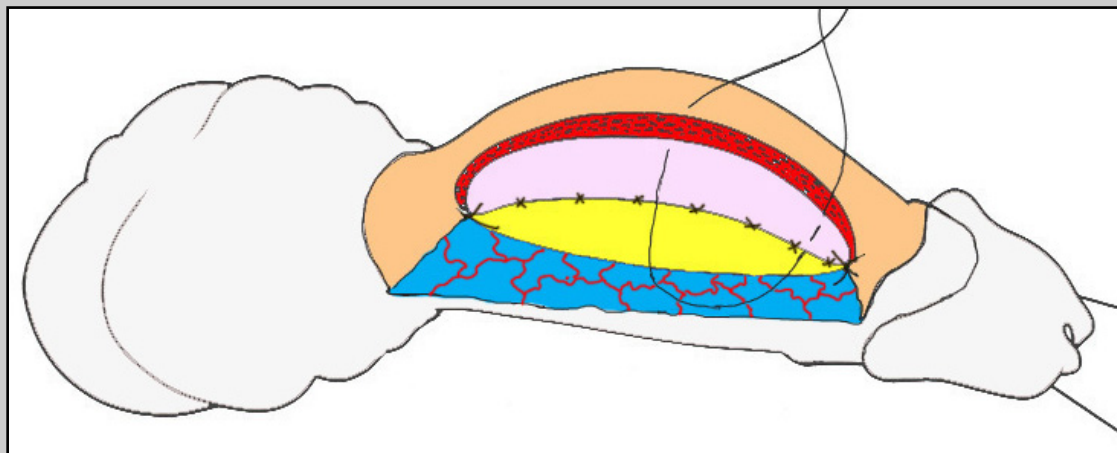
Modified Orandi's flap



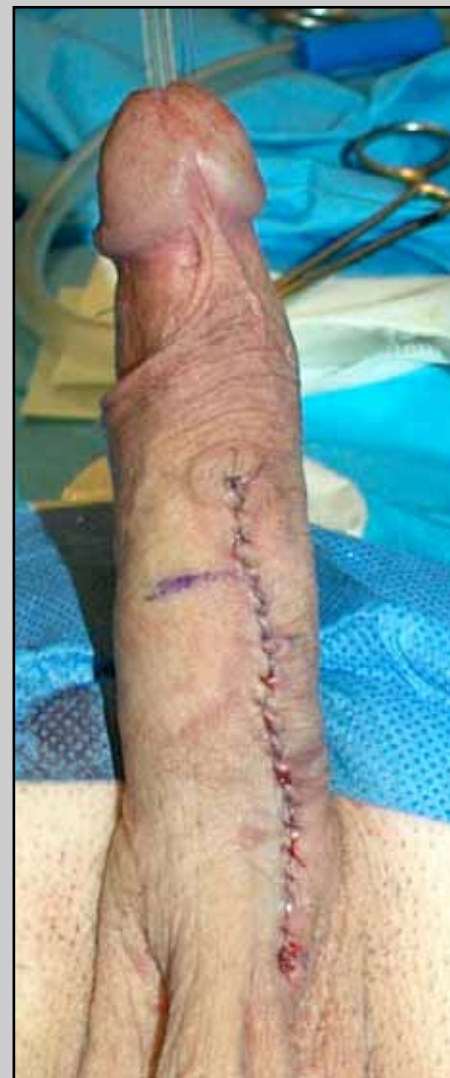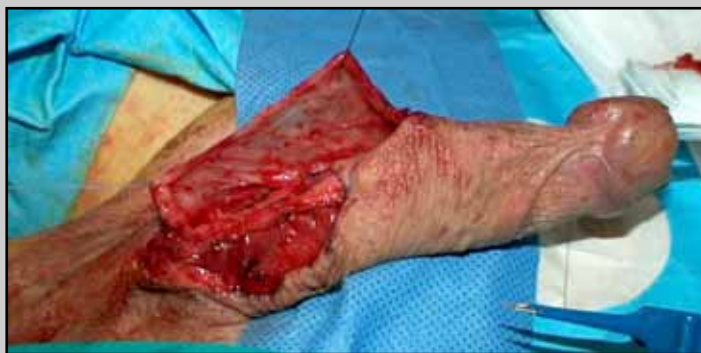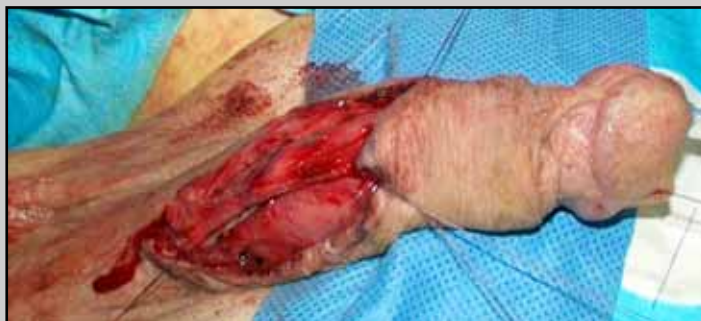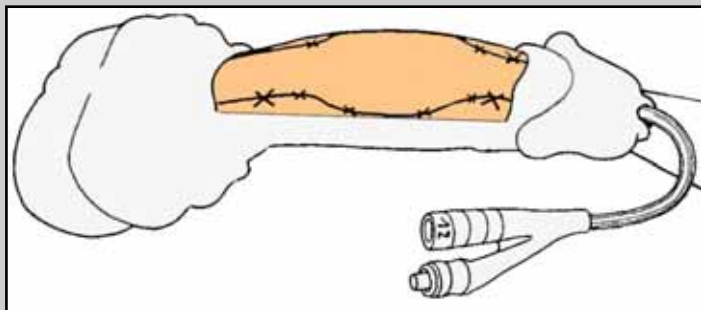
Modified Orandi's flap



Modified Orandi's flap

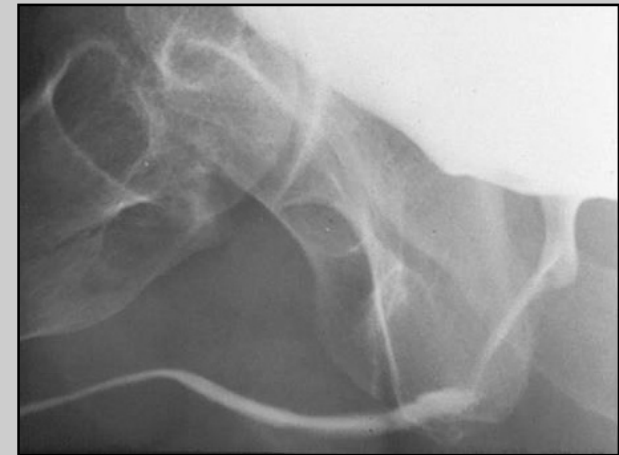


Modified Orandi's flap

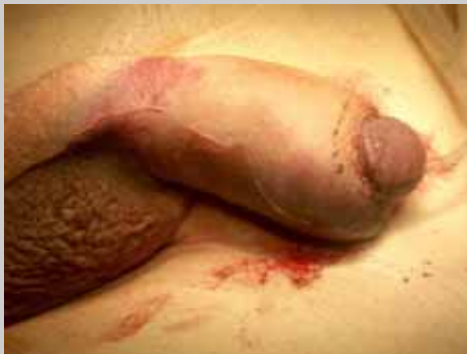

Post-operative care

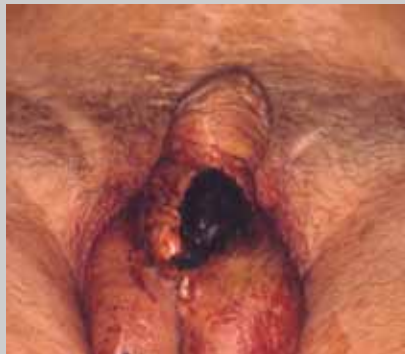- Patient is discharged from the hospital three days after surgery
- Patient is maintained on oral antibiotics until the catheter is removed
- Two weeks following surgery, the catheter is removed and voiding cysto-urethrography is obtained



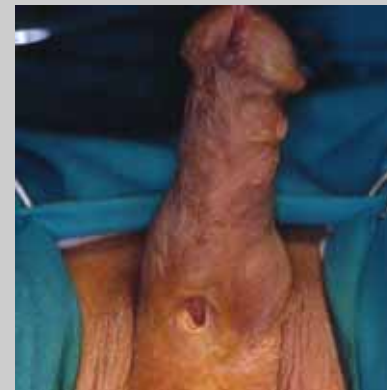
Complications following one-stage flap or graft penile urethroplasty



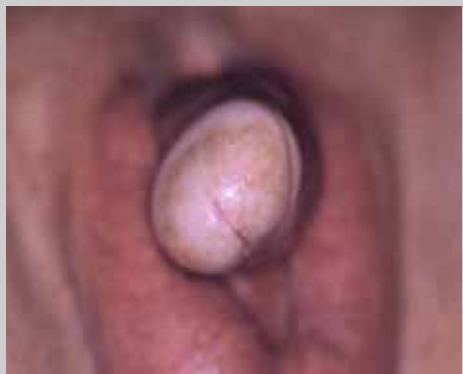penile hematoma



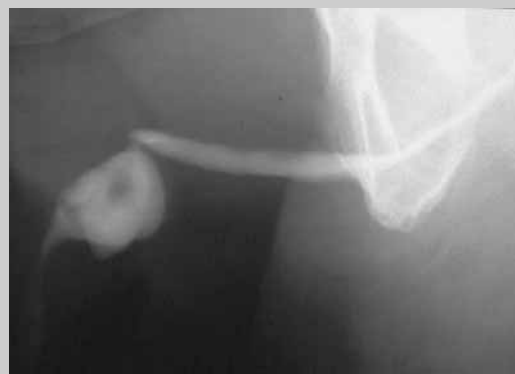skin necrosis



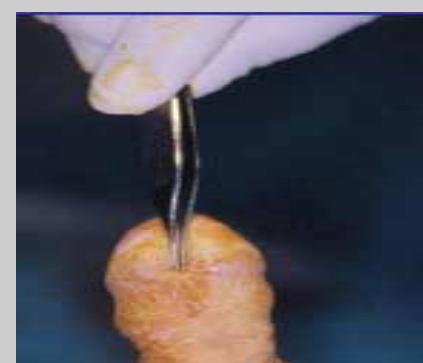
fistula



penile-glans torsion



sacculation



meatal stenosis