

# Center for Reconstructive Urethral Surgery



**GUIDO BARBAGLI M.D.**

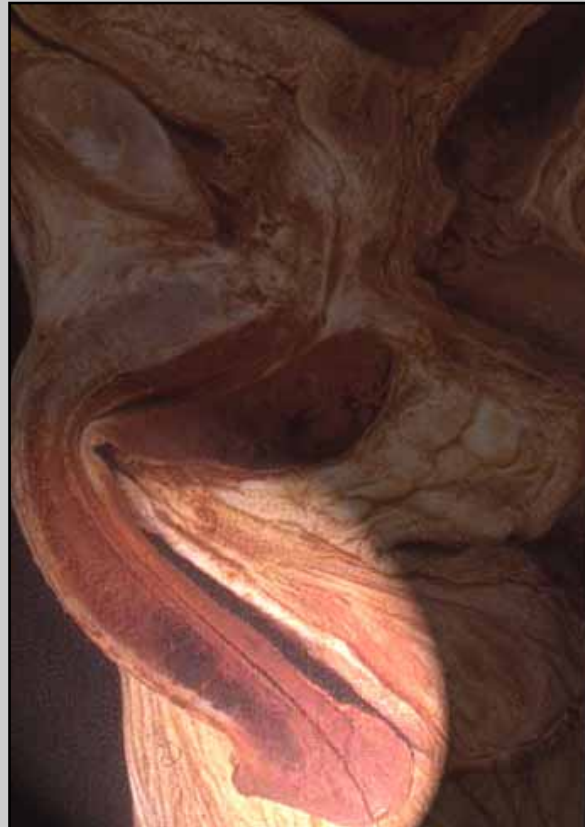
**Arezzo - ITALY**

**e-mail: [info@urethralcenter.it](mailto:info@urethralcenter.it)**

**Website: [www.urethralcenter.it](http://www.urethralcenter.it)**

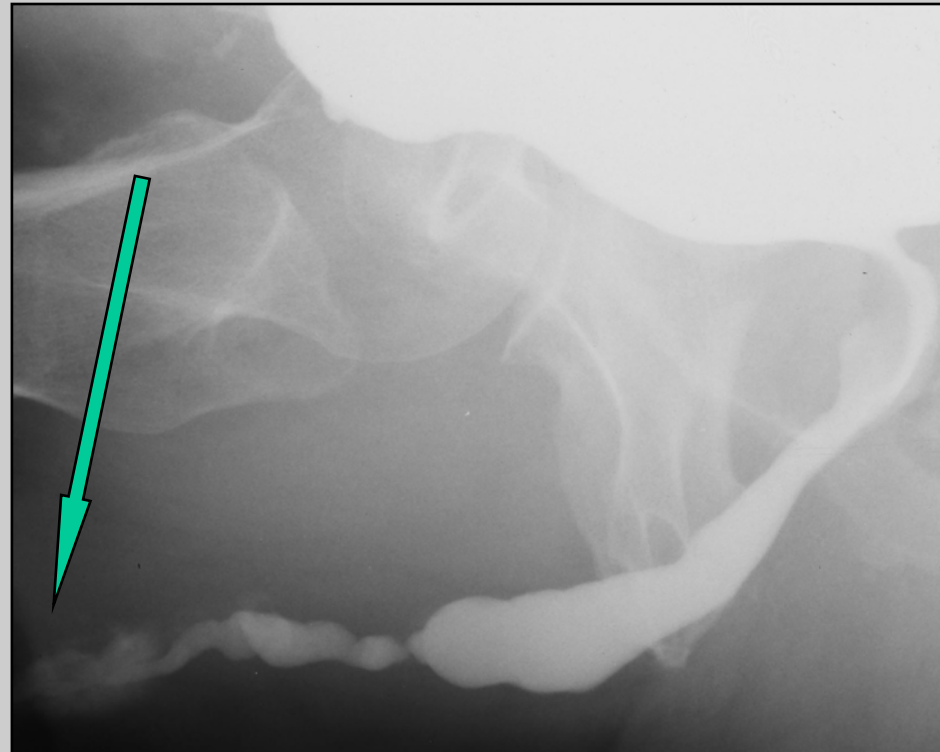
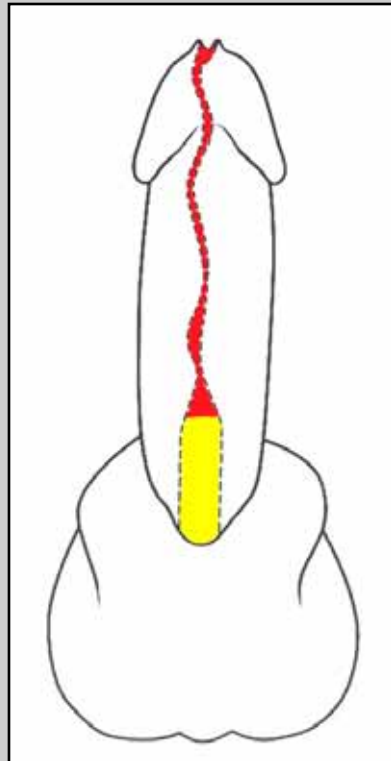
# **Two-stage urethroplasty using oral mucosal graft**

# Two-stage urethroplasty using oral mucosal graft



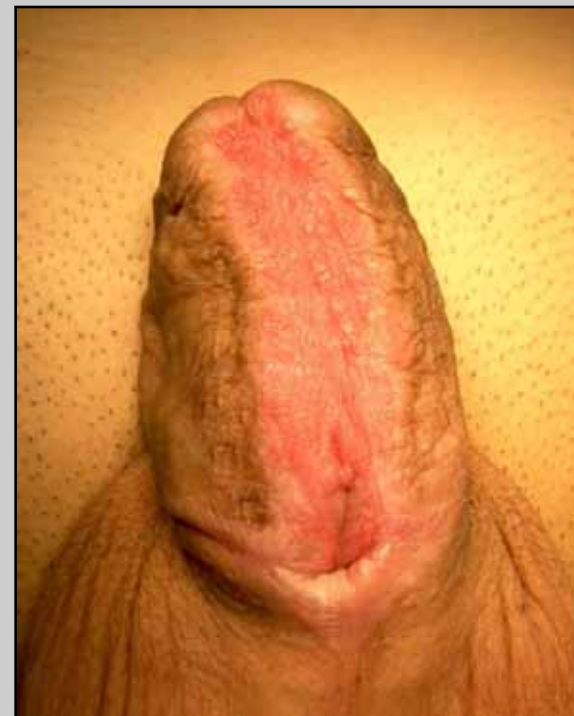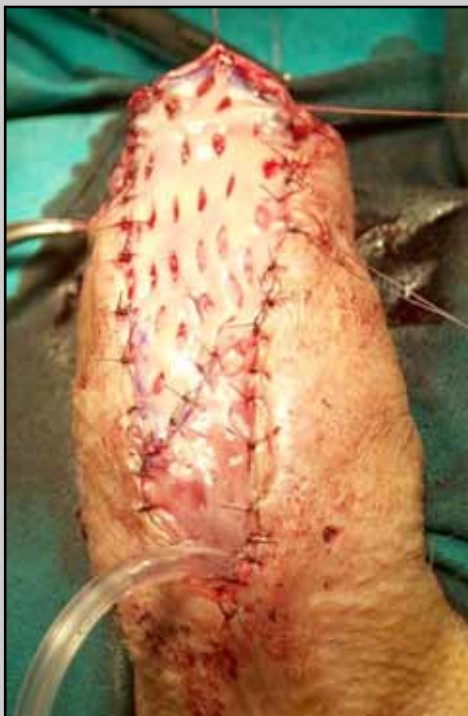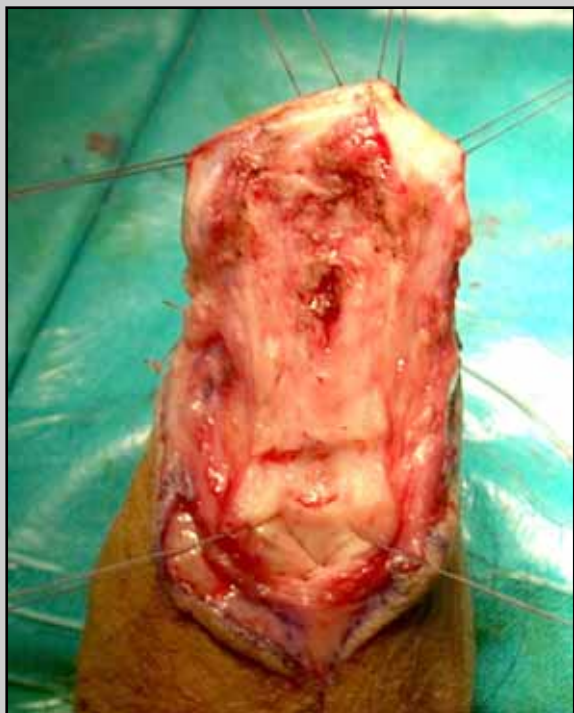
**Penile urethra**

# Two-stage urethroplasty using oral mucosal graft

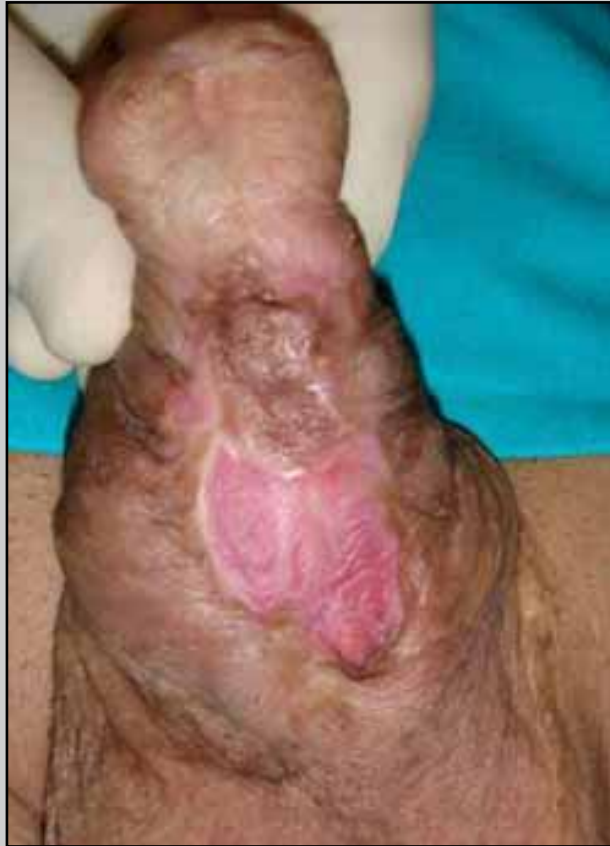

**Obliterative penile urethral strictures involving the external urinary meatus**

# First stage



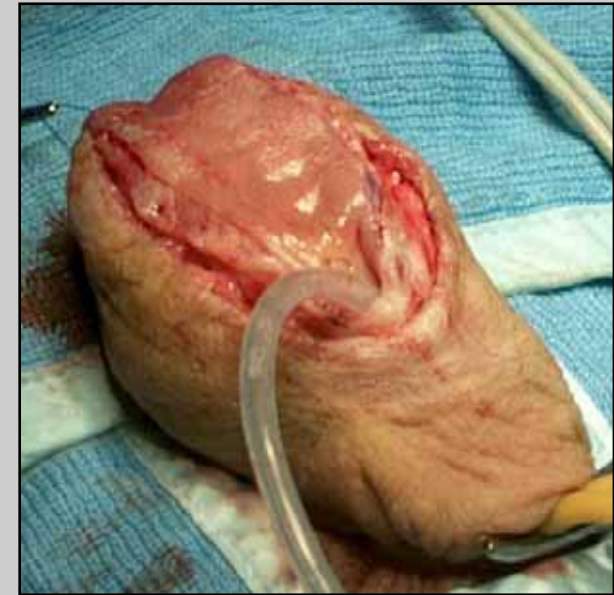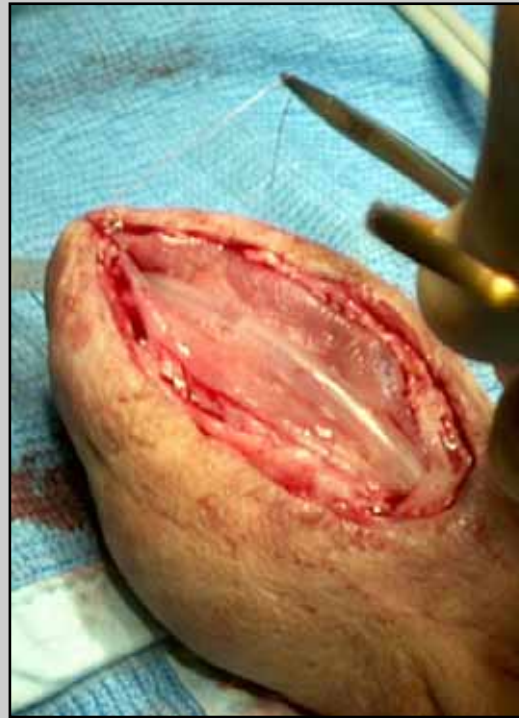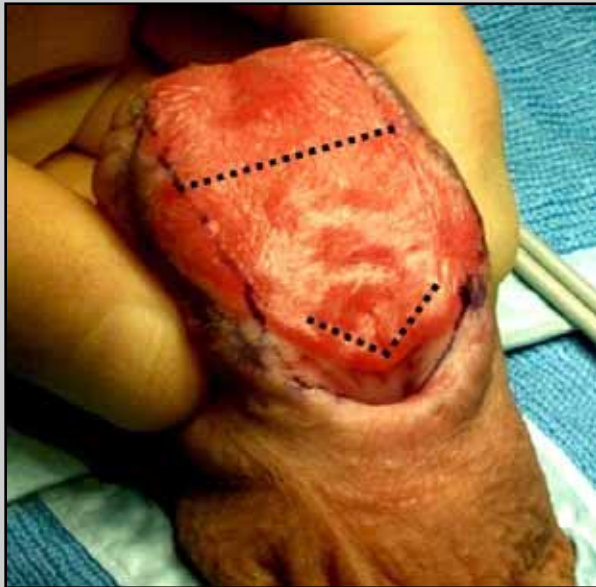# Complications following the first stage of urethroplasty



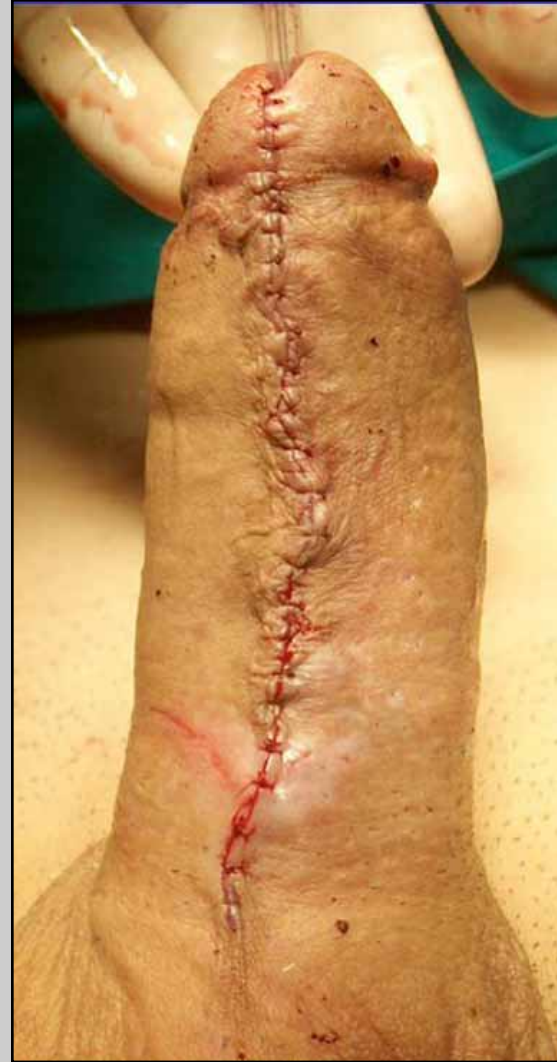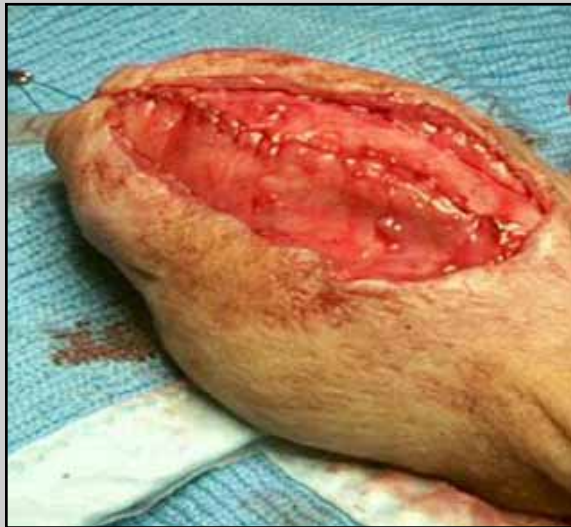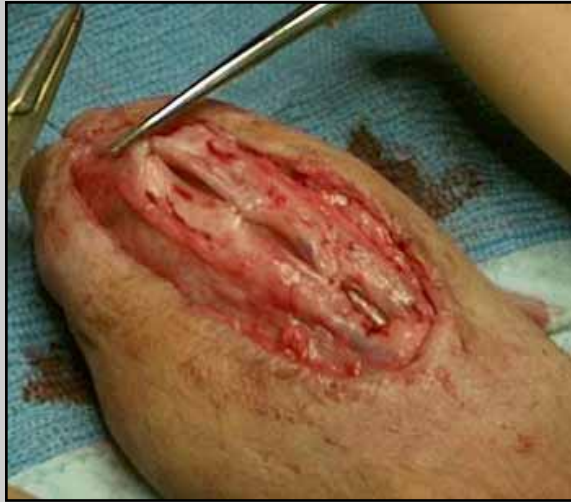scarring of the initial graft,  
requiring new grafting procedures



## Second stage (one year later)

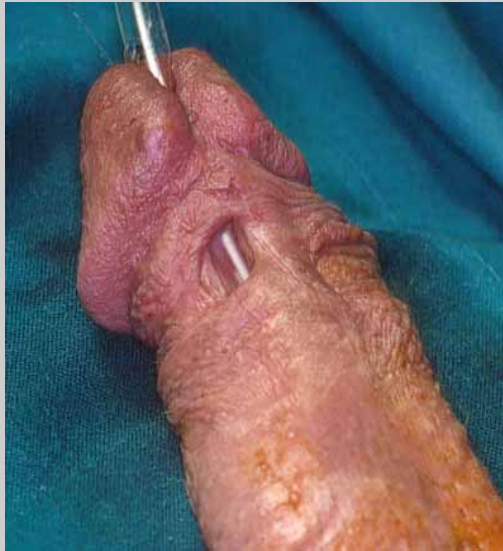

## Second stage

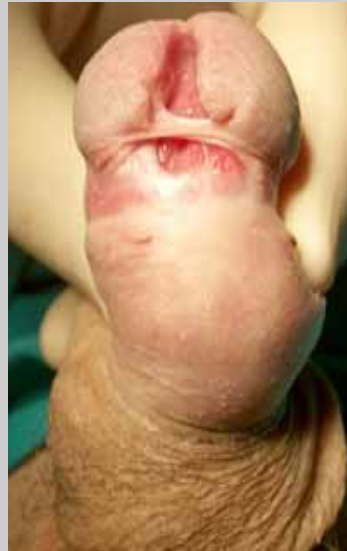



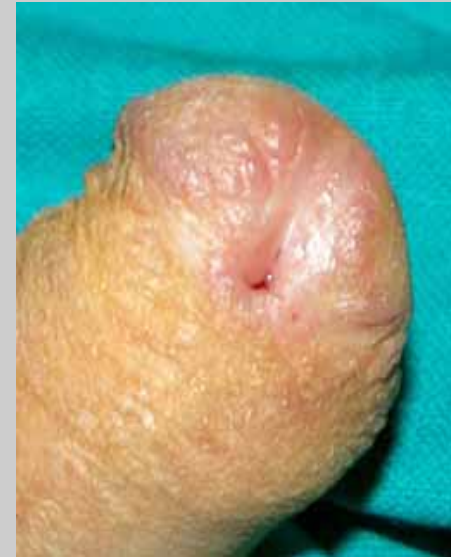# Complications following the second stage of urethroplasty



**fistula**



**glans dehiscence**



**meatal stenosis**

# Post-operative care

- **Patient is discharged from the hospital five days after surgery**
- **Patient is maintained on oral antibiotics until the catheter is removed**
- **Two weeks following surgery, the catheter is removed and voiding cysto-urethrography is obtained**

