

Center for Reconstructive Urethral Surgery



GUIDO BARBAGLI M.D.

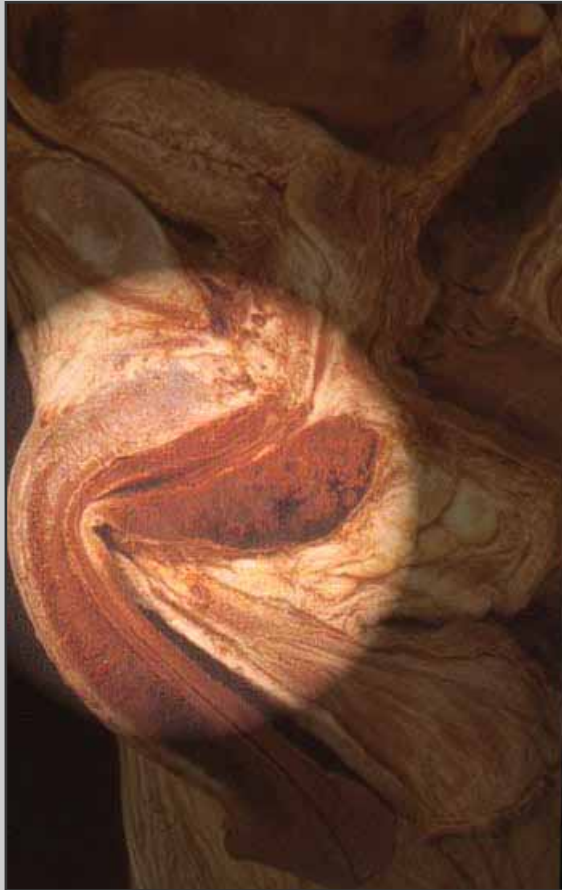Arezzo - ITALY

e-mail: info@urethralcenter.it

Website: www.urethralcenter.it

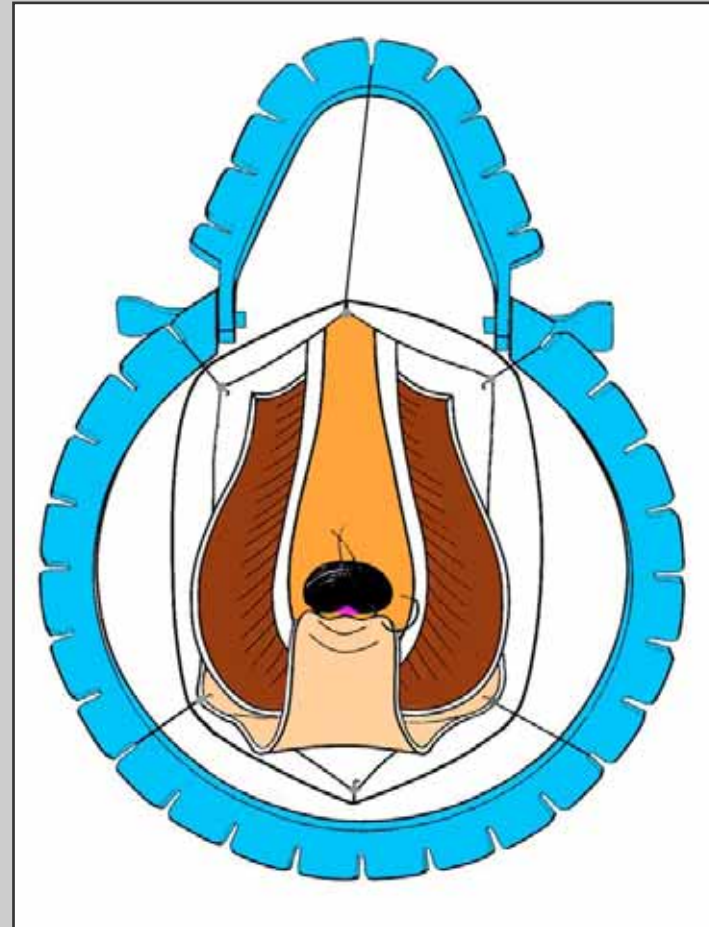
Two-stage urethroplasty

Two-stage urethroplasty



Bulbar urethra

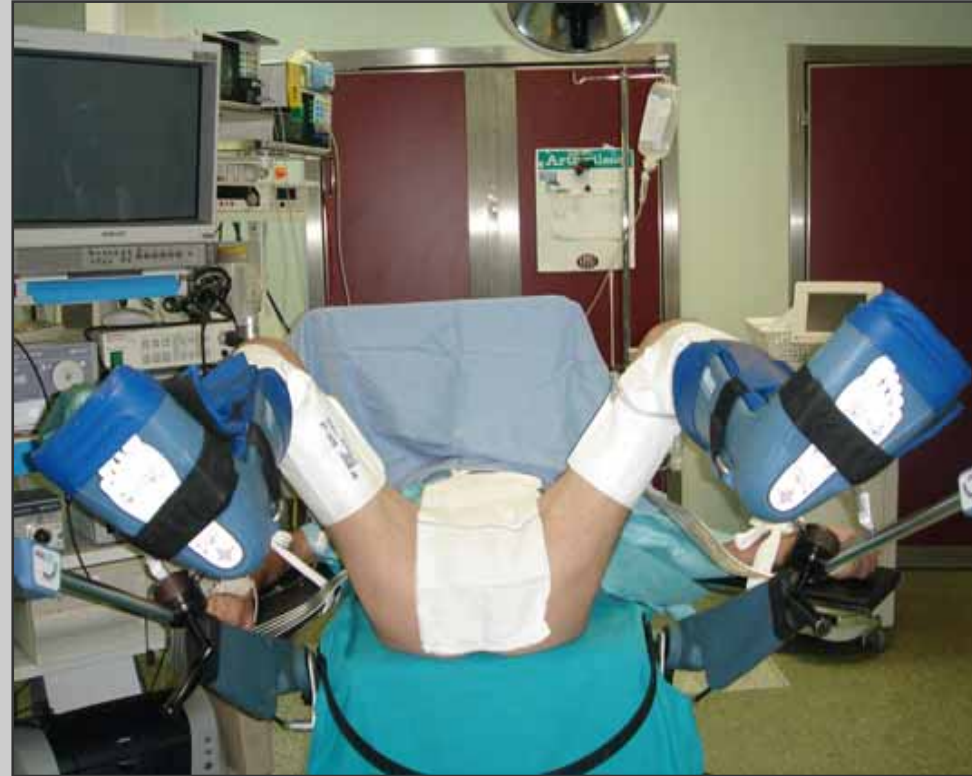Two-stage urethroplasty



Surgical technique: step by step

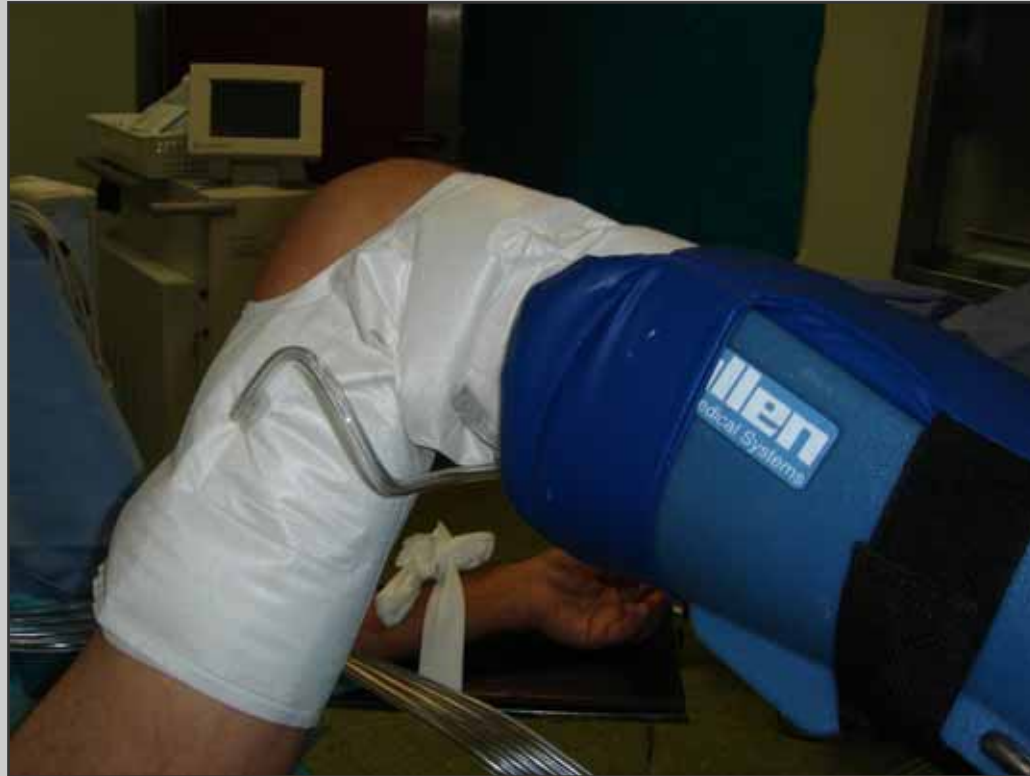First stage

Preparation of the patient

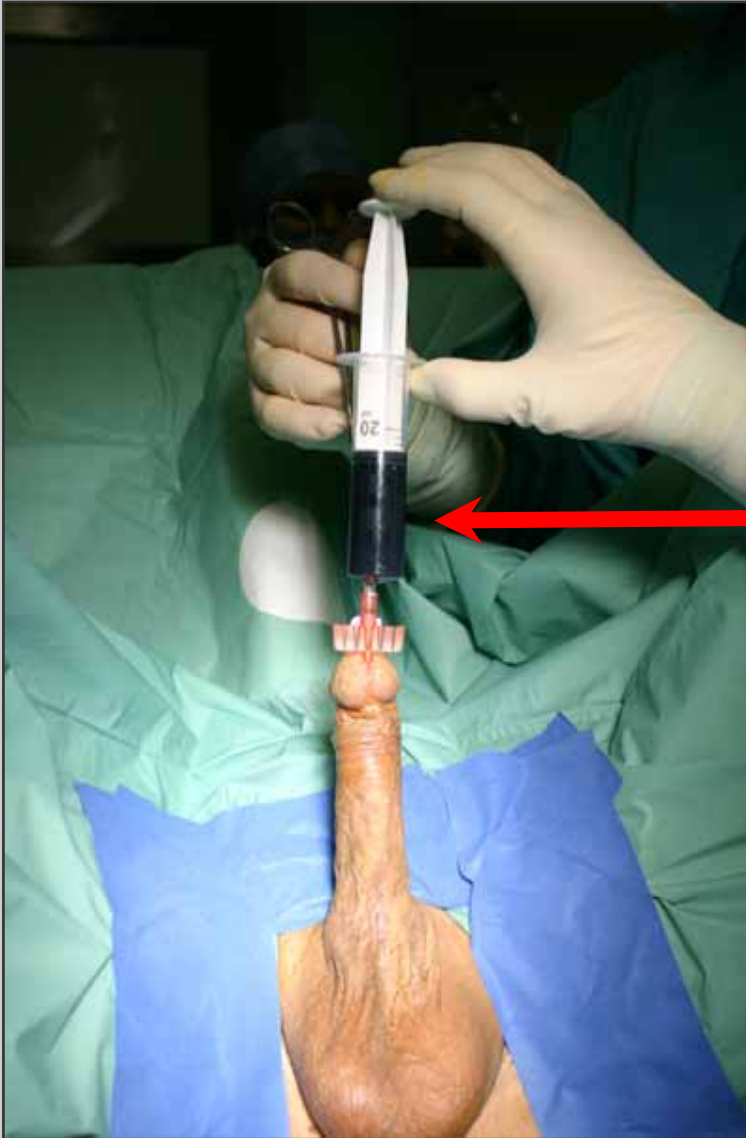

Simple lithotomy position

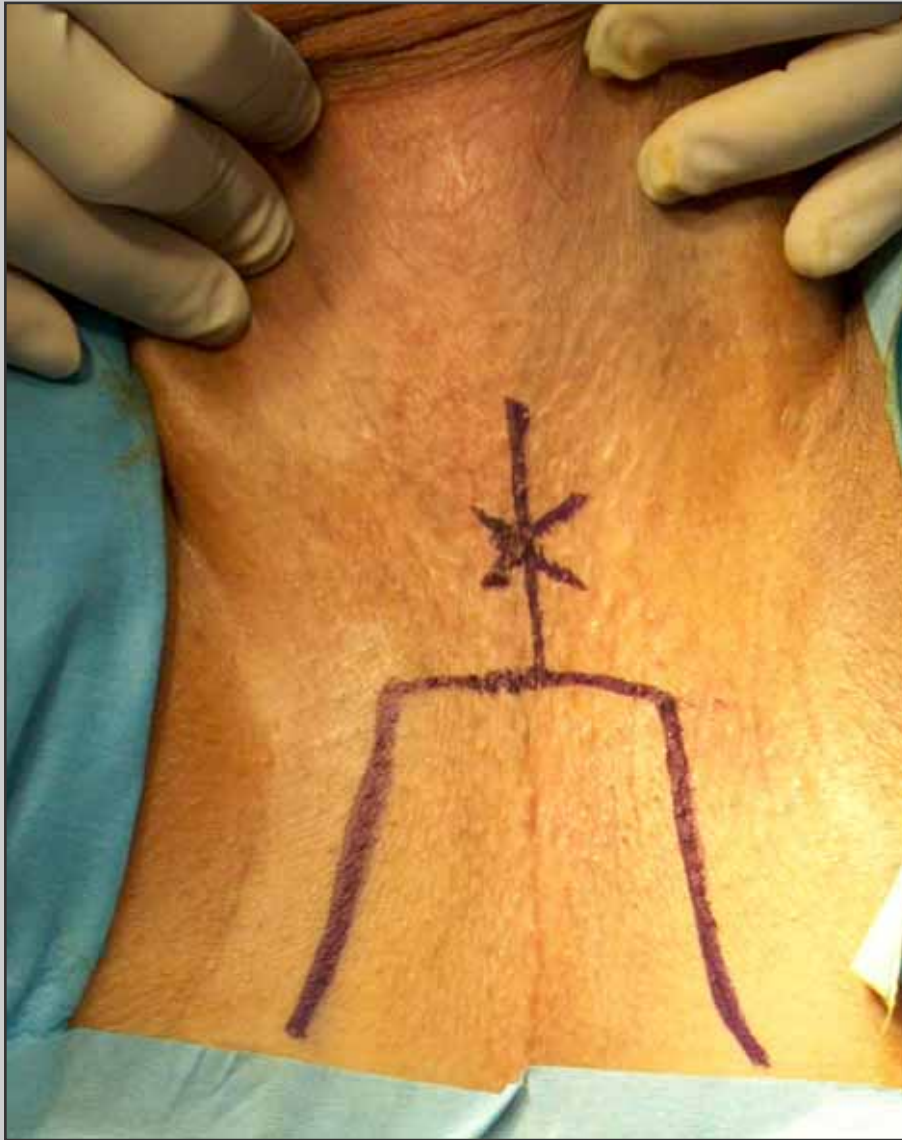Preparation of the patient



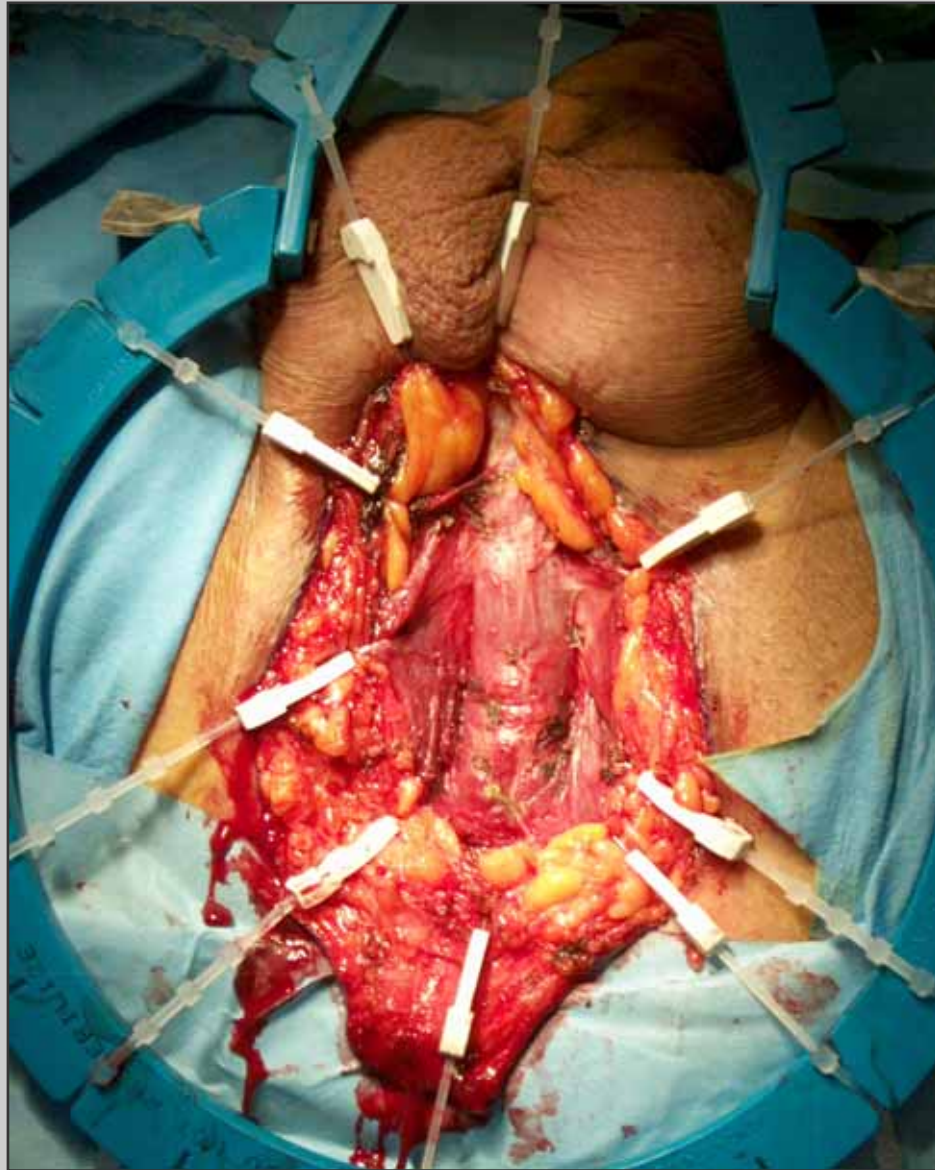
Allen stirrups with sequential inflatable compression sleeves



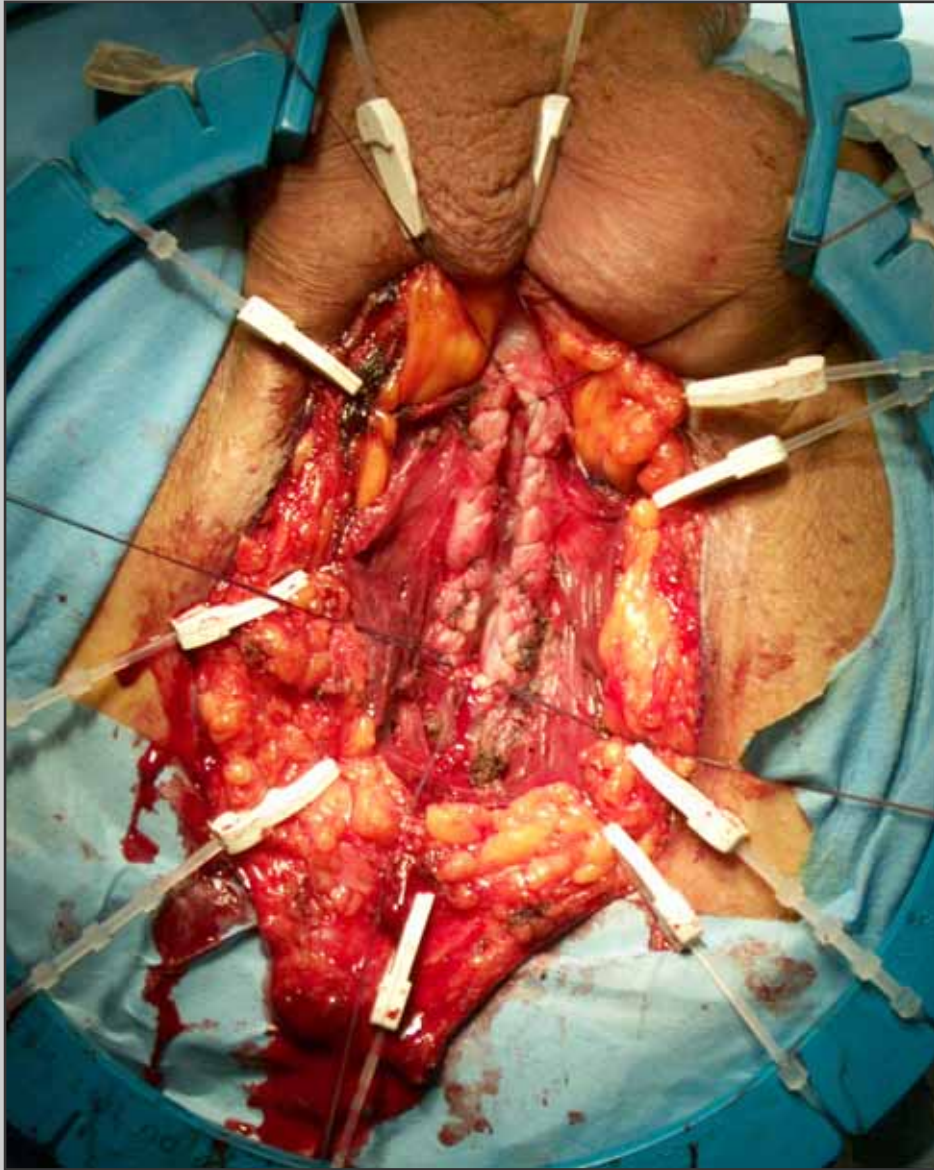
**Methylene blue is injected
into the urethra**



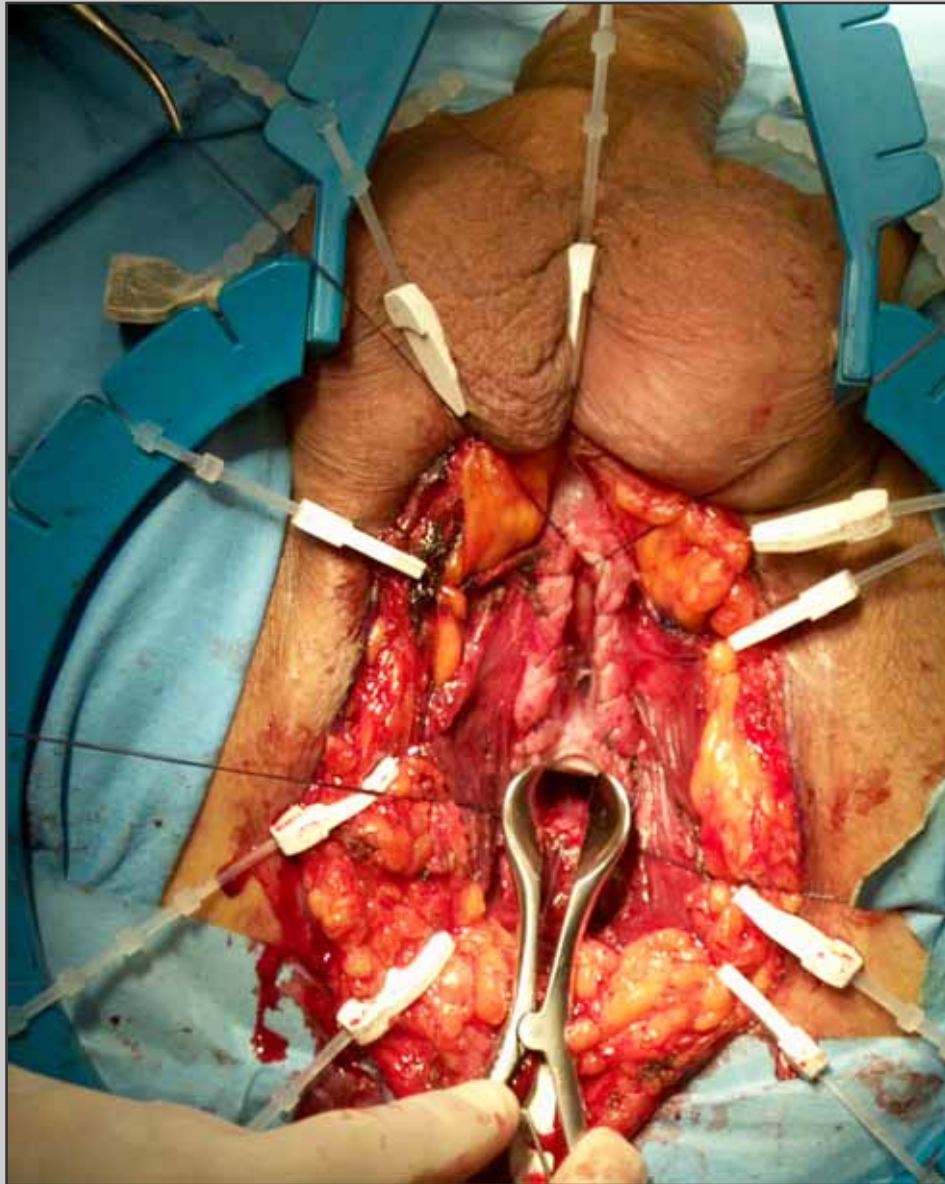
**“U” inverted perineal
incision**



**Opening of the
bulbospongiosum
muscle**



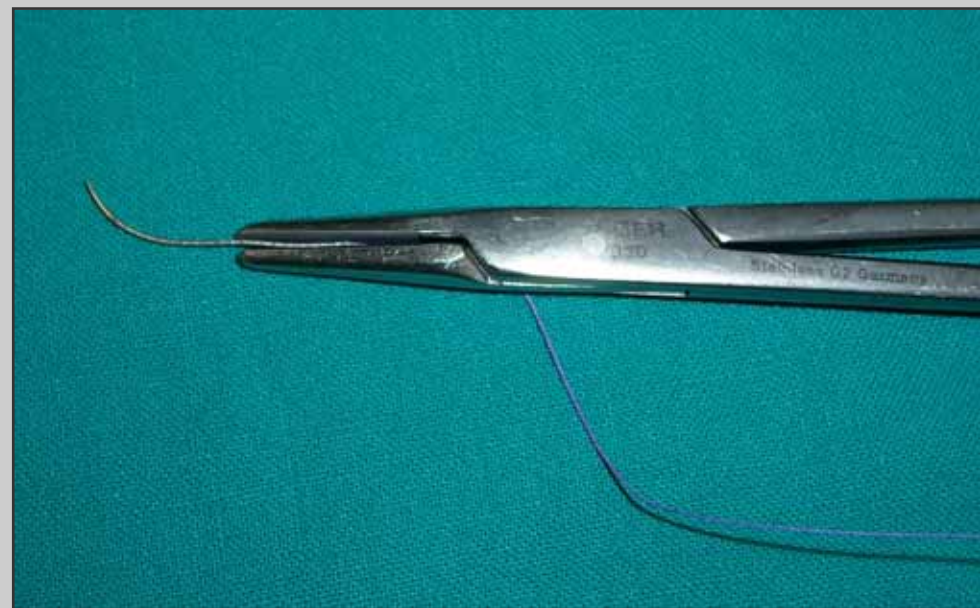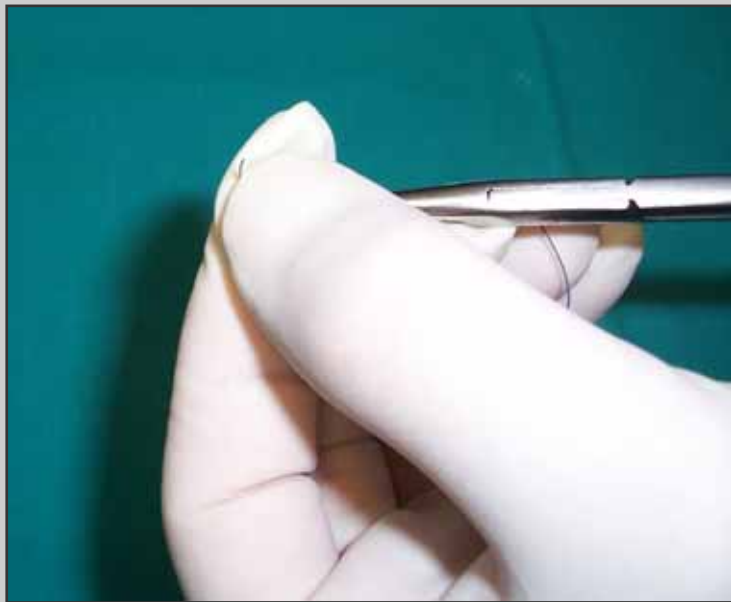
**Opening of the ventral
urethral surface and
suture of the spongiosum
tissue**

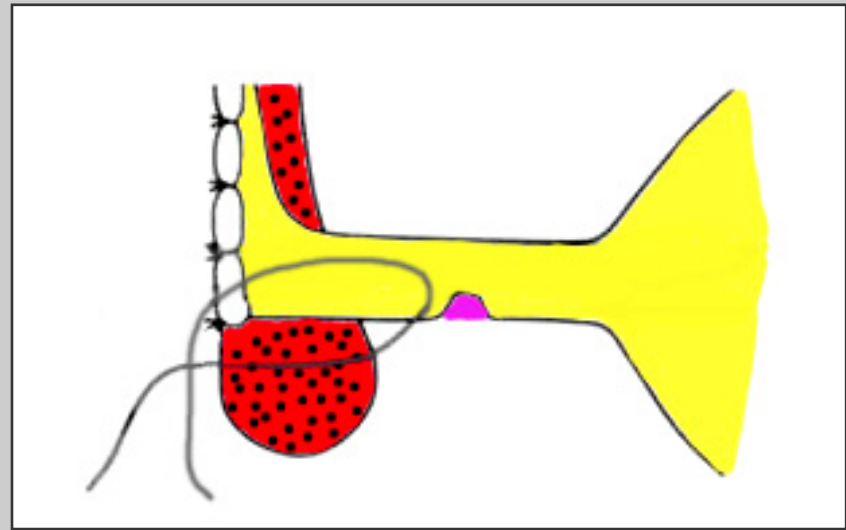
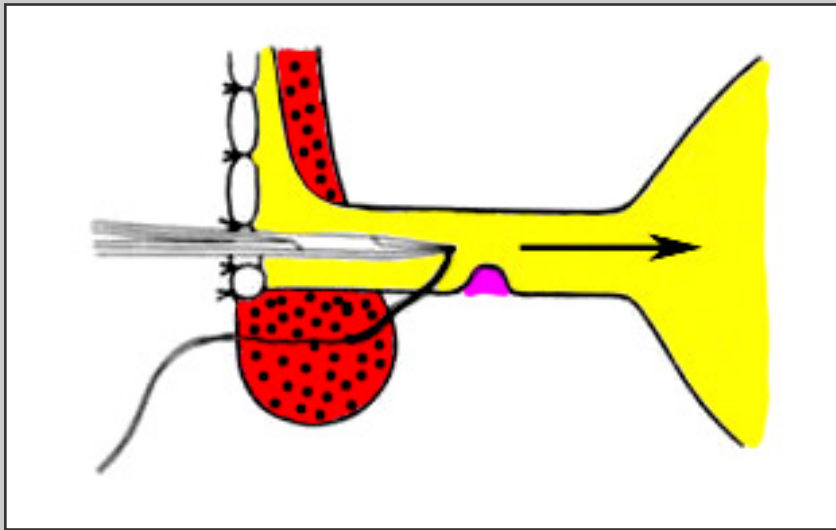
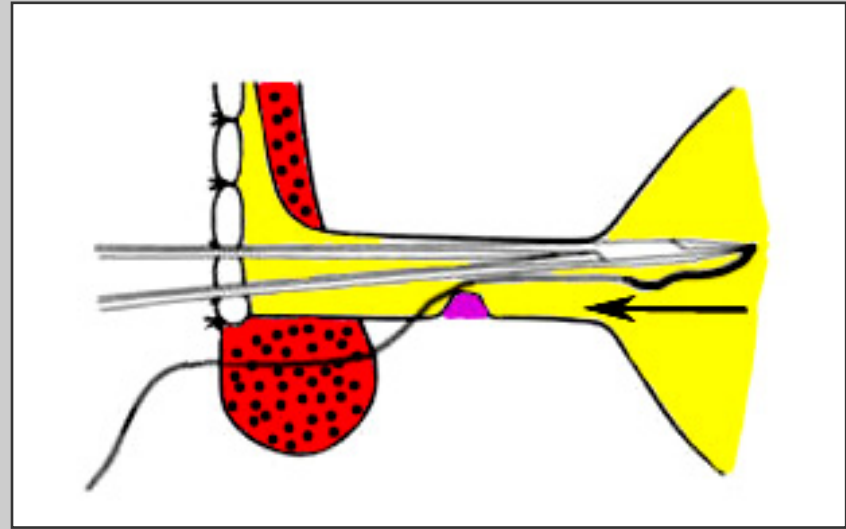
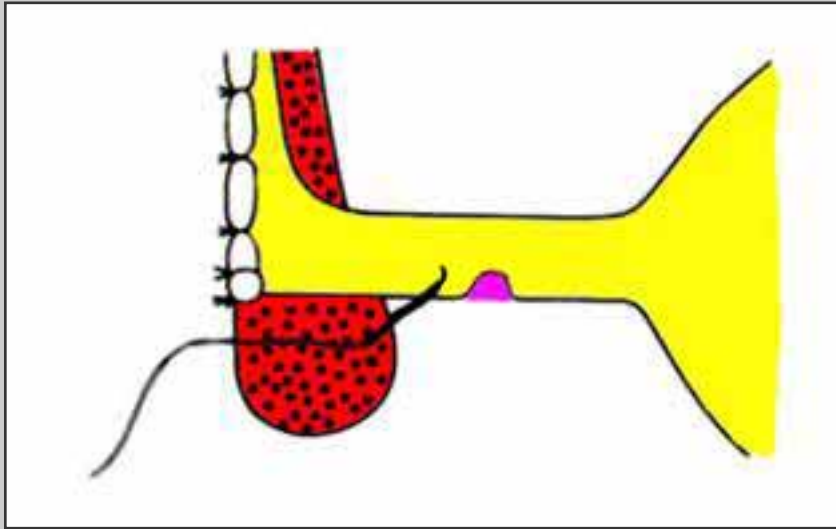


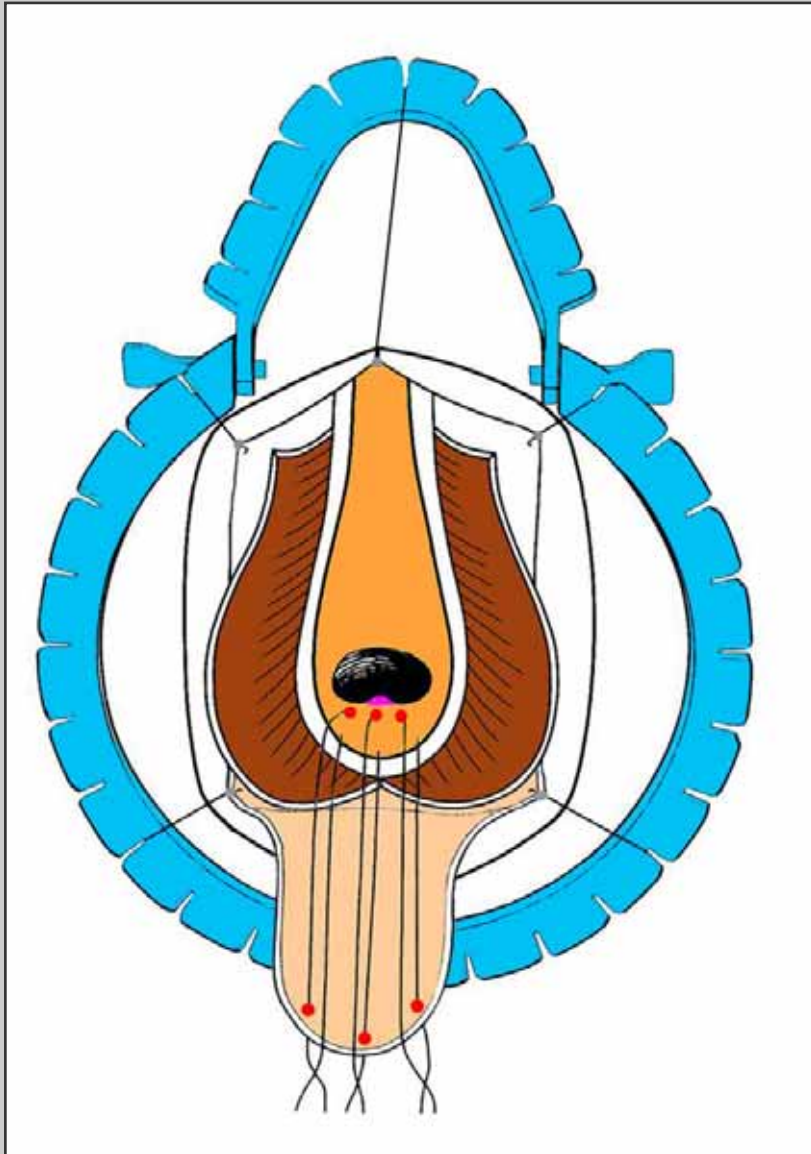
**Nasal speculum is
inserted in the proximal
urethral stoma**



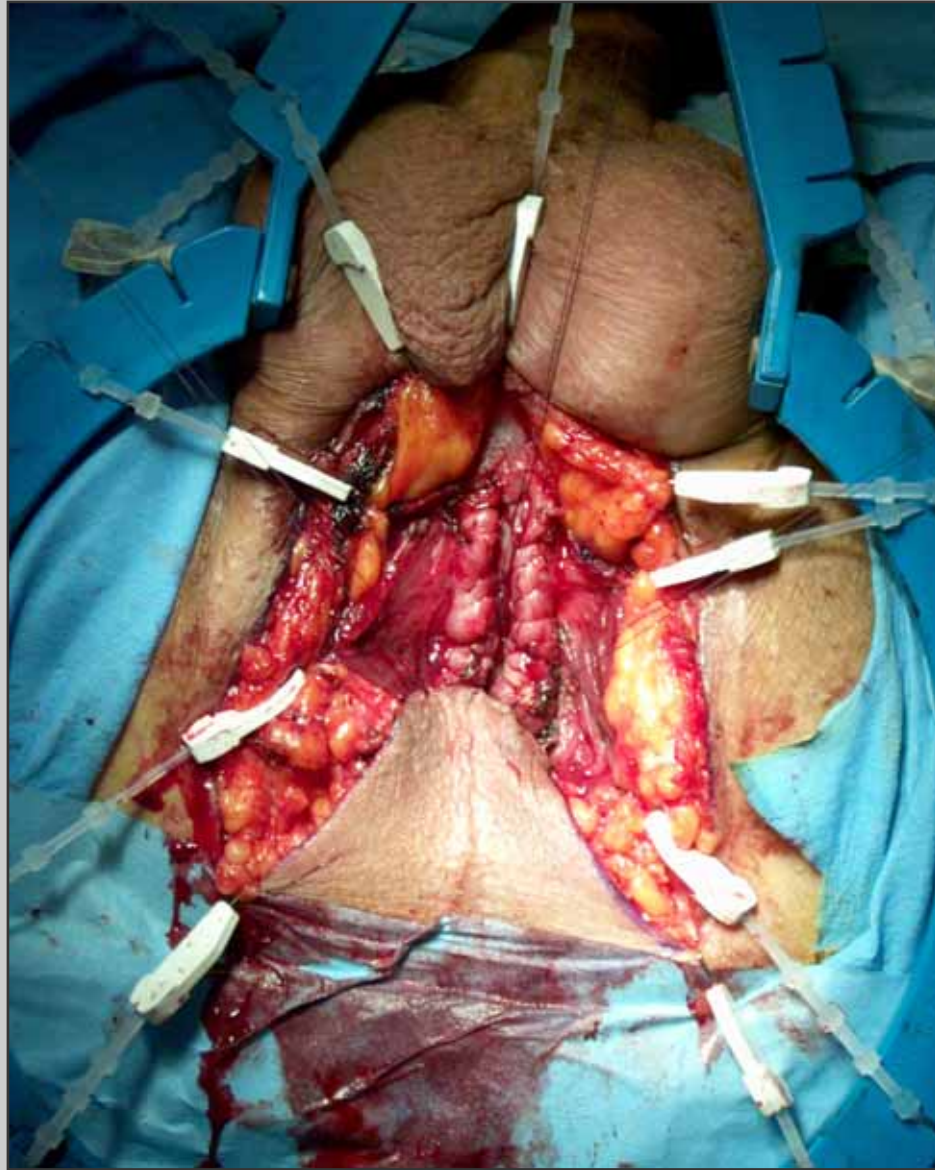
**The needle in
modified according
the Webster's
technique**



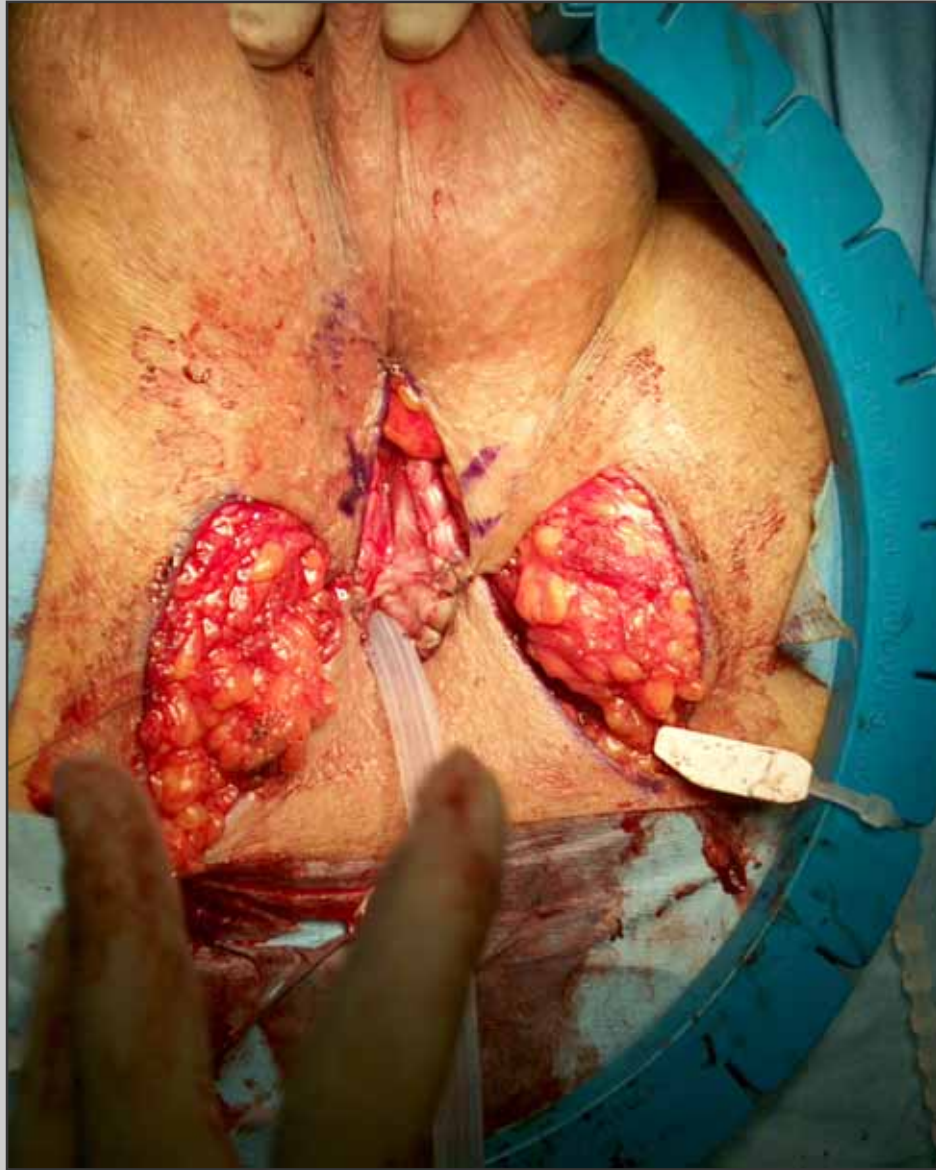




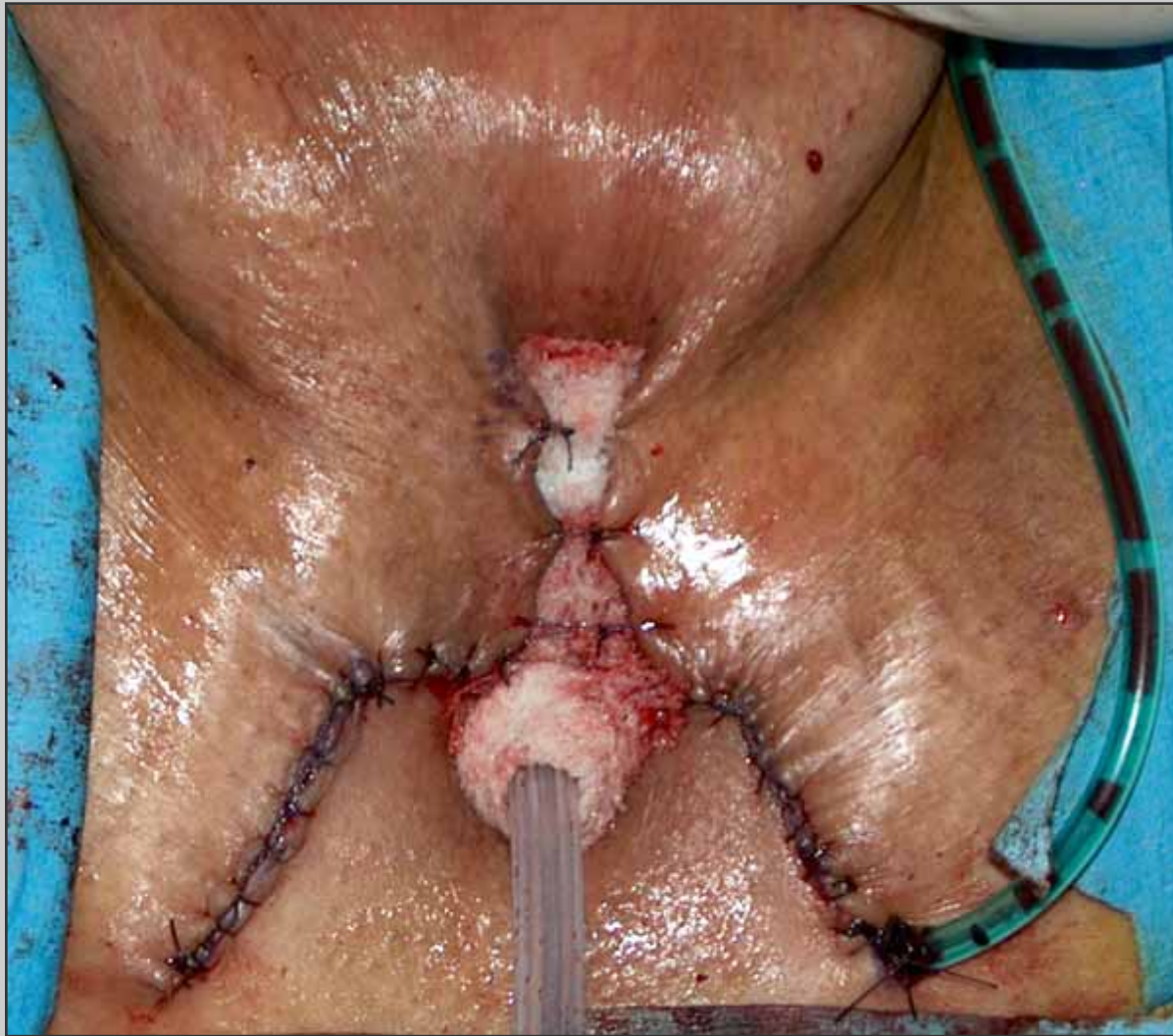**Three stitches are
passed through the apex
of the scrotal flap**



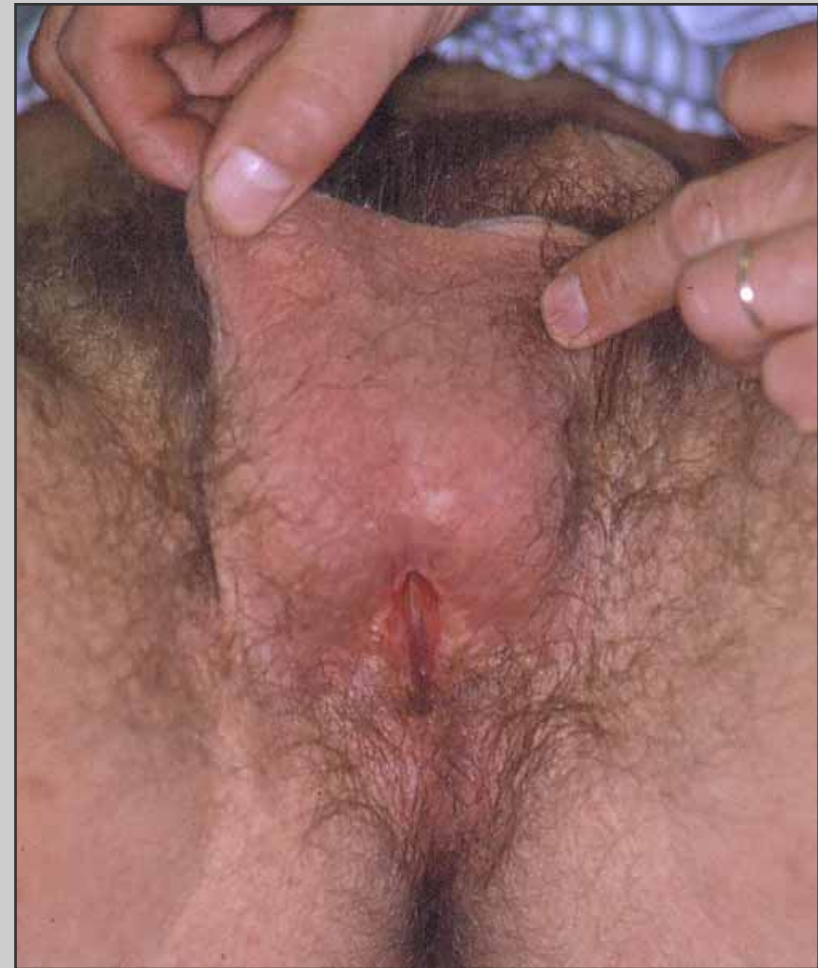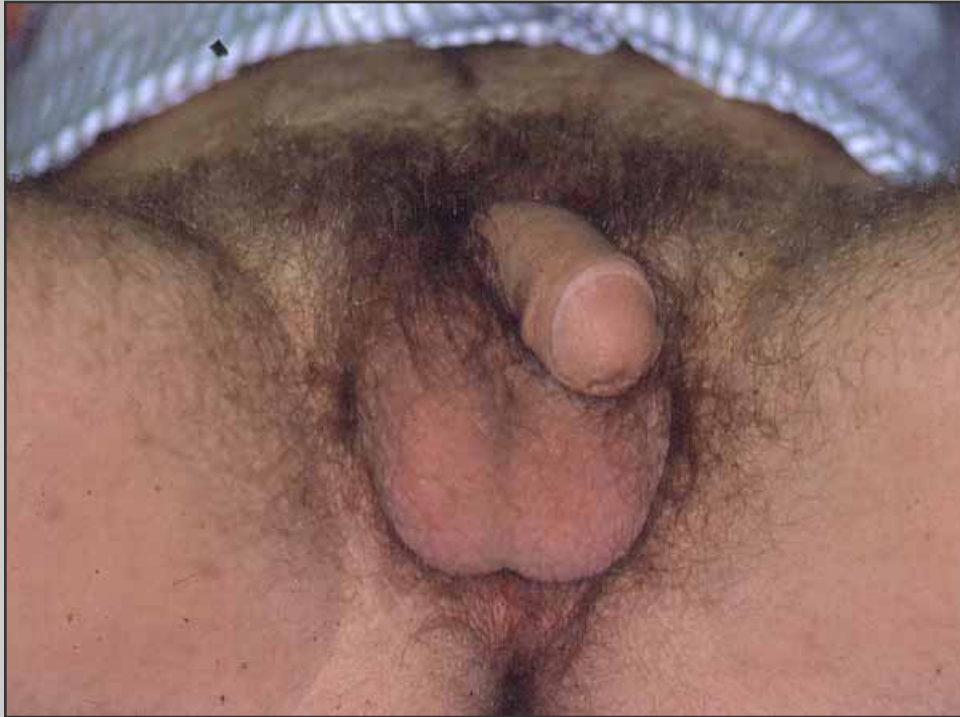**The scrotal flap is
sutured to the proximal
urethral opening**



**Two scrotal flaps are
sutured to the urethral
plate**

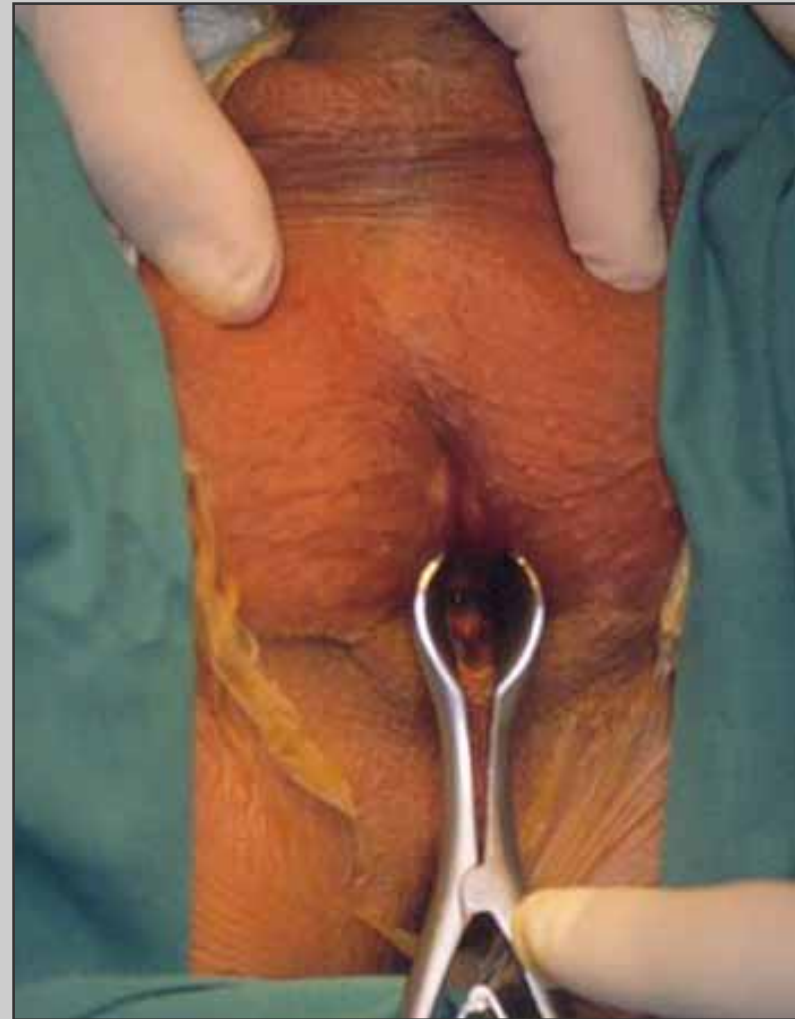
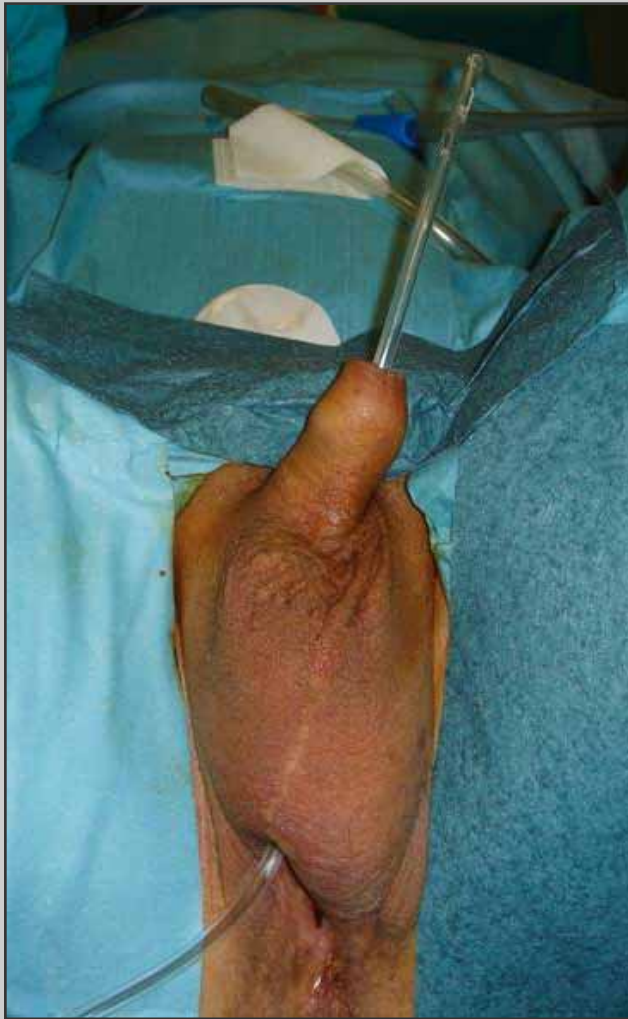
Final view of the perineal urethrostomy

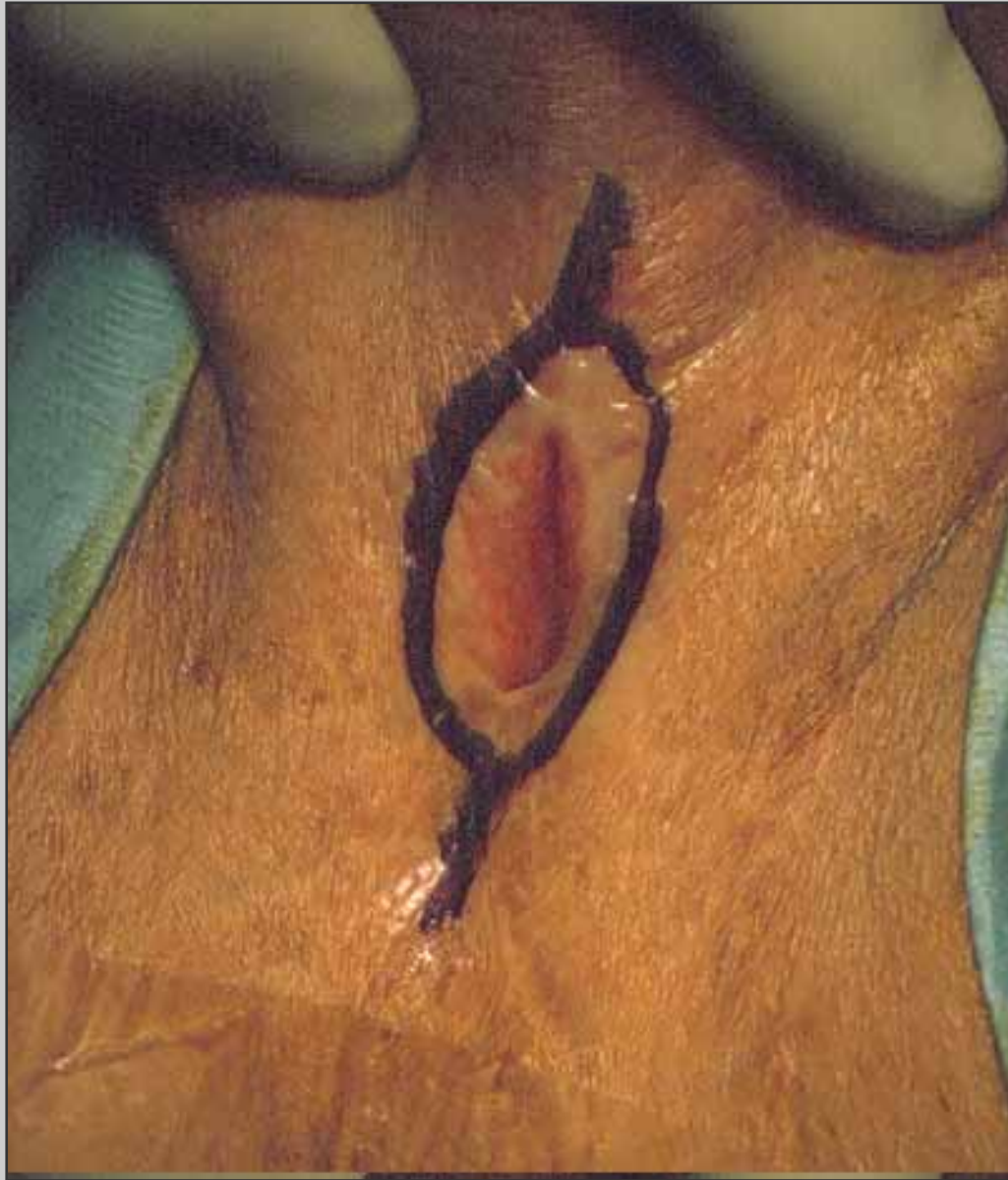

View of the perineal urethrostomy one year later

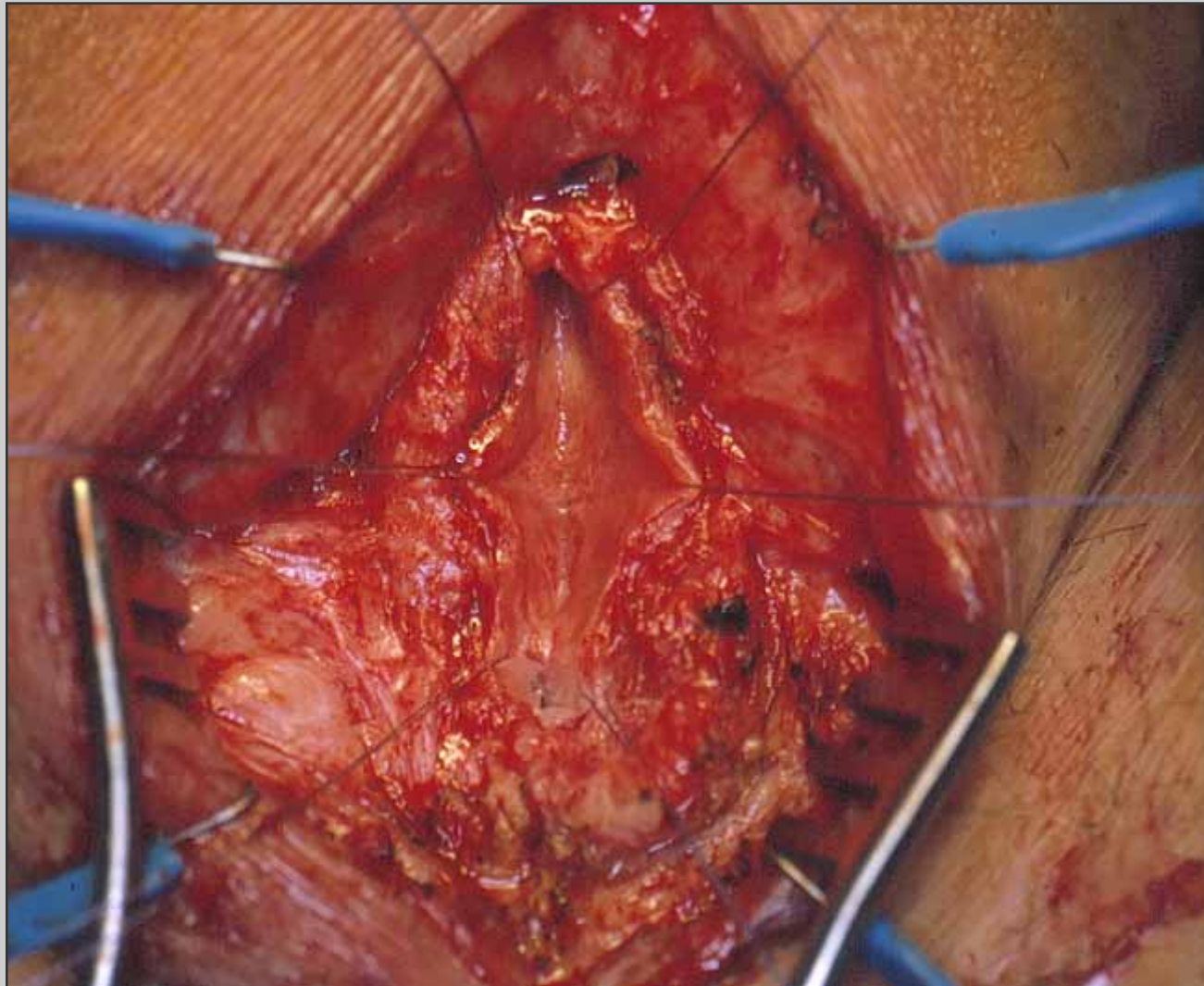
Second stage



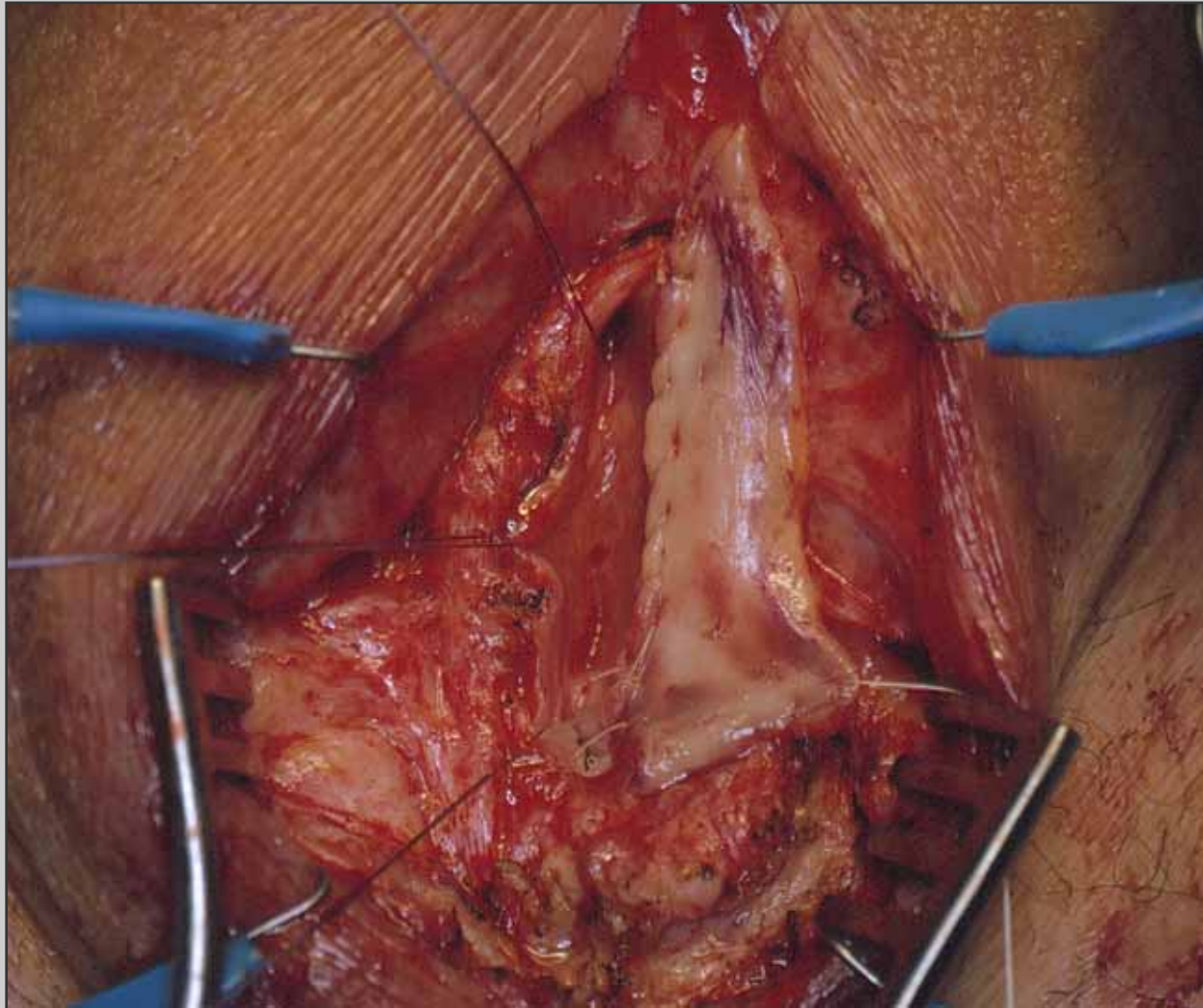
Evaluation of the distal and proximal urethra



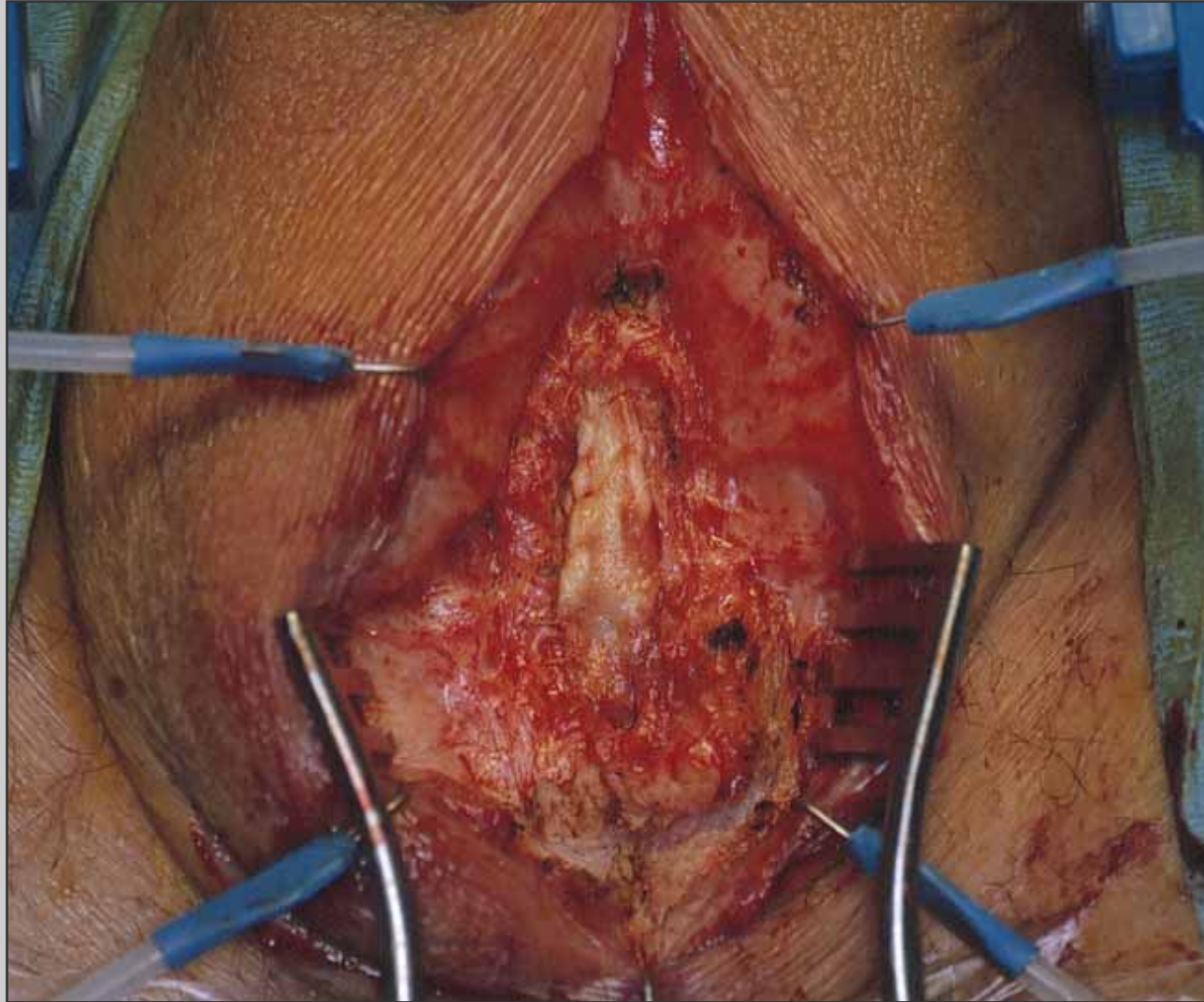
**Incision around the
perineal stoma**



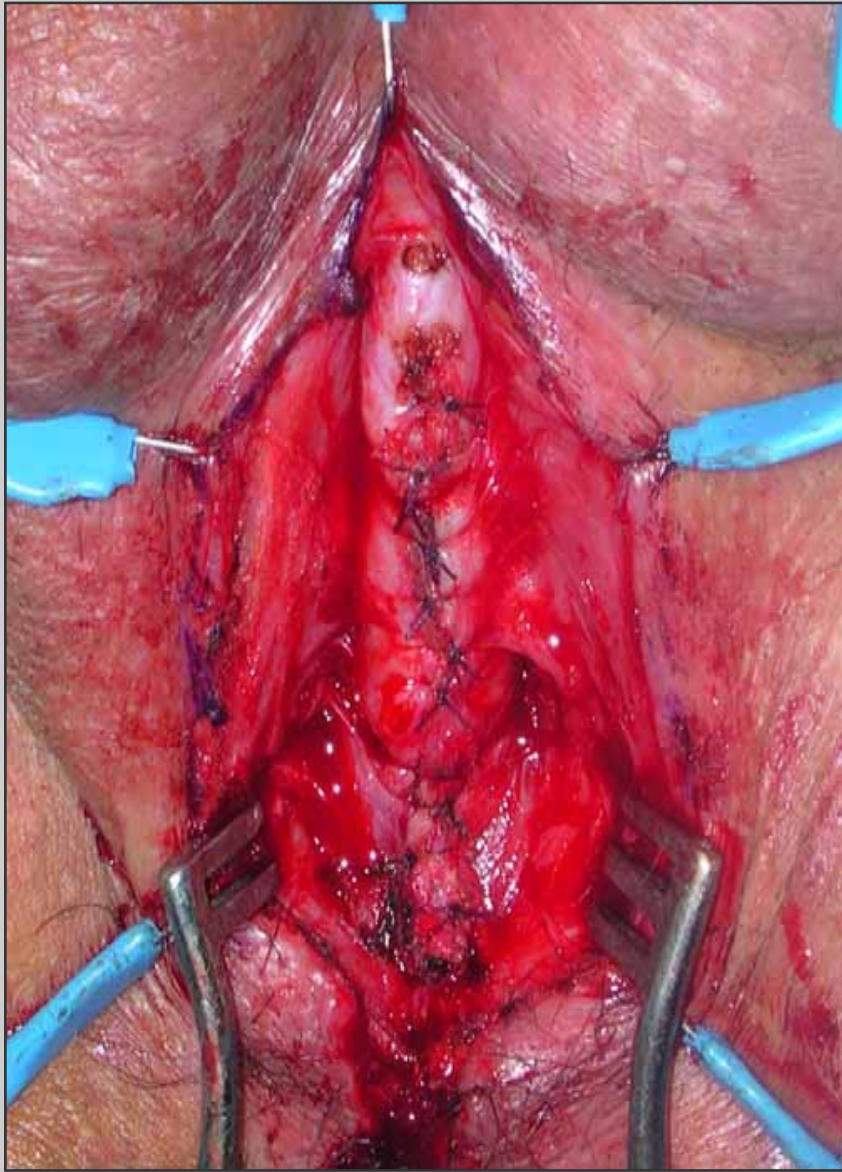
The scrotal skin is removed



Buccal mucosal graft is sutured to the urethral plate



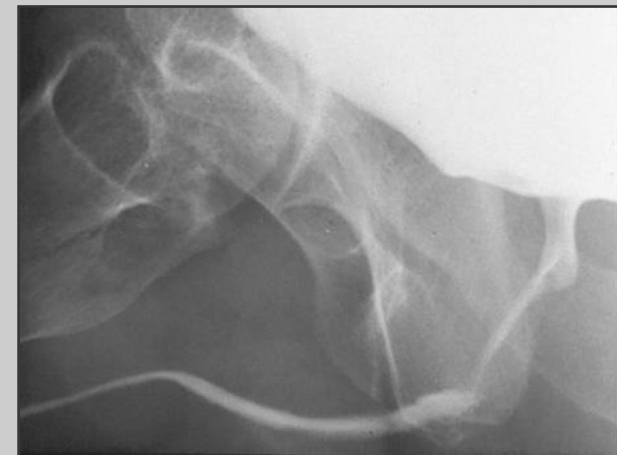
Buccal mucosal graft is rotated to cover the urethral plate



**The spongiosum tissue
is closed over the graft**

Post-operative care

- **Patient is discharged from the hospital three days after surgery**
- **Patient is maintained on oral antibiotics until the catheter is removed**
- **Three weeks following surgery, the catheter is removed and voiding cysto-urethrography is obtained**



Post-operative complications

- **Temporary numbness or dysesthesia to the perineum**
- **Scrotal swelling**
- **Urethral fistula**