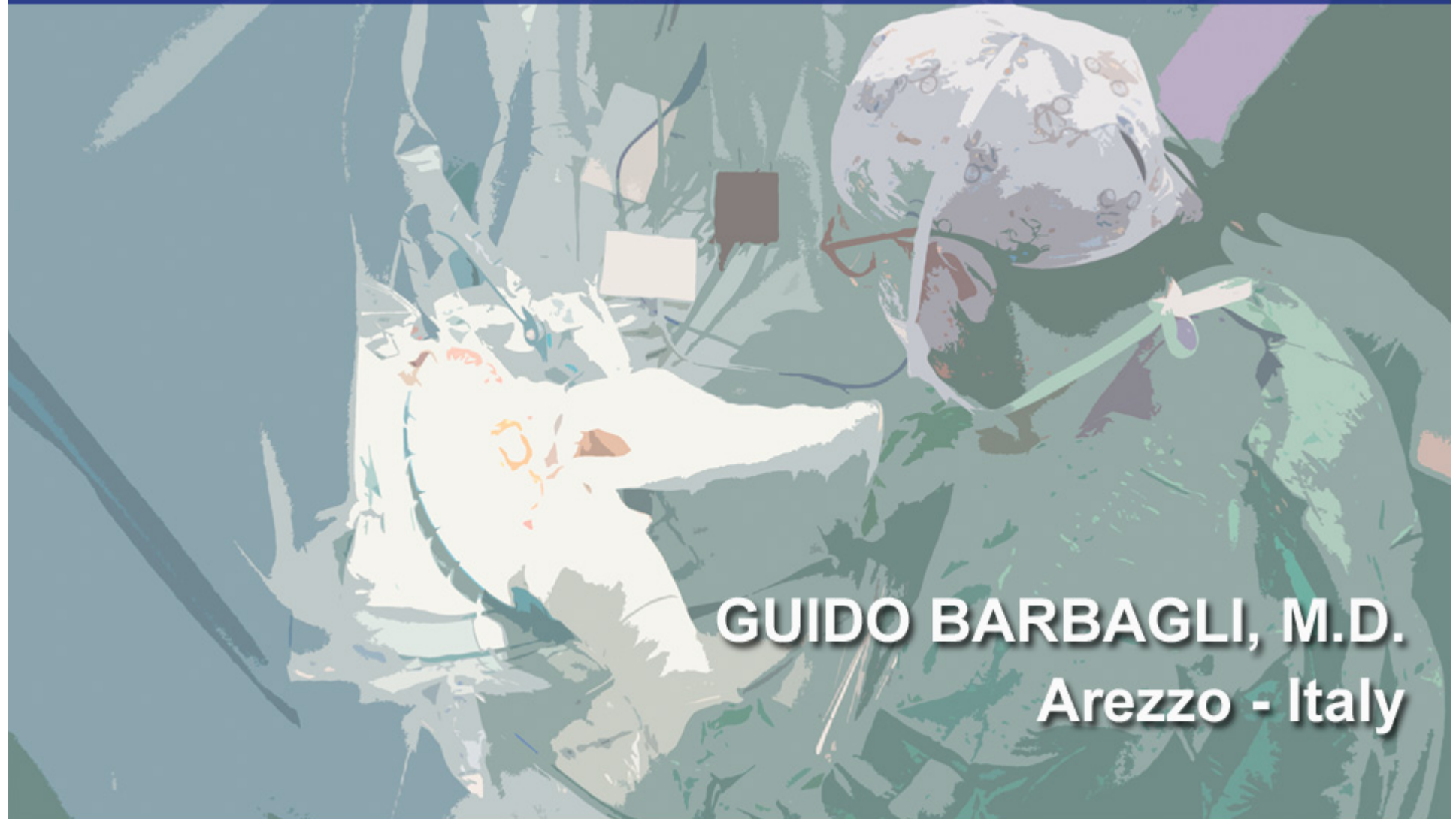

CENTER FOR RECONSTRUCTIVE URETHRAL SURGERY



GUIDO BARBAGLI, M.D.
Arezzo - Italy

e-mail: info@urethralcenter.it

Websites: www.uretra.it
www.urethralcenter.it

URETHRAL REPAIR AND RECONSTRUCTION FORUM

Urethral Strictures and Reconstruction



Shanghai – Cina
Saturday 5, 2015

e-mail: info@urethralcenter.it

Websites: www.uretra.it
www.urethralcenter.it

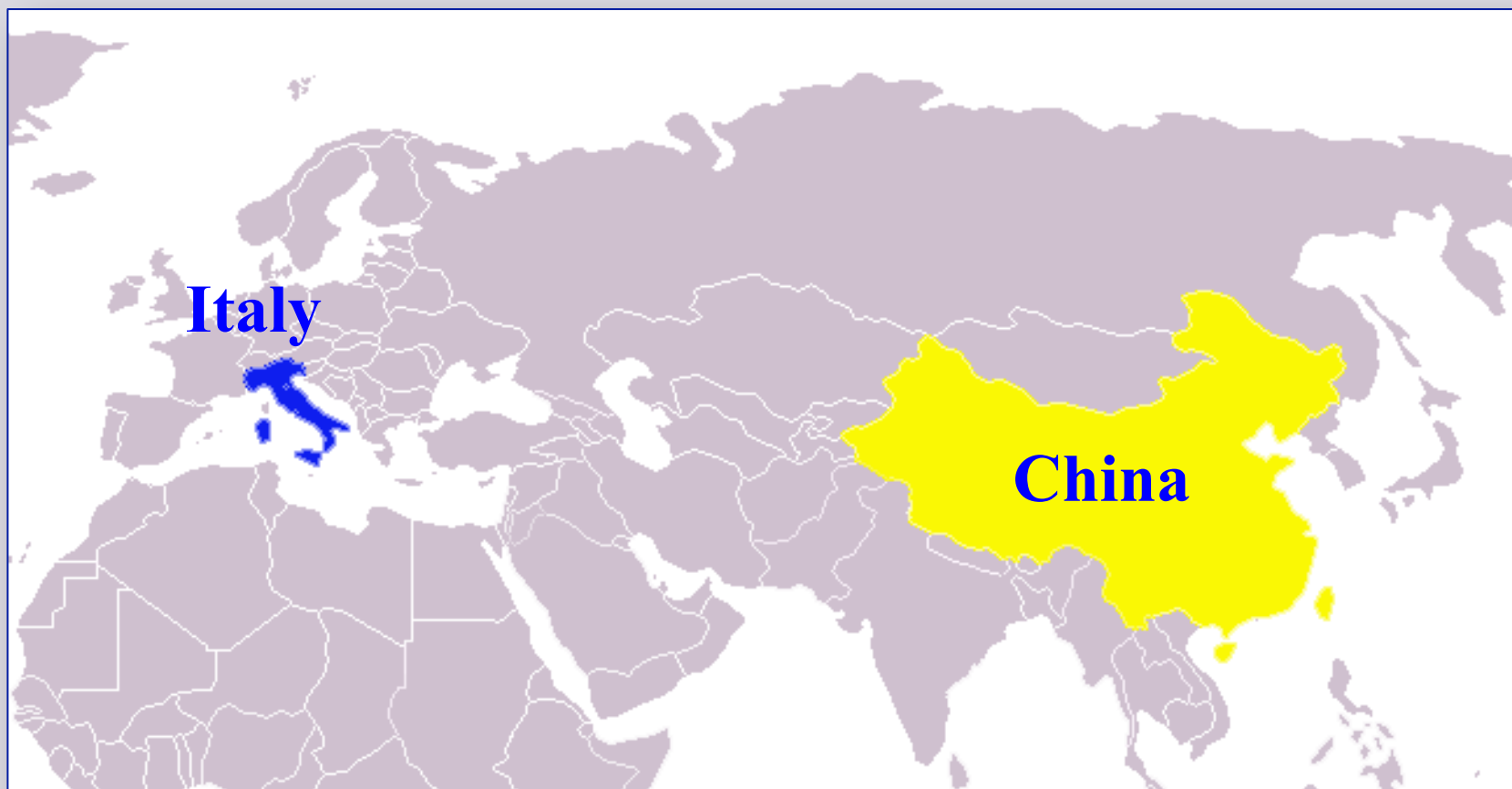**How you choice for anterio urethroplasty:
Free graft or skin flap ?**

A geographic analysis of male urethral stricture aetiology and location

Daniel M. Stein, D. Joseph Thum, Guido Barbagli*, Sanjay Kulkarni†, Salvatore Sansalone‡, Ashish Pardeshi† and Chris M. Gonzalez

*Department of Urology, Feinberg School of Medicine, Northwestern University, Chicago, IL, USA, *Center for Reconstructive Urethral Surgery, Arezzo, Italy, †Kulkarni Urethroplasty Center, Pune, India, and ‡Department of Urology, School of Medicine Tor Vergata, University of Rome, Rome, Italy*

BJU Int 2013; 112:830-834

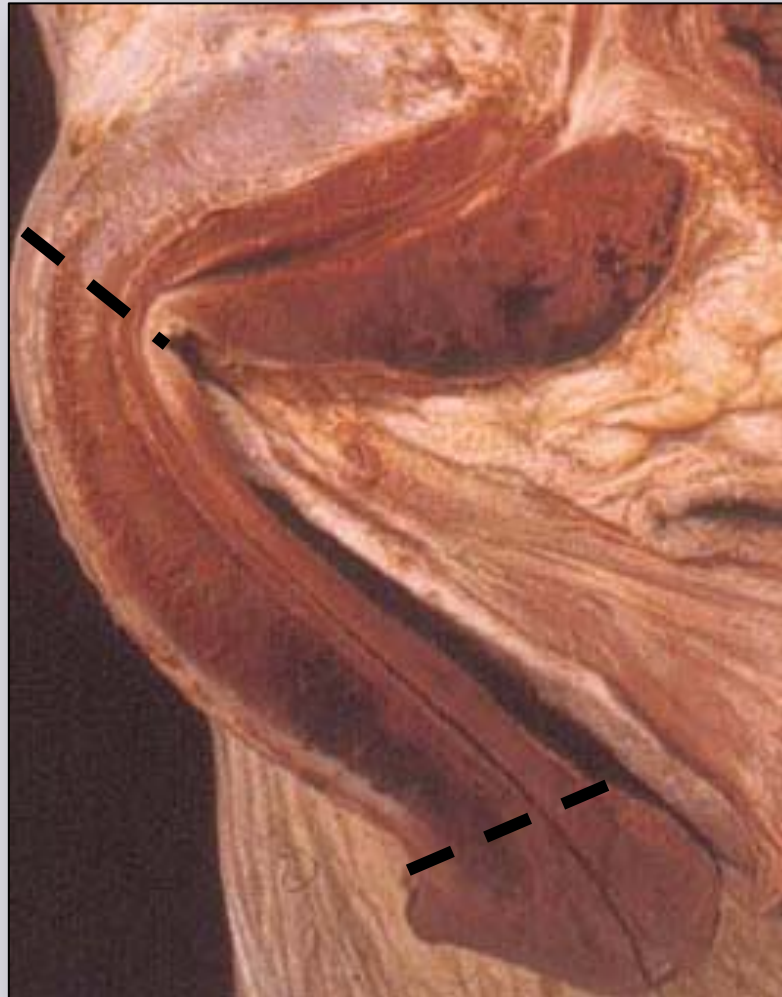


e-mail: info@urethralcenter.it

Websites: www.uretra.it
www.urethralcenter.it

CENTER FOR RECONSTRUCTIVE URETHRAL SURGERY

Anterior urethra

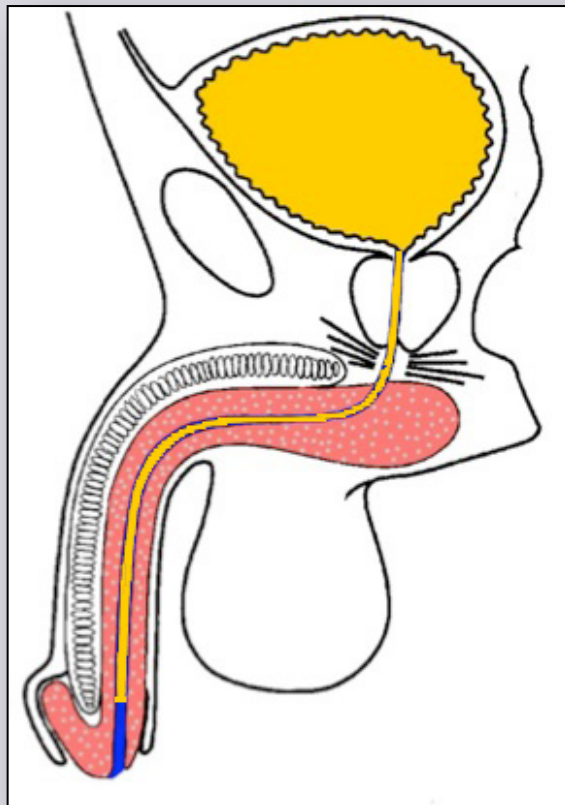


**Penile
urethra**

Bulbar urethra

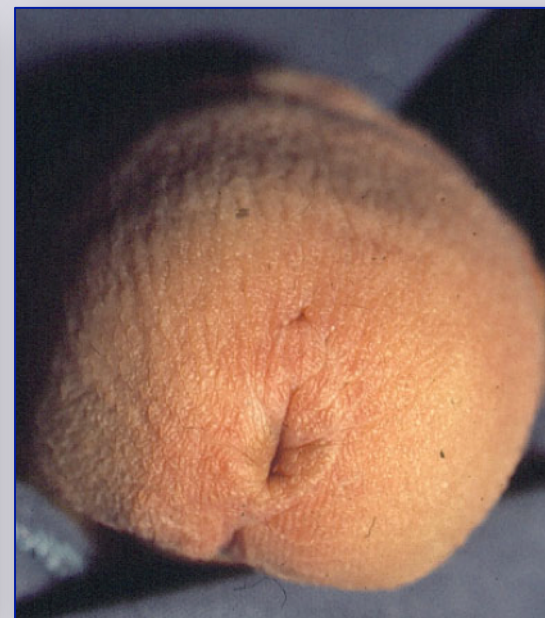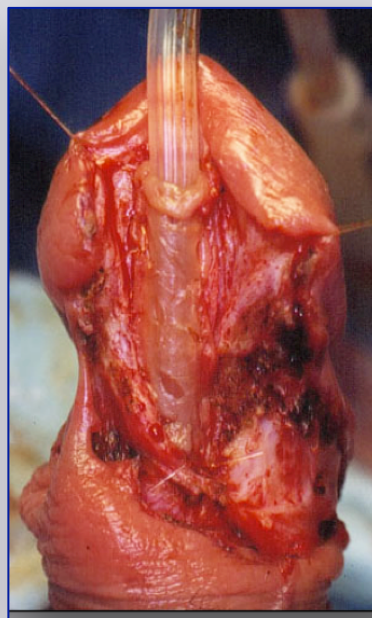
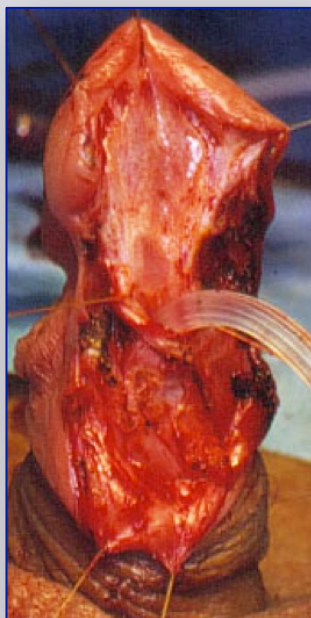
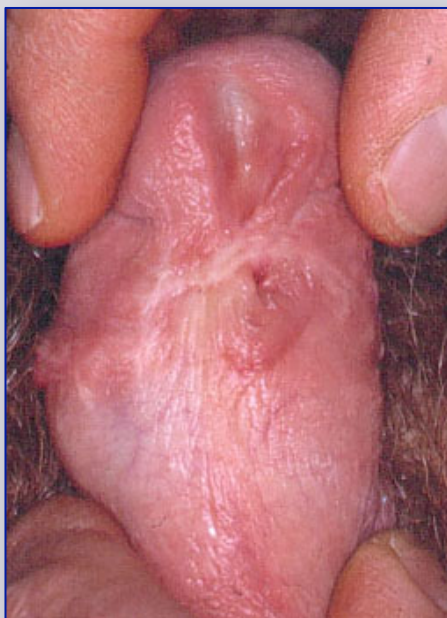**Navicularis
urethra**

Navicularis urethra

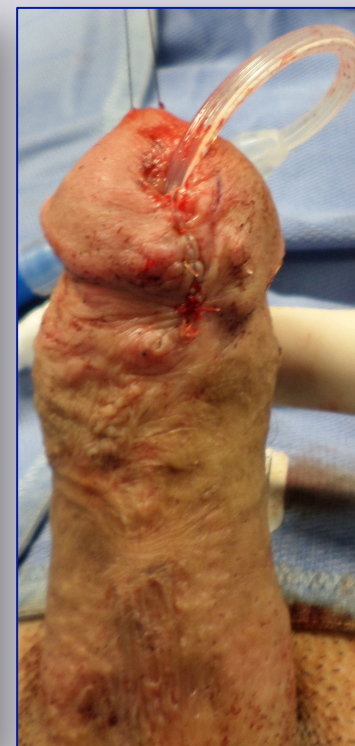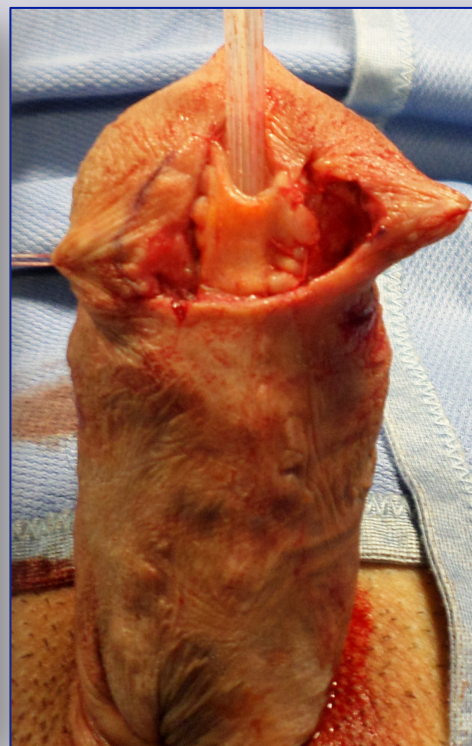

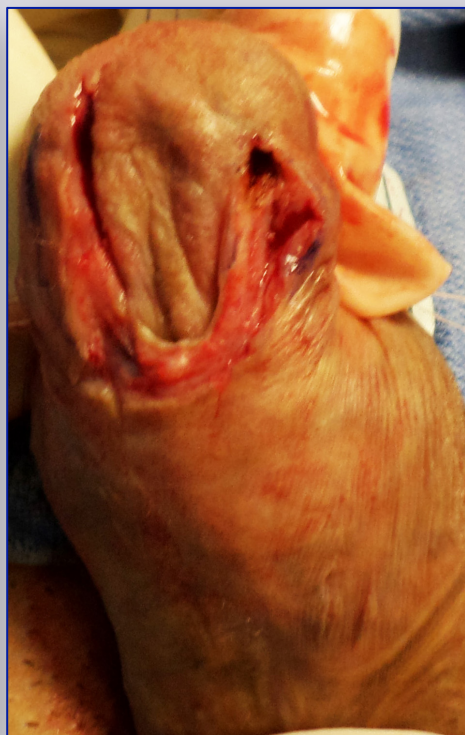
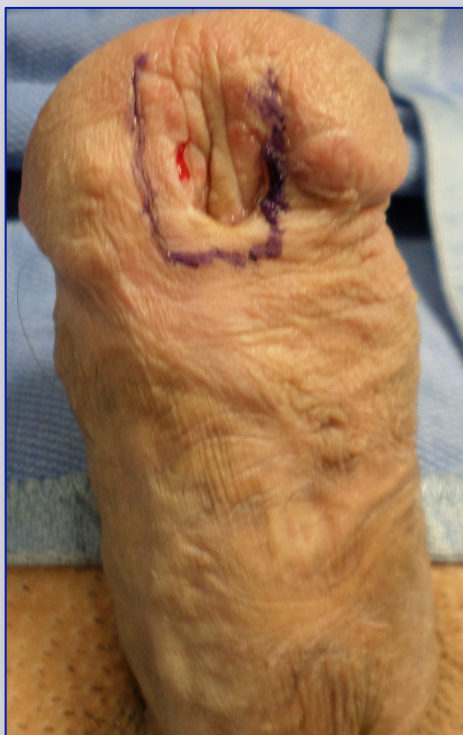Graft or Flap ?

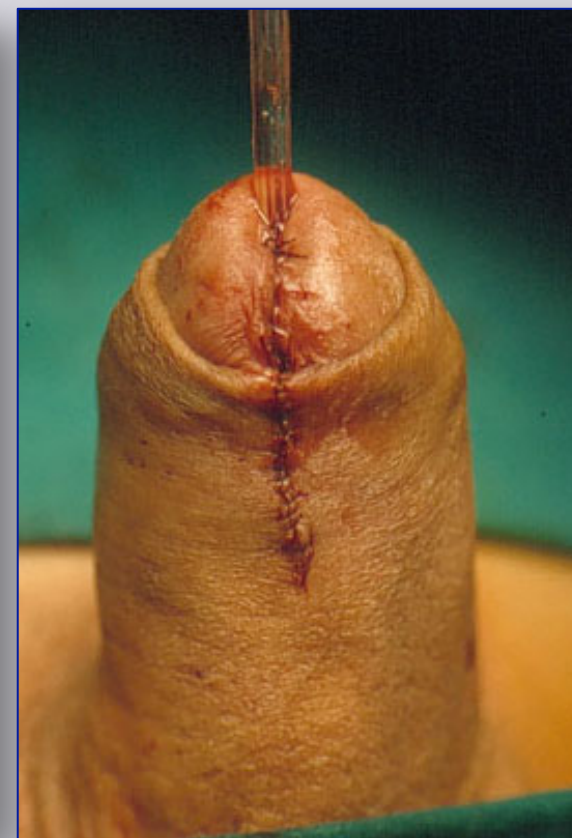
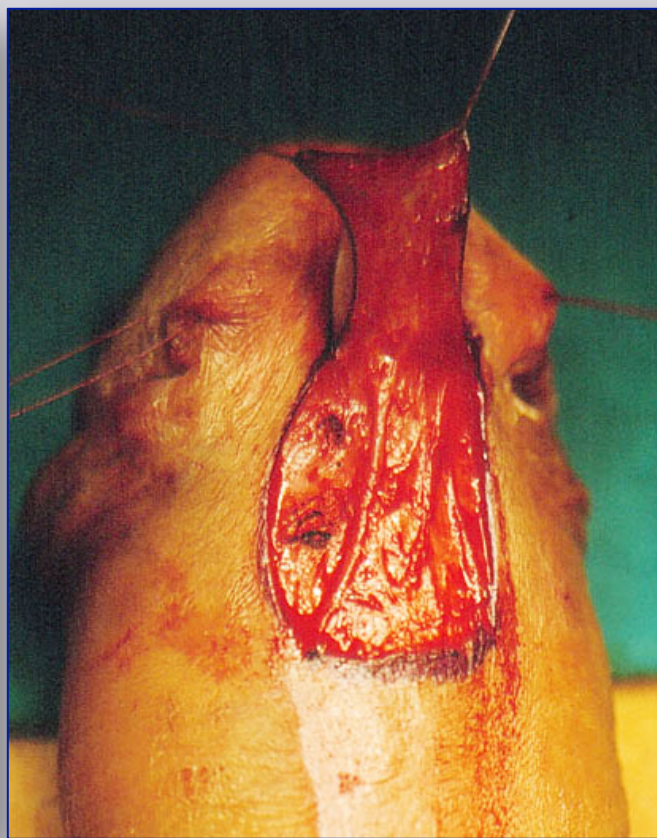
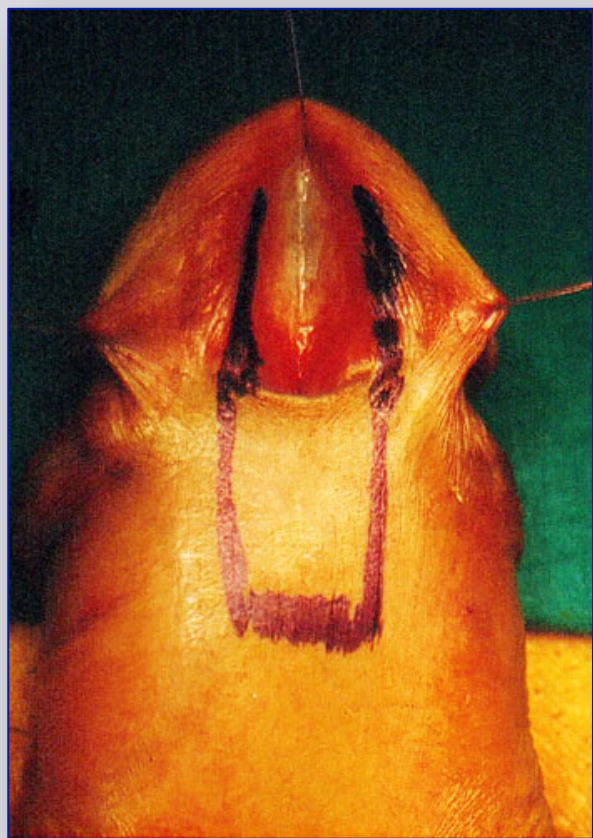
Graft meatoplasty using preputial skin



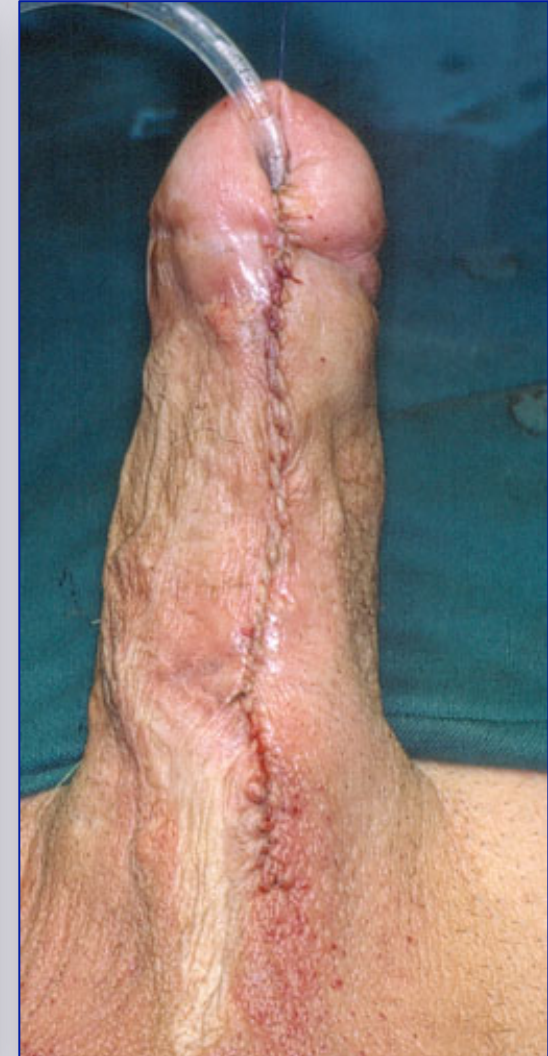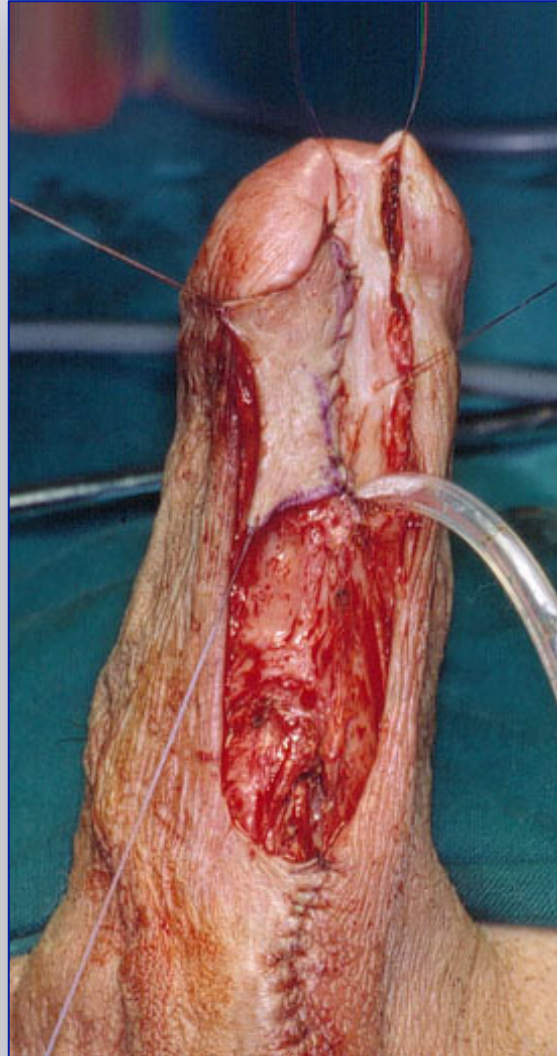
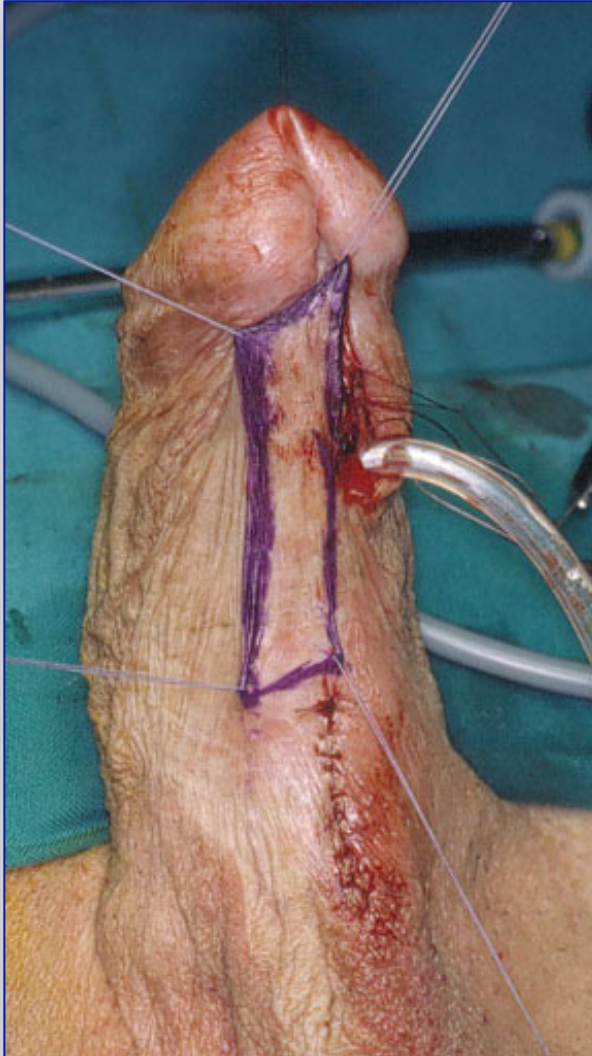
Graft meatoplasty using oral mucosa



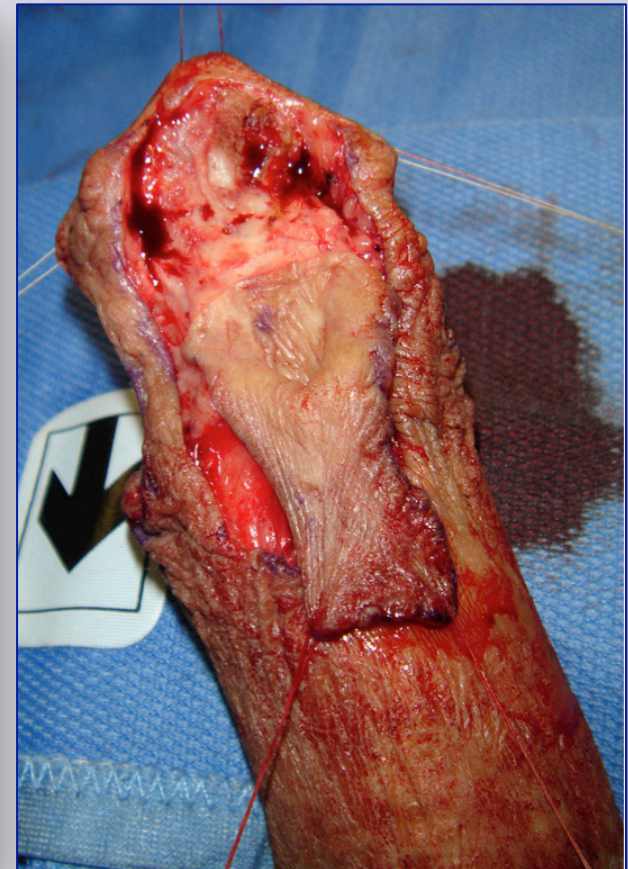
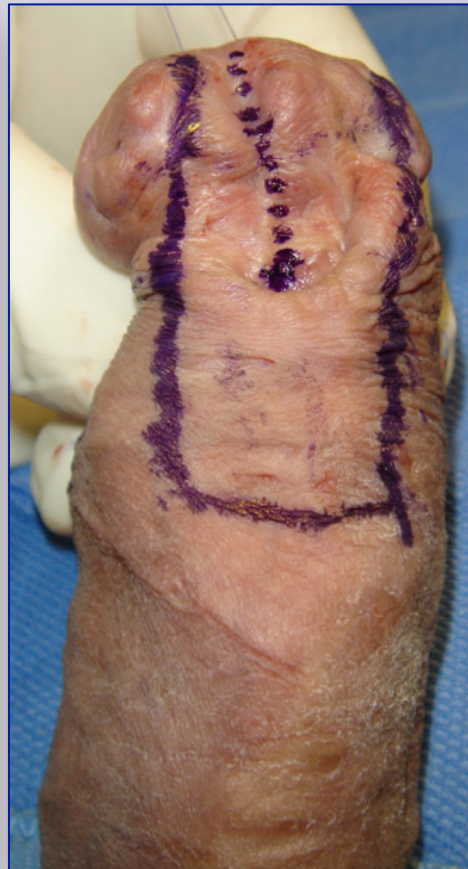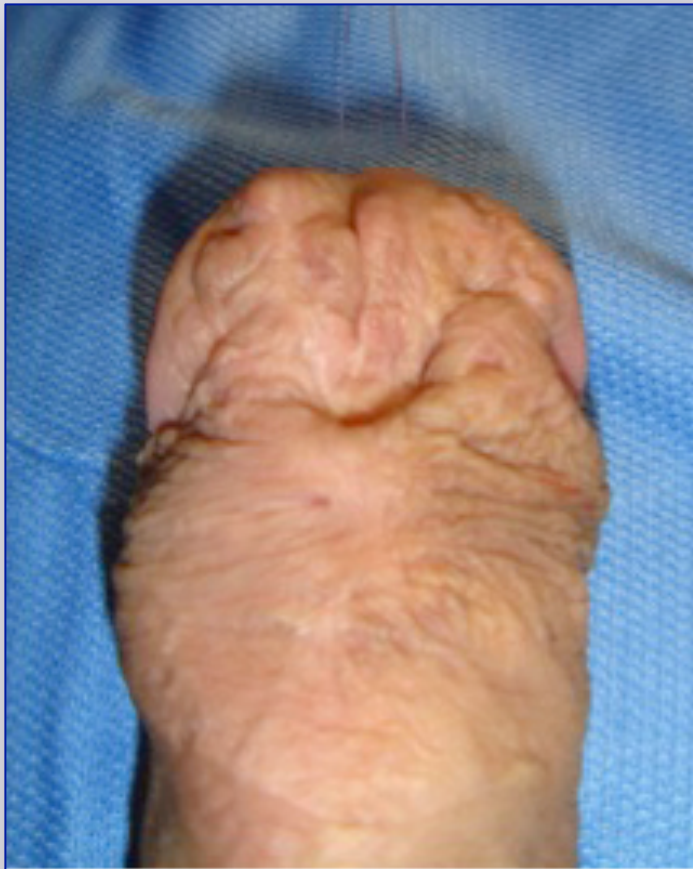Skin flap meatoplasty



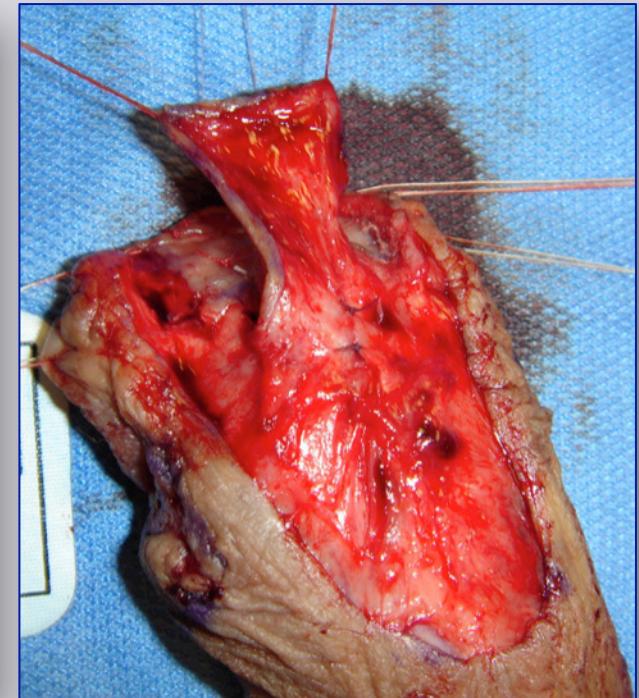
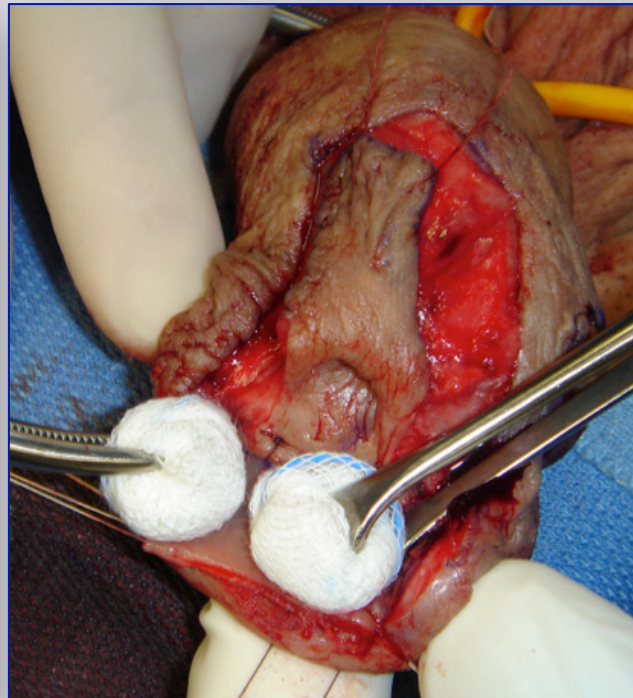
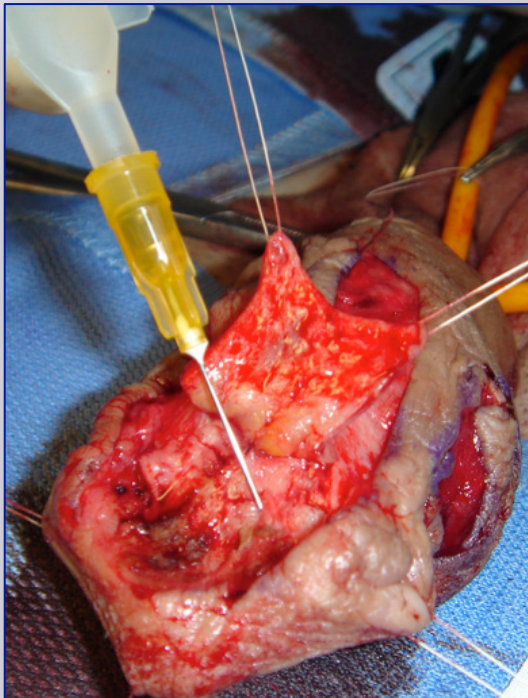
Skin flap meatoplasty



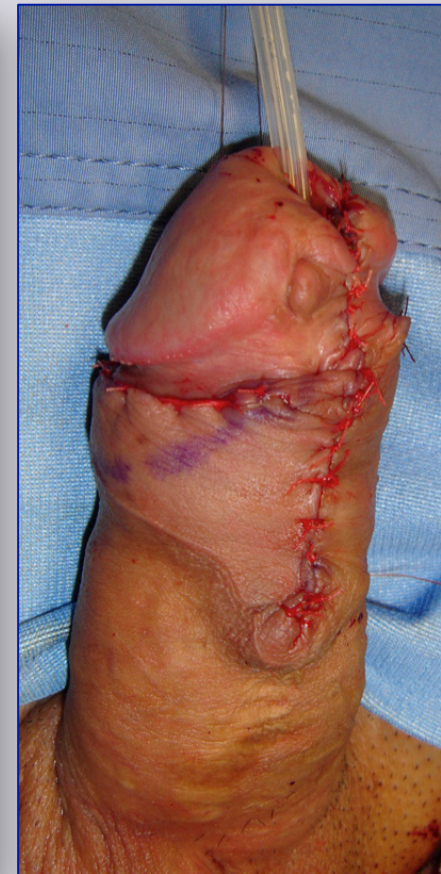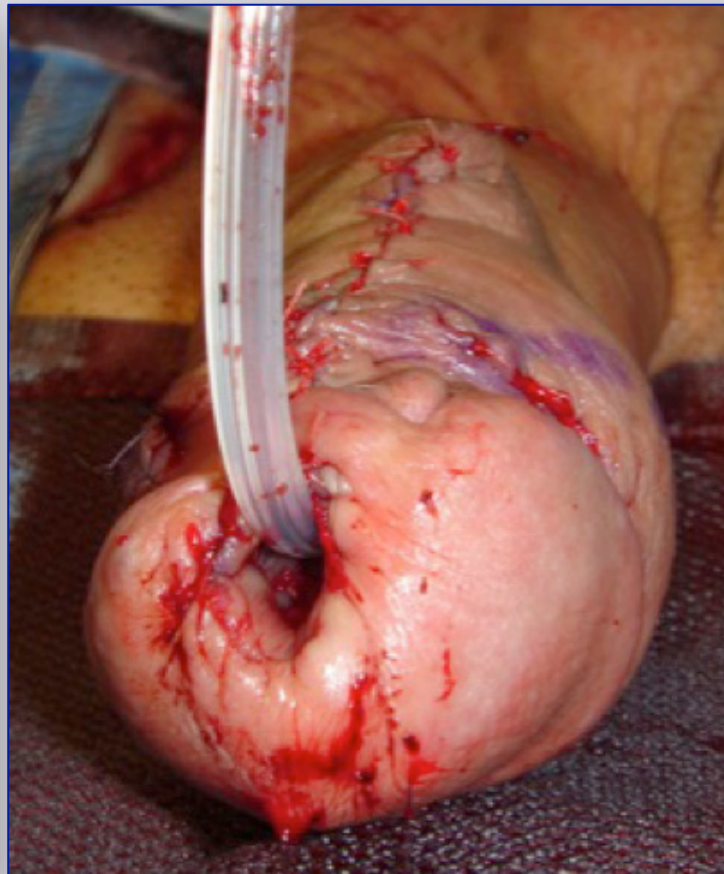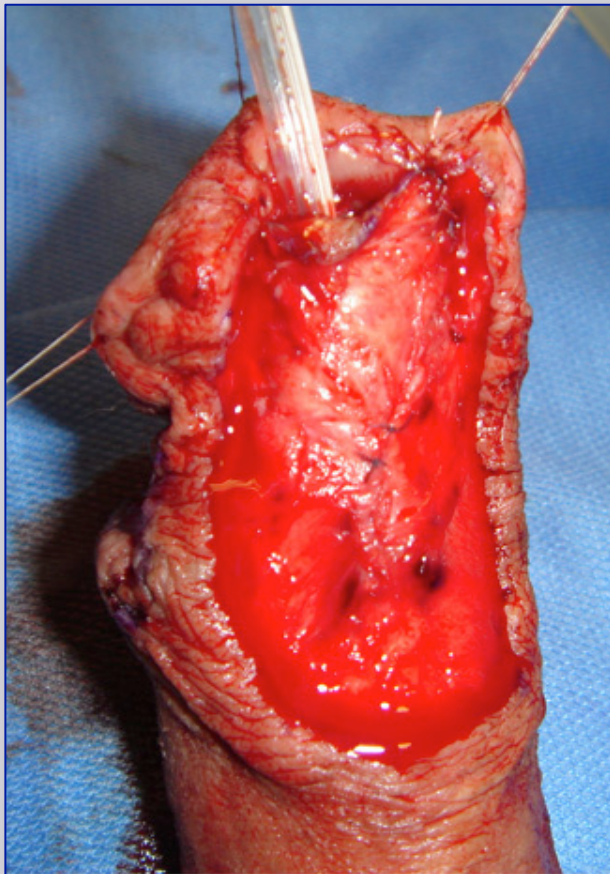
Combined flap and graft urethroplasty with a new glue (Glubran 2)



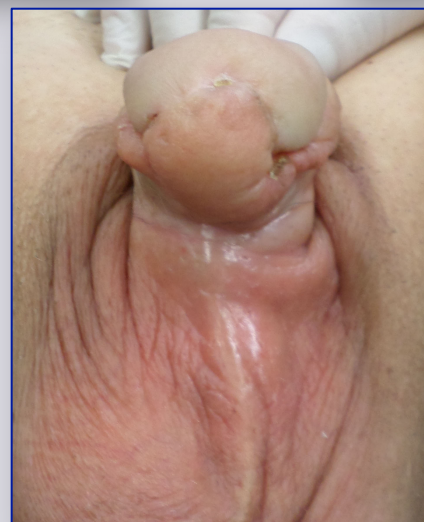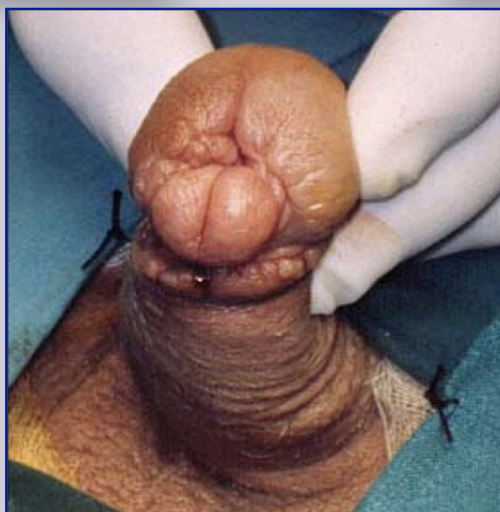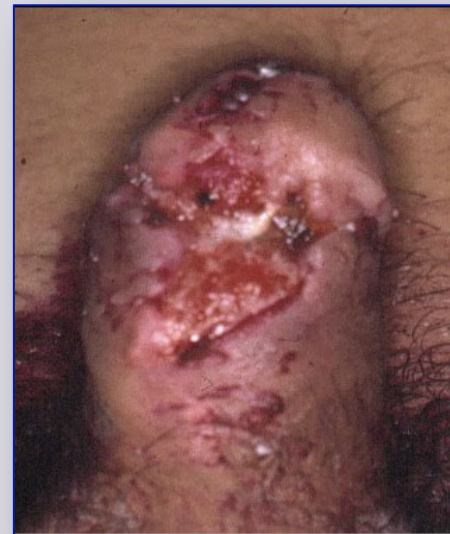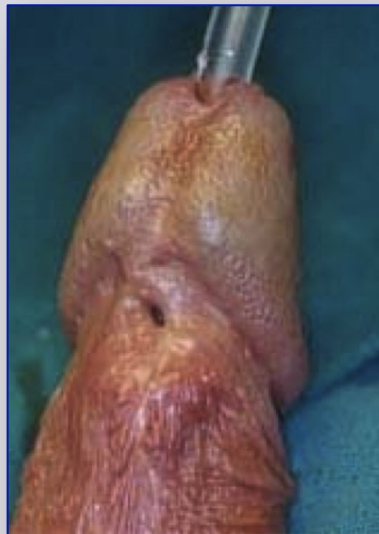
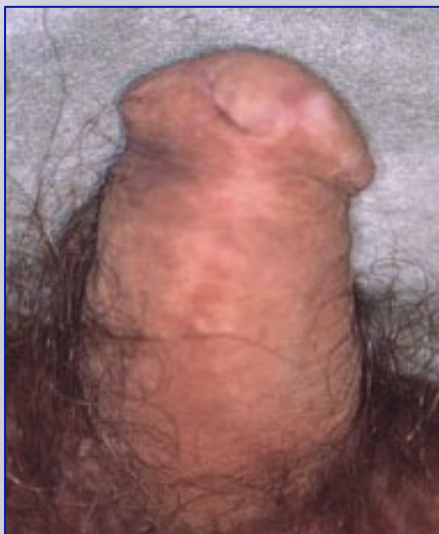Combined flap and graft urethroplasty with new glue (Glubran 2)



Combined flap and graft urethroplasty with new glue (Glubran 2)

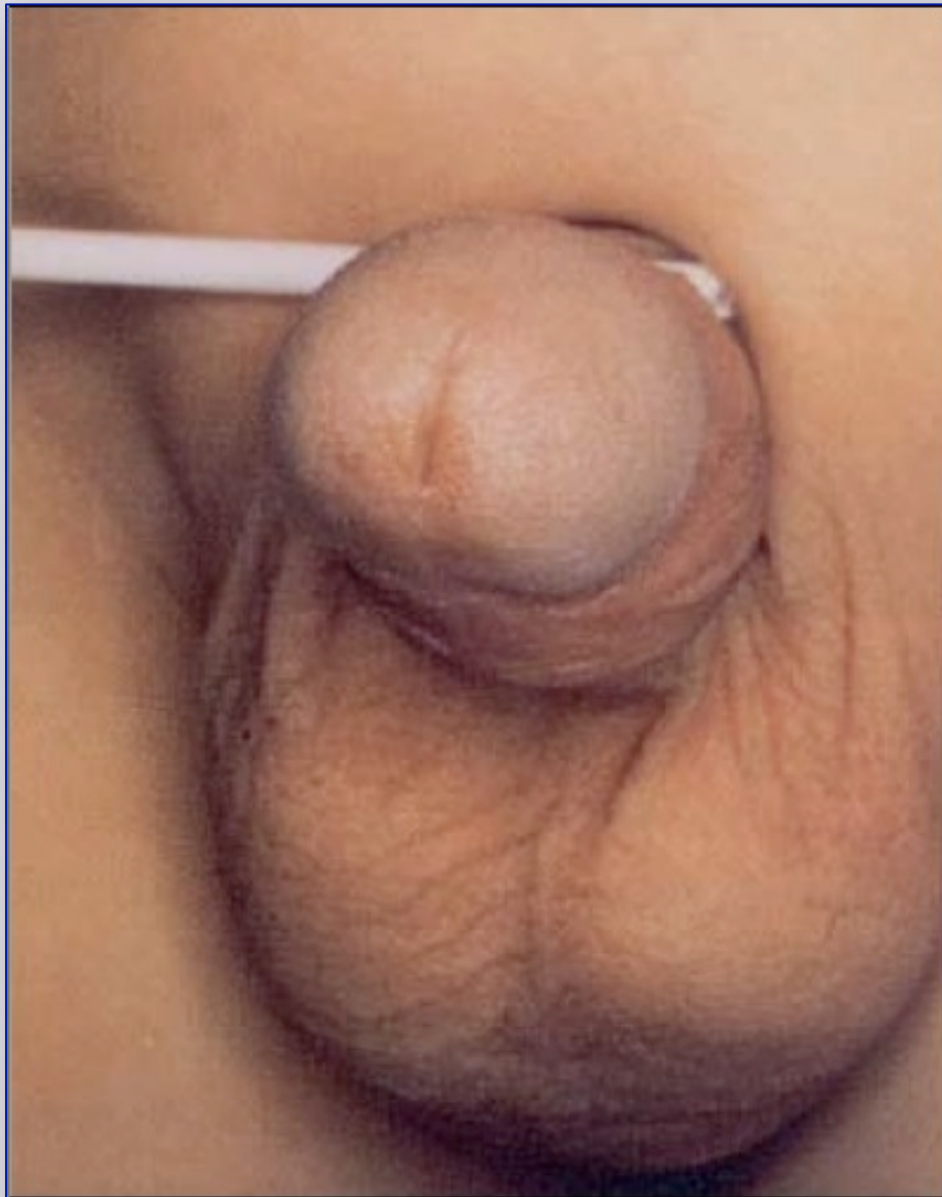

Complications of meatoplasty



How you choice for navicularis urethroplasty: Free graft or skin flap ?

- 1. Free graft or skin flap are both adaptable techniques for navicularis urethroplasty.**
- 2. The choice is mainly based on surgeon preference and background and patient/penis characteristics:**
 - a) glans size-shape-conformation**
 - b) penile skin conformation: normal vs scarred**
 - c) stricture etiology: failed hypospadias vs. other**
 - d) patient age and expectation**

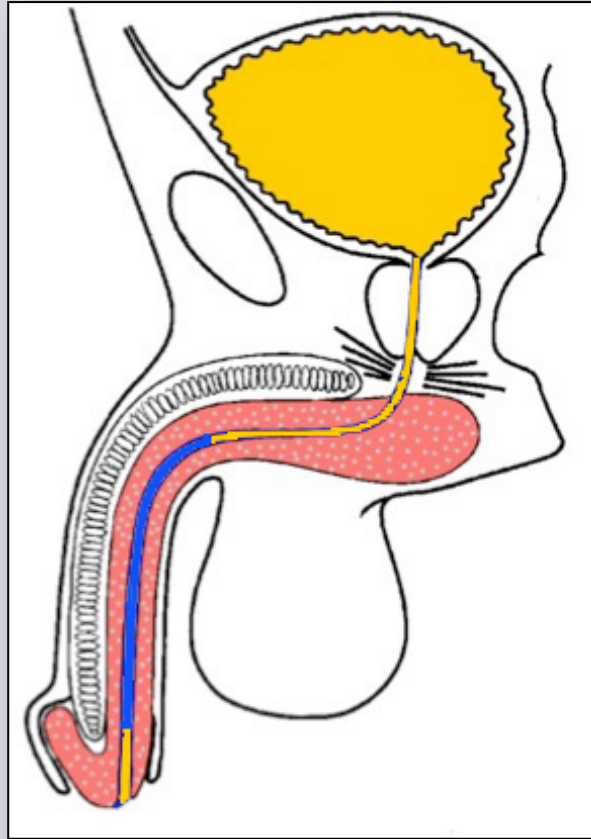


Conclusion



**It is more difficult to
repair 1 cm meatal
stenosis than 5 cm
bulbar stricture**

Penile urethra



Graft or Flap ?

Reconstruction of Penile Urethra:

Graft or Flap ?

In the last 15 years there has been a great change in the approach of penile urethral stricture repair:

- 1. The use of oral mucosal graft**
- 2. The evolution of dorsal onlay technique**
- 3. The use of minimally invasive techniques**

Reconstruction of Penile Urethra:

Graft or Flap ?

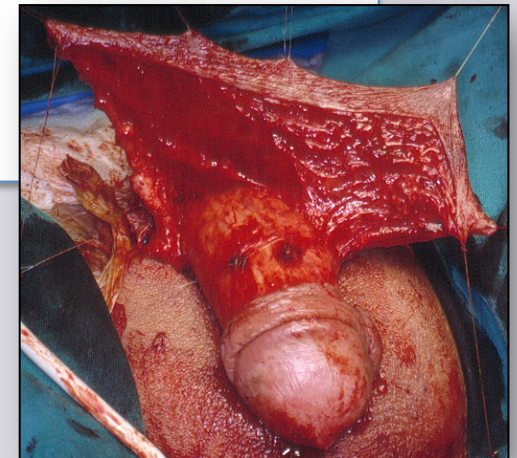
The oral mucosa used as graft is superior to the skin for many reasons:

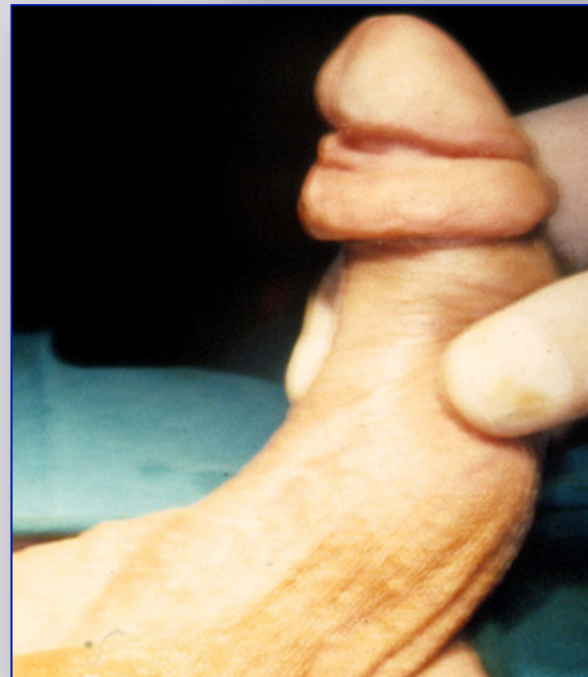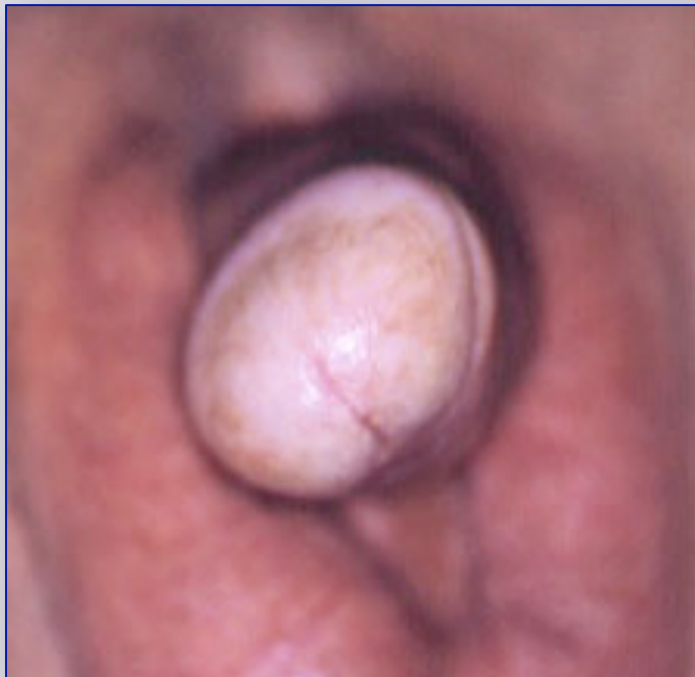
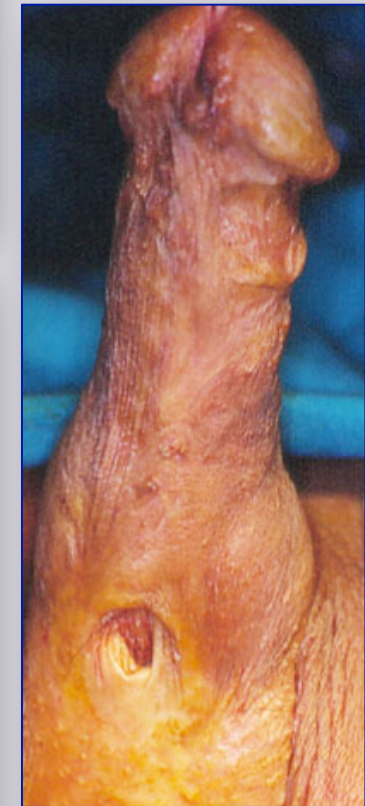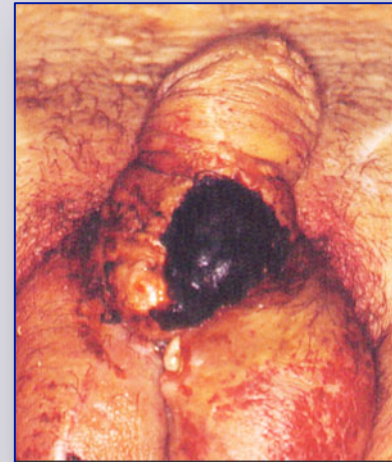
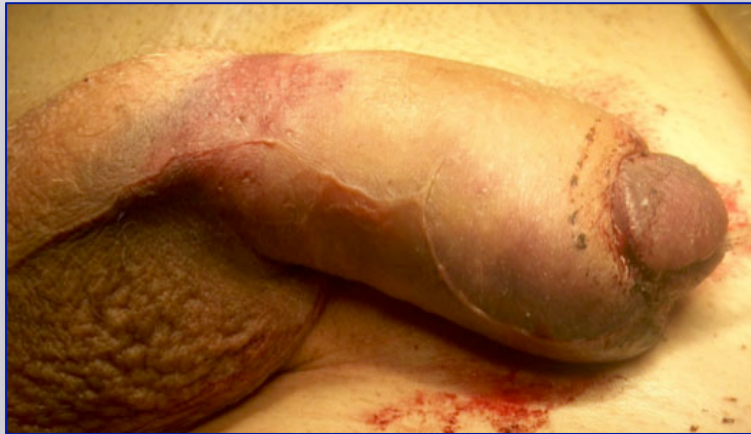- 1. The harvestin site is concealed**
- 2. It is more elastic and resistant due to its biological properties**
- 3. It is more resistant to infection**
- 4. It is more flexible material that should be used as onlay/inlay, dorsal/ventral, patch/tube.....**

Reconstruction of Penile Urethra: Graft or Flap ?

The use of preputial skin flap require the fully involvement of all penile components in the reconstruction and this may have a negative consequences on:

1. Aesthetic penile appearance
2. Erection (chordee-glans penile rotation)
3. Psicological negative impact on patient





e-mail: info@urethralcenter.it

Websites: www.uretra.it
www.urethralcenter.it

DOCTOR

**You need penile
urethroplasty.**

**Yes. I agree. But
don't touch my
penis!!!!!!**



e-mail: info@urethralcenter.it

Websites: www.uretra.it
www.urethralcenter.it

Graft penile urethroplasty with a new glue (Glubran 2)

VIDEO 1

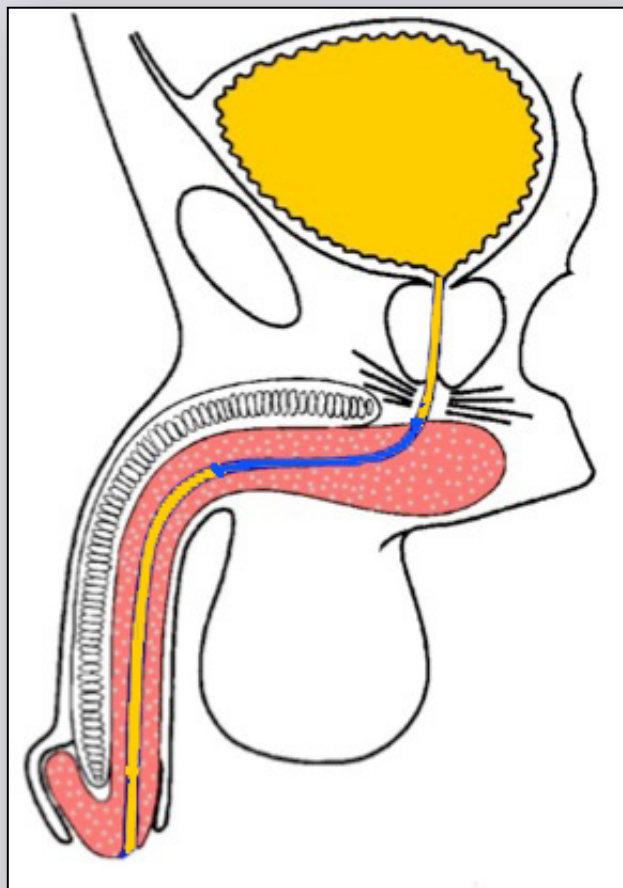
Flap penile urethroplasty with a new glue (Glubran 2)

VIDEO 2

How you choice for penile urethroplasty: Free graft or skin flap ?

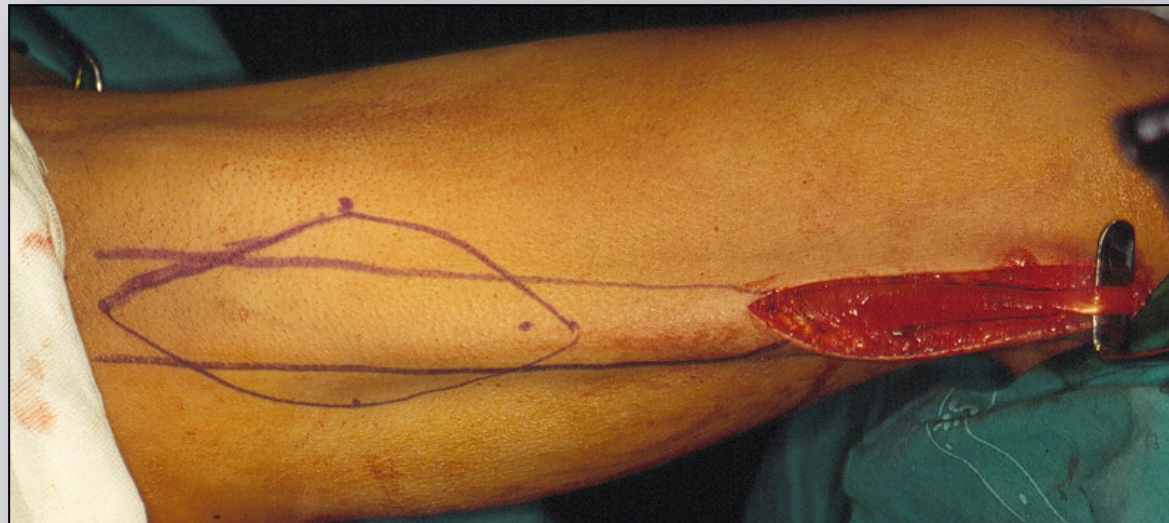
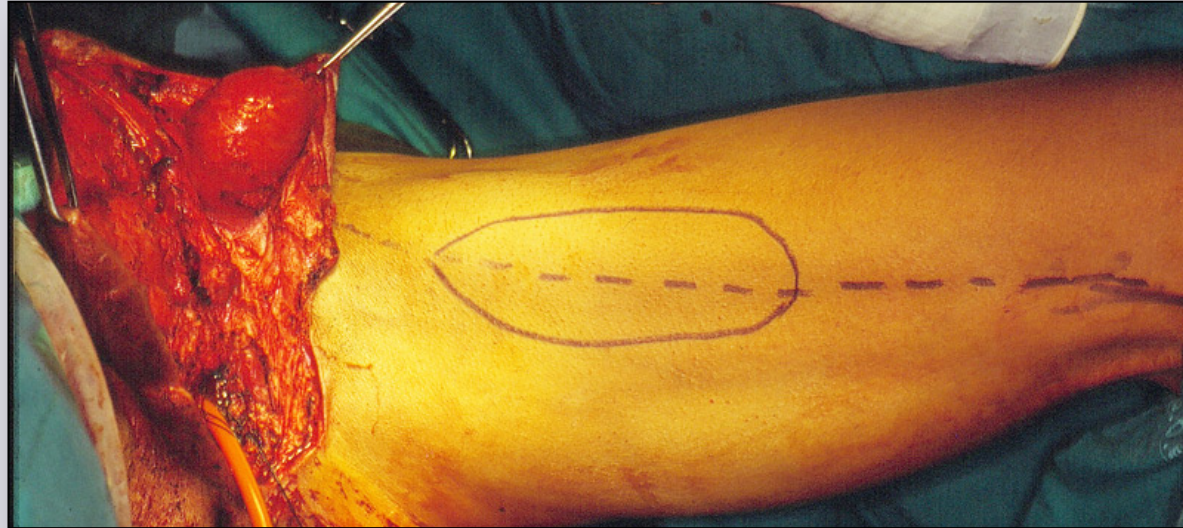
- 1. Graft reconstruction of penile urethra is easy, fast, safe, and don't cause any aesthetic change in penile apperance and represents the first choice in penile urethroplasty.**
- 2. Flap reconstruction should be use as a second choice in penile urethroplasty.**

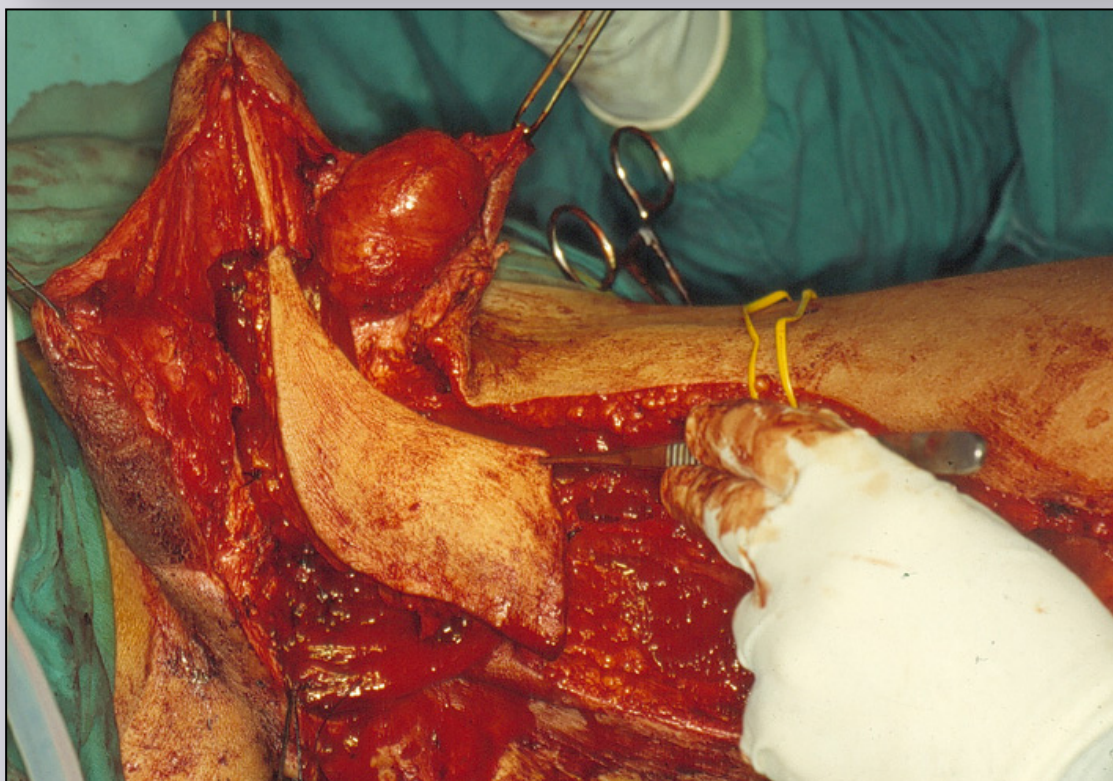
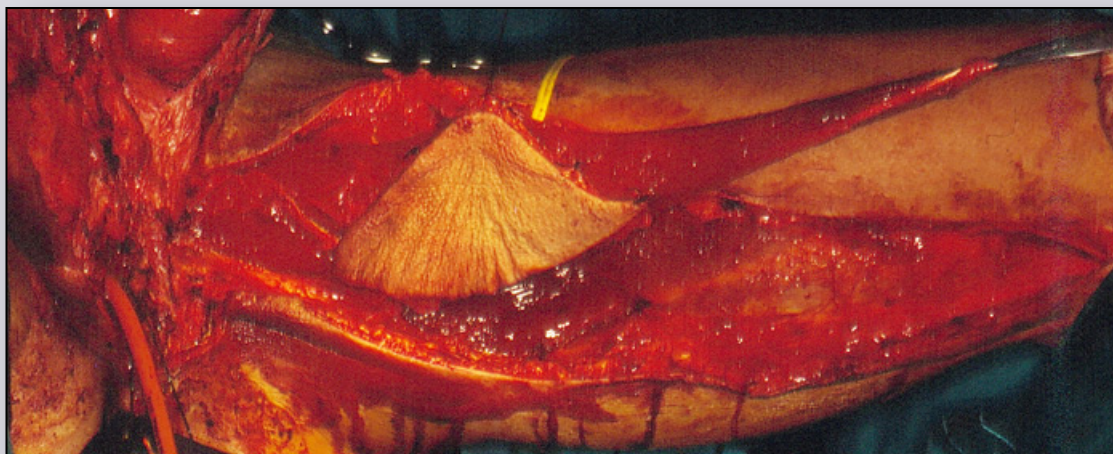
Bulbar urethra



Graft or Flap ?

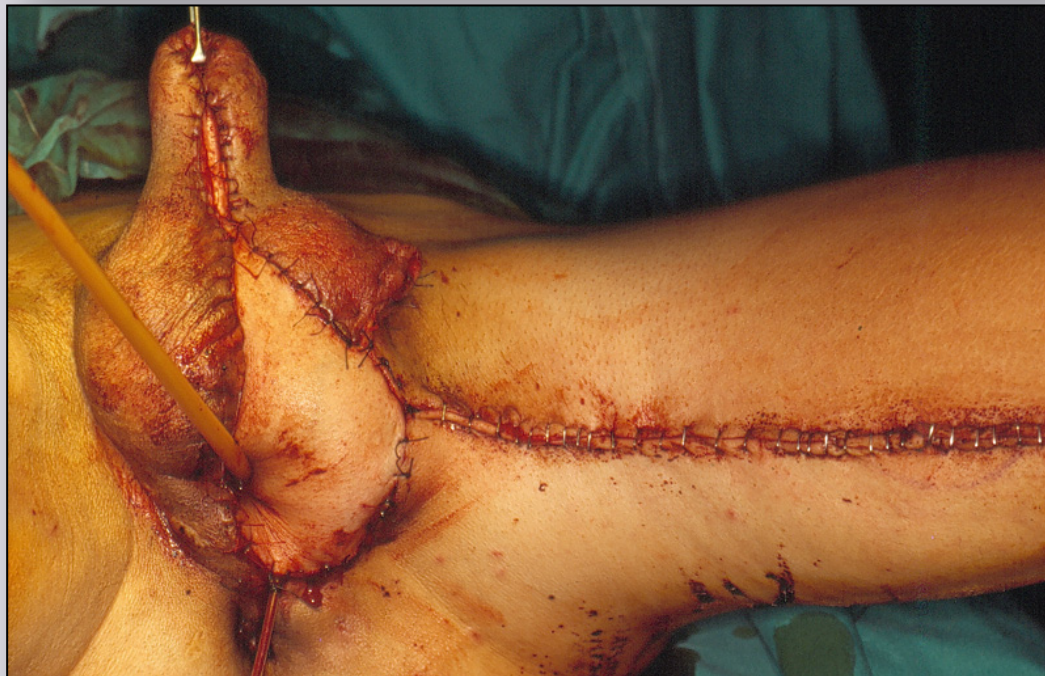
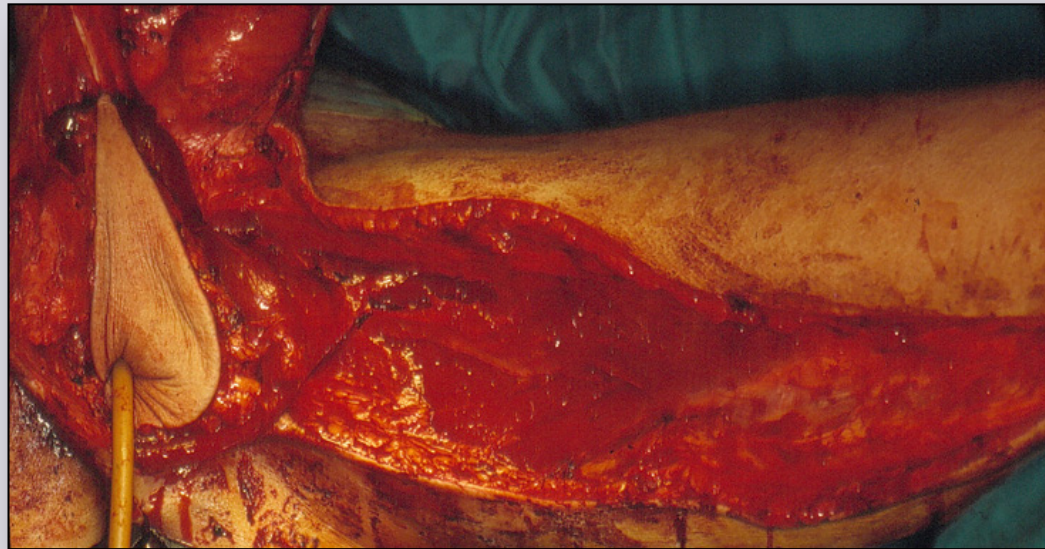
Bulbar staged flap urethroplasty





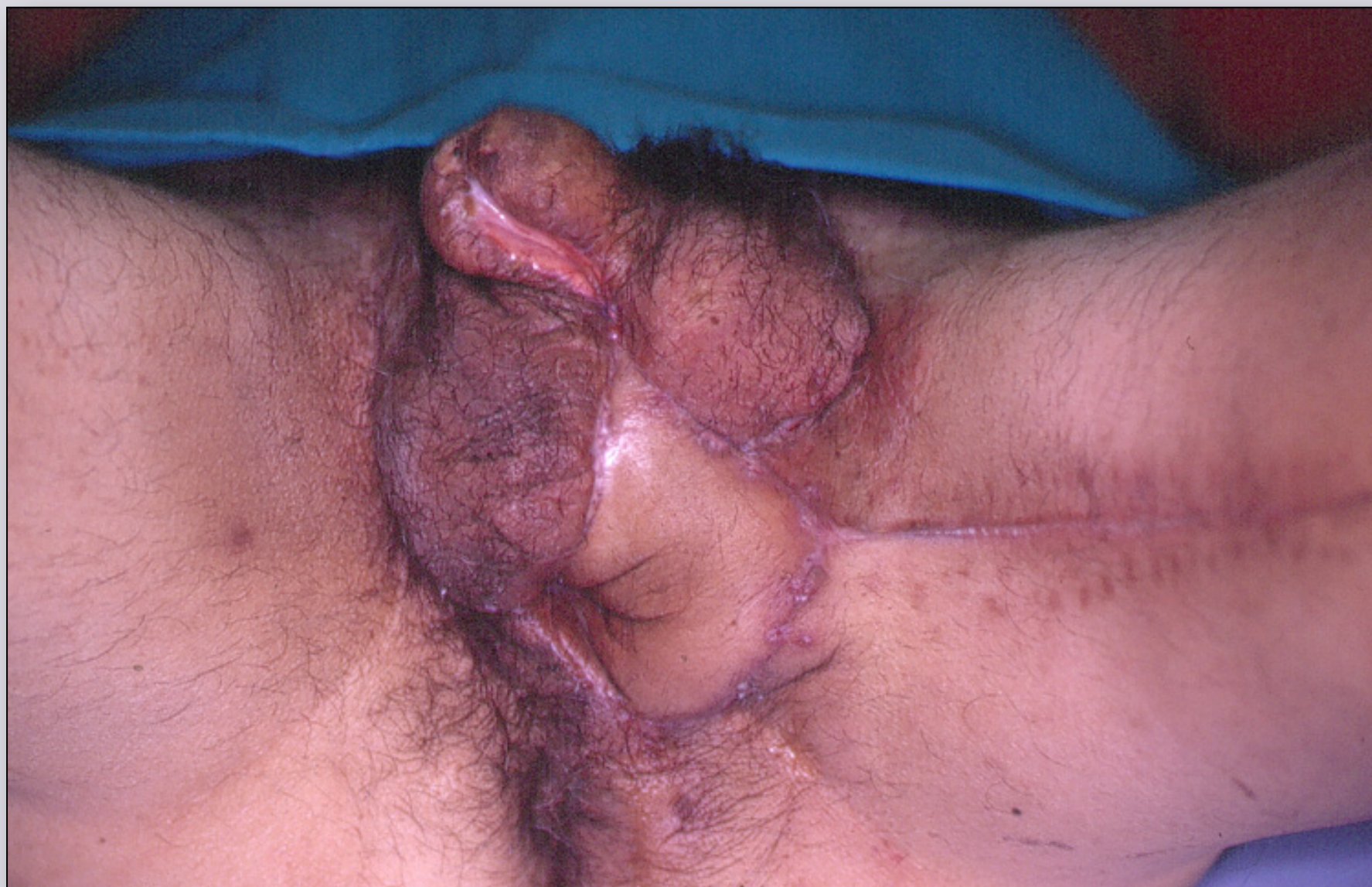e-mail: info@urethralcenter.it

Websites: www.uretra.it
www.urethralcenter.it



e-mail: info@urethralcenter.it

Websites: www.uretra.it
www.urethralcenter.it



e-mail: info@urethralcenter.it

Websites: www.uretra.it
www.urethralcenter.it

Graft bulbar urethroplasty with a new glue (Glubran 2)

VIDEO 3

How you choice for bulbar urethroplasty: Free graft or skin flap ?

- 1. Graft reconstruction of the bulbar urethra is easy, fast, safe, using different surgical techniques and represents the first choice in bulbar urethroplasty.**
- 2. Flap reconstruction should be use as a second choice in bulbar urethroplasty only for few selecetd cases.**



Register now !

www.webon.uretra.it

e-mail: info@urethralcenter.it

Websites: www.uretra.it
www.urethralcenter.it