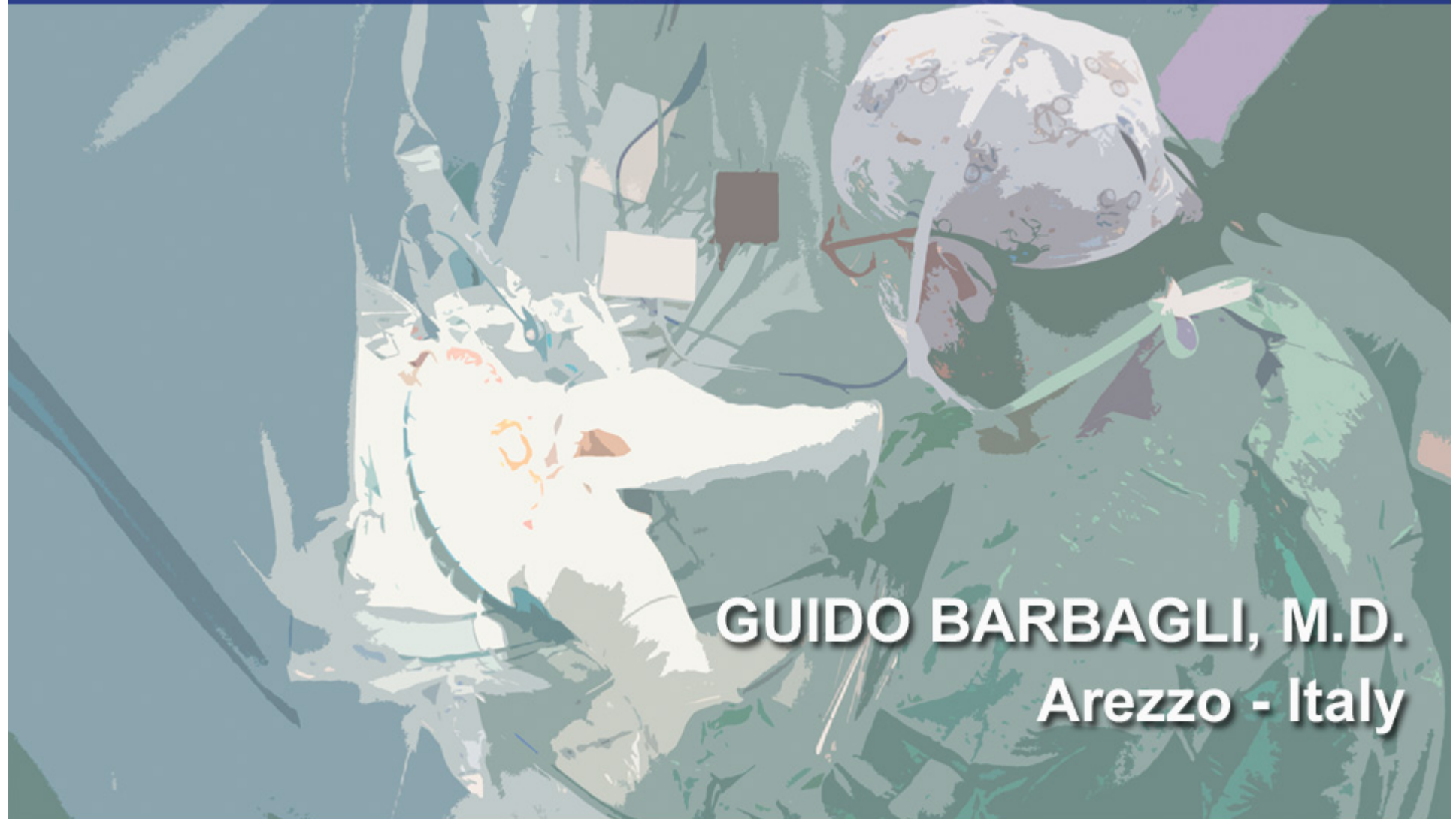

CENTER FOR RECONSTRUCTIVE URETHRAL SURGERY



GUIDO BARBAGLI, M.D.
Arezzo - Italy

e-mail: info@urethralcenter.it

Websites: www.uretra.it
www.urethralcenter.it




Centro Chirurgico Toscano **Arezzo – Italy**

www.centrochirurgicotoscano.it

e-mail: info@urethralcenter.it

Websites: www.uretra.it
www.urethralcenter.it

*ADVANCED EDUCATIONAL COURSE ON:
Urethral Strictures and Reconstruction*



Moscow – Russia
June 18 – 19, 2015

e-mail: info@urethralcenter.it

Websites: www.uretra.it
www.urethralcenter.it

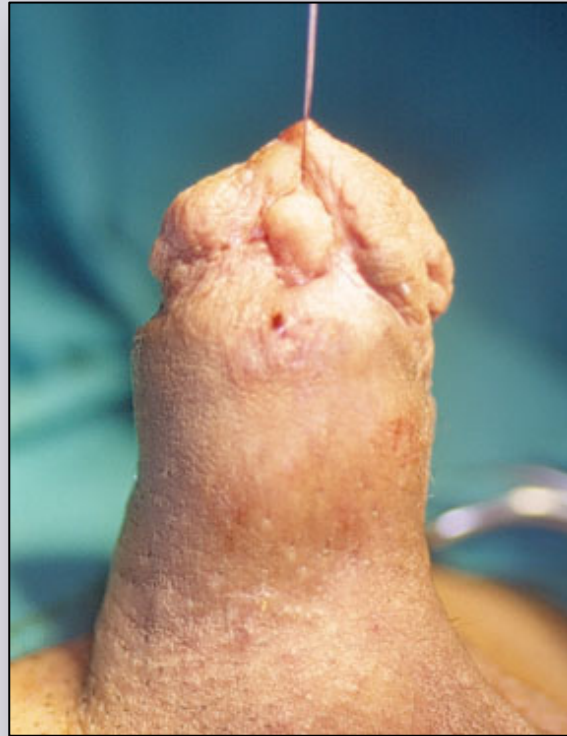Reconstruction of penile urethra



e-mail: info@urethralcenter.it

Websites: www.uretra.it
www.urethralcenter.it

Meatal stenosis



Meatotomy

or

Meatoplasty ?



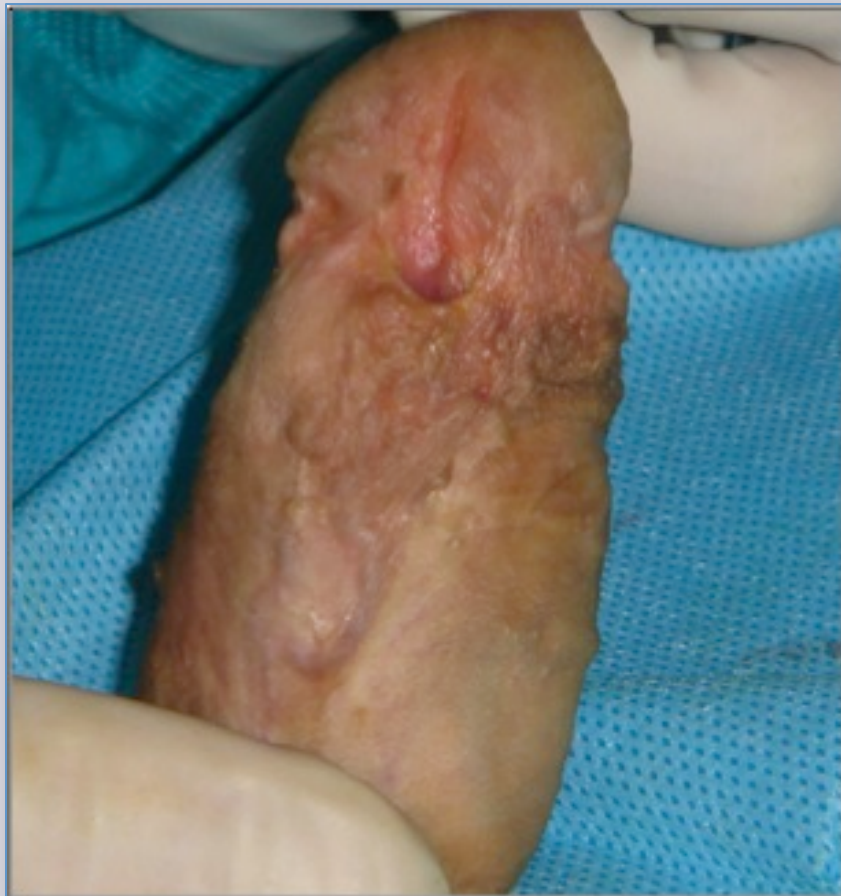Distal urethroplasty for isolated fossa navicularis and meatal strictures

Joshua J. Meeks, Guido Barbagli*, Nitin Mehdiratta, Michael A. Granieri and Chris M. Gonzalez

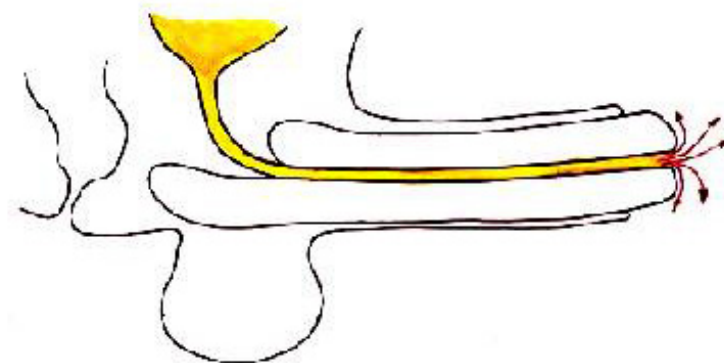
*Department of Urology, Northwestern University, Feinberg School of Medicine, Chicago, IL, USA, and *Center for Reconstructive Urethral Surgery, Arezzo, Italy*

BJU Int 2011; 109: 616-619.

Complications after meatotomy



84% satisfied or very satisfied



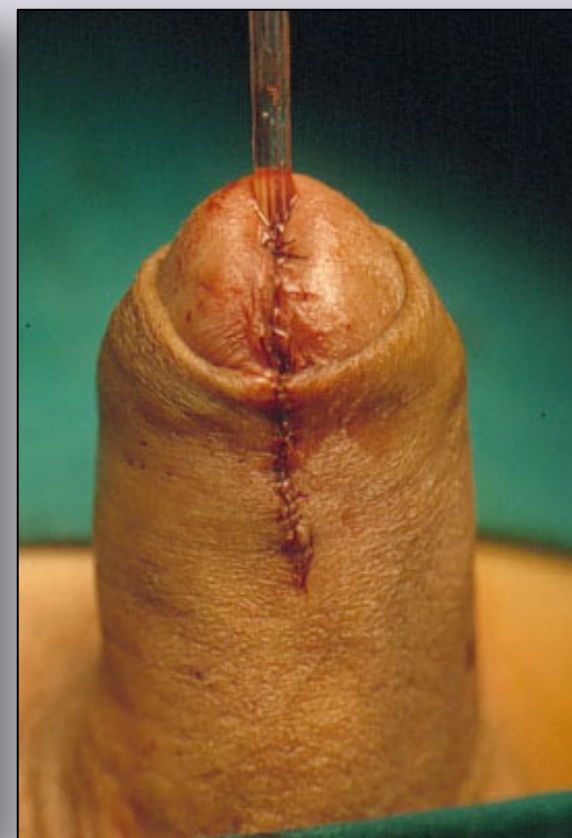
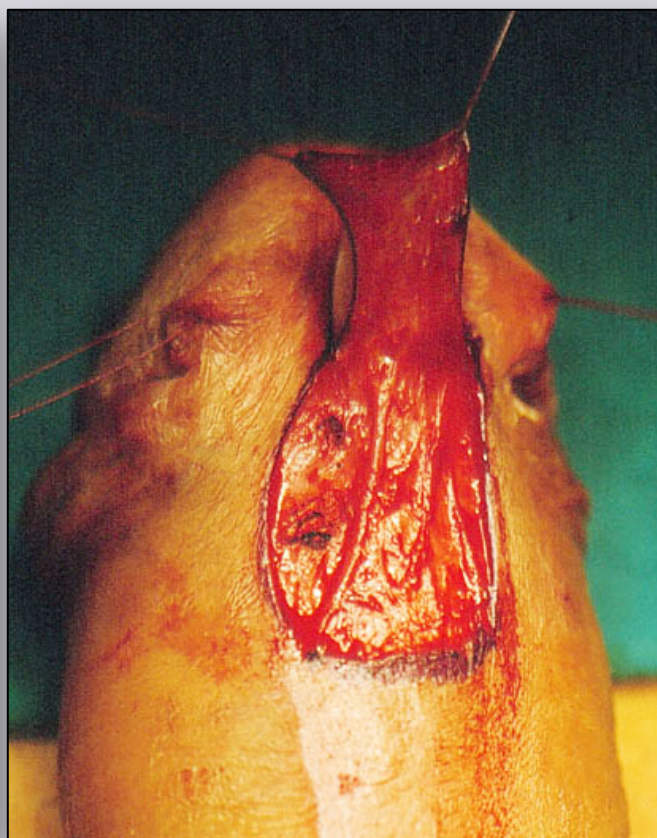
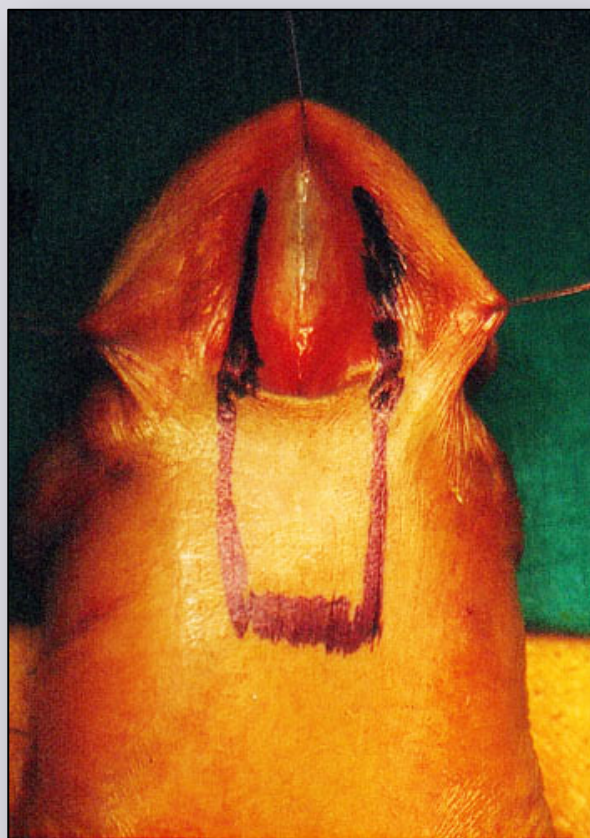
Fluttering stream (58.4%)

Irregular stream (33.3%)

Deviation of stream (8.3%)

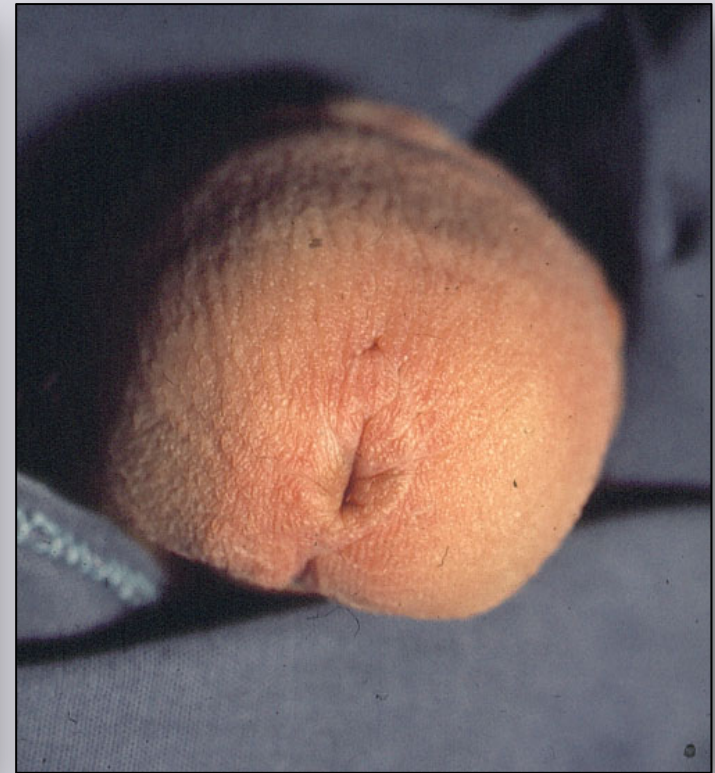
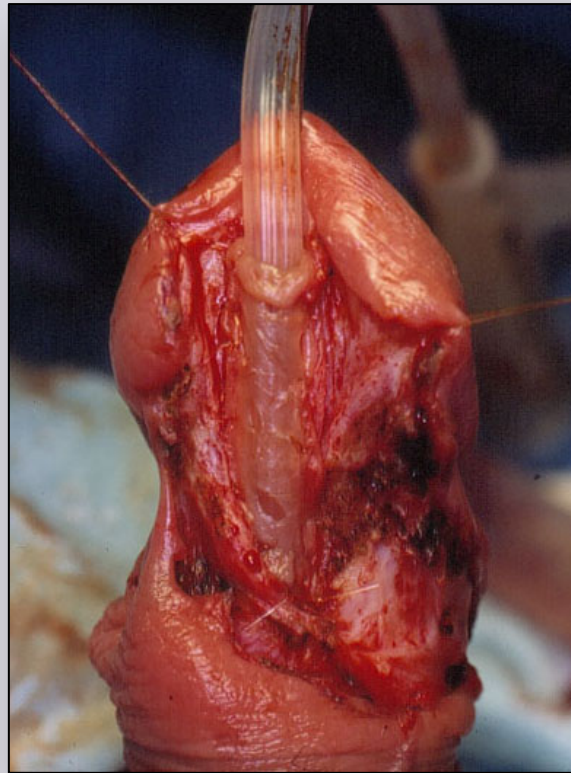
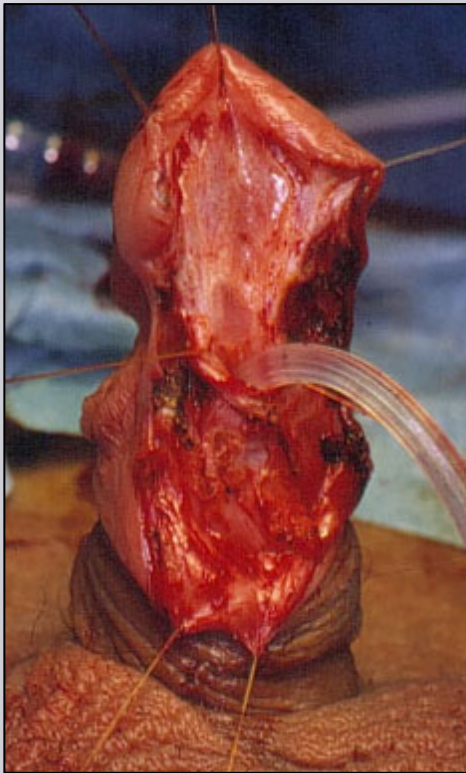
BJU Int 2012; 109: 616-619

Blandy-Tresidder meatoplasty

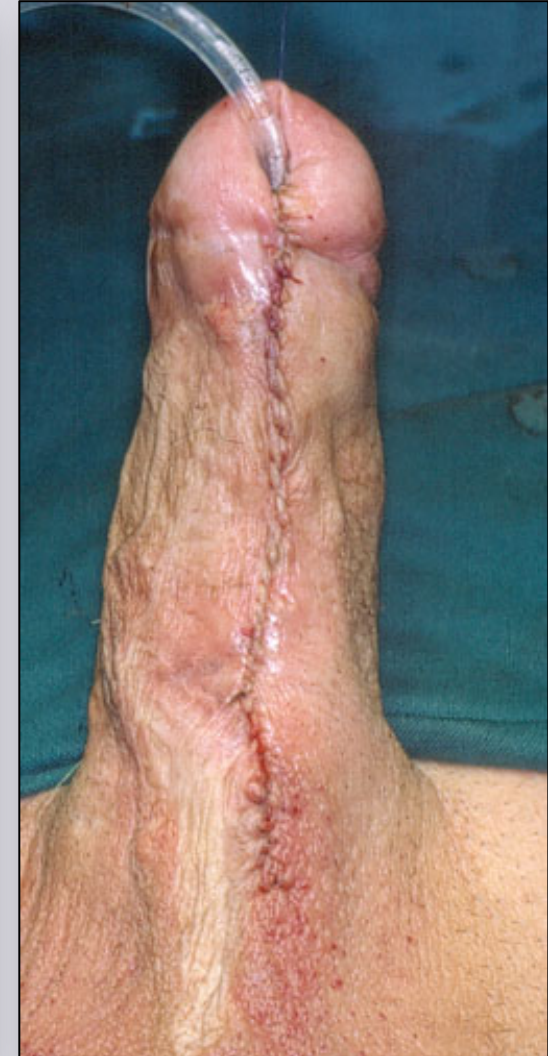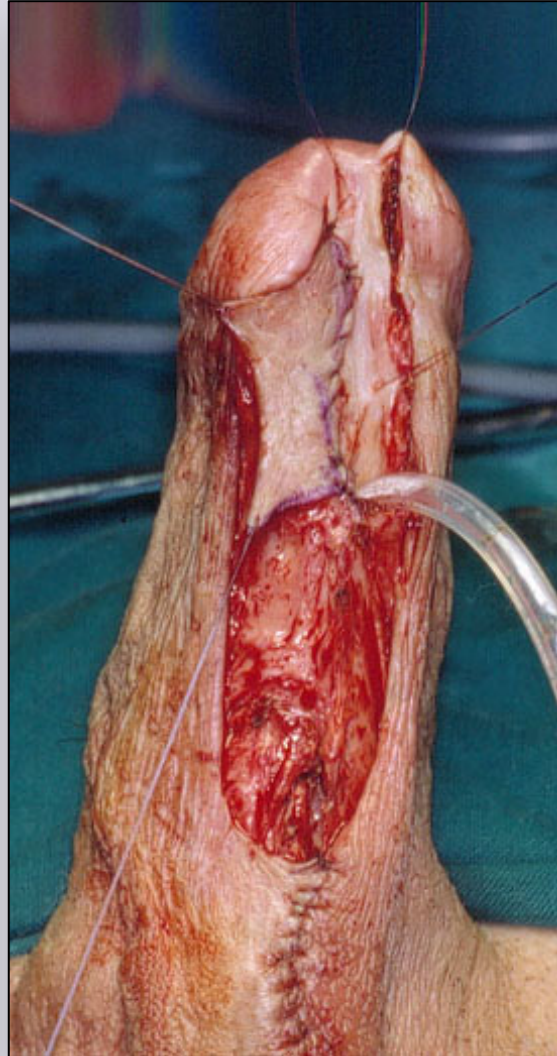
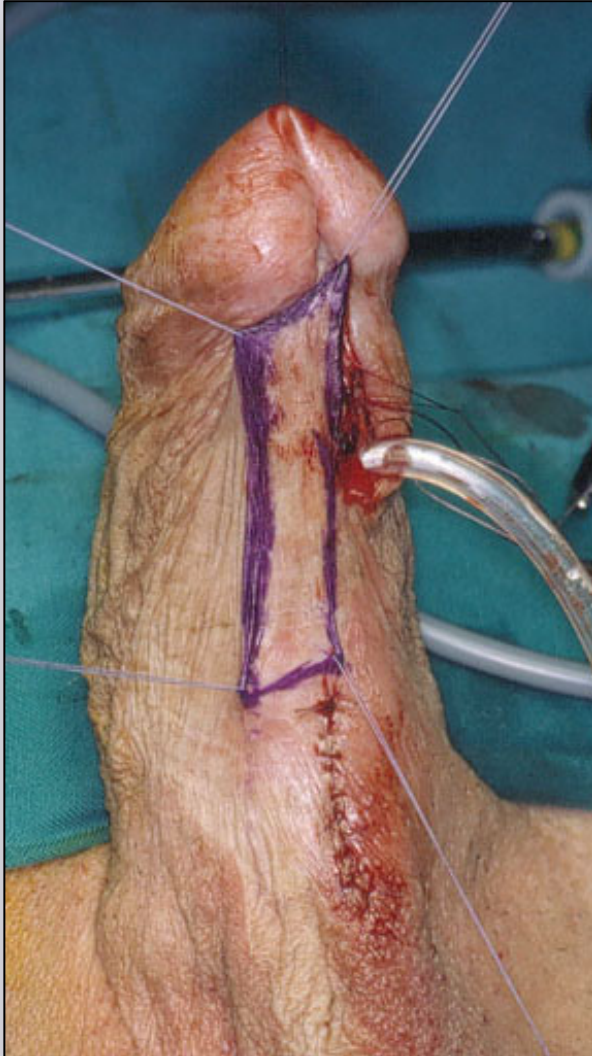


Br J Urol 1967; 39:633-234

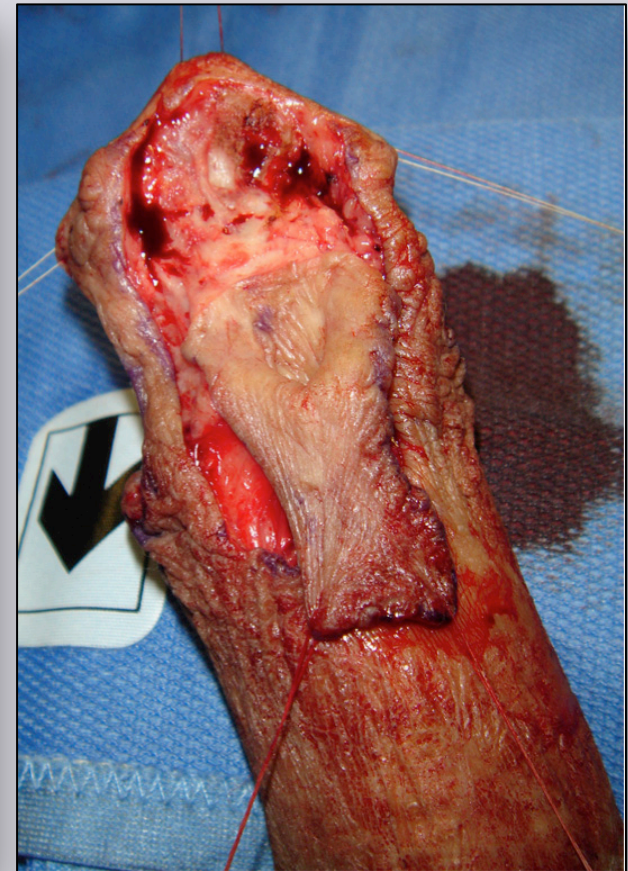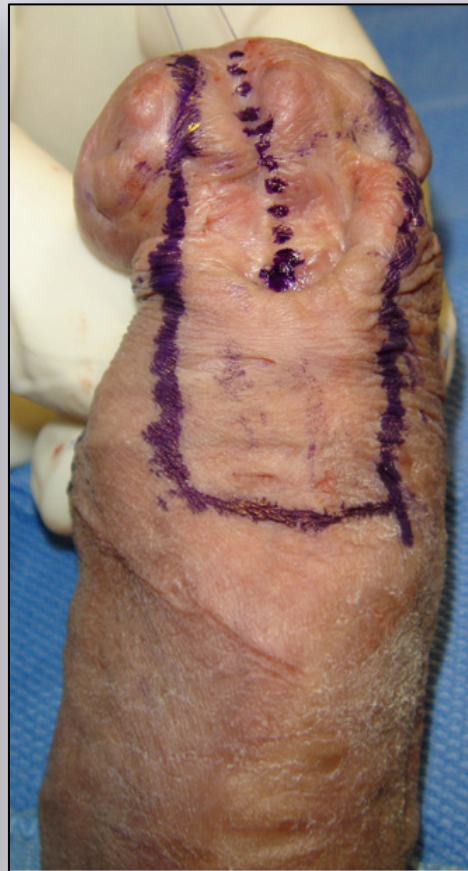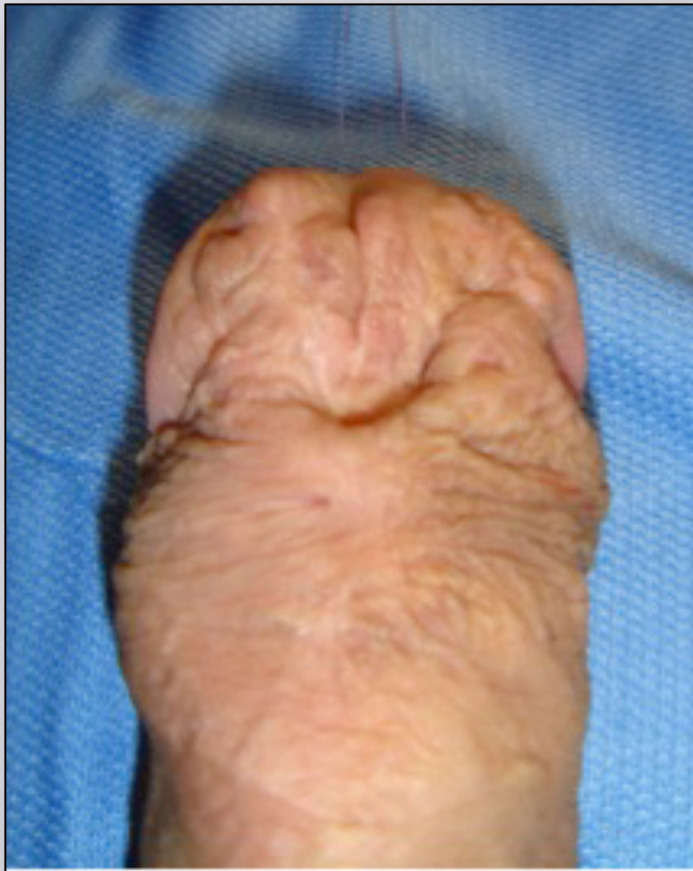Skin graft meatoplasty



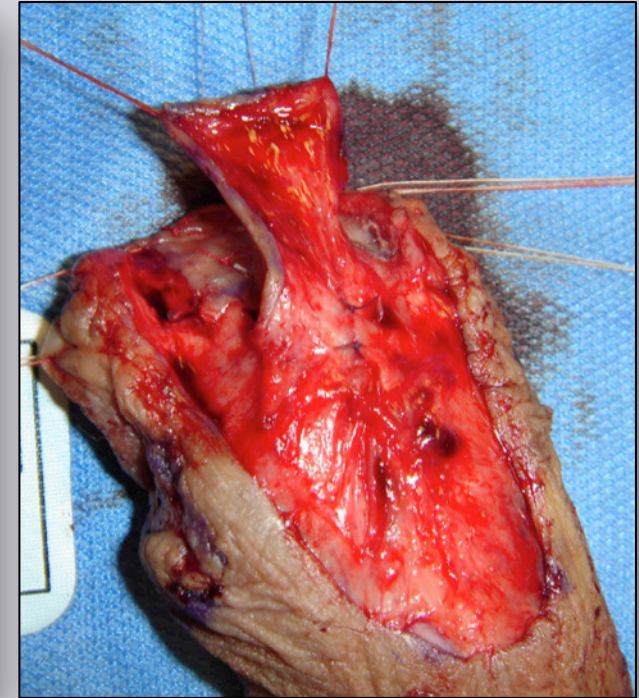
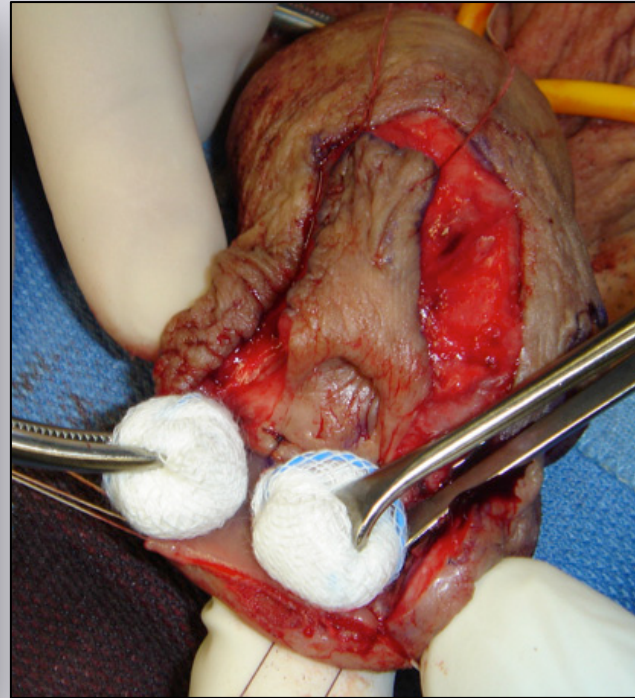
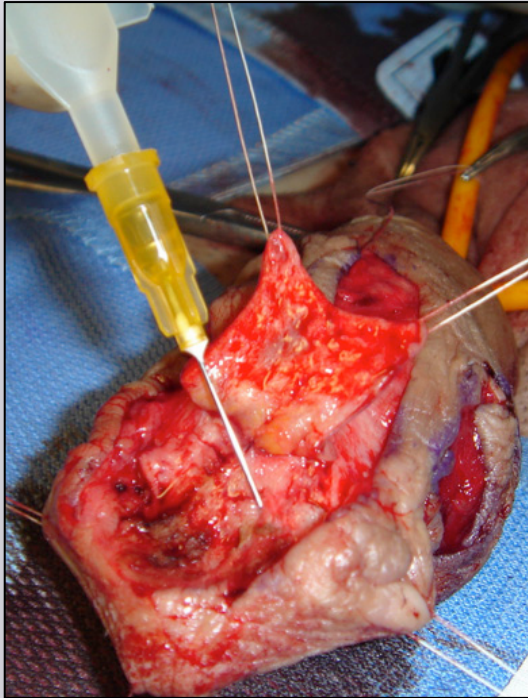
Skin flap meatoplasty



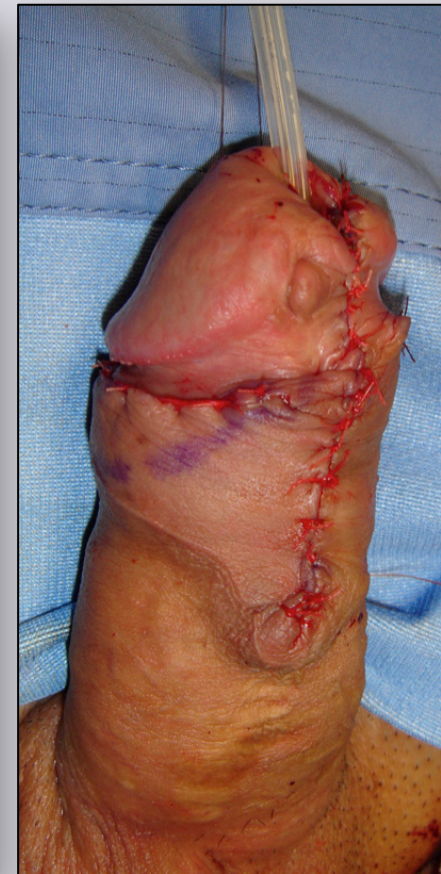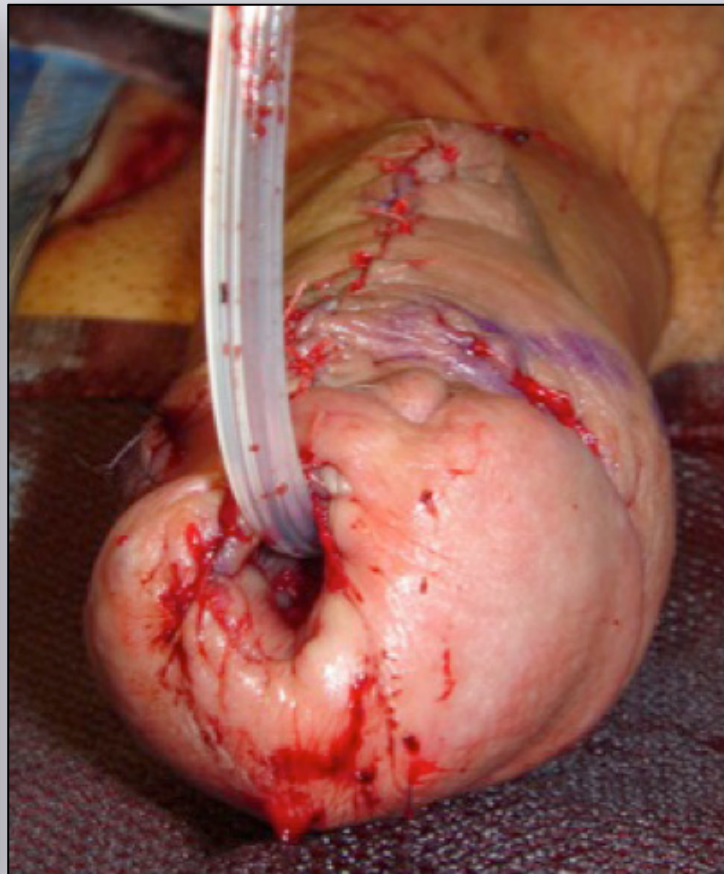
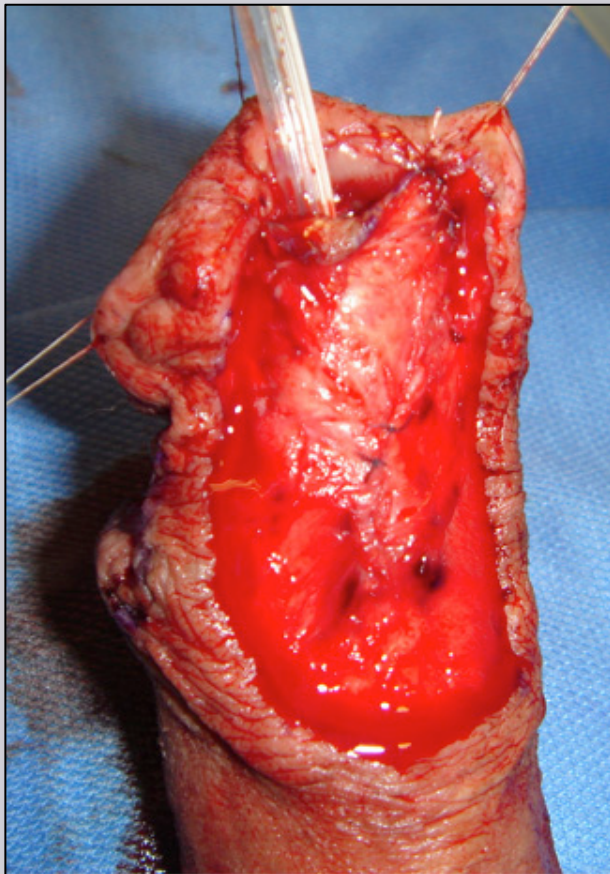
Combined flap and graft urethroplasty with new glue (Glubran 2)



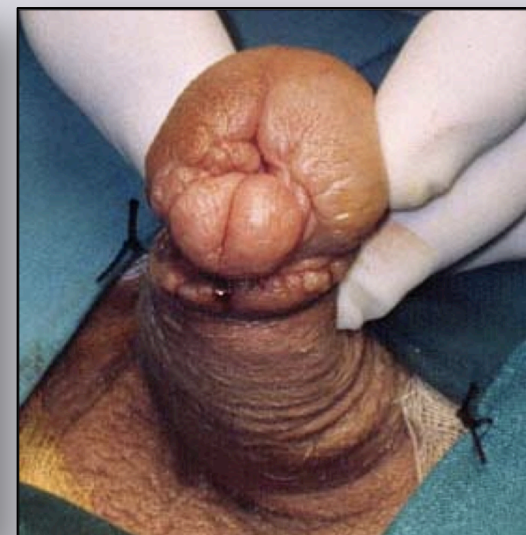
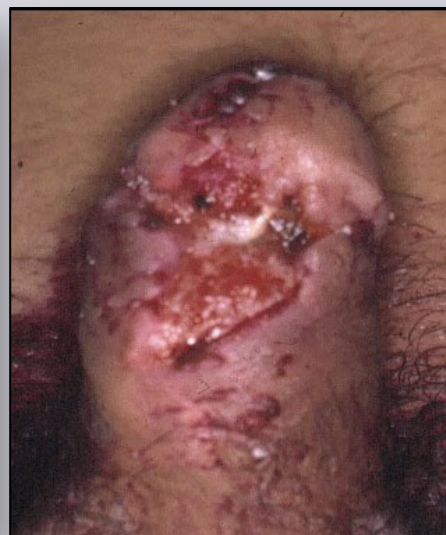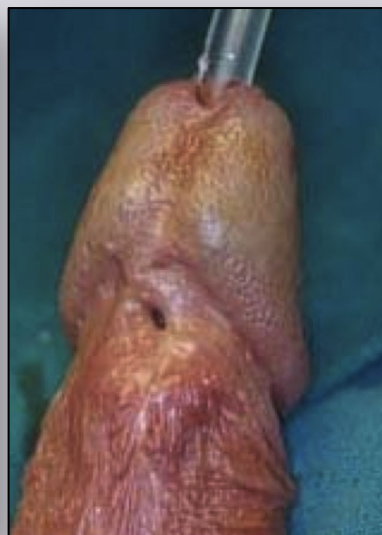
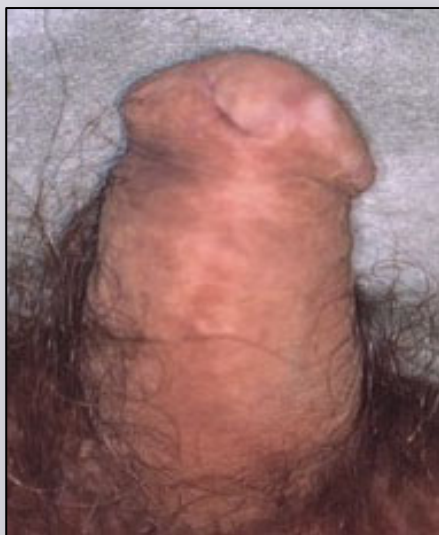Combined flap and graft urethroplasty with new glue (Glubran 2)



Combined flap and graft urethroplasty with new glue (Glubran 2)



Complications of meatoplasty



**Our results in 46 patients updated to
December 2013**

38 meatotomy: 84.2%
(mean followup 73 months)

8 meatoplasty 75%
(mean followup 101 monts)

WWW.URETRA.IT

WWW.URETHRALCENTER.IT

e-mail: info@urethralcenter.it

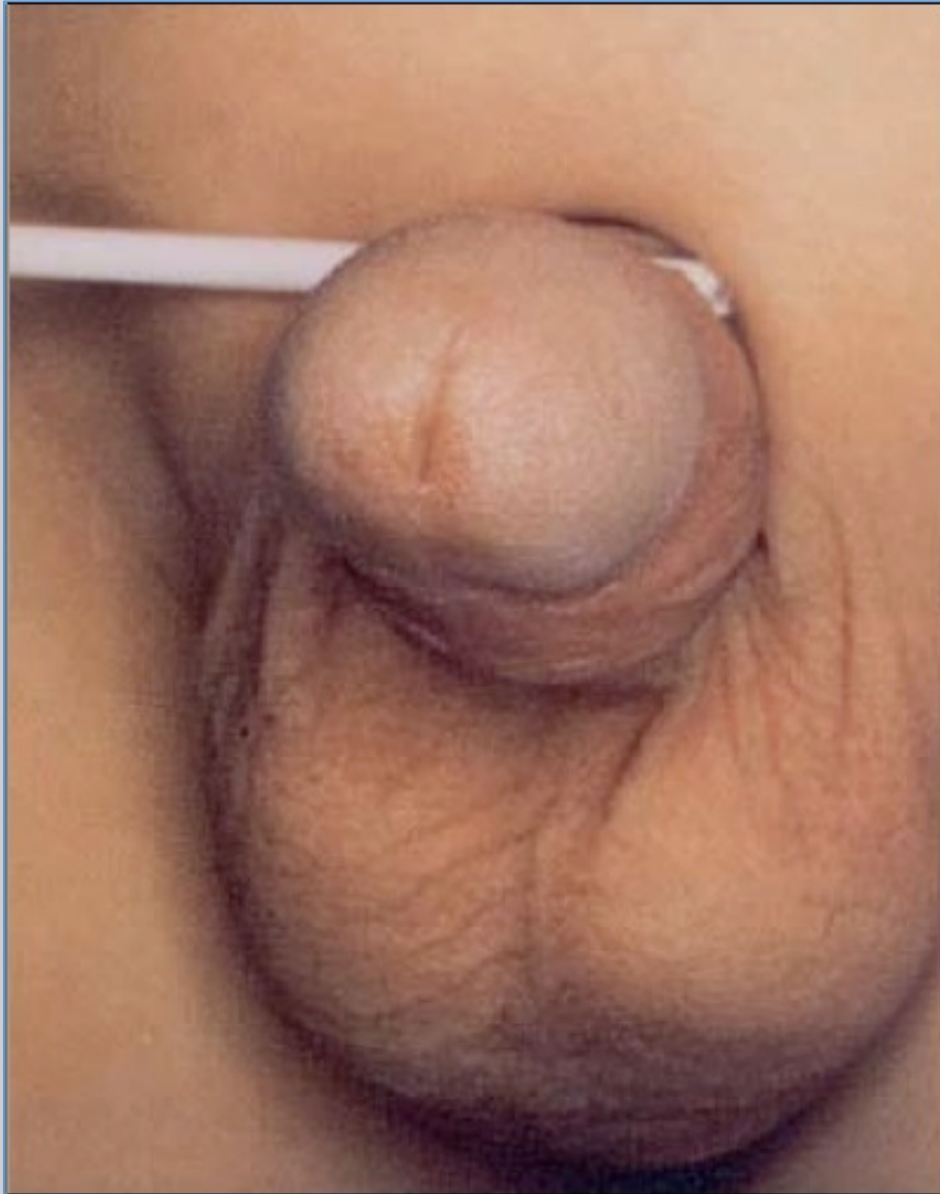Websites: www.uretra.it
www.urethralcenter.it

Patients selected for meatotomy

- **Old patient**
- **Patient with important co-morbidity**
- **Patient psychologically stable**
- **Patient who underwent numerous previous failed surgical attempts**
- **Patient with a small glans**

Patients selected for meatoplasty

- Young patient
- Patient requiring an aesthetic outcome
- Patient with big glans

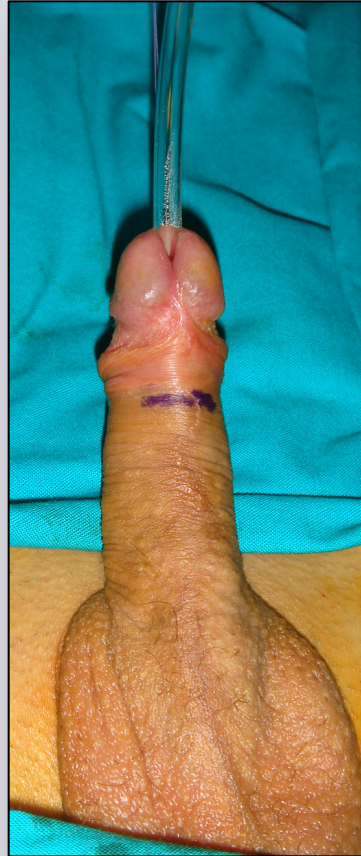

Conclusion



**It is more difficult to
repair 1 cm meatal
stenosis than 5 cm
bulbar stricture**

Penile urethral stricture



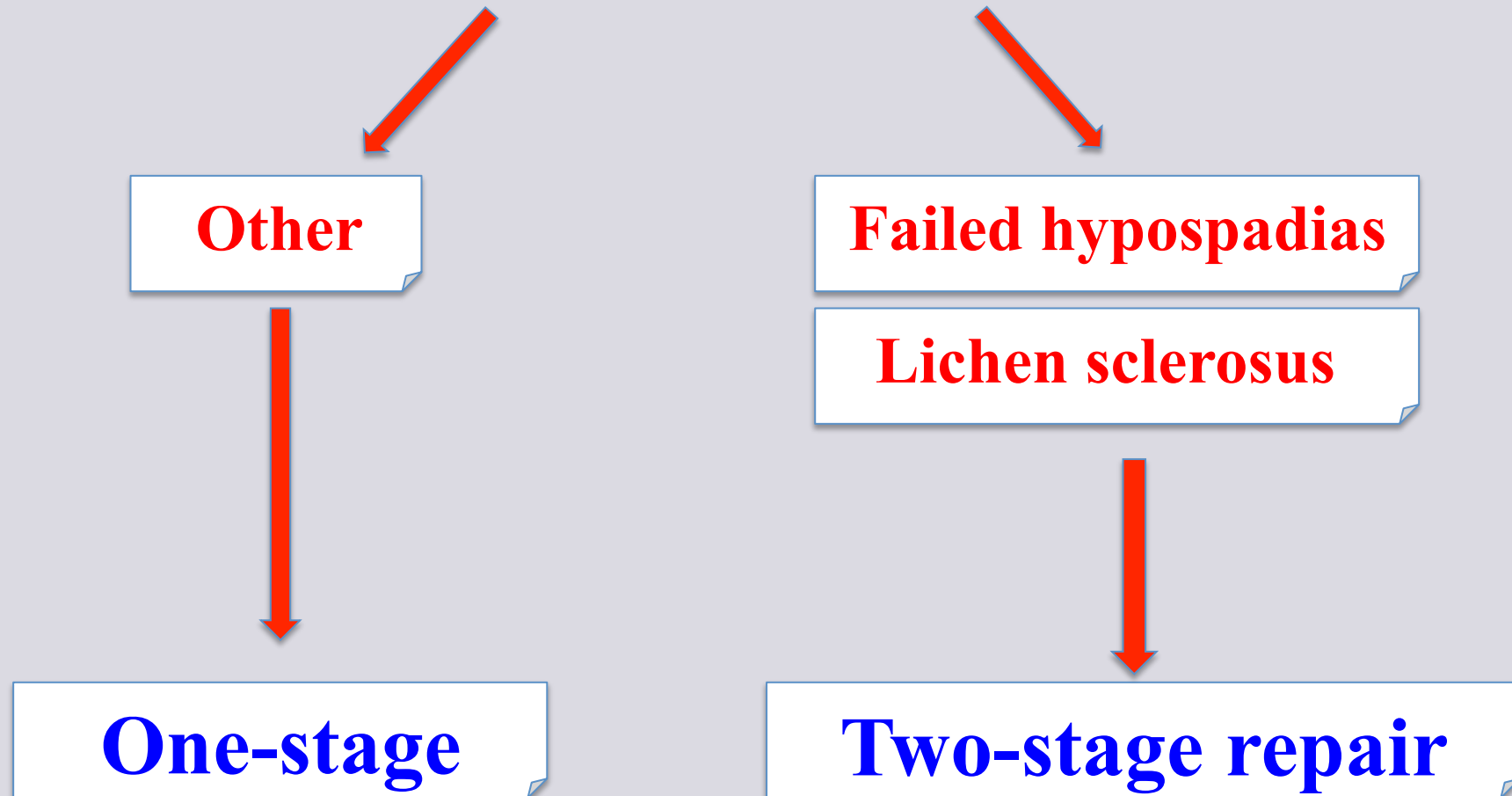
One-stage

or

Two-stage repair ?

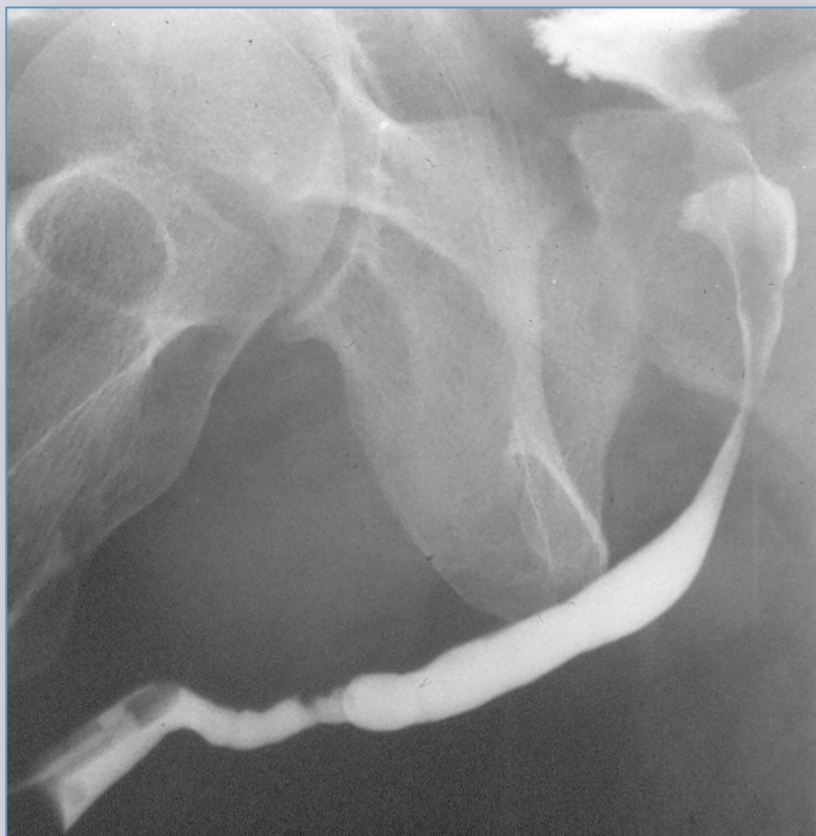Penile urethral stricture

Etiology

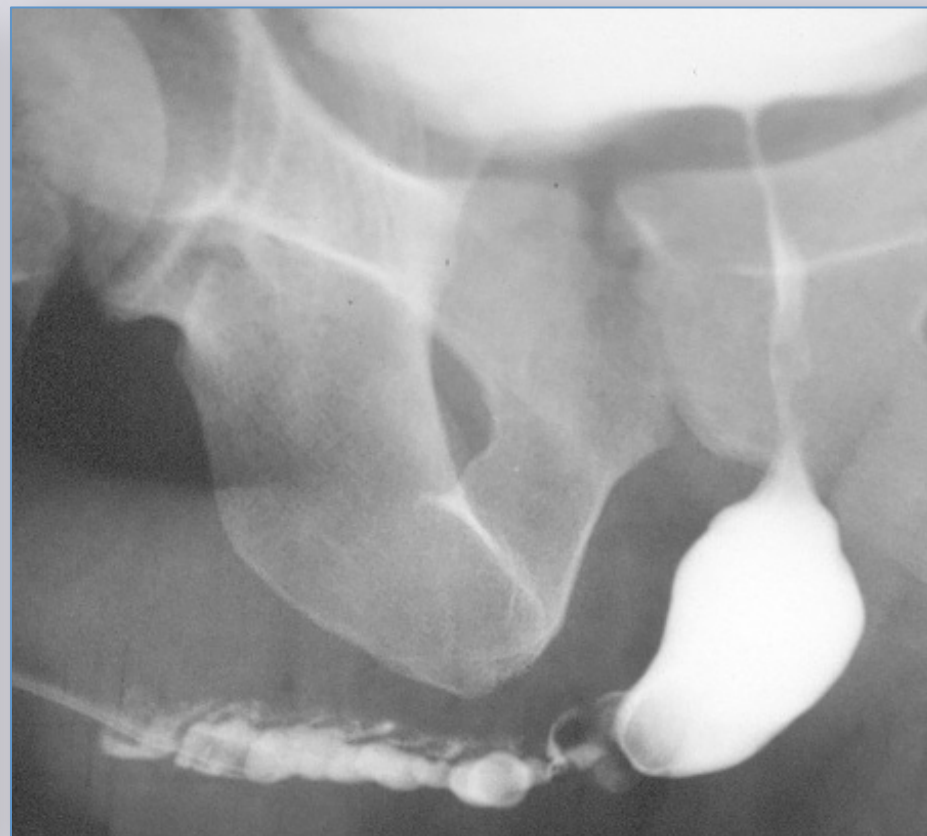

Penile urethral stricture

Radiological features



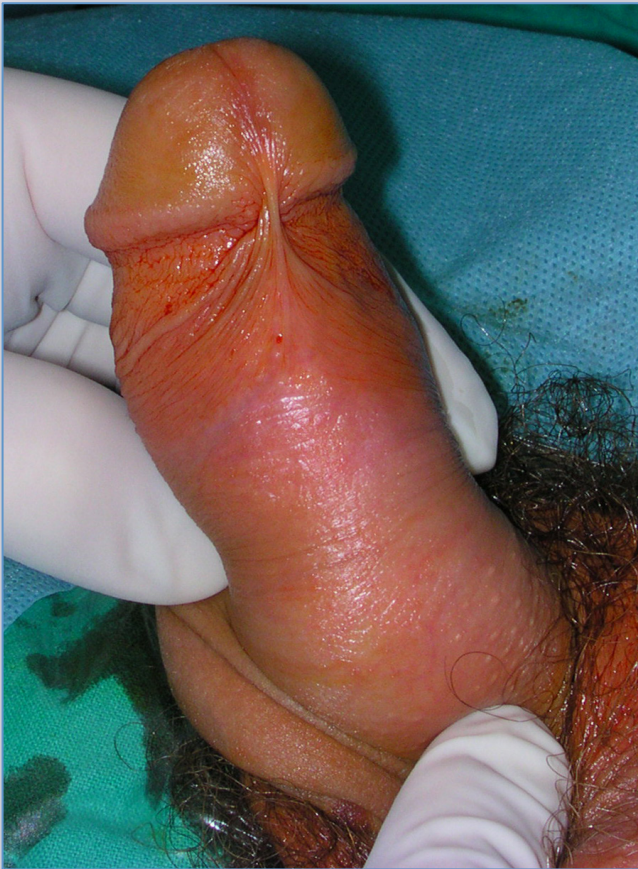One-stage



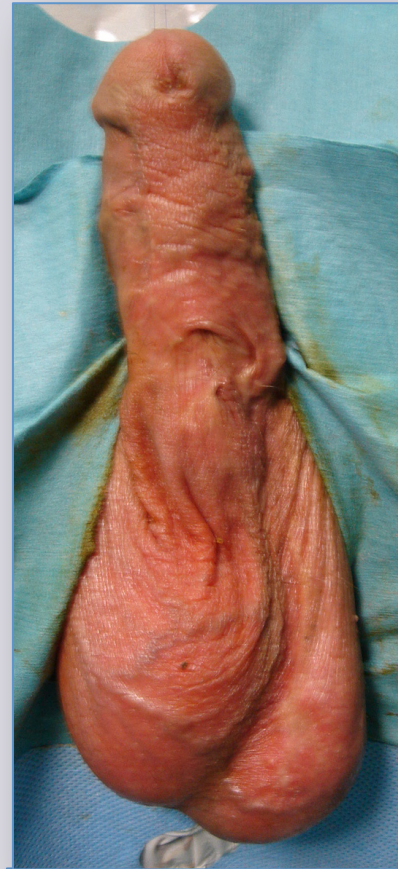
Two-stage

Penile urethral stricture

Clinical features



One-stage



Two-stage

Ideal patients for one-stage repair

- **Young patient**
- **Stricture not involving the meatus**
- **No obliterative stricture**
- **Patient with big glans**
- **Selected patients with Lichen sclerosis stricture or failed hypospadias repair**
- **When the risk of post-operative complications or failure is < 20% according to our experience**

One-stage penile urethroplasty

VIDEO

PENILE ASOPA

One-stage penile urethroplasty

VIDEO

PENILE ORANDI

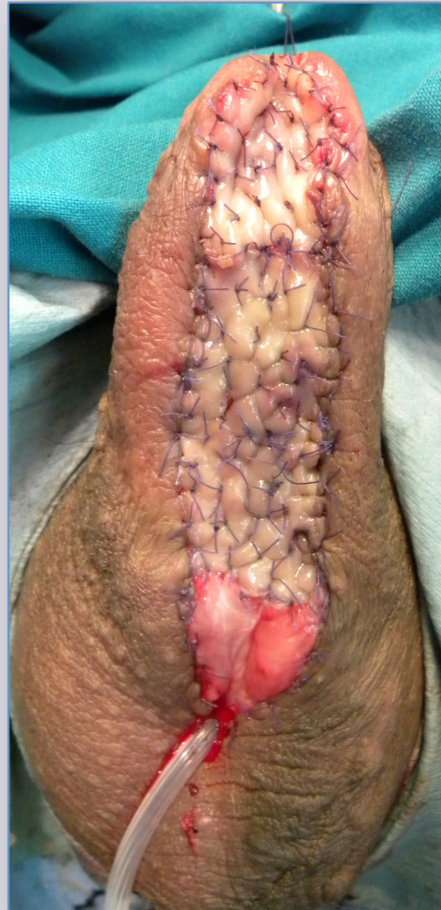Two-stage penile urethroplasty

When use the oral mucosa at the first stage ?

No



**Failed hypospadias
Other etiology**



Yes



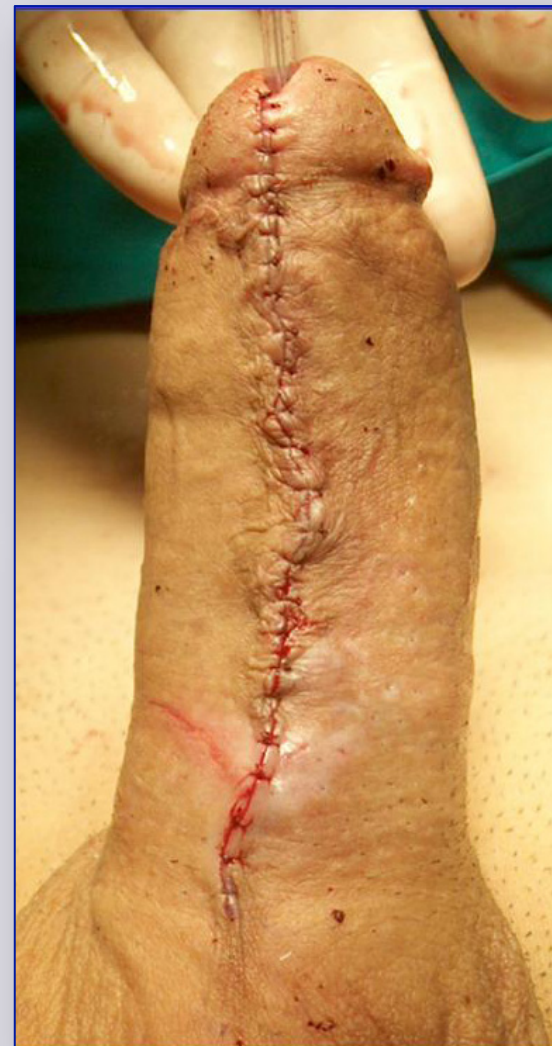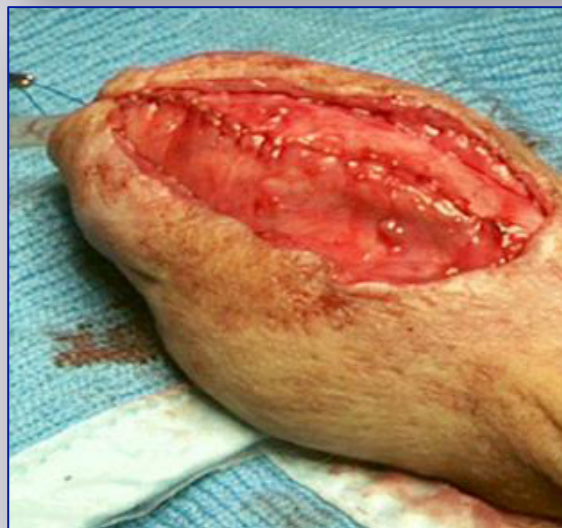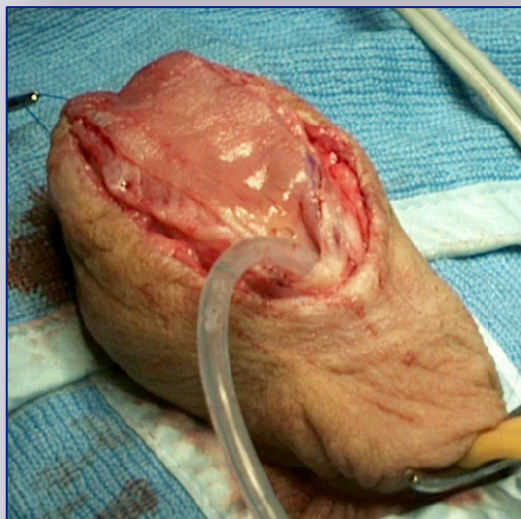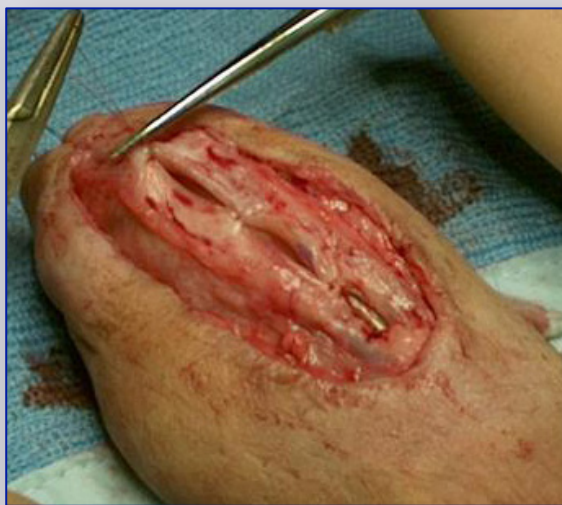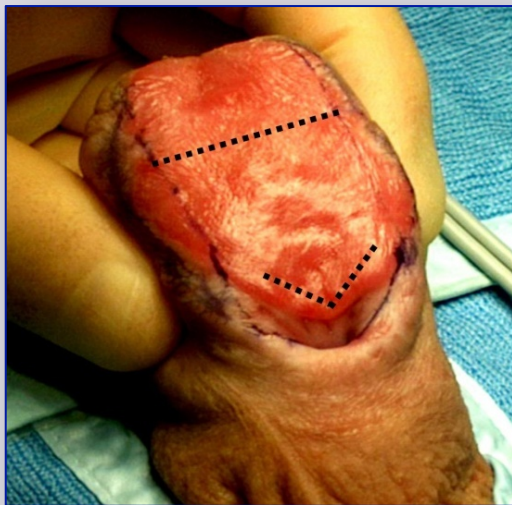Lichen sclerosus

One-stage penile urethroplasty

VIDEO

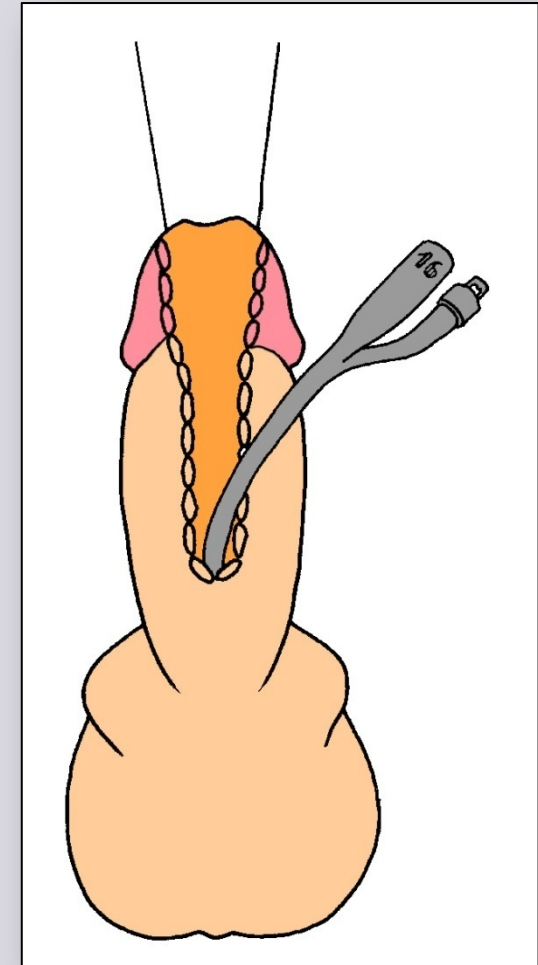
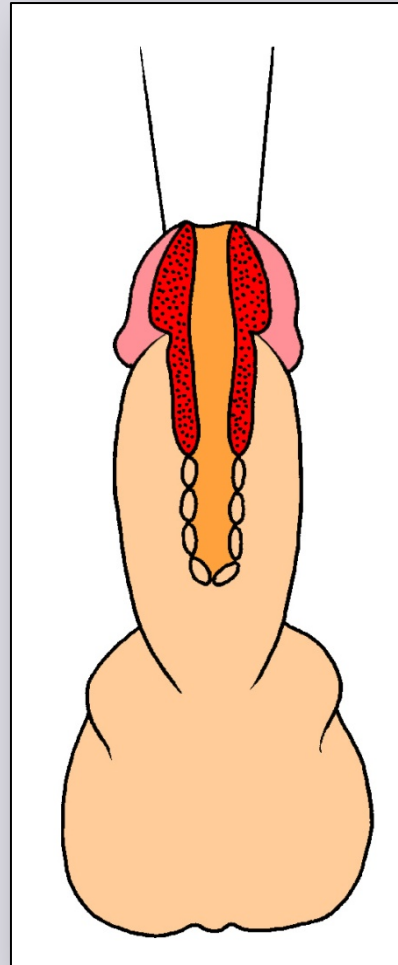
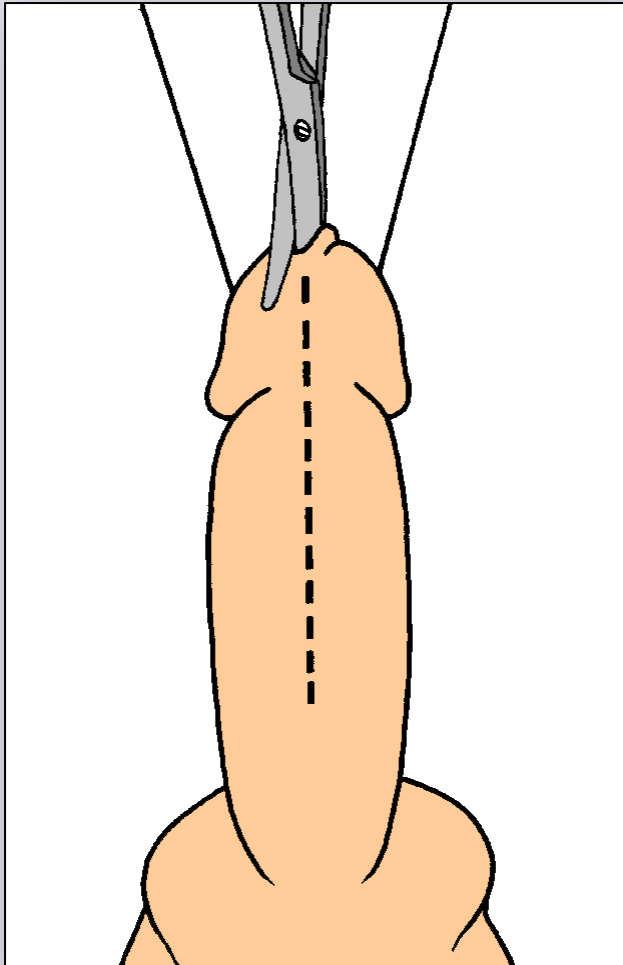
FIRST-STAGE PENILE ORAL MUCOSA

Second stage

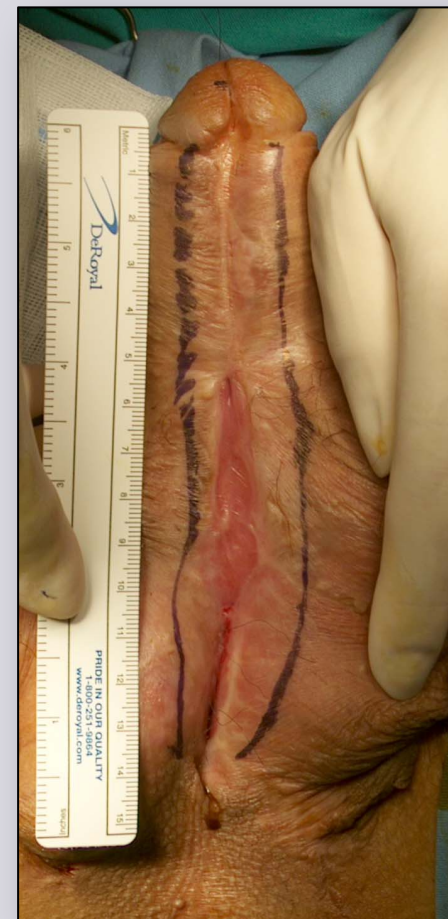
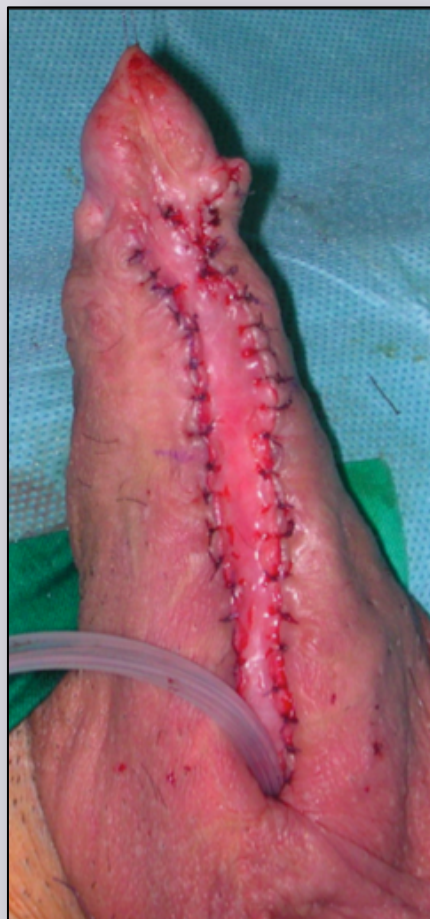
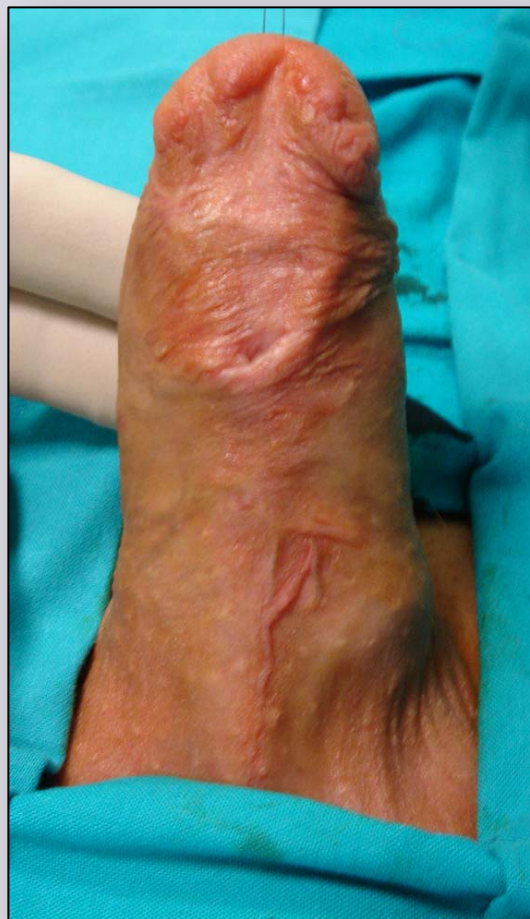**How to do two-stage penile
urethroplasty using oral mucosa
only at the second stage**

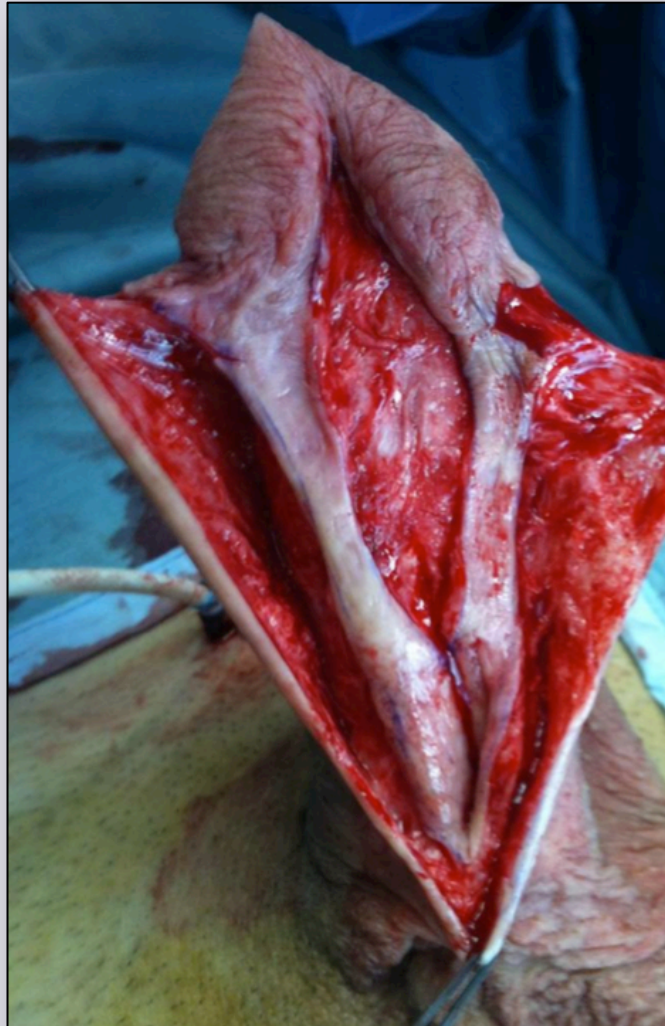First stage – Johanson's urethroplasty

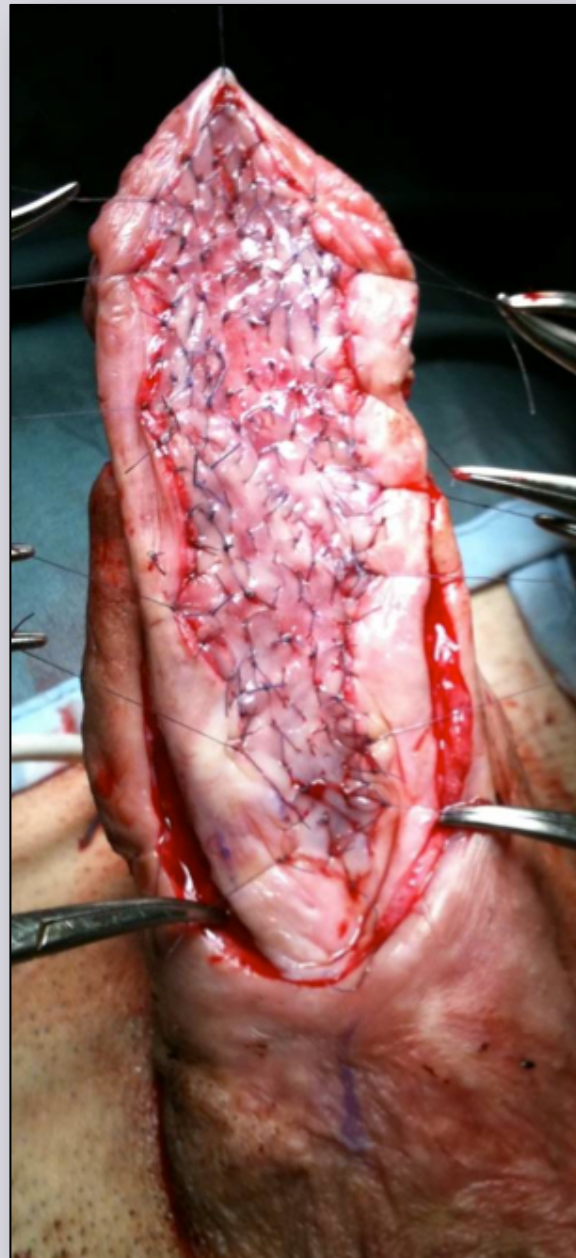

First stage – Johanson's urethroplasty



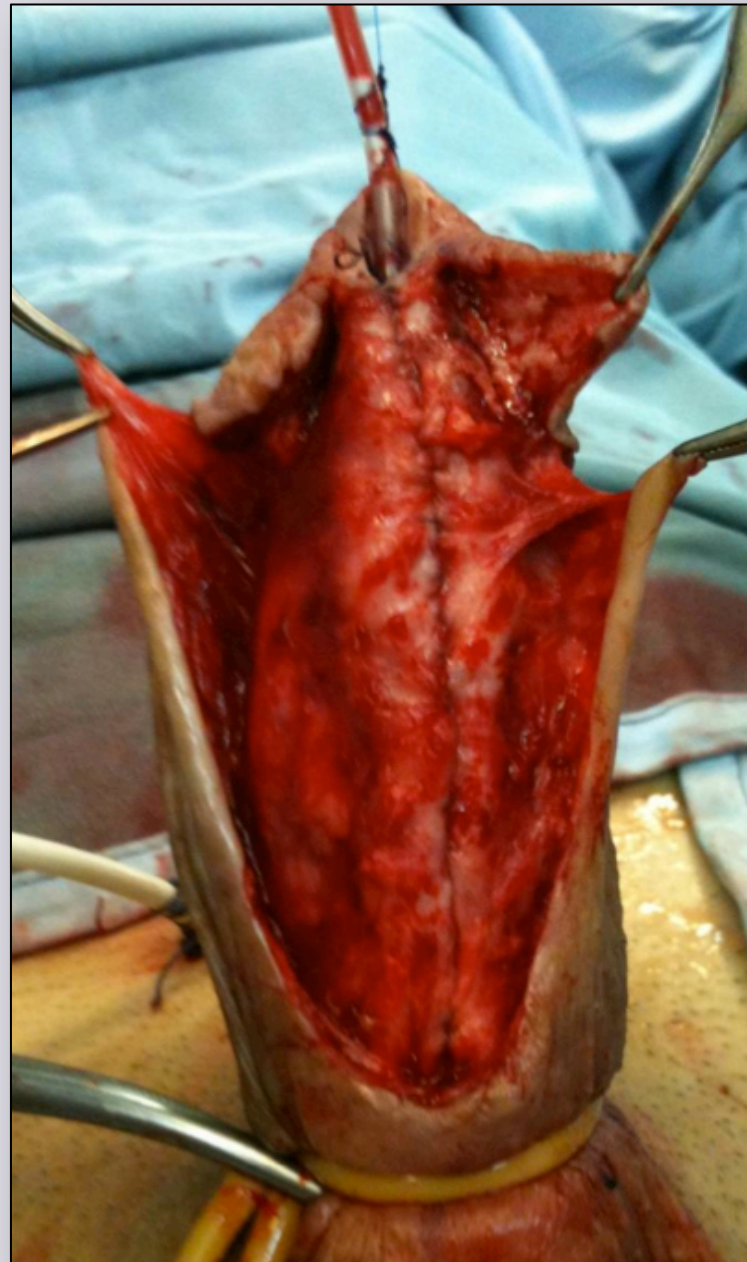Second stage – Oral graft inlay urethroplasty





e-mail: info@urethralcenter.it

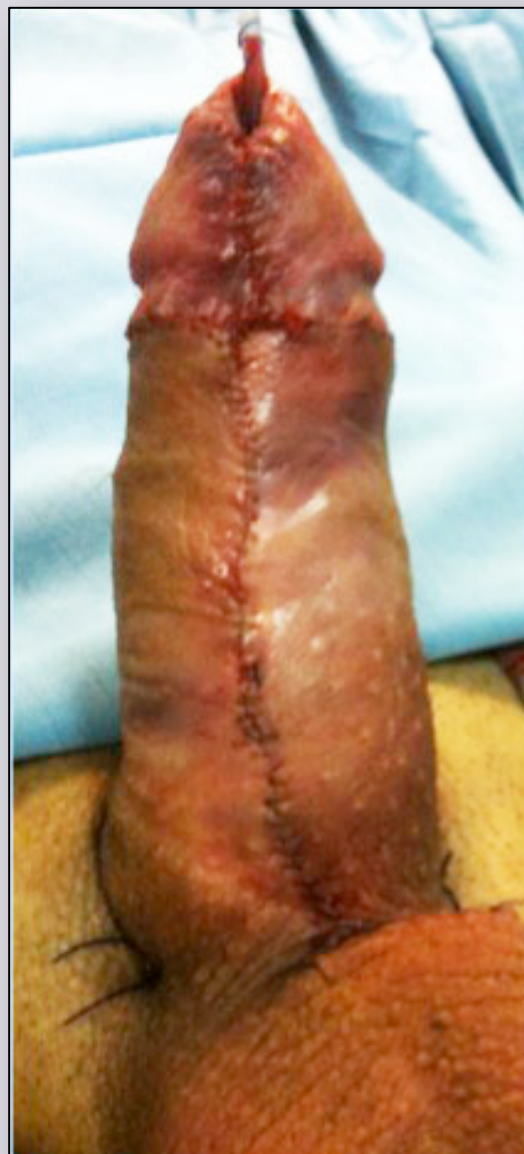Websites: www.uretra.it
www.urethralcenter.it



e-mail: info@urethralcenter.it

Websites: www.uretra.it
www.urethralcenter.it

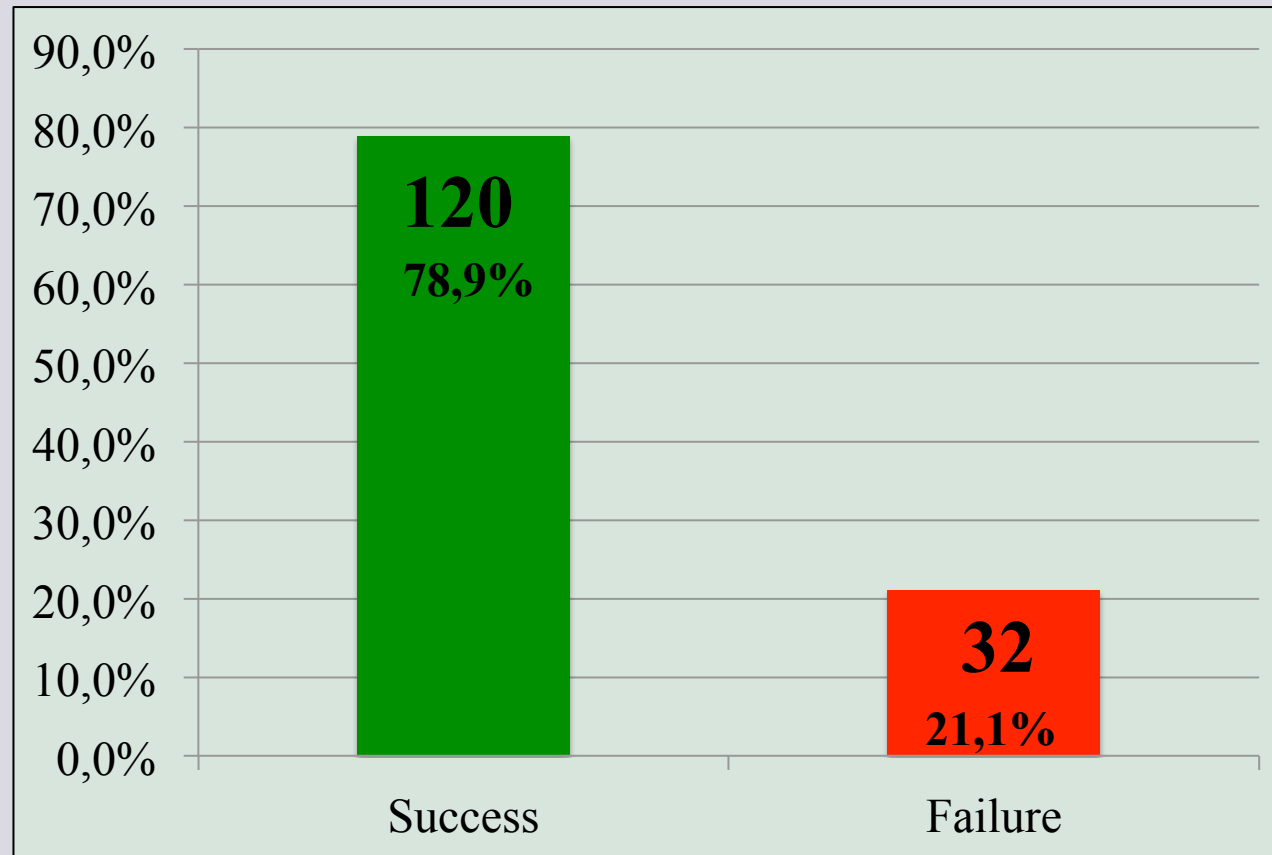
CENTER FOR RECONSTRUCTIVE URETHRAL SURGERY



e-mail: info@urethralcenter.it

Websites: www.uretra.it
www.urethralcenter.it

Our results in 152 patients updated to December 2013



Our results in 152 patients updated to December 2013

type of surgery	N. patients	success	failure
One-stage oral graft	37 (24.3%)	31 (83.8%)	6 (16.2%)
One-stage skin graft	34 (22.3%)	23 (67.6%)	11 (32.4%)
One-stage skin graft	14 (9.2%)	10 (71.4%)	4 (28.6%)
Two-stage	13 (8.6%)	10 (76.9%)	3 (23.1%)
Two-stage oral graft	17 (11.2%)	15 (88.2%)	2 (11.8%)
Other	37	-	-
TOTAL	152		

Conclusions



It is difficult to standardize the surgical therapeutic strategy in patients with penile urethral stricture and many factors should be take into consideration before to plan the surgery.

Conclusions

Stricture etiology
Radiological features
Features of the penis and genitalia

Surgeon background and experience/preference

Patient age and expectations
Patient co-morbidity
Patient psychological status



Register now !

www.webon.uretra.it

e-mail: info@urethralcenter.it

Websites: www.uretra.it
www.urethralcenter.it