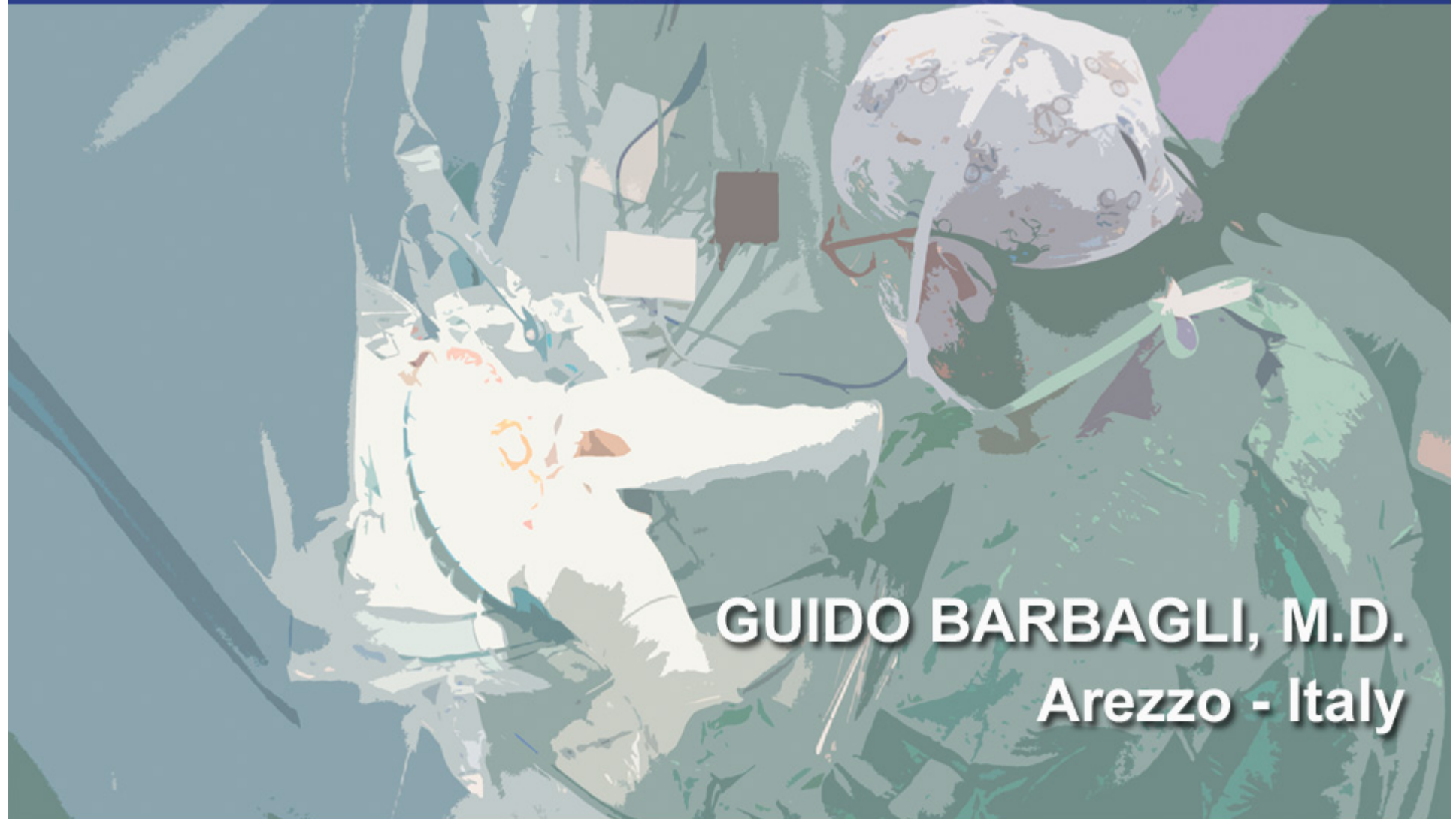

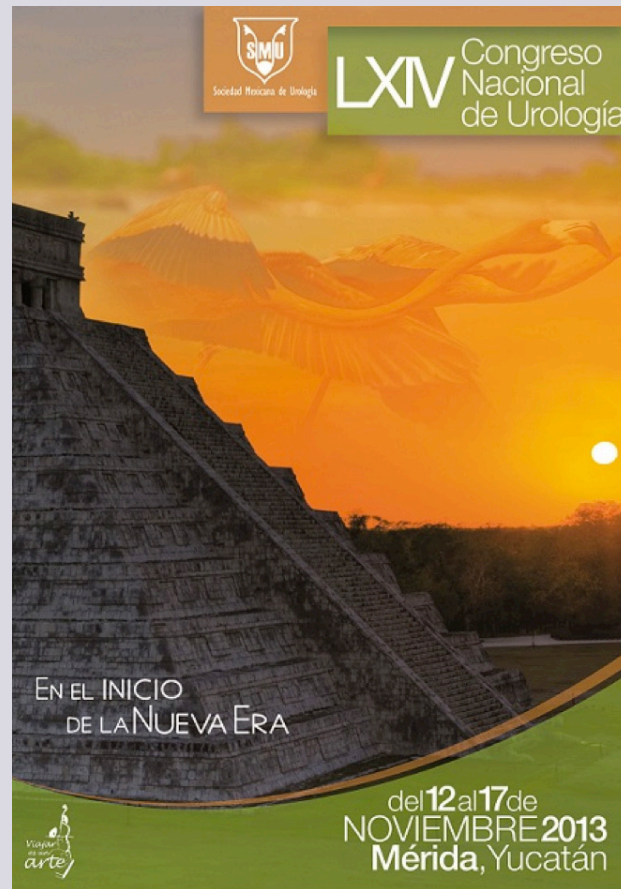CENTER FOR RECONSTRUCTIVE URETHRAL SURGERY



GUIDO BARBAGLI, M.D.
Arezzo - Italy

e-mail: info@urethralcenter.it

Websites: www.uretra.it
www.urethralcenter.it



Nueva clasificación de las estenosis de uretra y algoritmo simplificado del tratamiento

e-mail: info@urethralcenter.it

Websites: www.uretra.it
www.urethralcenter.it

Based-evidence Medicine

Metanalysis review

Guidelines

Consensus Conferences



Urological literature on urethral stricture

- ❖ Few prospective, randomized studies
- ❖ No homogenous series of patients
- ❖ Small sample size – no statistical significance



Can Reconstructive Urethral Surgery Proceed Without Randomised Controlled Trials?

Guido Barbagli^a, Massimo Lazzeri^{b,*}

^a Center for Reconstructive Urethral Surgery, Arezzo, Italy

^b Department of Urology, Santa Chiara Hospital (GIOMI group), Florence, Italy

What has history taught us? The history of urethral reconstruction is based on observational studies that appear today to be disarming in their apparent ease. In 1968, Orandi introduced the concept of penile skin flap urethroplasty, publishing a paper consisting merely of two pages and two black and white figures and that lacked any outcome assessment [10]. Oral mucosa has become the most popular substitute material in the treatment of urethral strictures, as it is readily available and easily harvested from the cheek, lip, or tongue, allowing for a concealed donor site scar and low oral morbidity [11–14]. Unfortunately, all the papers that have contributed to the widespread use of the oral mucosa graft are retrospective, not prospective, and they are not RCTs.

**Personal opinion of high-volume surgeon from
high-volume Center for Urethral Surgery
(± 400 urethral surgeries for year)**

Data published in peer review scientific Journals

**Data fully available and updated in our websites
every two years**



Opposing Views

Urethral Strictures is Now an Open Surgical Disease

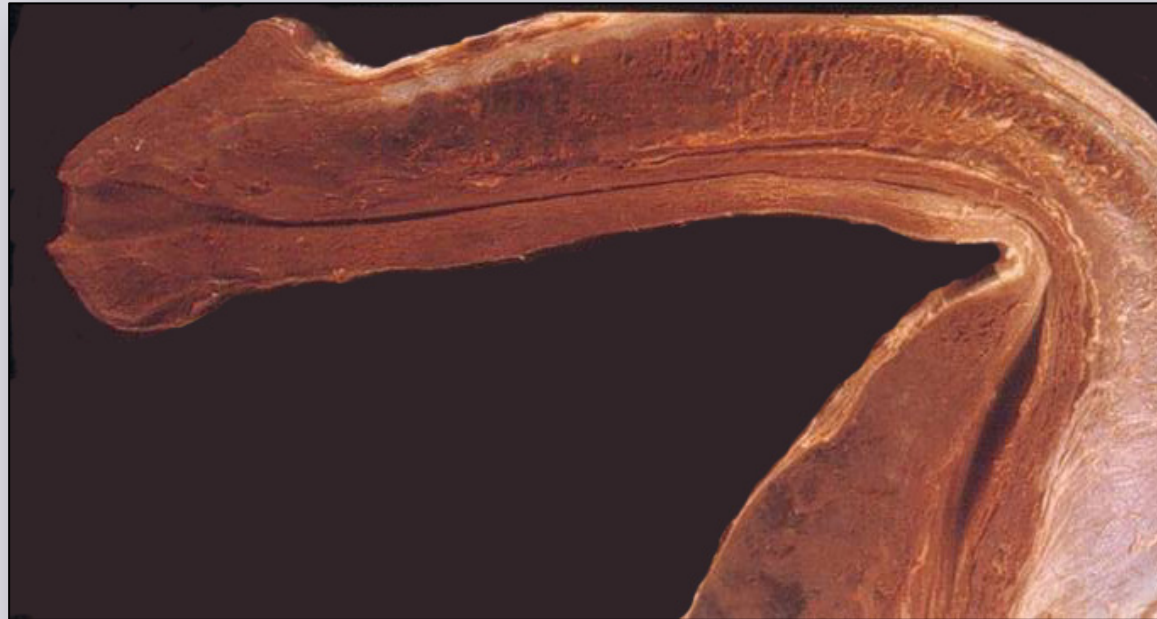
Allen Morey

**Cost-Effective Approach to Short Bulbar Urethral Strictures
Supports Single Internal Urethrotomy Before Urethroplasty**

Hunter Wessels

J Urol 2009; 181: 953-955

New classification of anterior urethral strictures

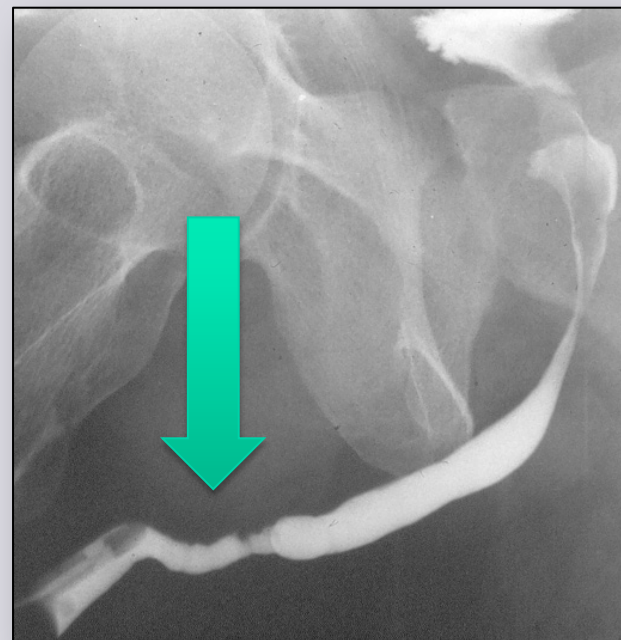
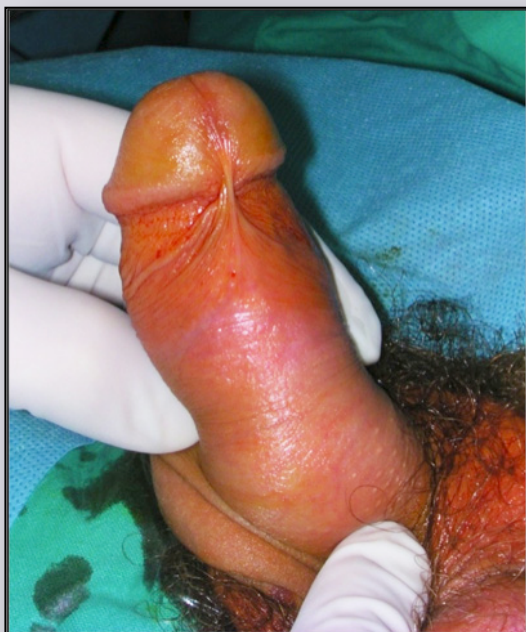

Penile

Simple

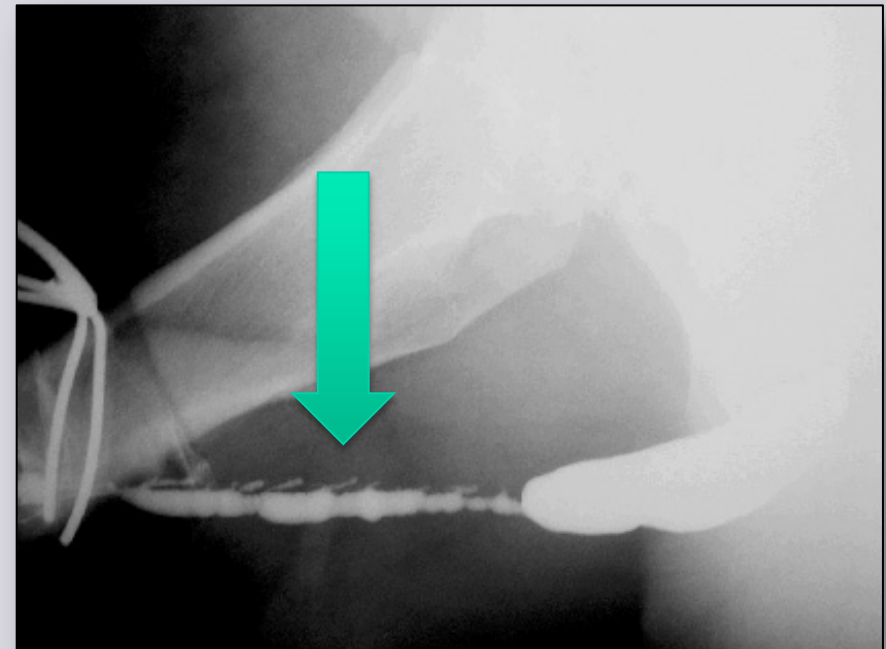
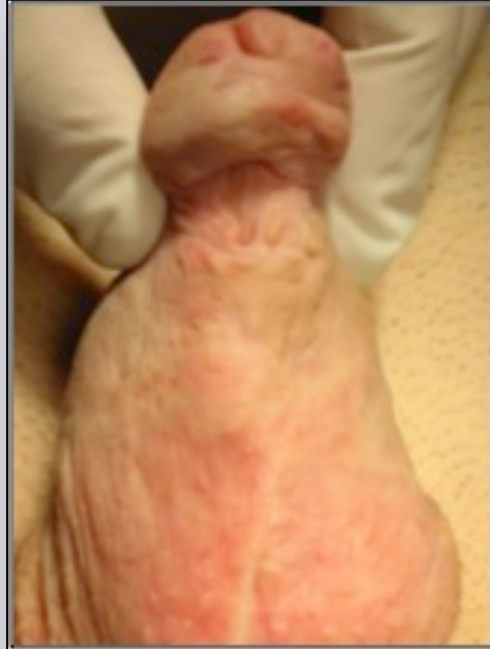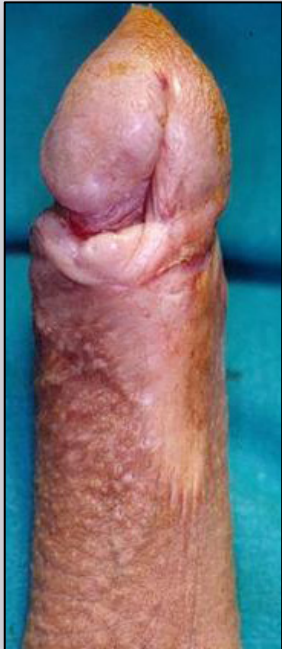Complex

Simple penile urethral stricture



1. The penis and genitalia are normal
2. Practicable urethral plate
3. No Lichen sclerosus
4. No failed hypospadias repair
5. No prior failed urethroplasty

Complex penile urethral stricture



1. Genital lichen sclerosus
2. Failed hypospadias
3. Prior failed urethroplasty
4. No practicable urethral plate

Penile urethral stricture

simple

complex

one-stage repair

two-stage repair

**wide urethral
plate**

oral graft inlay

**narrow urethral
plate**

penile skin flap

**one-stage urethroplasty
by perineal approach**

Failed hypospadias

**first-stage
Johanson**

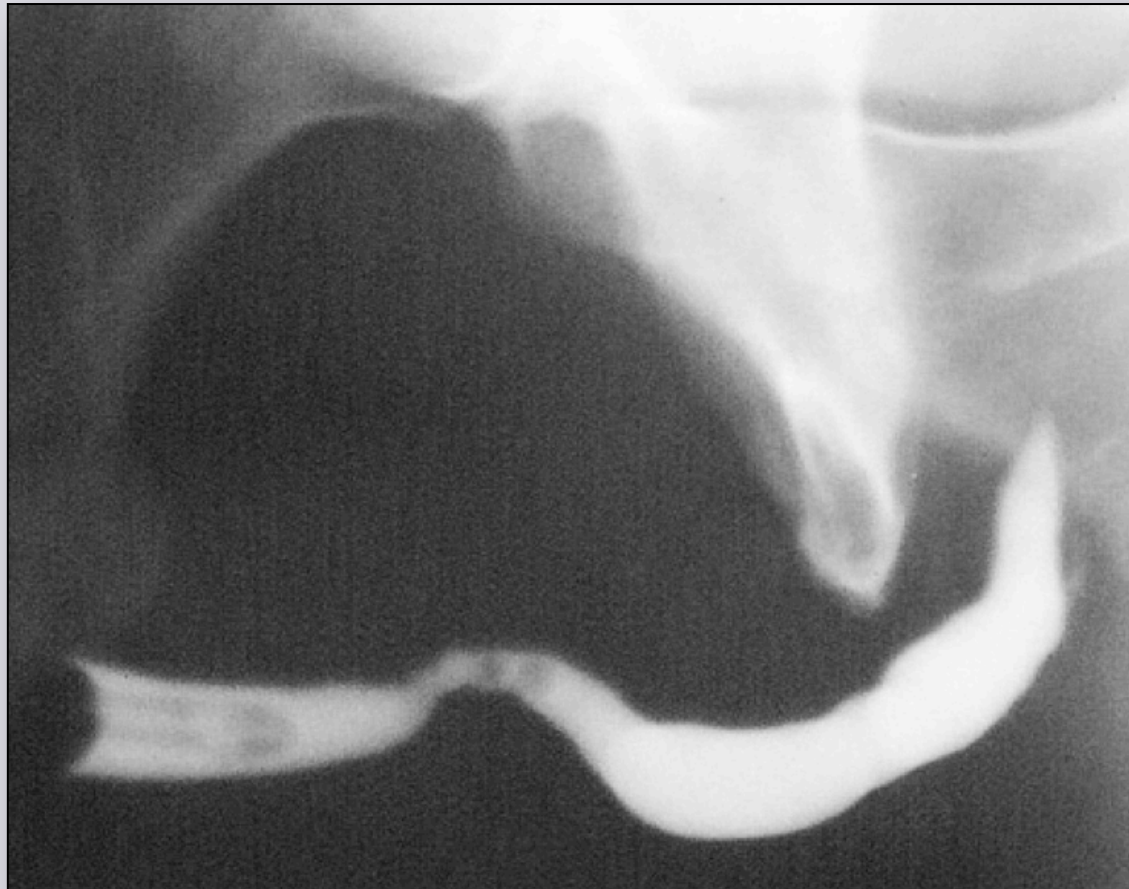**second-stage
oral graft inlay**

Lichen sclerosus

**first-stage
oral mucosa**

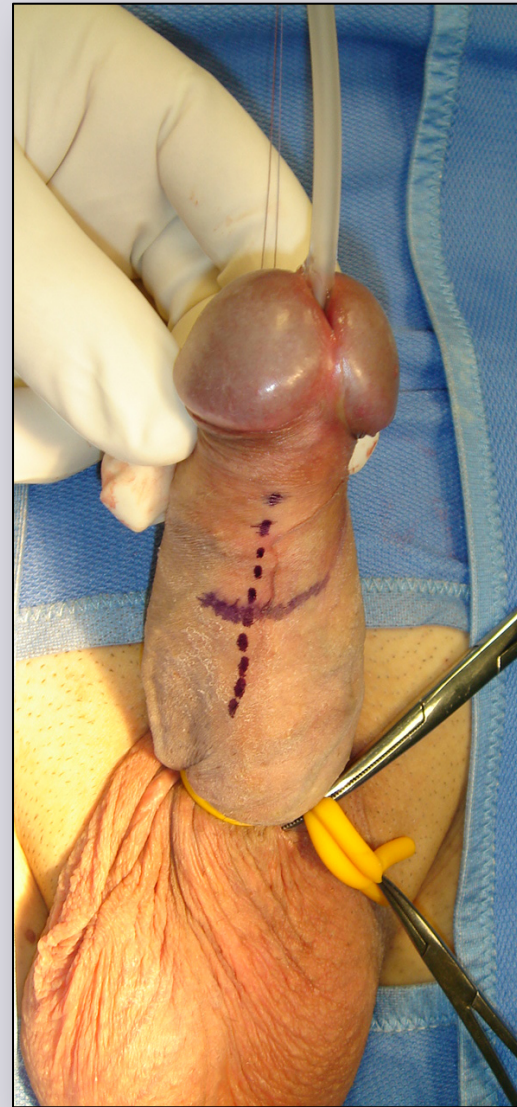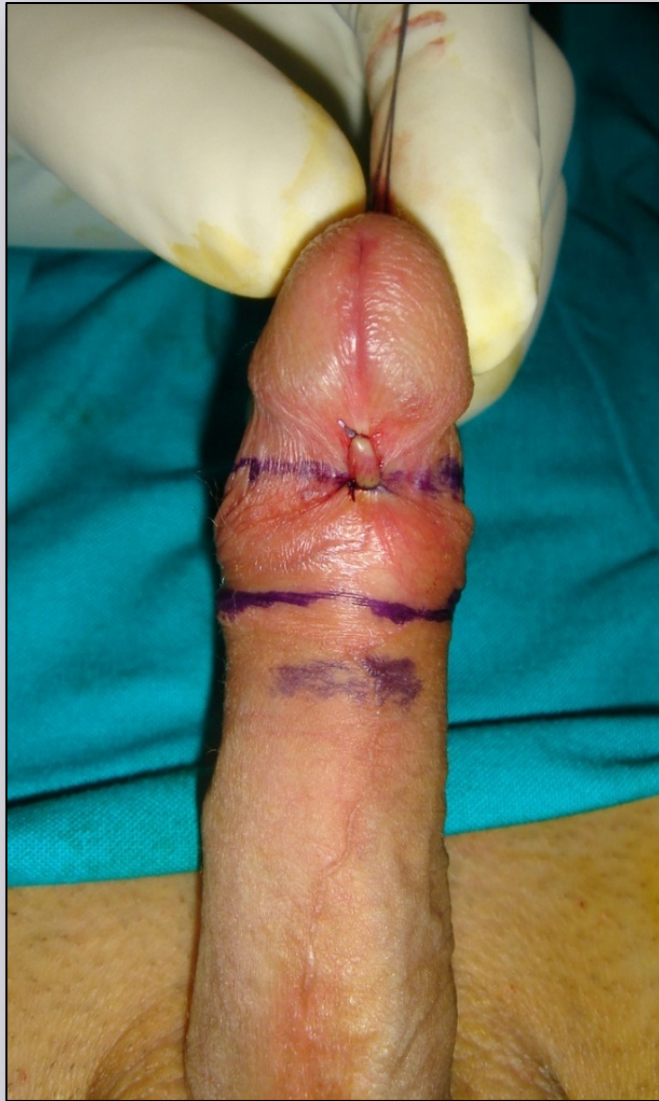**second-stage
primary closure**

One-stage oral graft inlay urethroplasty



Wide urethral plate

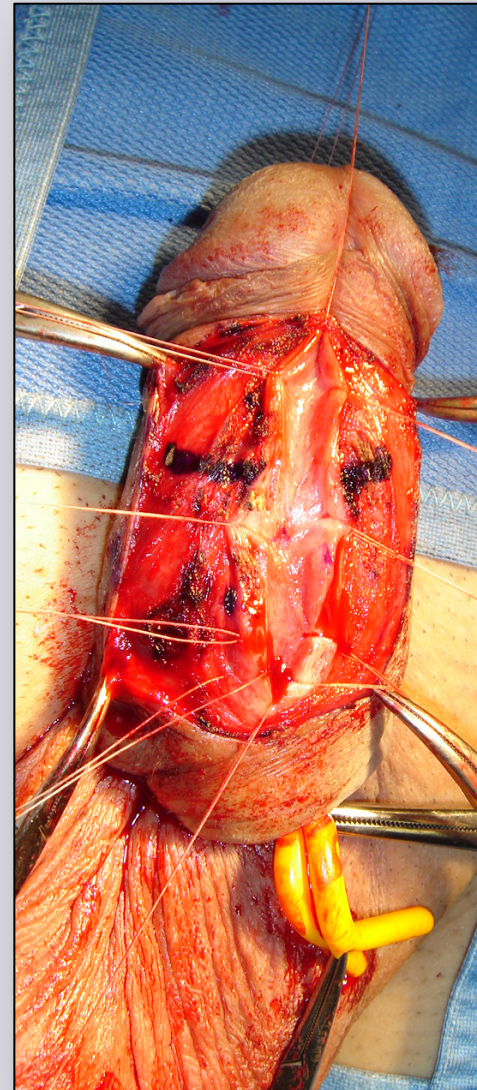
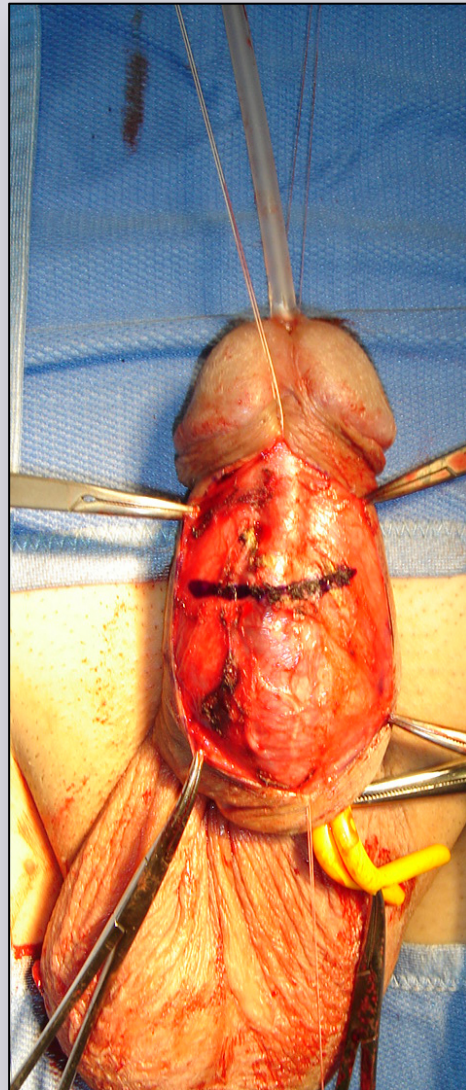
One-stage oral graft inlay urethroplasty



e-mail: info@urethralcenter.it

Websites: www.uretra.it
www.urethralcenter.it

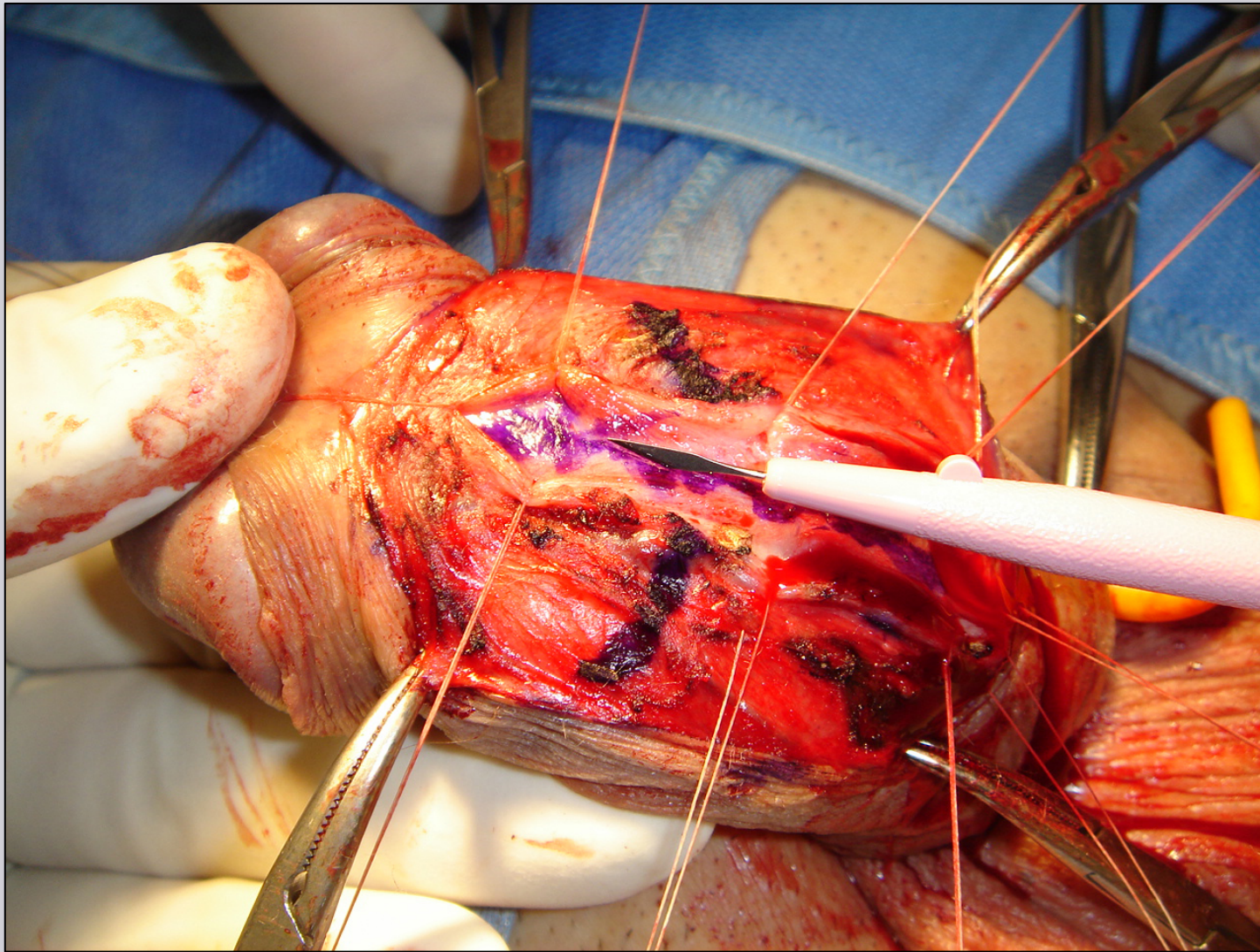
One-stage oral graft inlay urethroplasty



e-mail: info@urethralcenter.it

Websites: www.uretra.it
www.urethralcenter.it

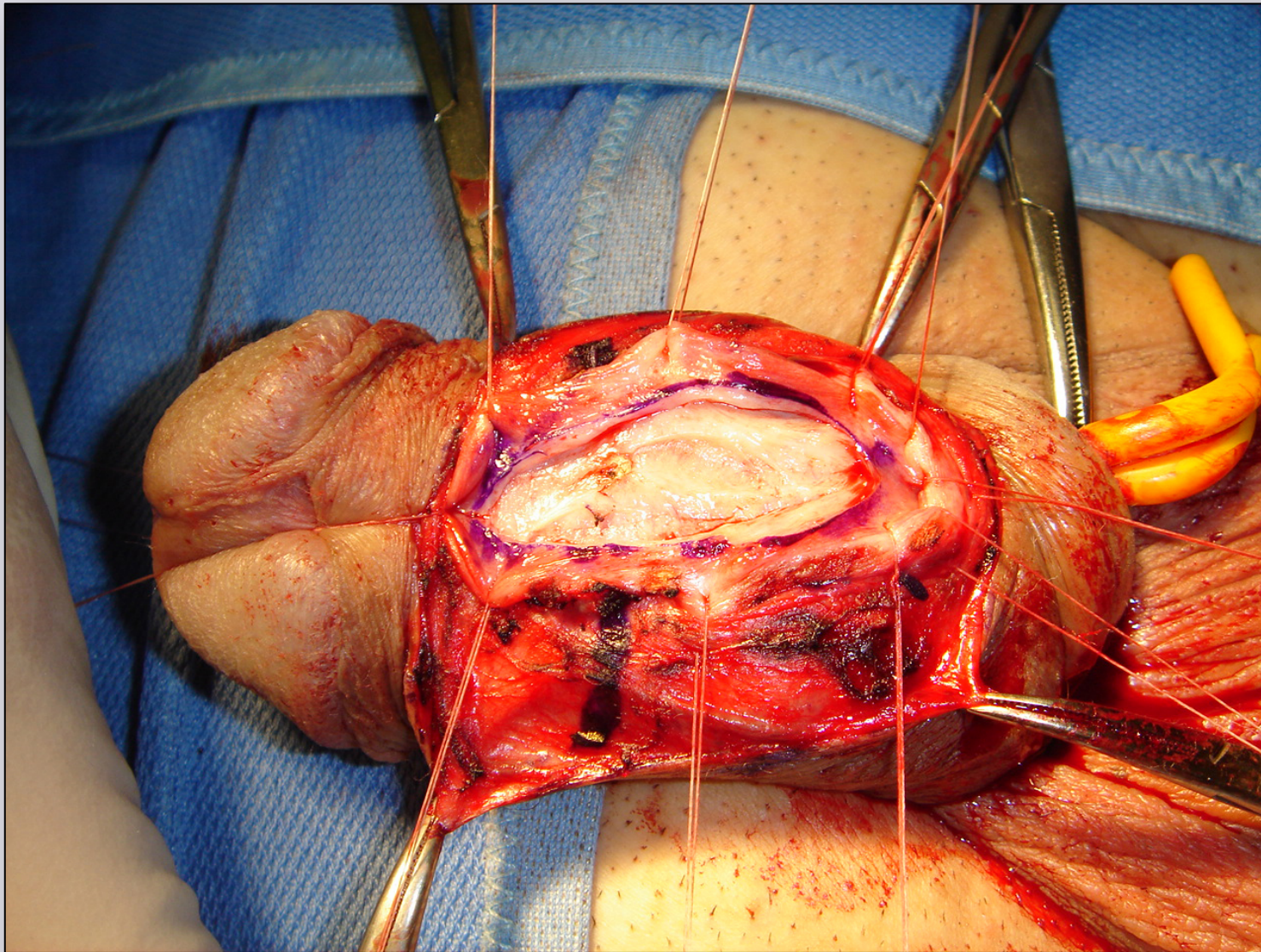
One-stage oral graft inlay urethroplasty



e-mail: info@urethralcenter.it

Websites: www.uretra.it
www.urethralcenter.it

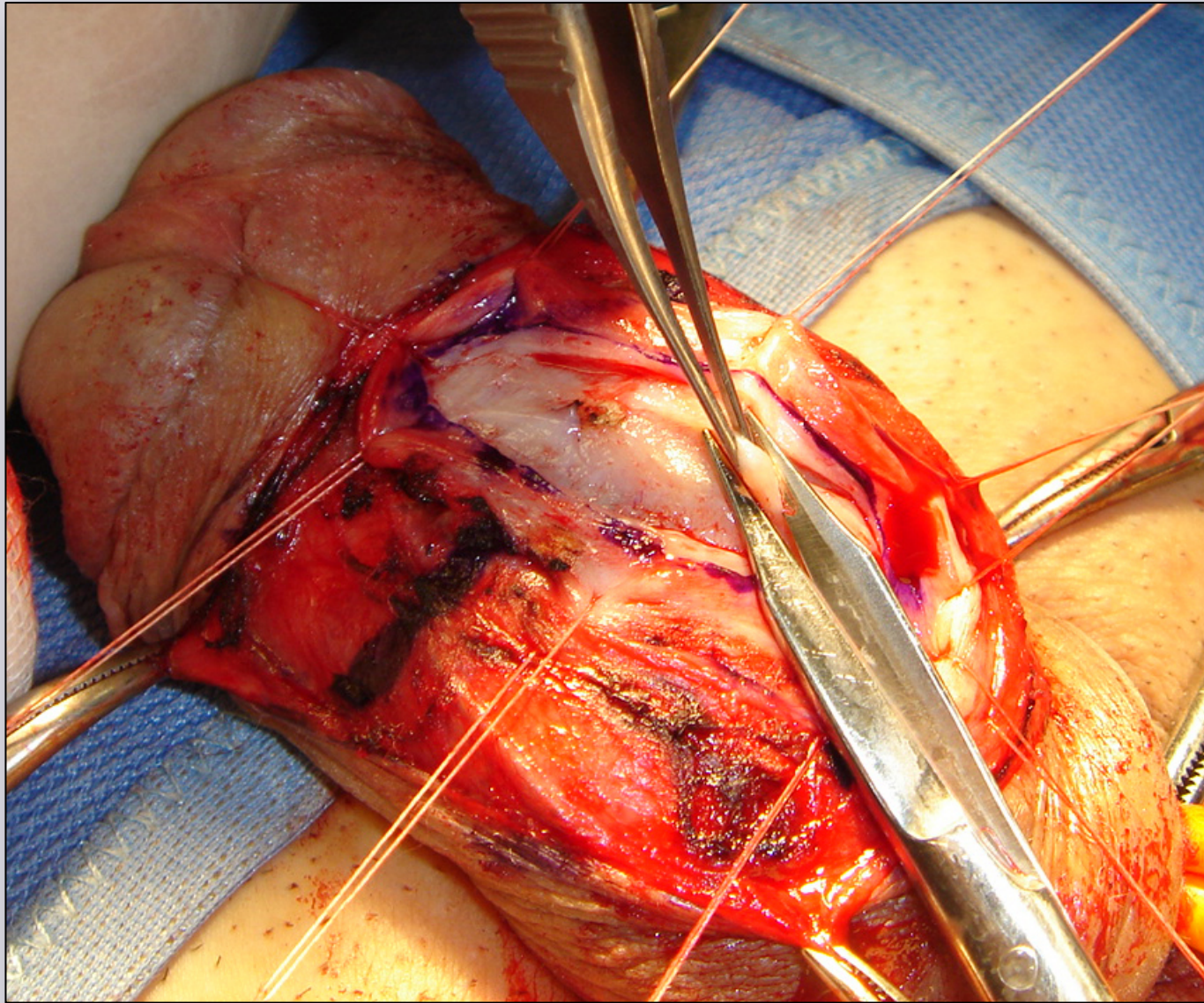
One-stage oral graft inlay urethroplasty



e-mail: info@urethralcenter.it

Websites: www.uretra.it
www.urethralcenter.it

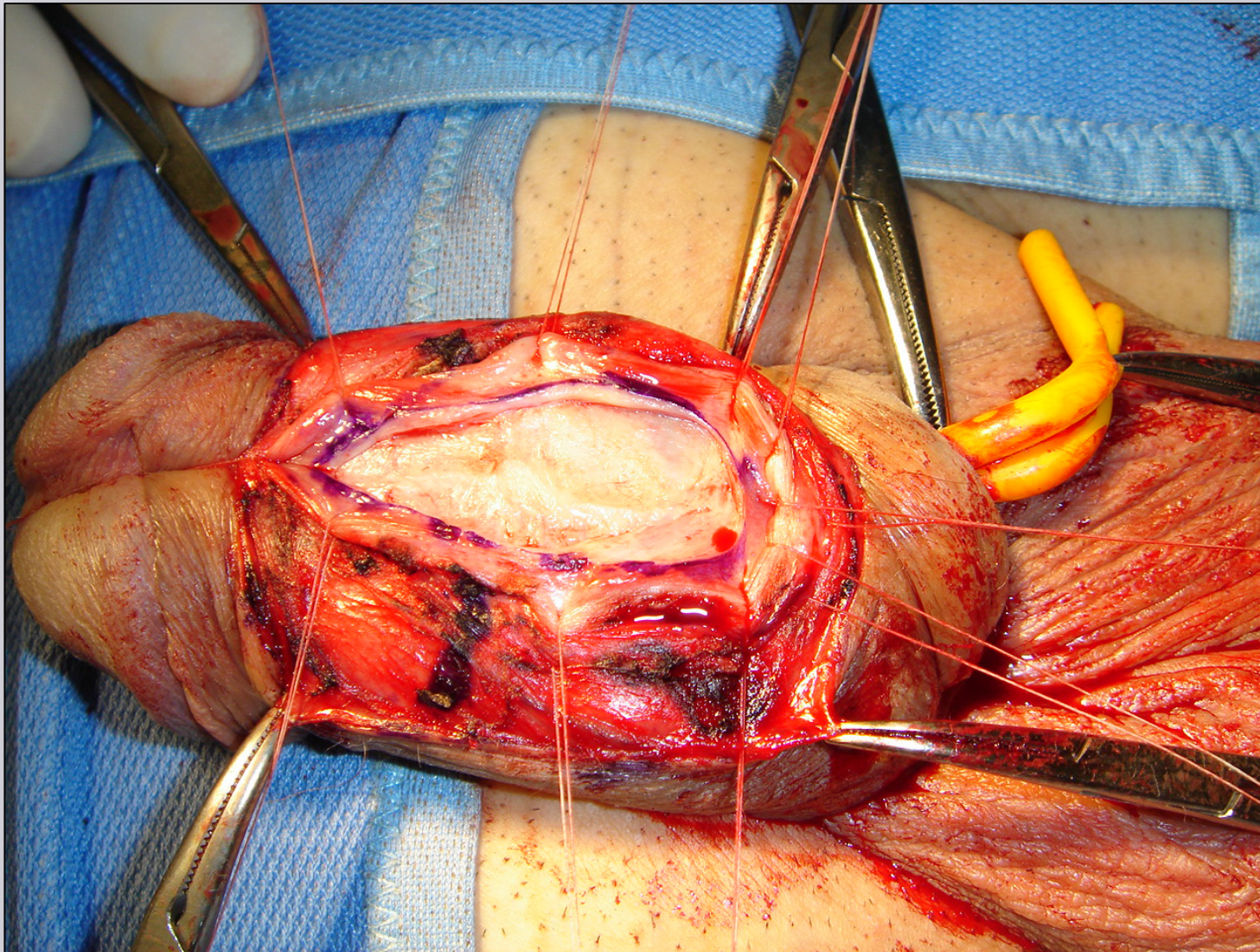
One-stage oral graft inlay urethroplasty



e-mail: info@urethralcenter.it

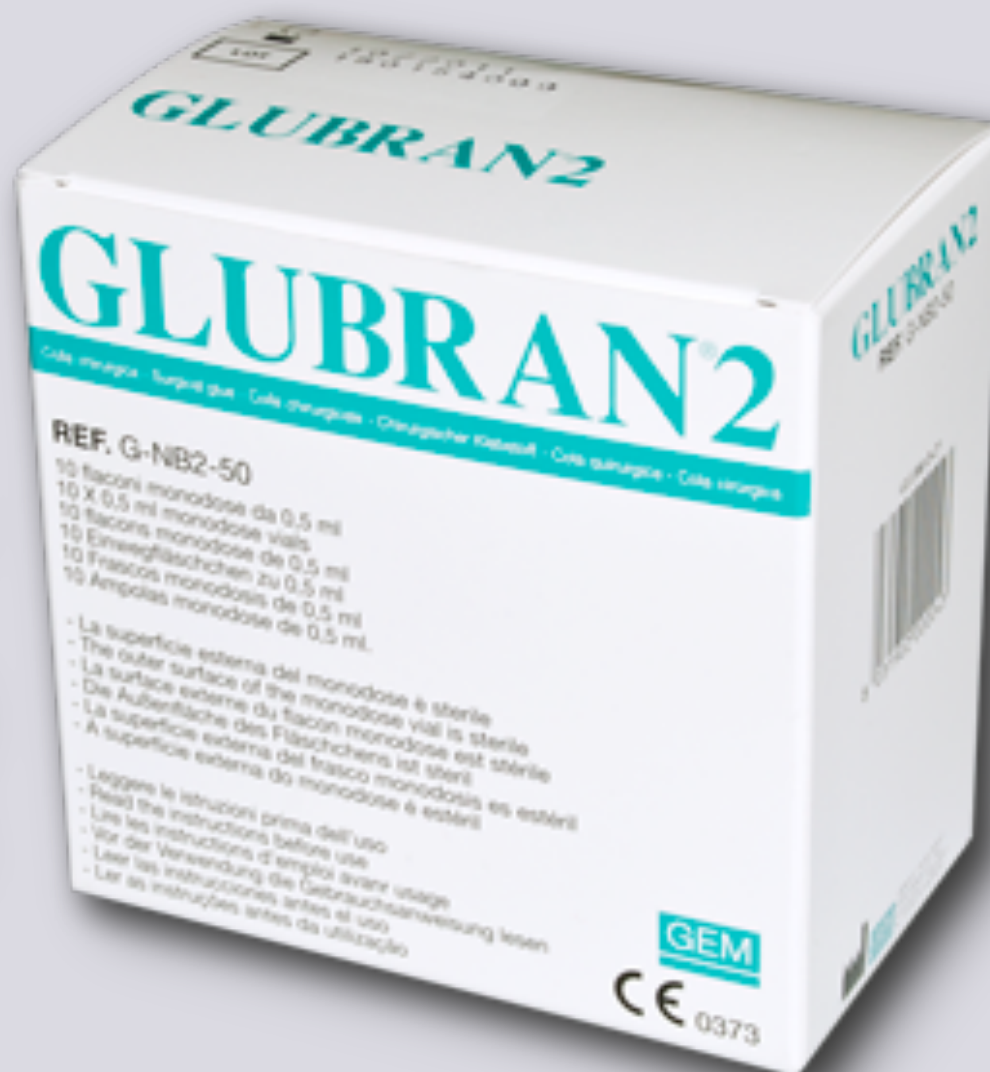Websites: www.uretra.it
www.urethralcenter.it

One-stage oral graft inlay urethroplasty



e-mail: info@urethralcenter.it

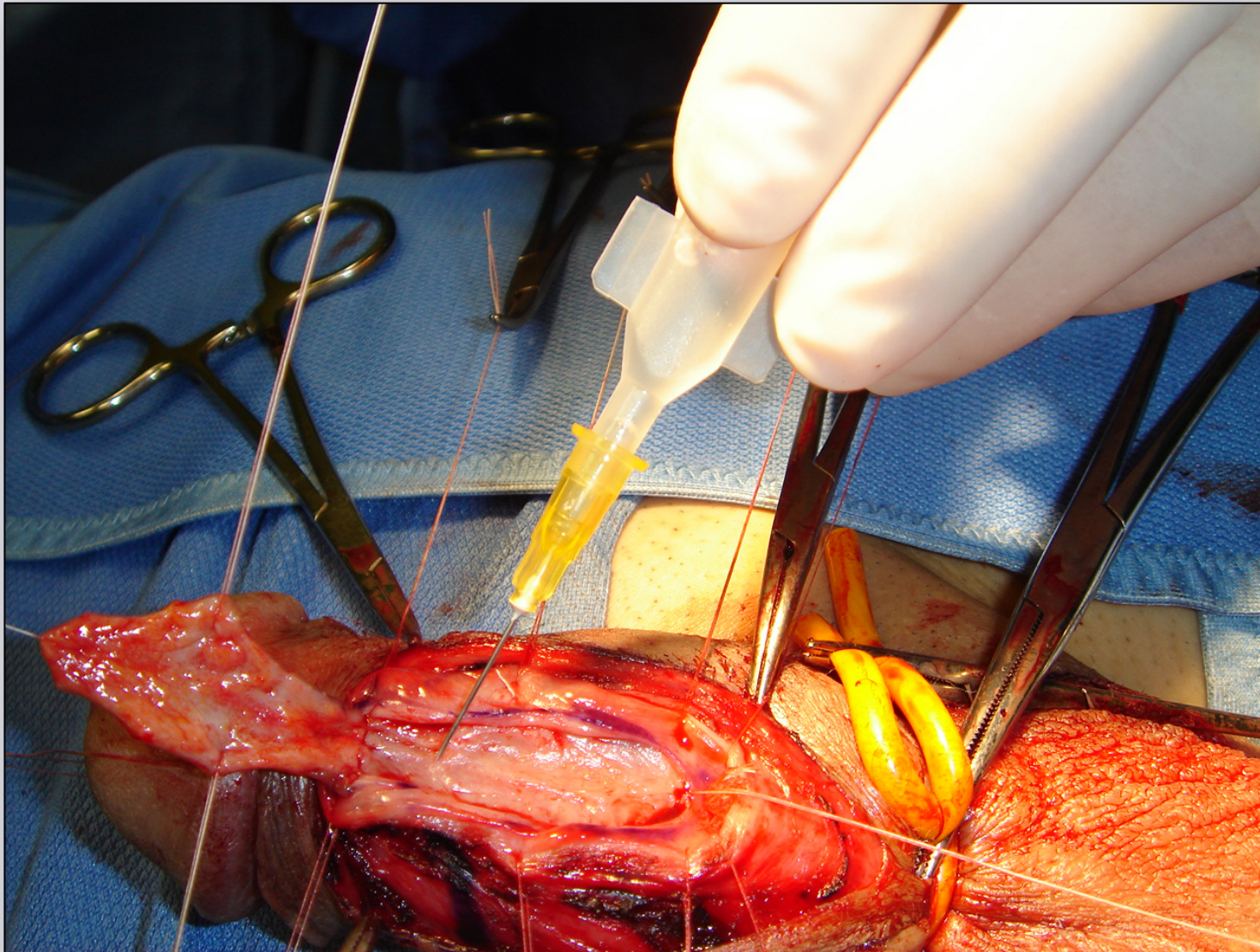
Websites: www.uretra.it
www.urethralcenter.it



e-mail: info@urethralcenter.it

Websites: www.uretra.it
www.urethralcenter.it

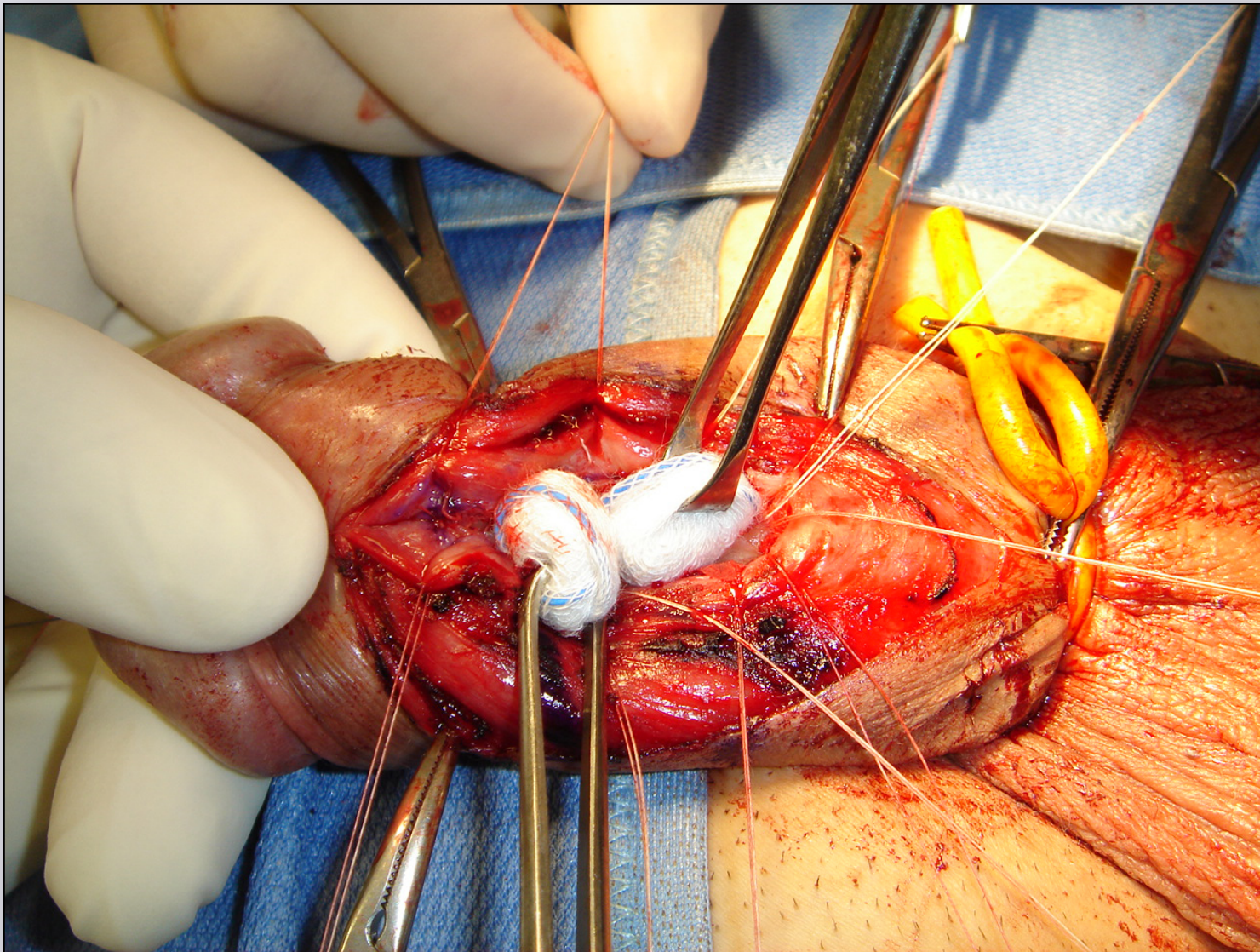
One-stage oral graft inlay urethroplasty



e-mail: info@urethralcenter.it

Websites: www.uretra.it
www.urethralcenter.it

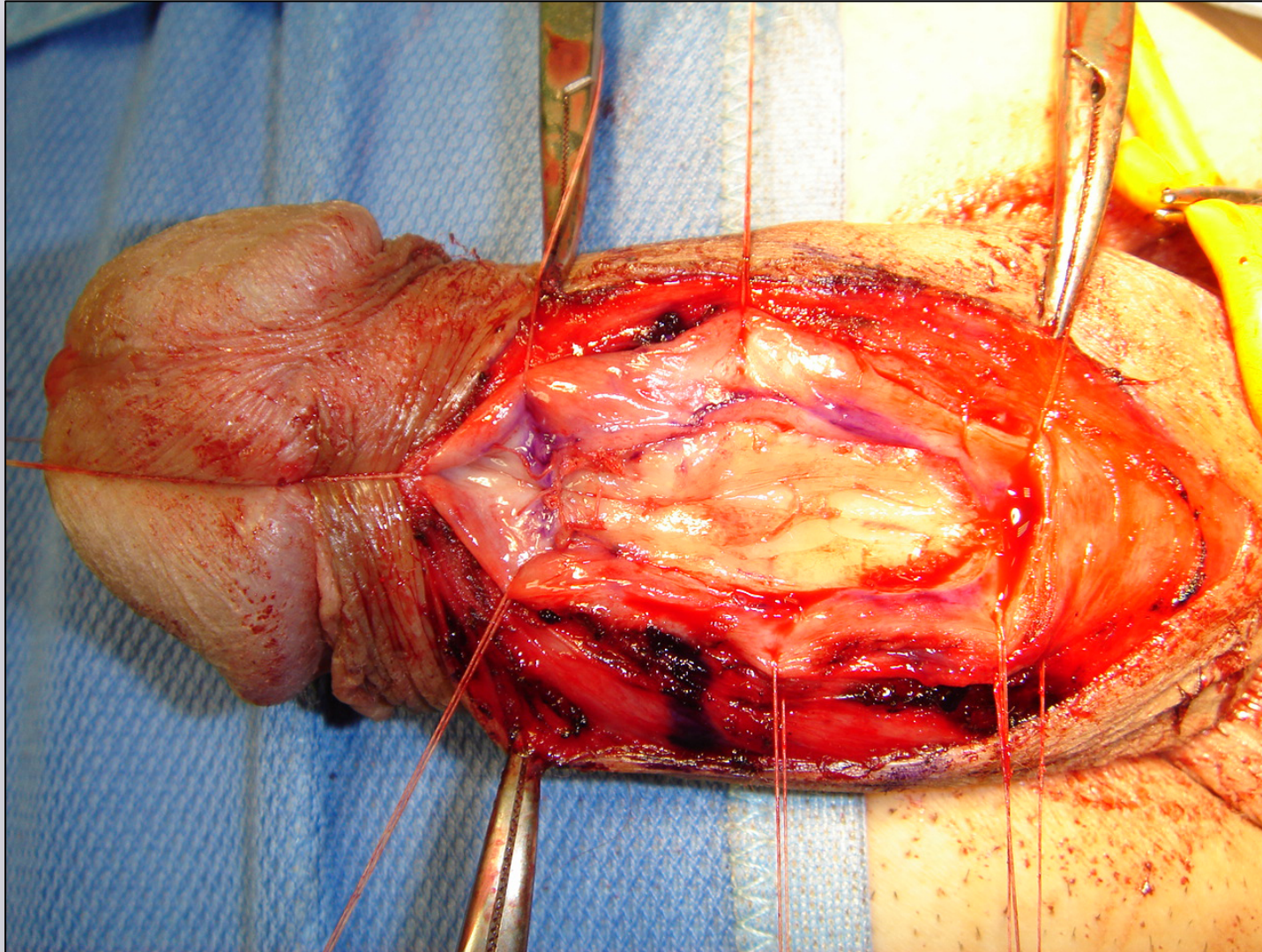
One-stage oral graft inlay urethroplasty



e-mail: info@urethralcenter.it

Websites: www.uretra.it
www.urethralcenter.it

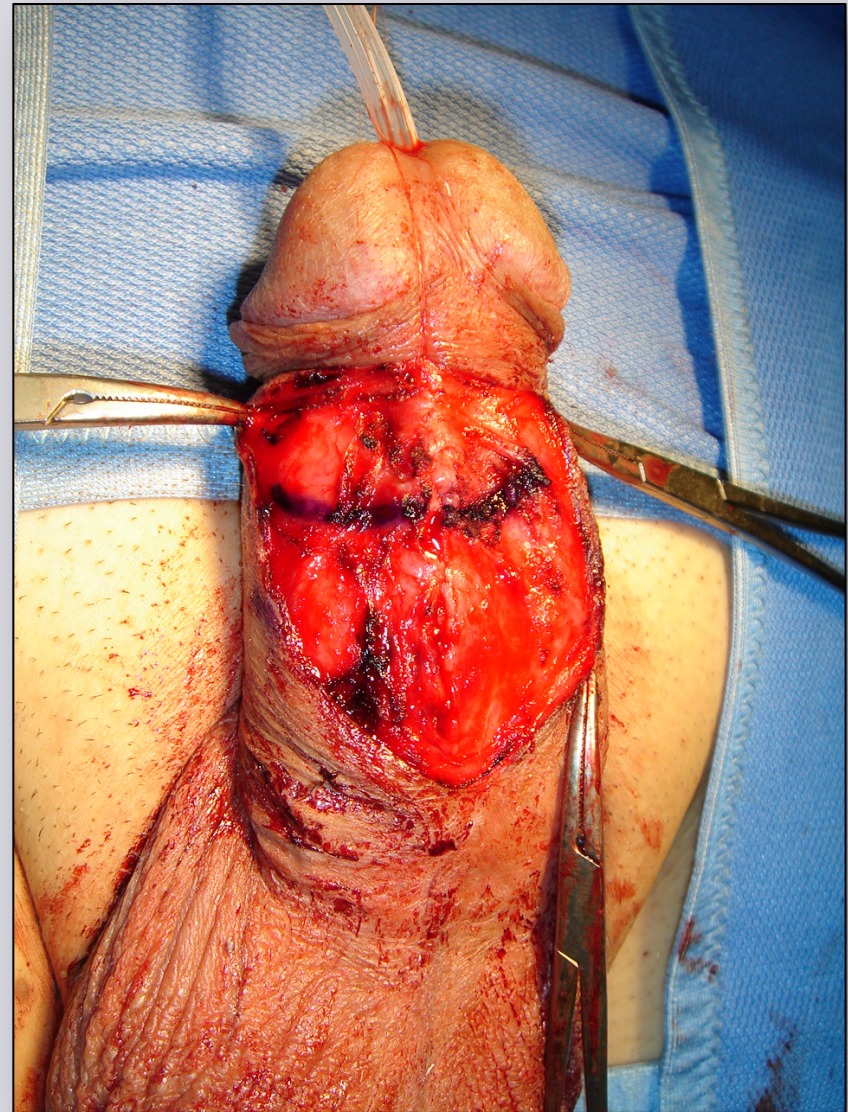
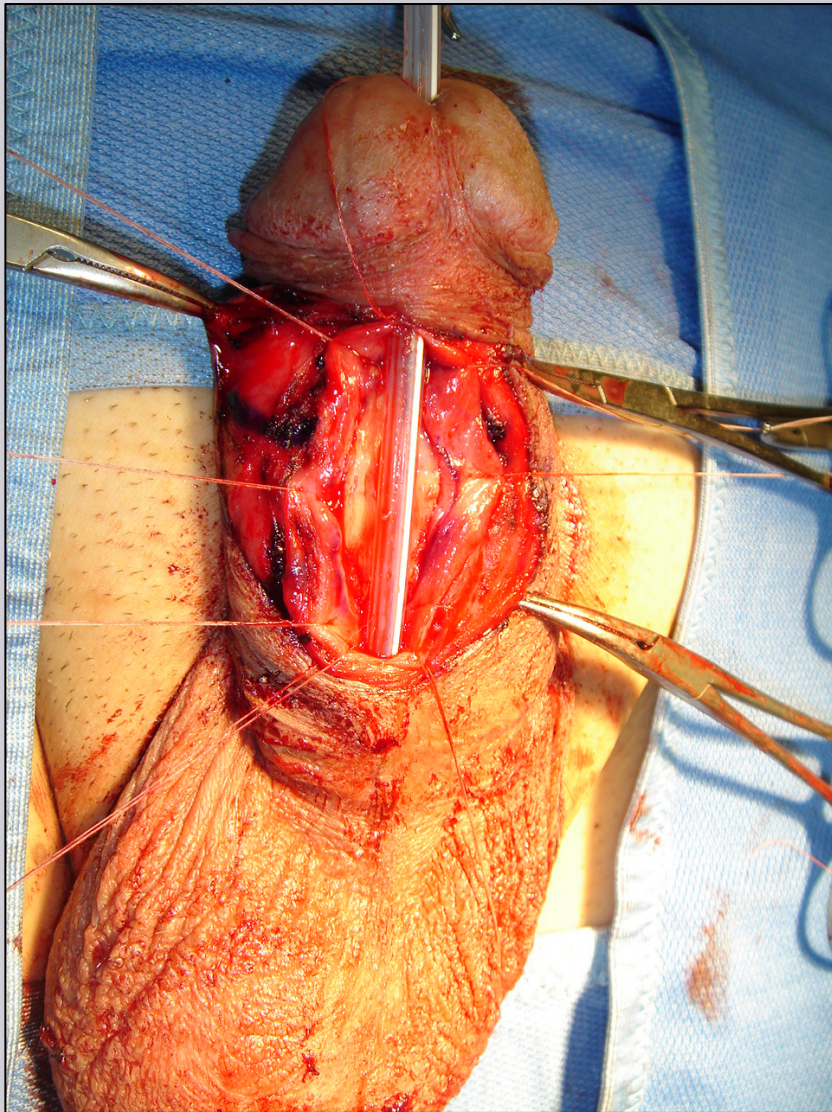
One-stage oral graft inlay urethroplasty



e-mail: info@urethralcenter.it

Websites: www.uretra.it
www.urethralcenter.it

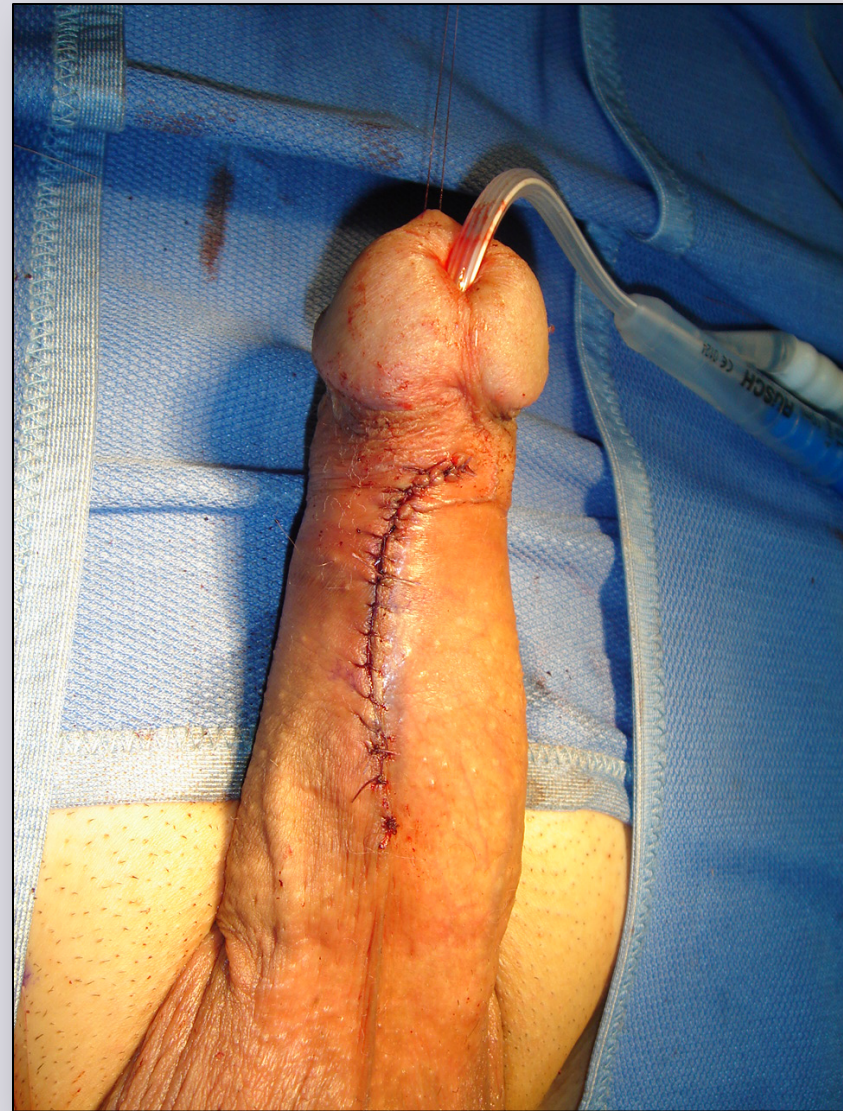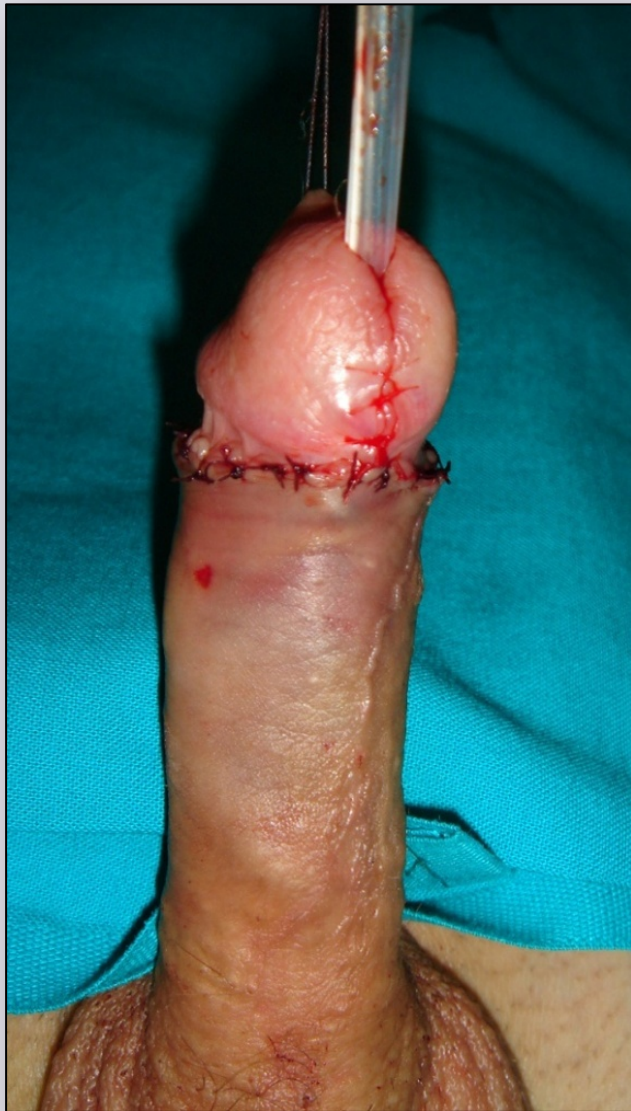One-stage oral graft inlay urethroplasty



e-mail: info@urethralcenter.it

Websites: www.uretra.it
www.urethralcenter.it

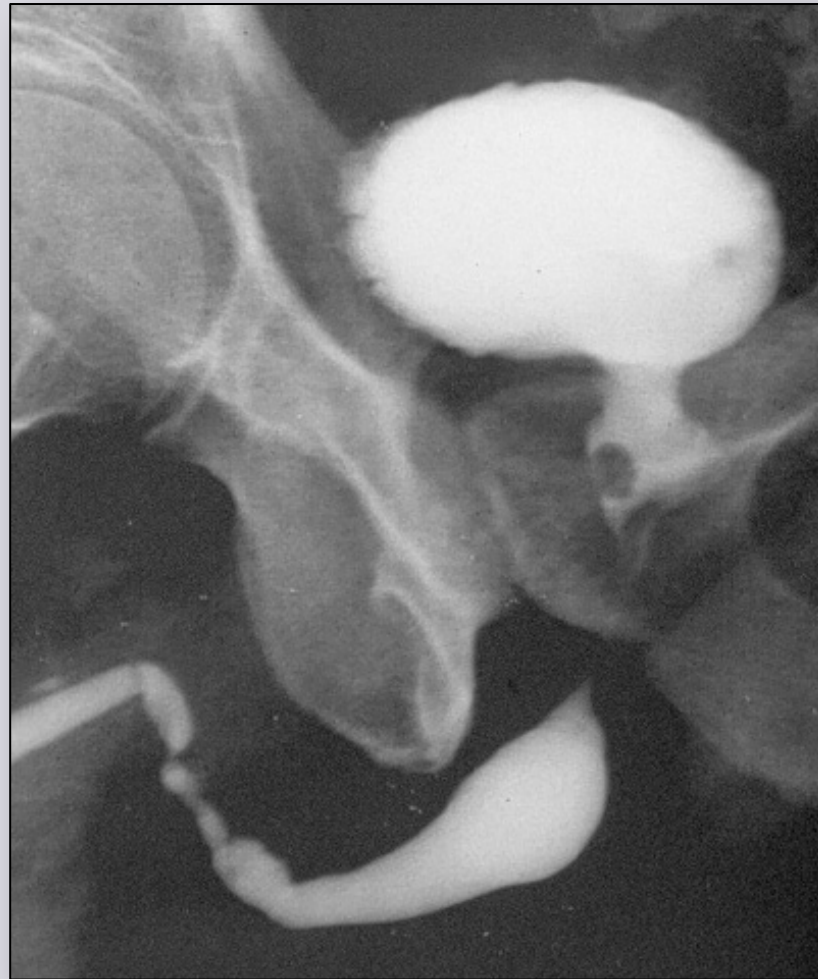One-stage oral graft inlay urethroplasty



e-mail: info@urethralcenter.it

Websites: www.uretra.it
www.urethralcenter.it

One-stage skin flap urethroplasty



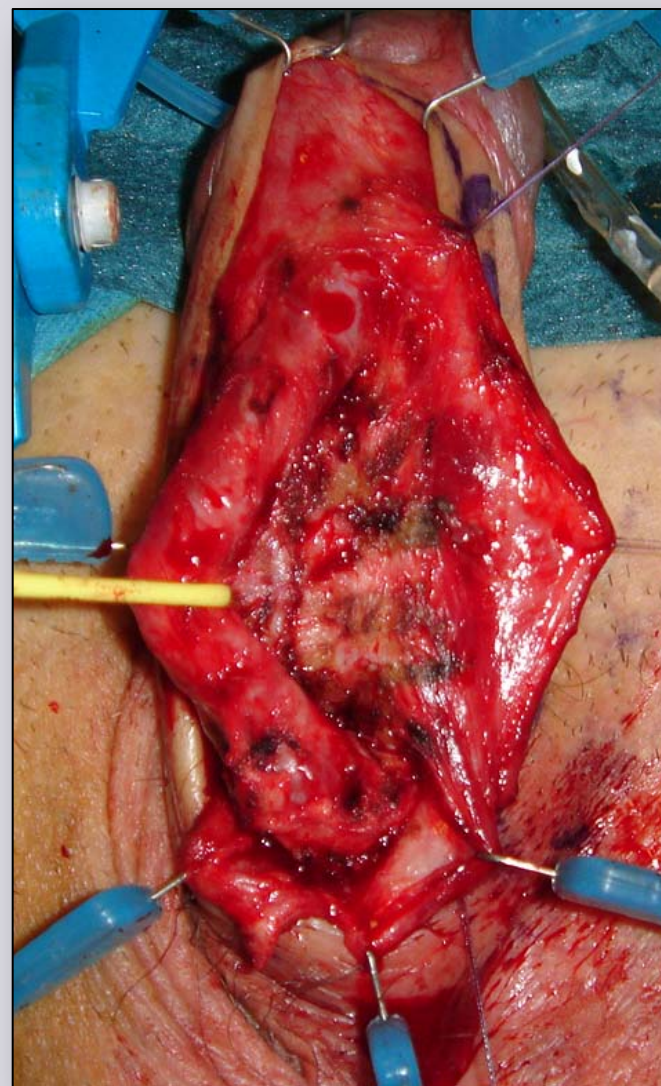
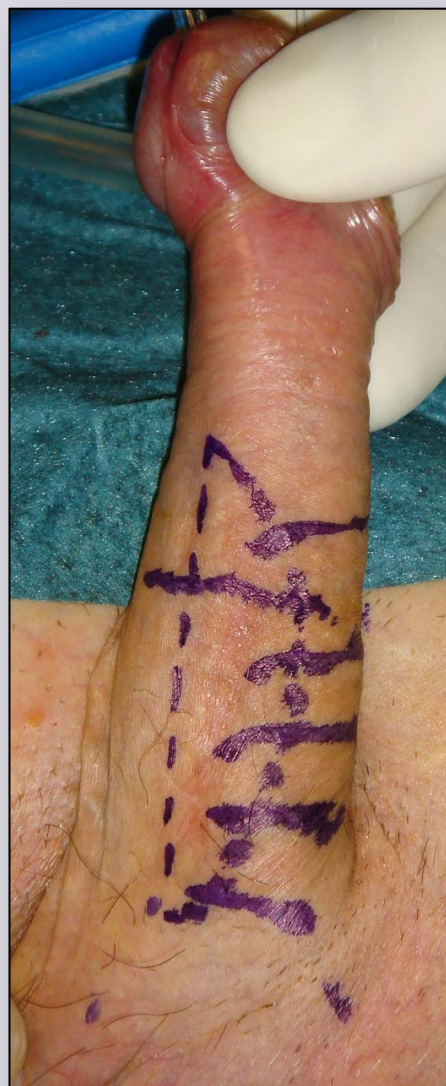Narrow urethral plate

e-mail: info@urethralcenter.it

Websites: www.uretra.it
www.urethralcenter.it

CENTER FOR RECONSTRUCTIVE URETHRAL SURGERY

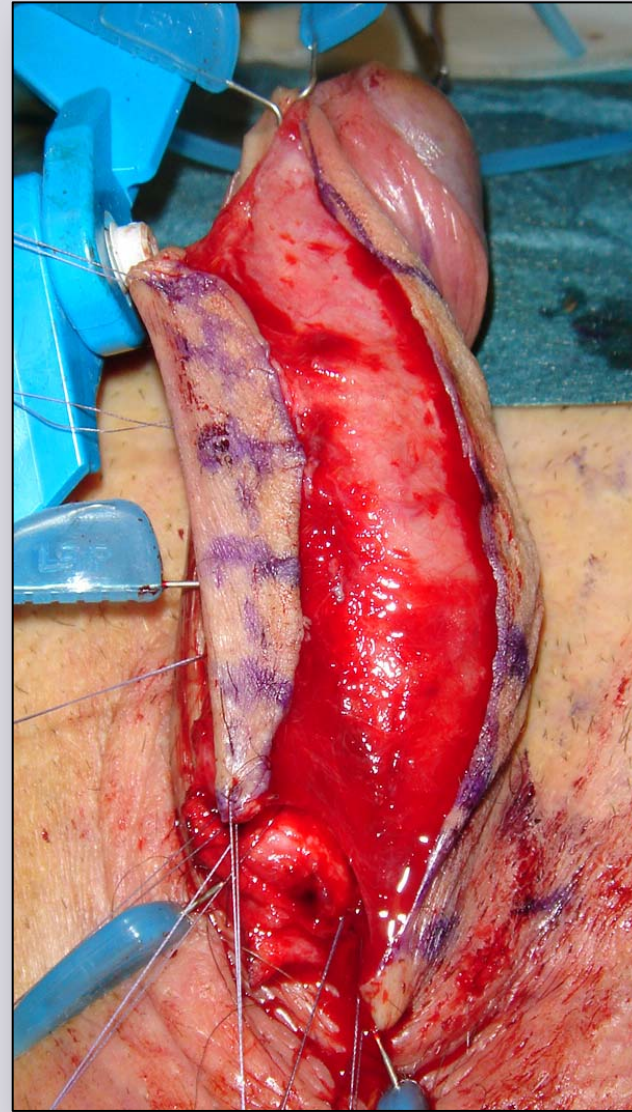
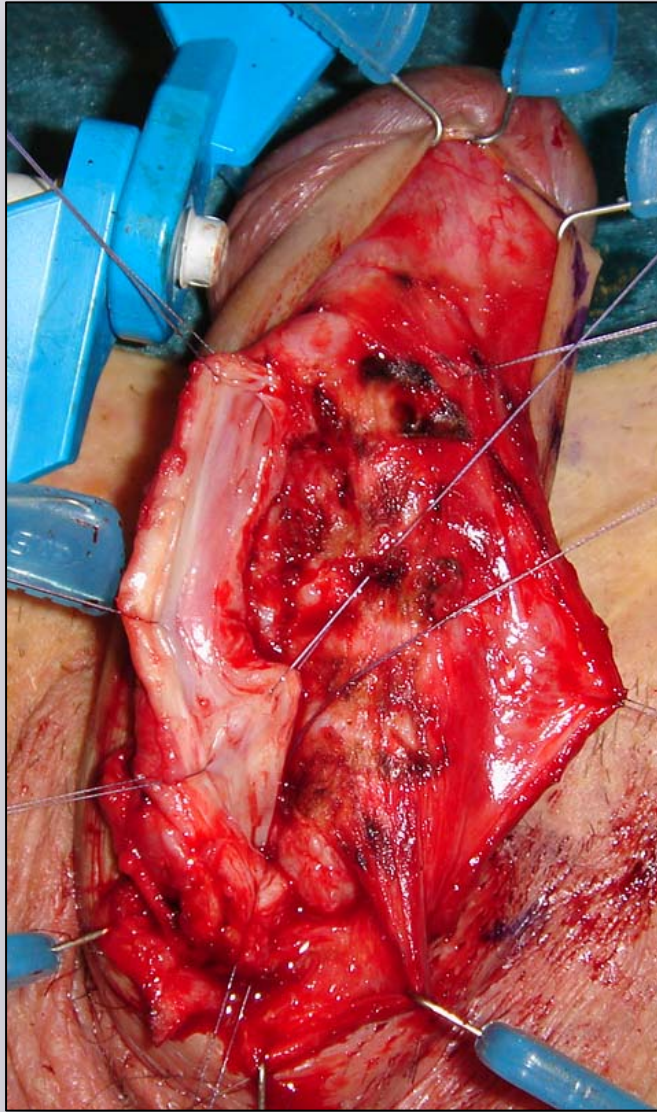
One-stage skin flap urethroplasty



e-mail: info@urethralcenter.it

Websites: www.uretra.it
www.urethralcenter.it

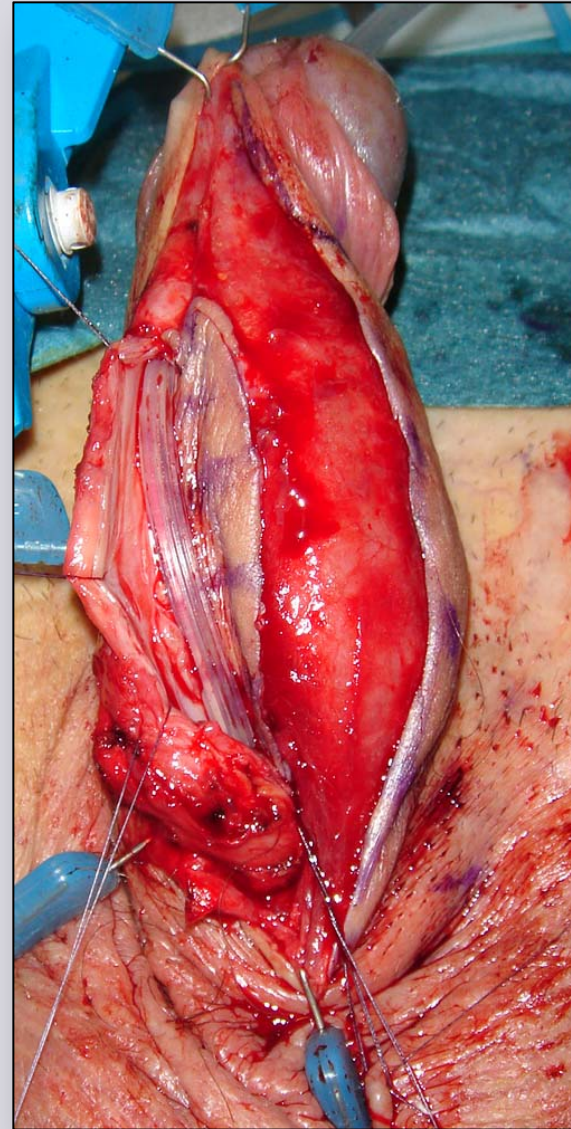
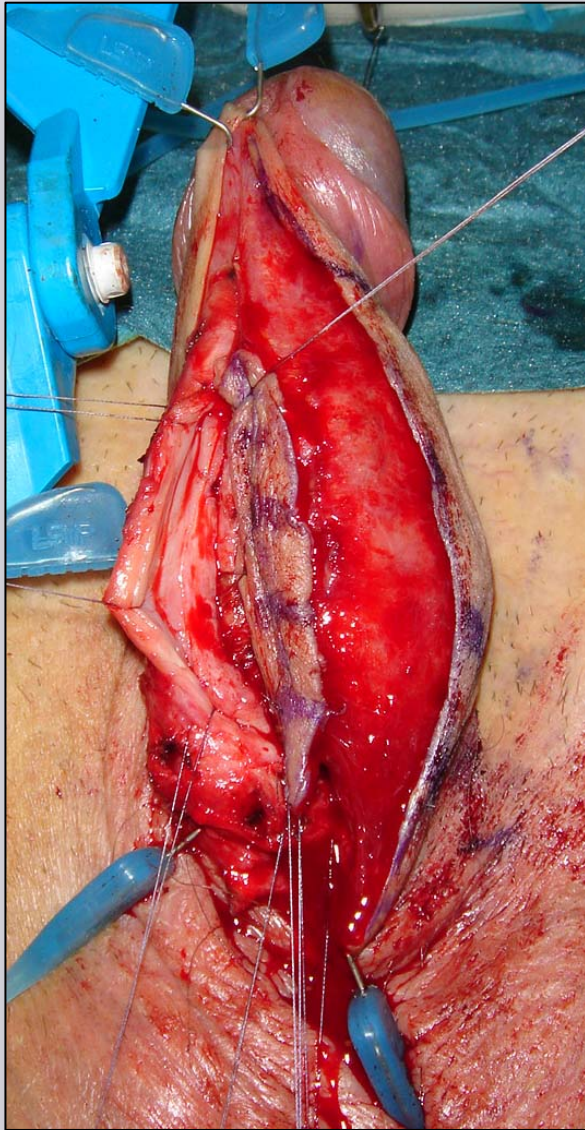
One-stage skin flap urethroplasty



e-mail: info@urethralcenter.it

Websites: www.uretra.it
www.urethralcenter.it

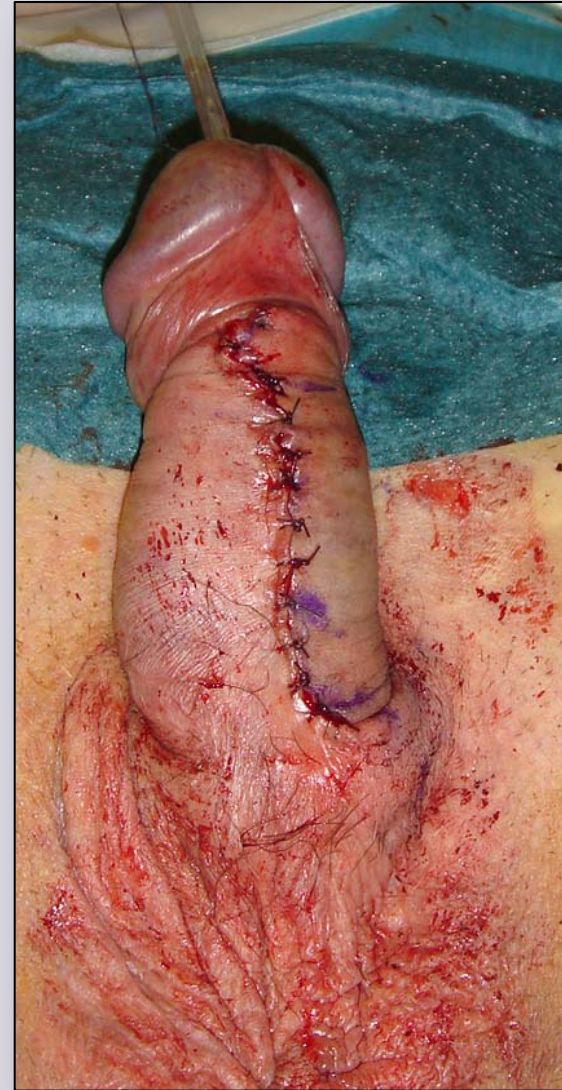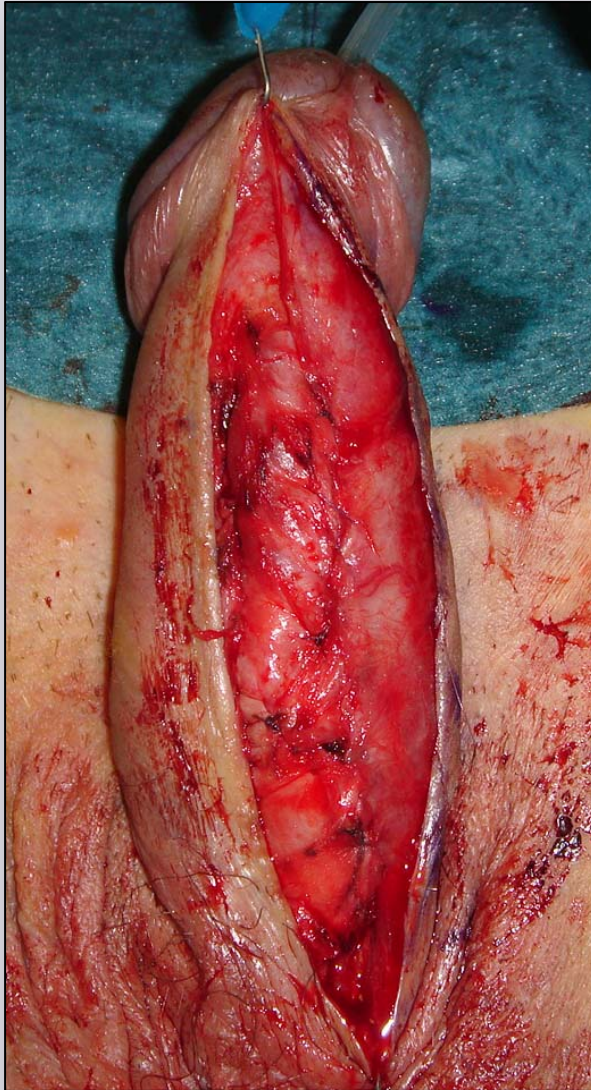
One-stage skin flap urethroplasty



e-mail: info@urethralcenter.it

Websites: www.uretra.it
www.urethralcenter.it

One-stage skin flap urethroplasty



e-mail: info@urethralcenter.it

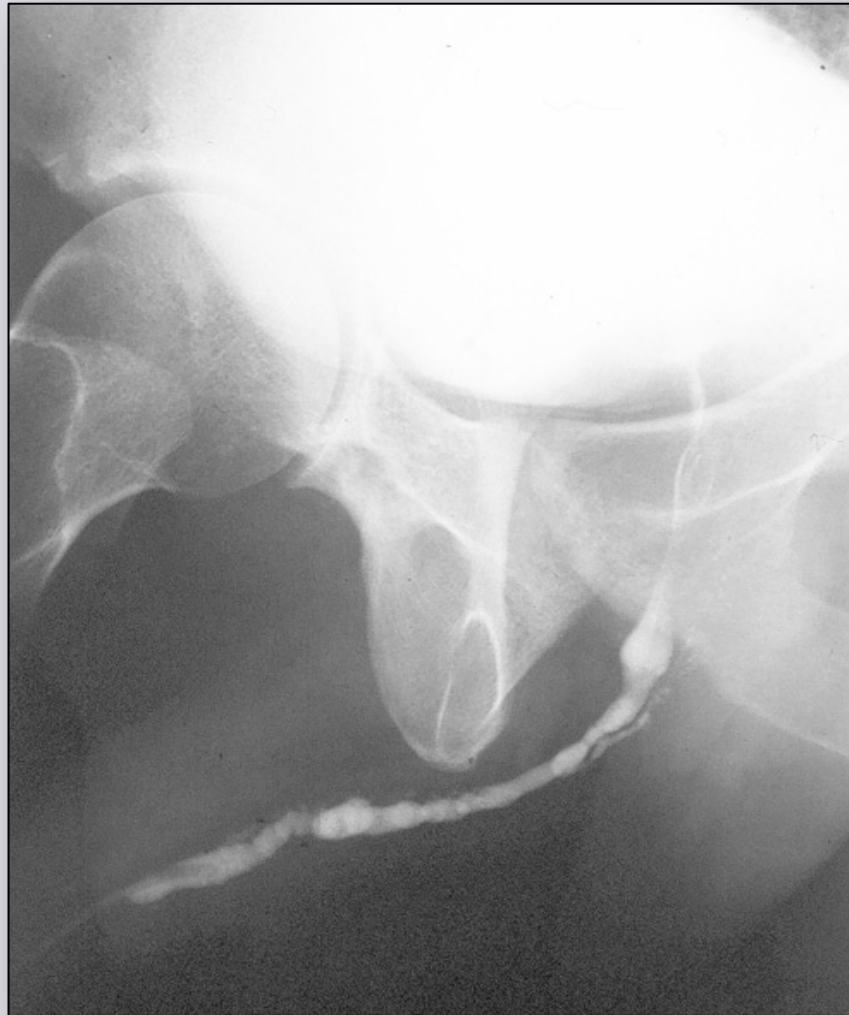Websites: www.uretra.it
www.urethralcenter.it

One-stage penile urethroplasty: graft or flap ?

- ❖ NO sure data available from literature
- ❖ NO comparative studies including evaluation of post-operative sexual and aesthetic dysfunctions and patient satisfaction
- ❖ Surgeon background and preference



One-stage urethroplasty - perineal approach



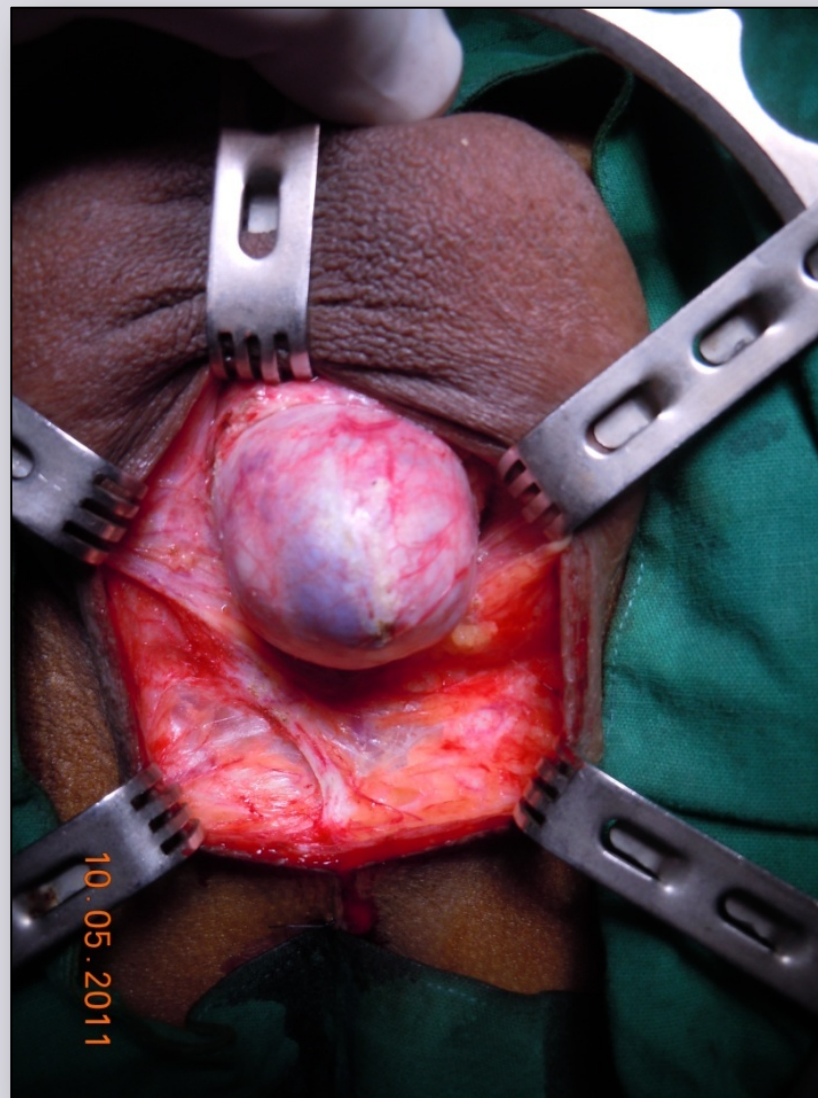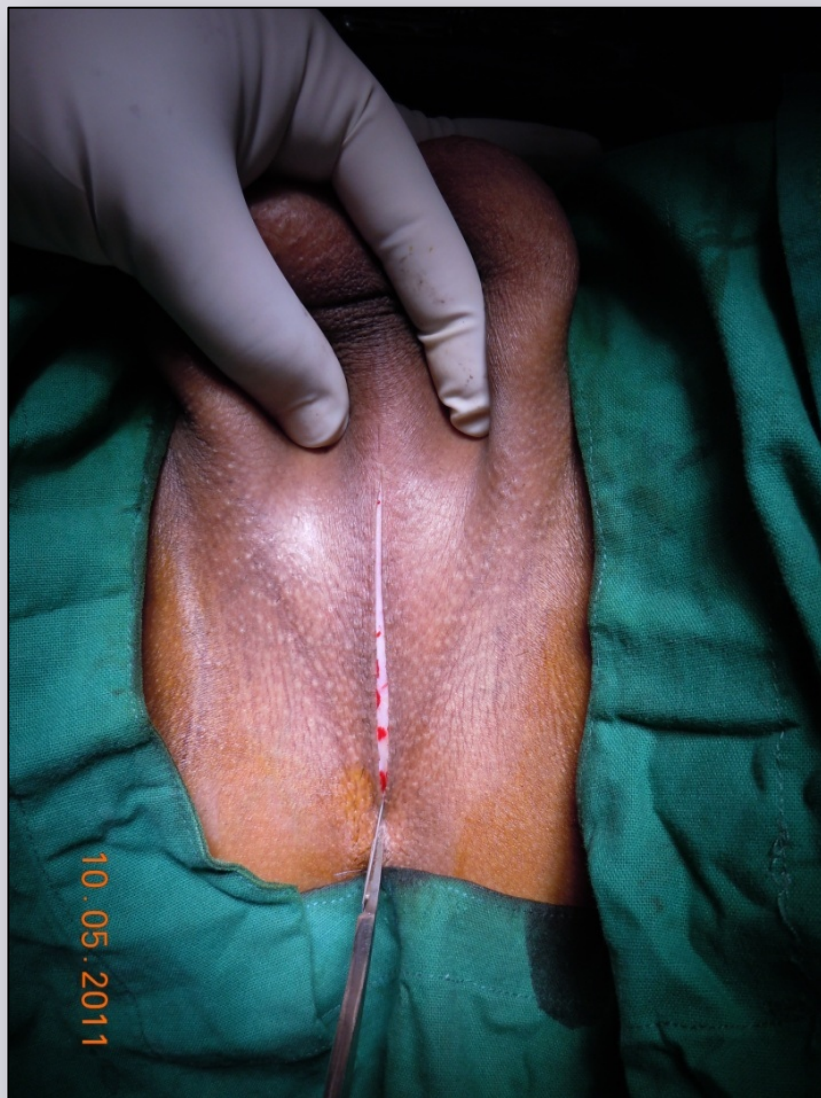Panurethral stricture

e-mail: info@urethralcenter.it

Websites: www.uretra.it
www.urethralcenter.it

CENTER FOR RECONSTRUCTIVE URETHRAL SURGERY

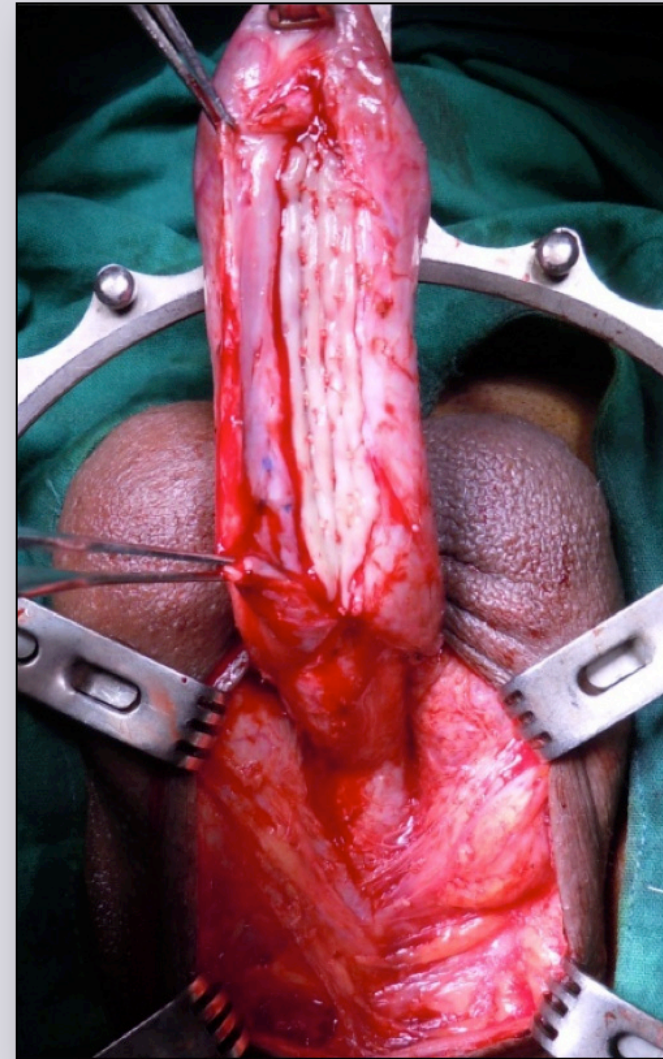
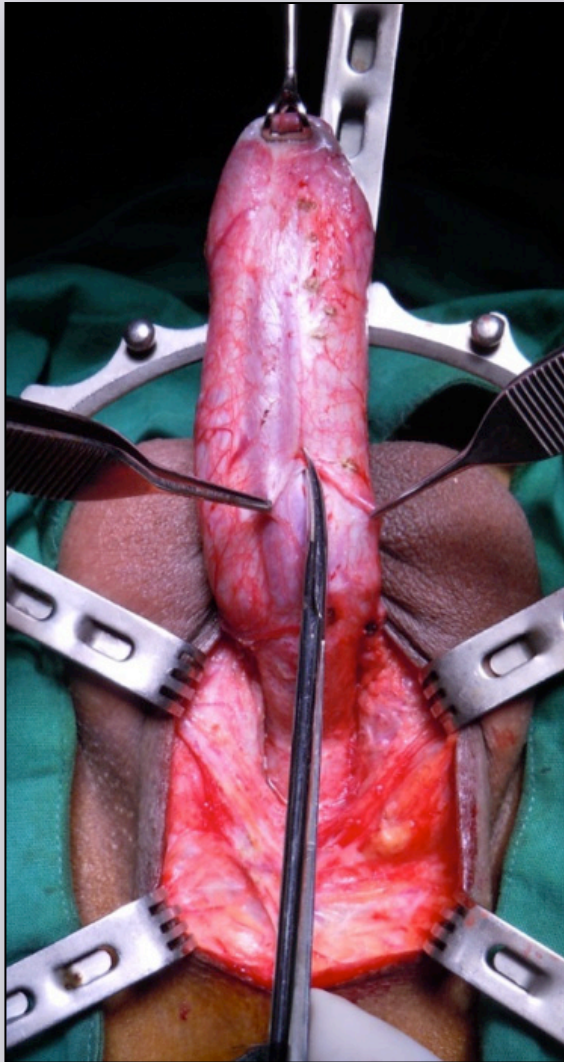
One-stage urethroplasty - perineal approach



e-mail: info@urethralcenter.it

Websites: www.uretra.it
www.urethralcenter.it

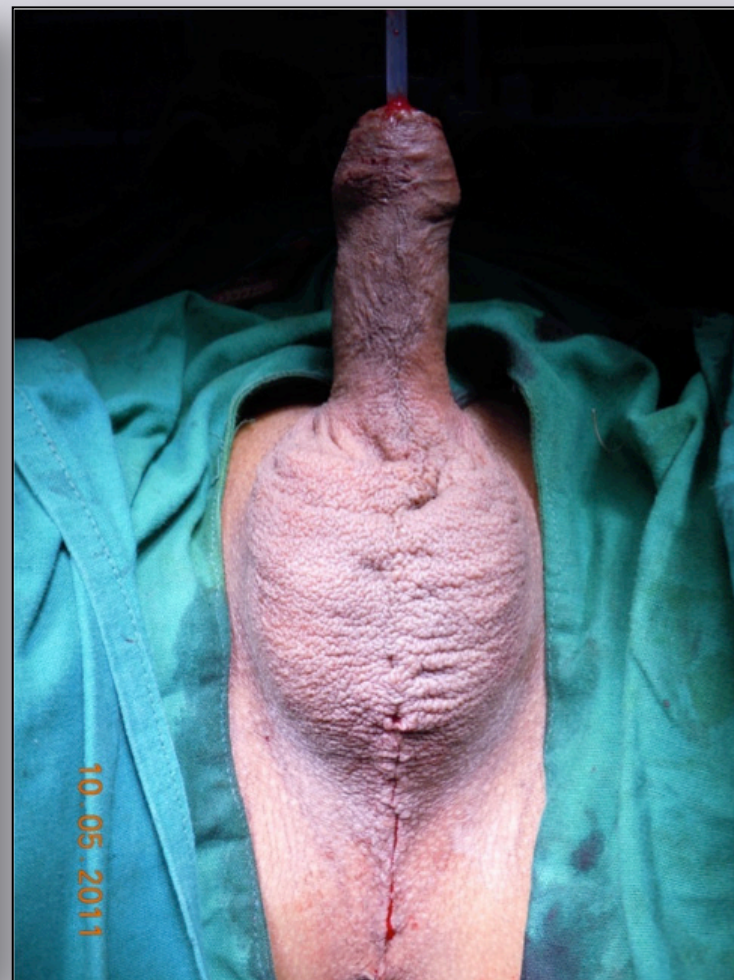
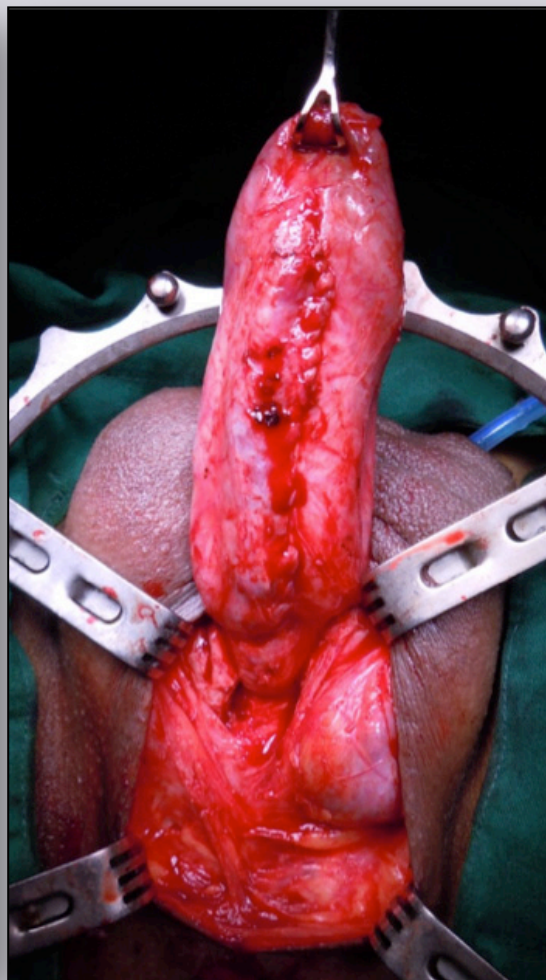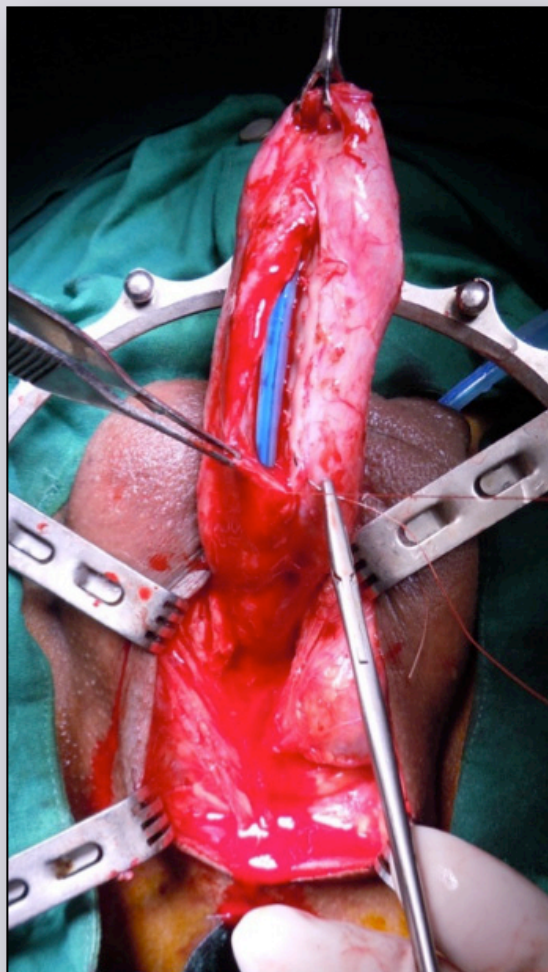
One-stage urethroplasty - perineal approach



e-mail: info@urethralcenter.it

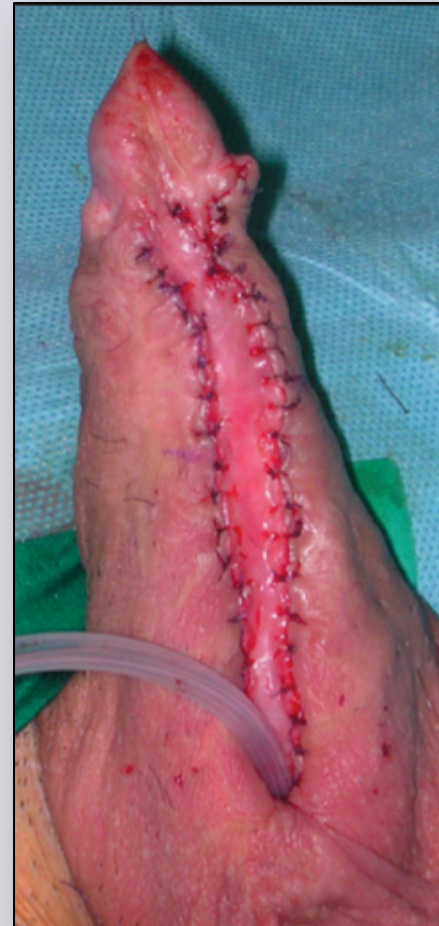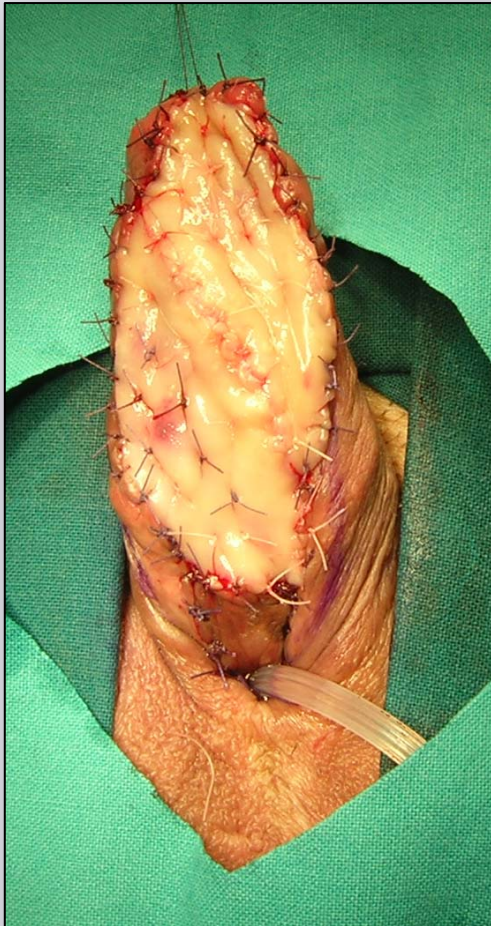
Websites: www.uretra.it
www.urethralcenter.it

One-stage urethroplasty - perineal approach

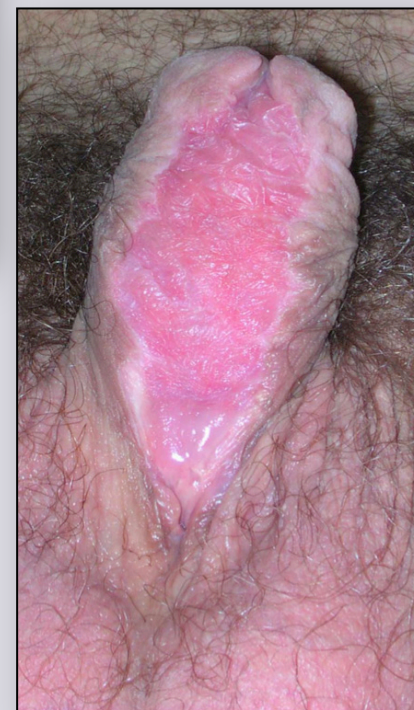
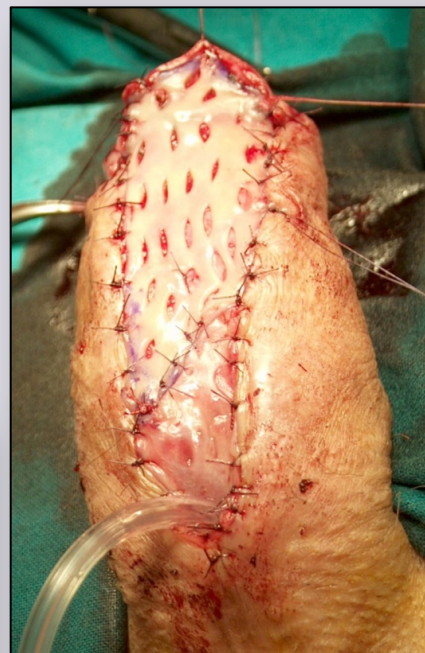
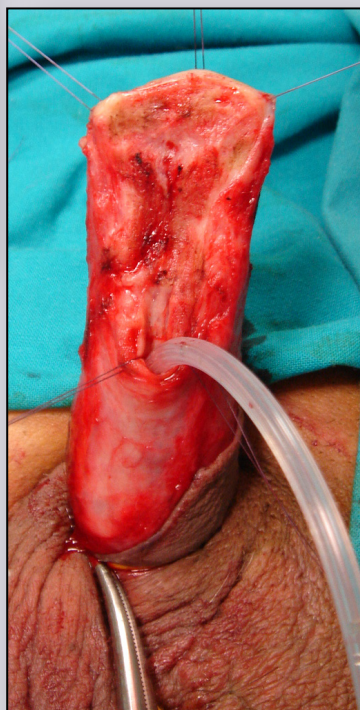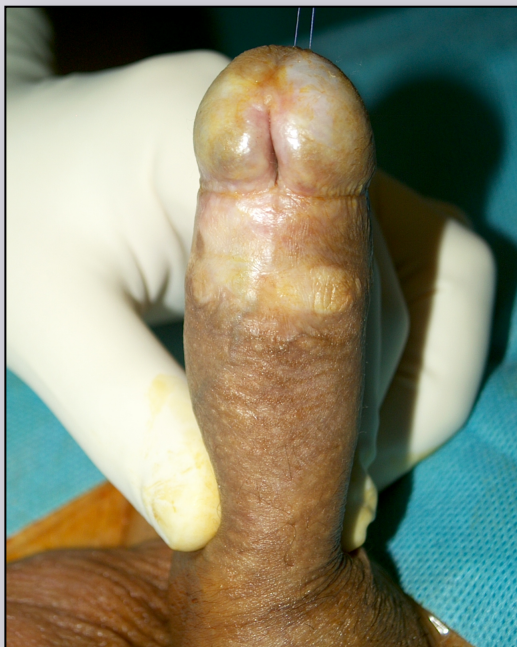Surgical repair of complex penile urethral stricture

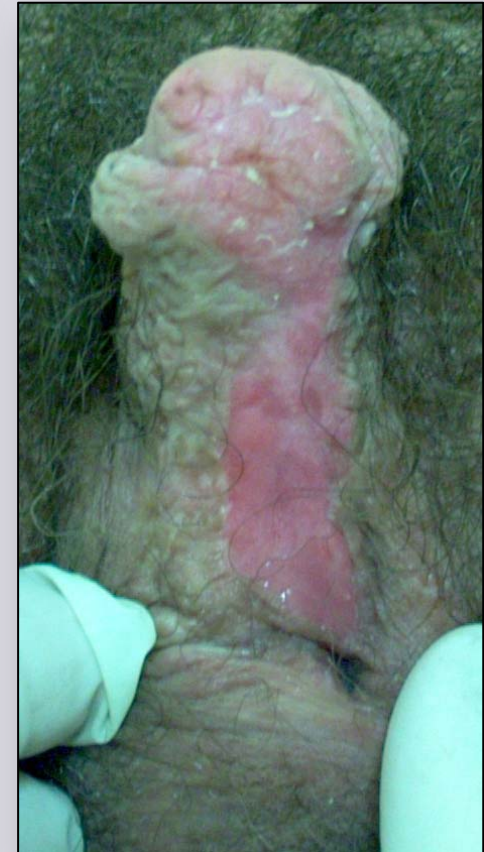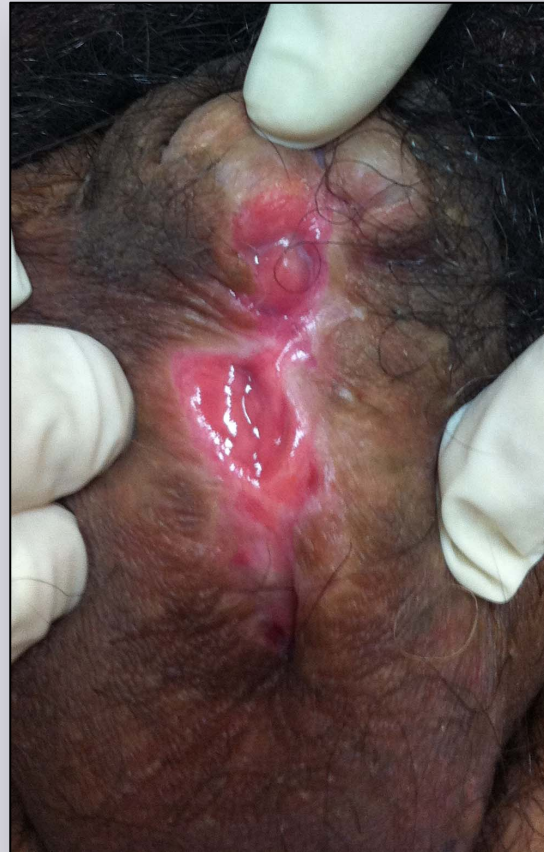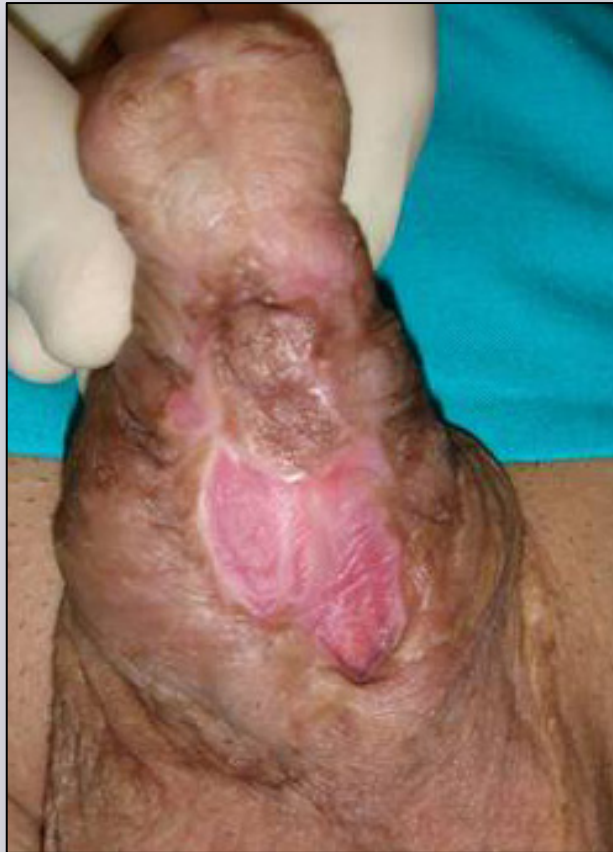Two-stage repair



First-stage - oral mucosa



**39% of our patients required new surgical revision
of the grafted area**

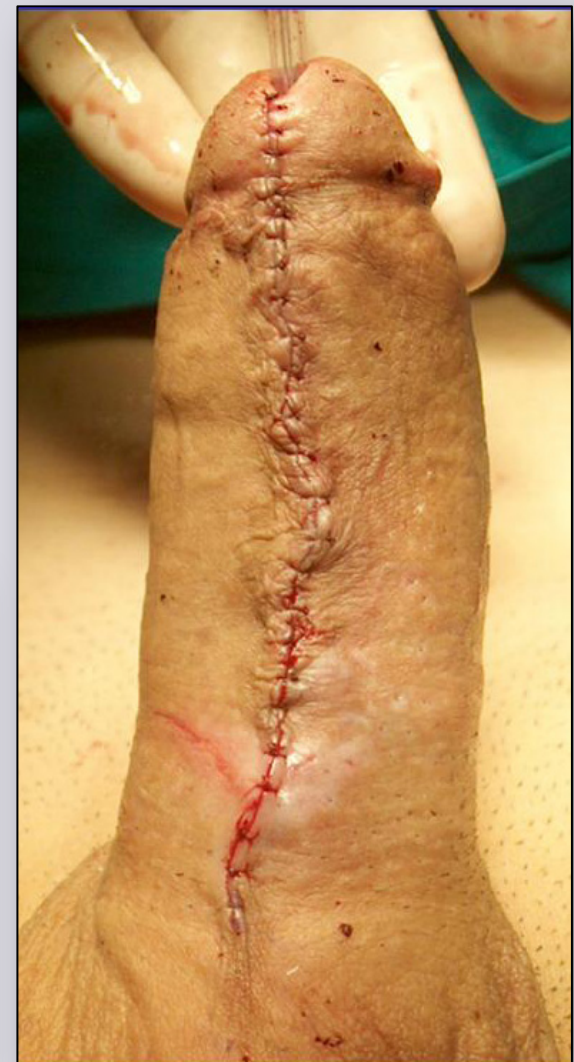
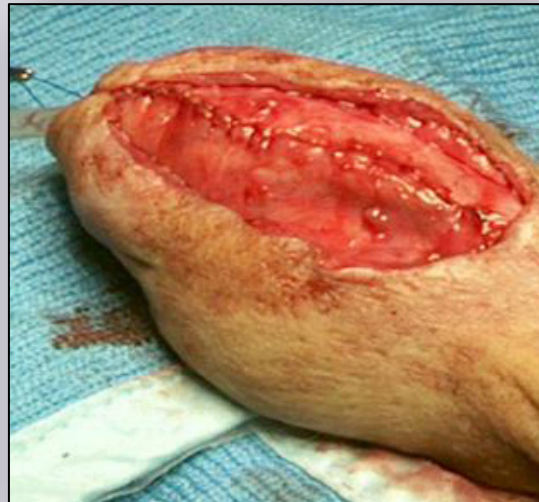
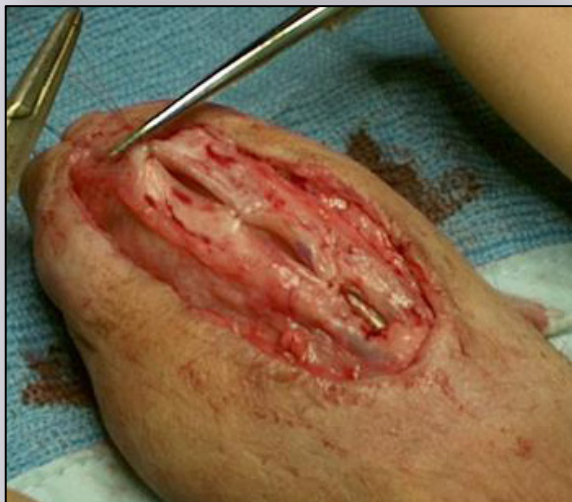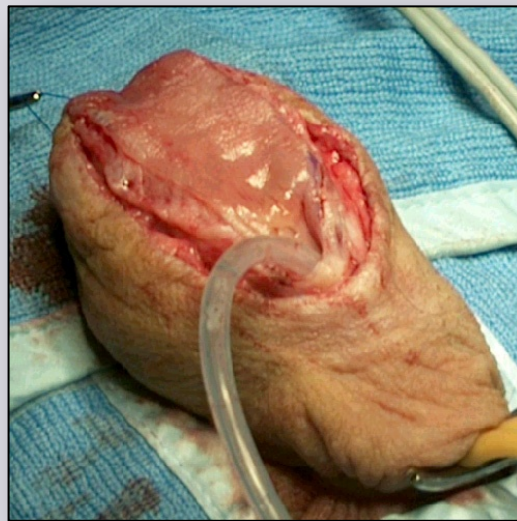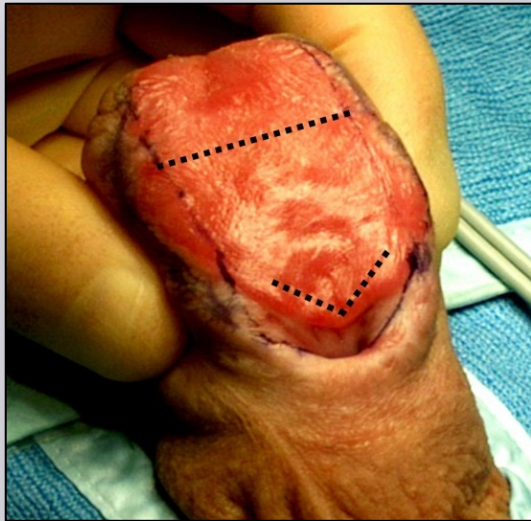Eur Urol 2006; 49: 887-895

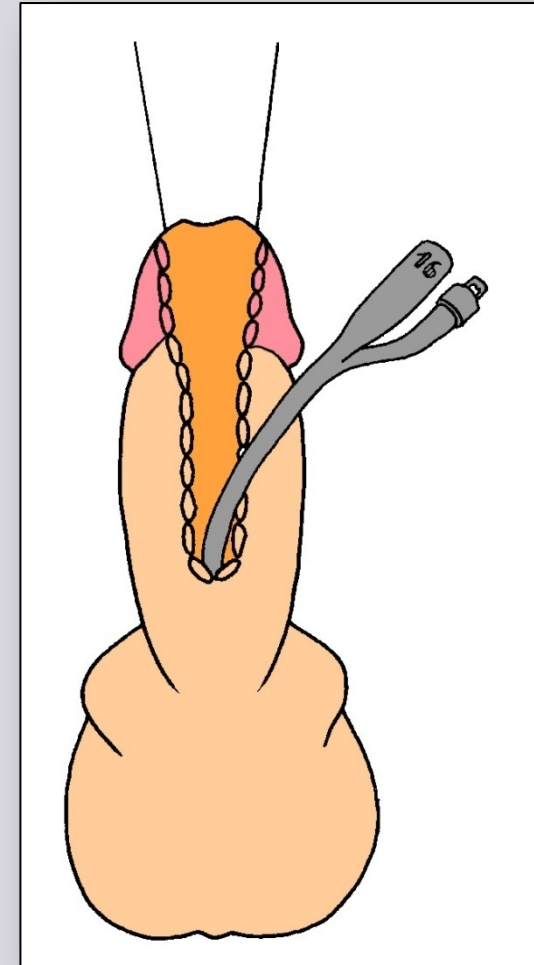
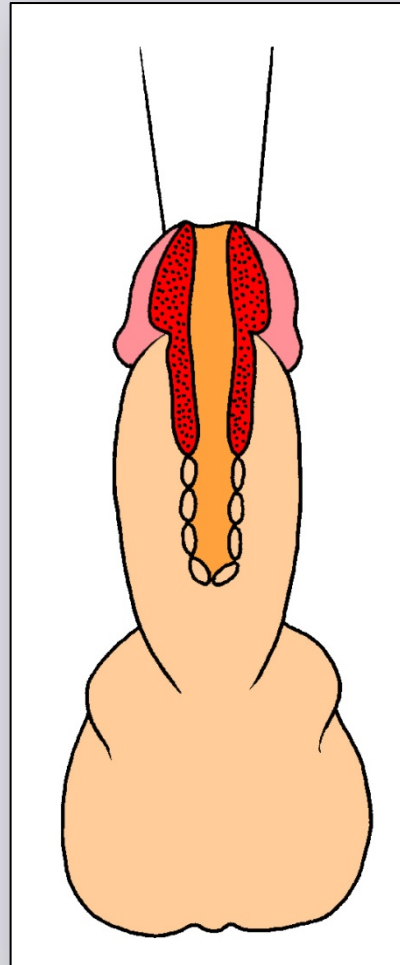
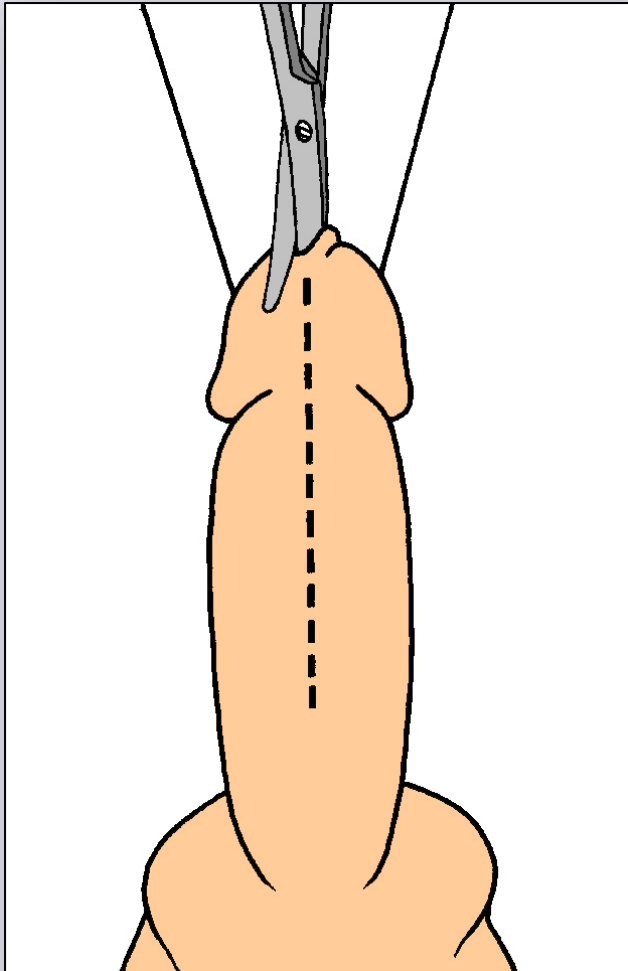
e-mail: info@urethralcenter.it

Websites: www.uretra.it
www.urethralcenter.it

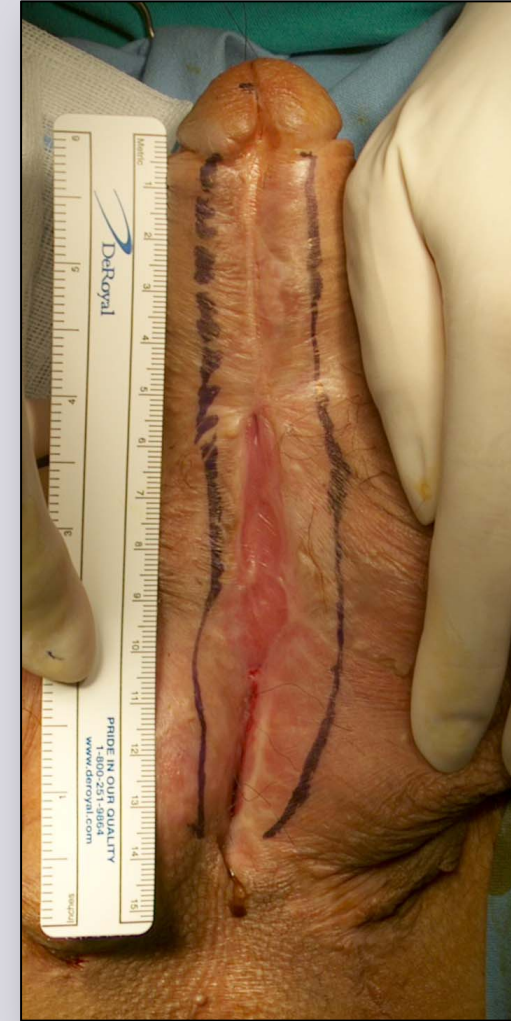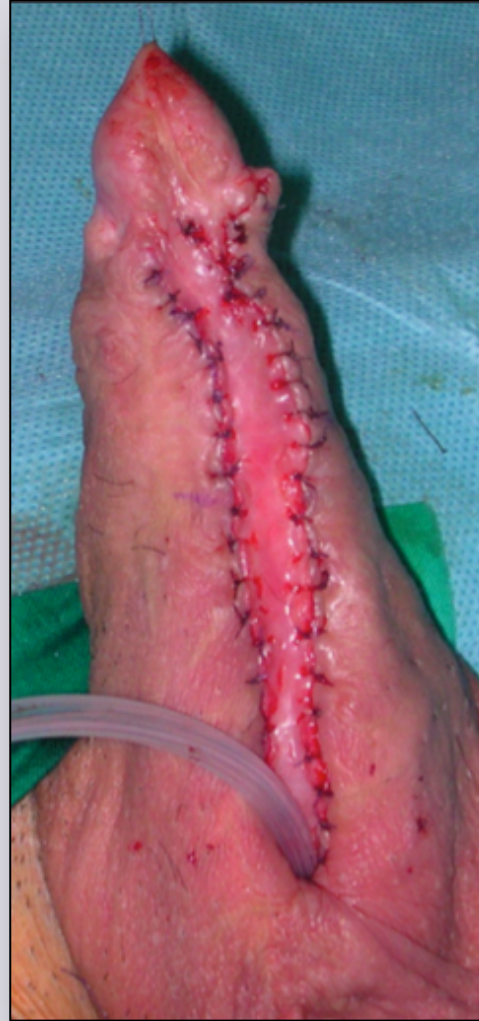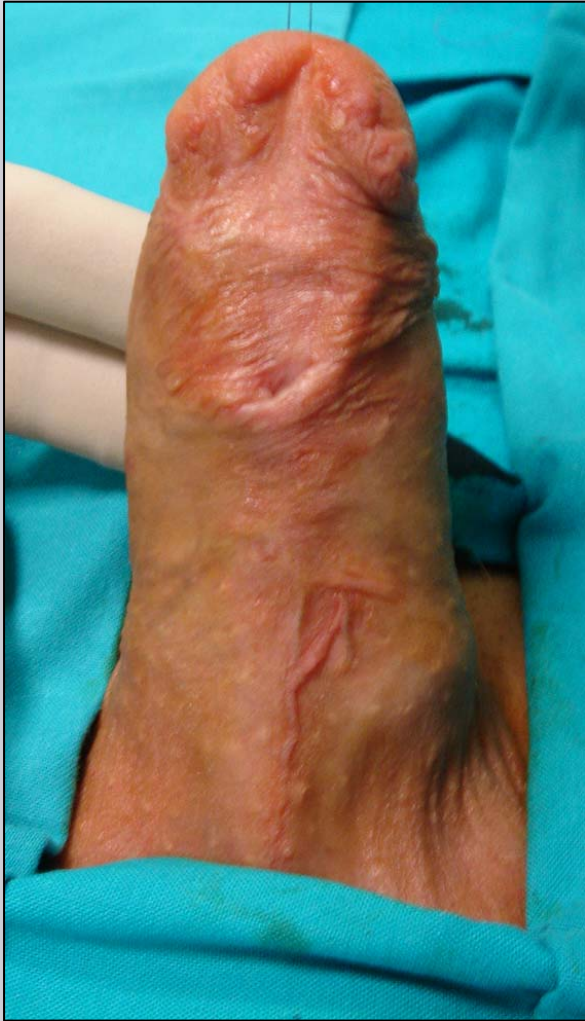Second stage - primary closure



First stage – Johanson



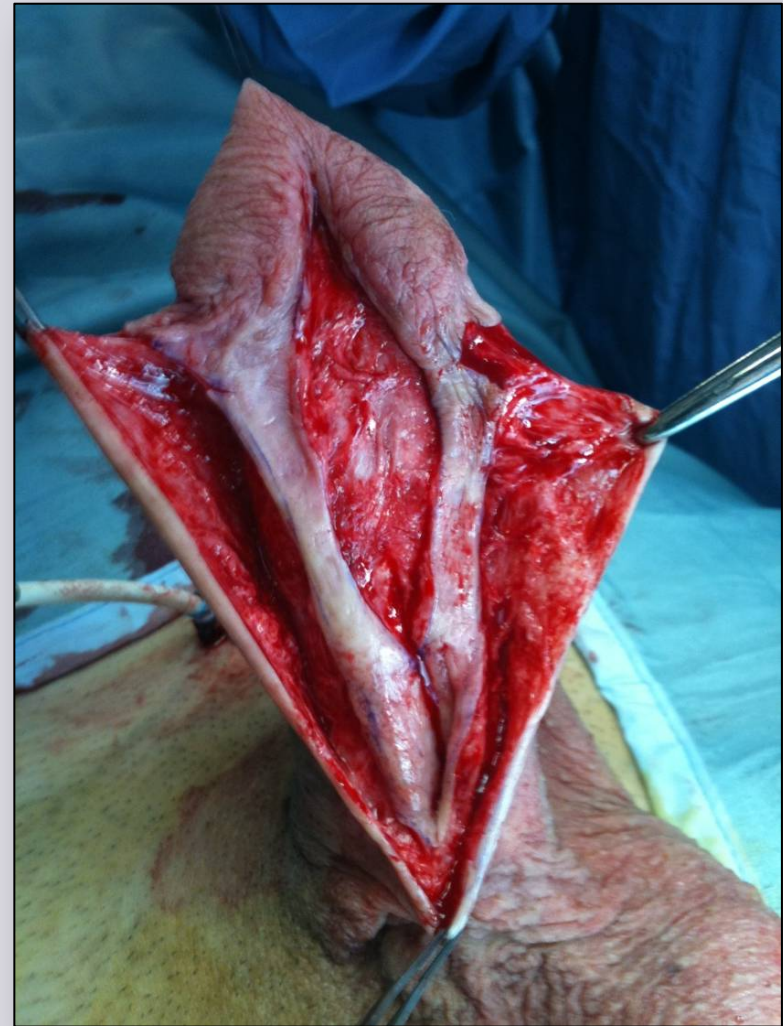
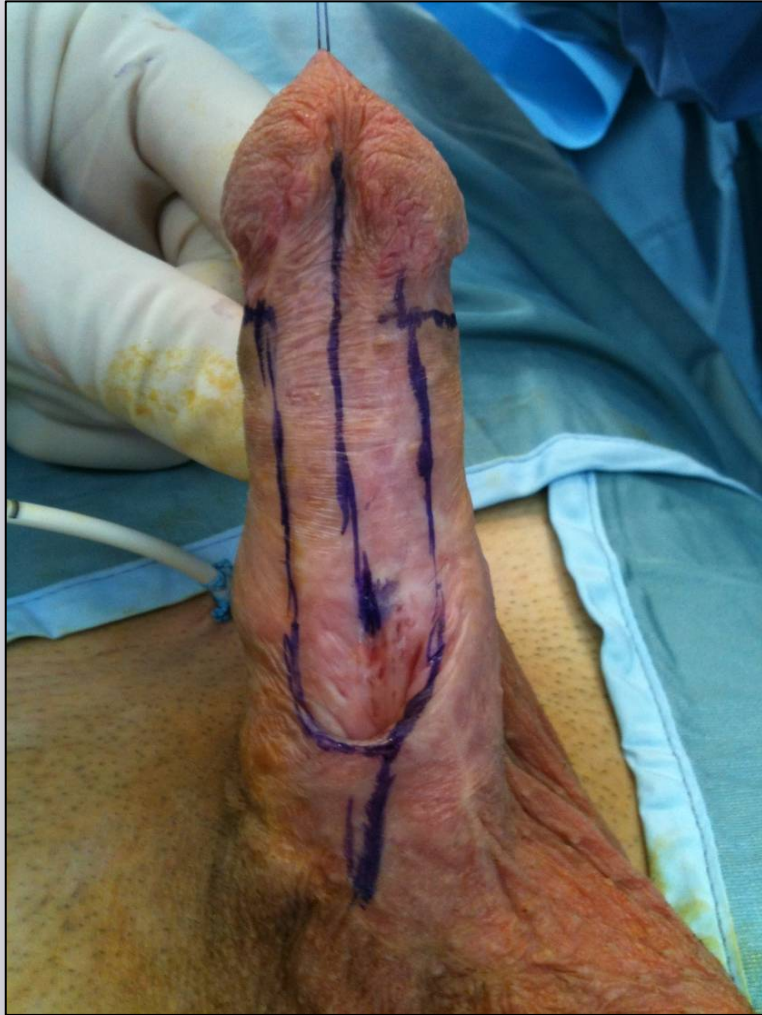First stage – Johanson



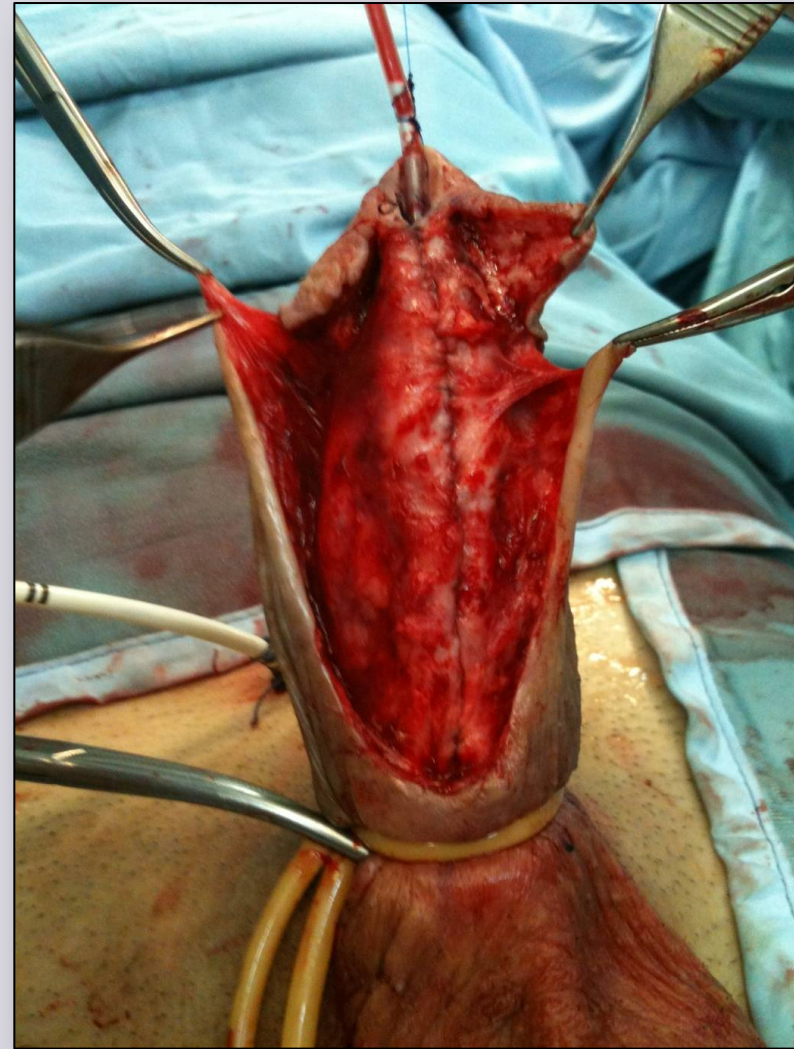
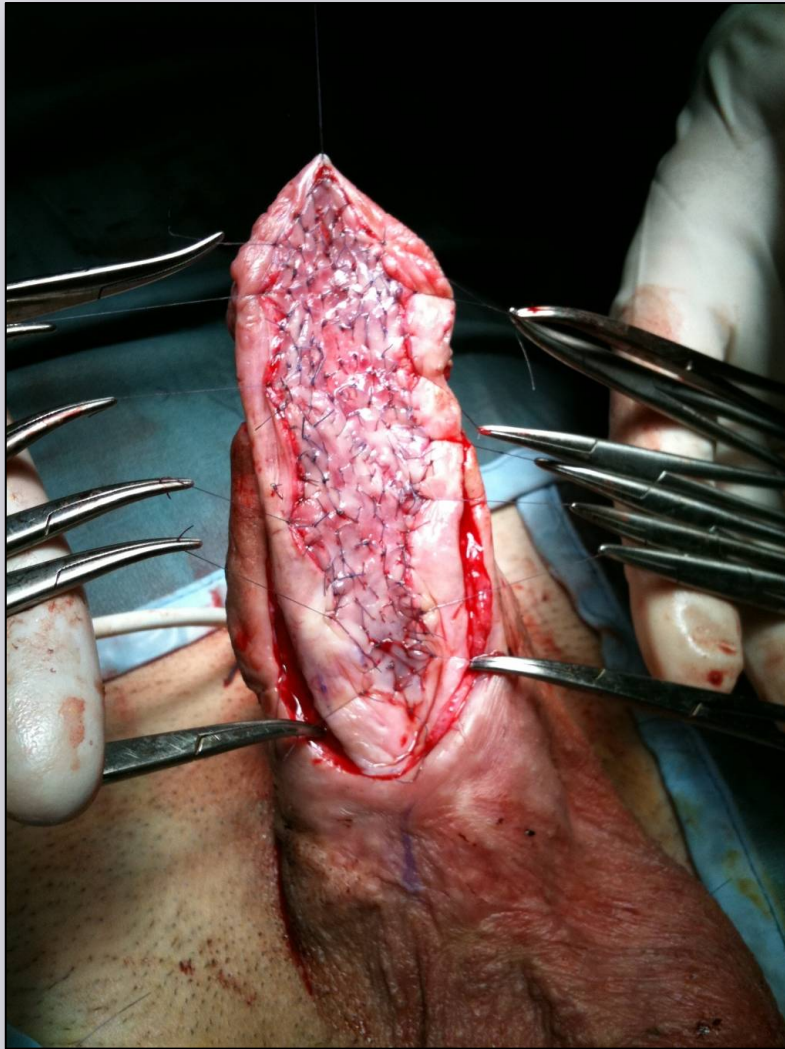
e-mail: info@urethralcenter.it

Websites: www.uretra.it
www.urethralcenter.it

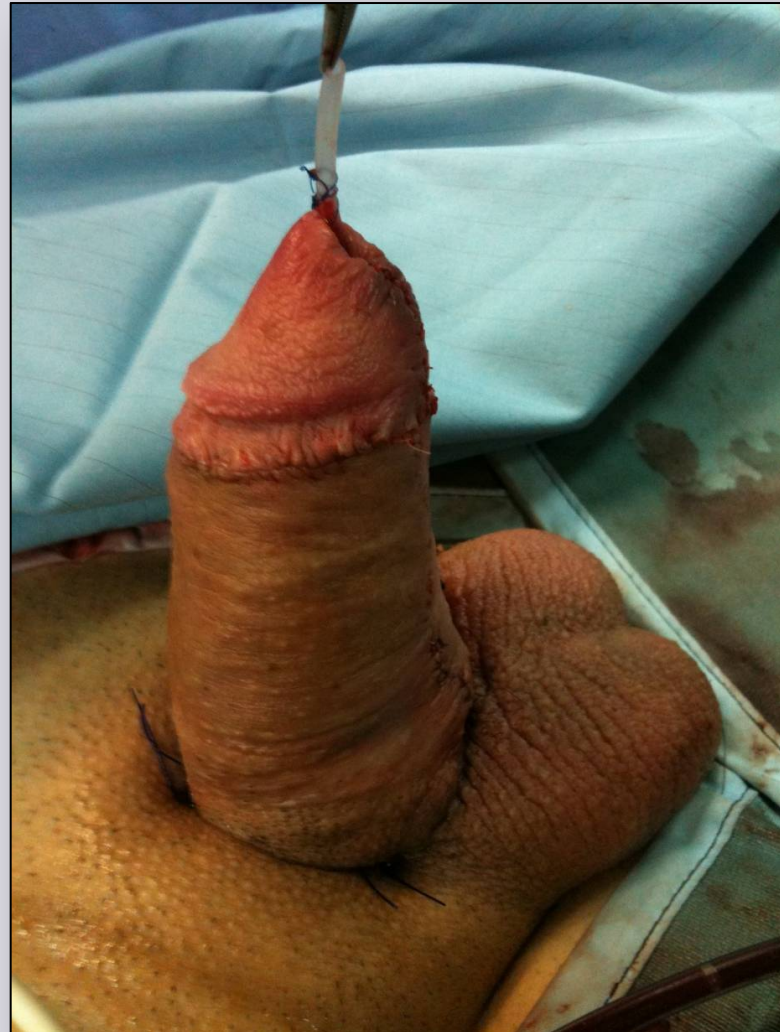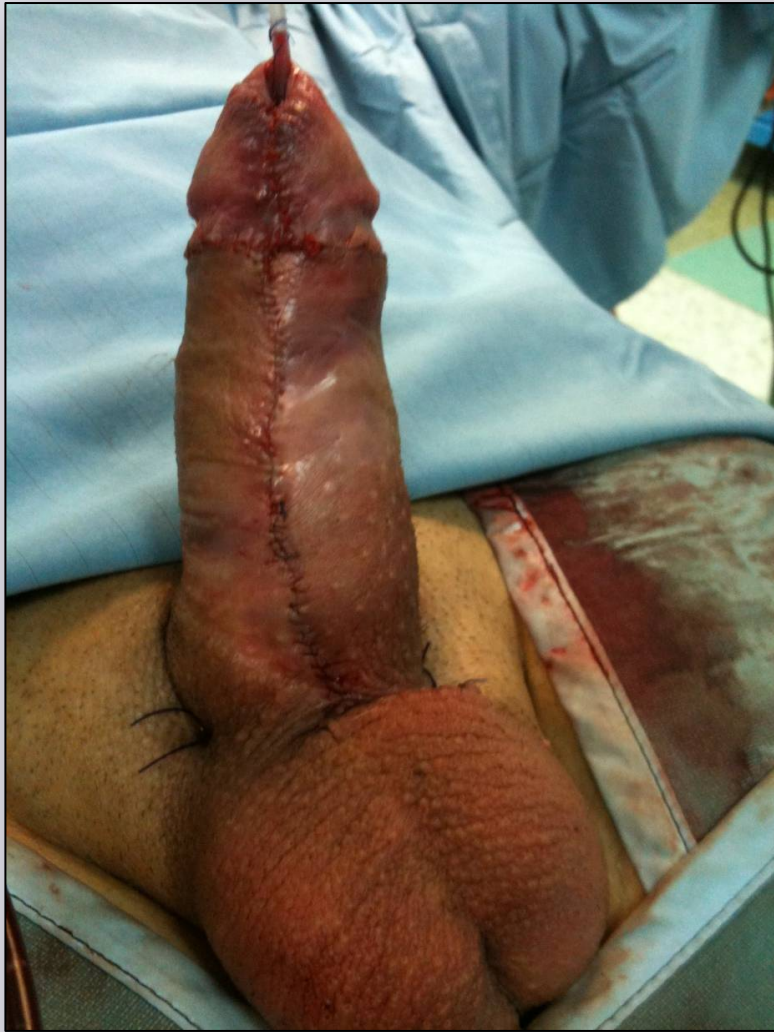Second stage - oral graft inlay

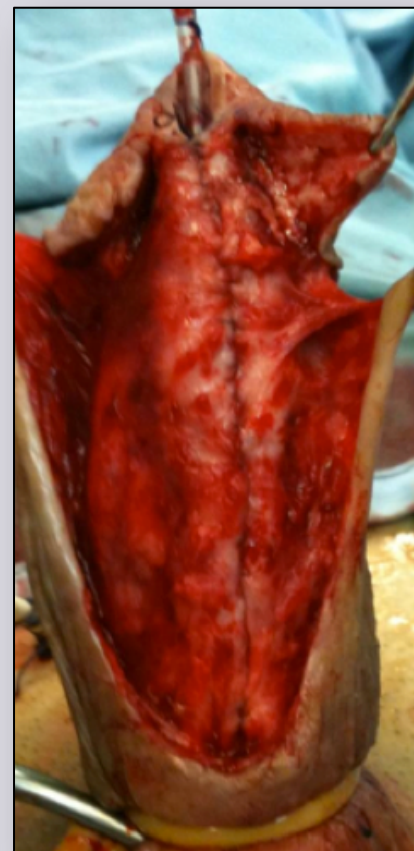
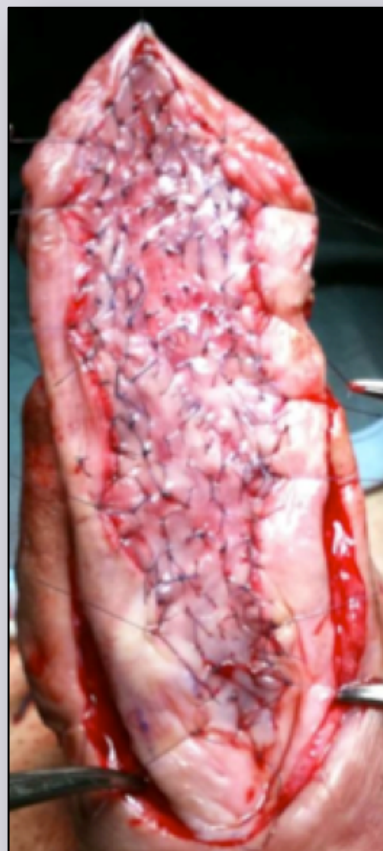
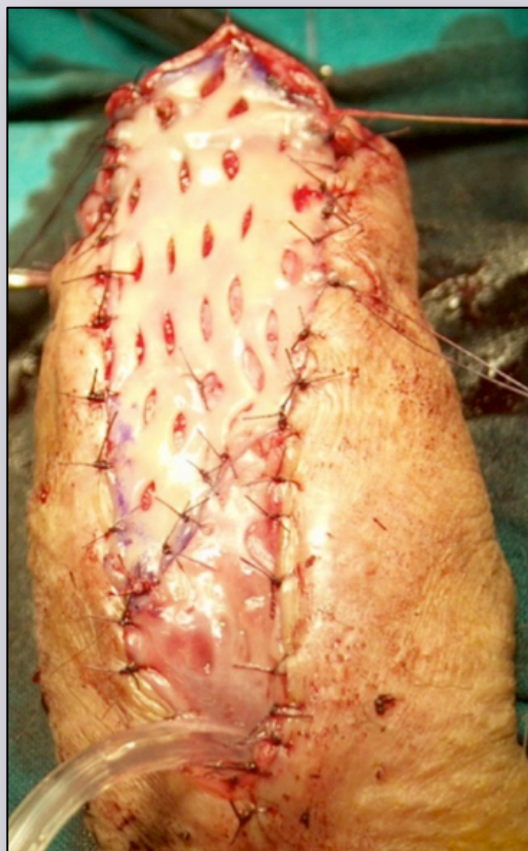Second stage - oral graft inlay



Second stage - oral graft inlay

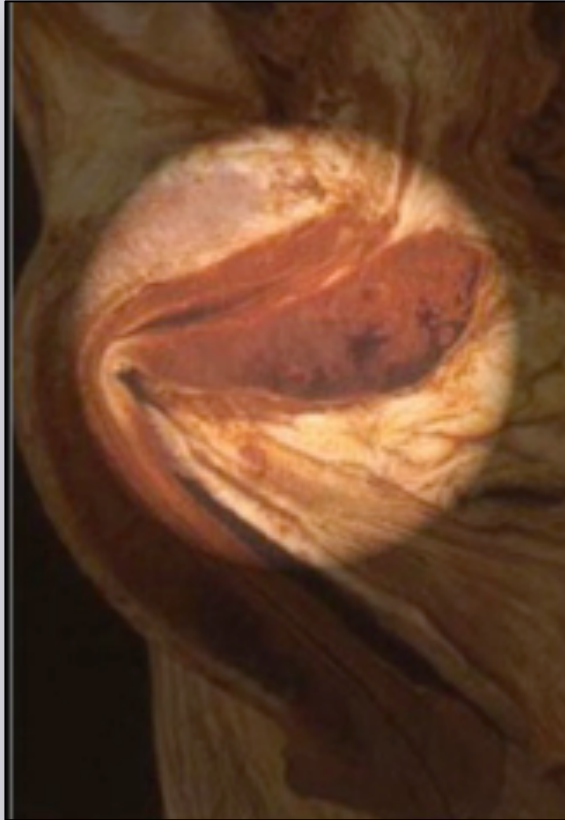




e-mail: info@urethralcenter.it

Websites: www.uretra.it
www.urethralcenter.it

New classification of anterior urethral strictures

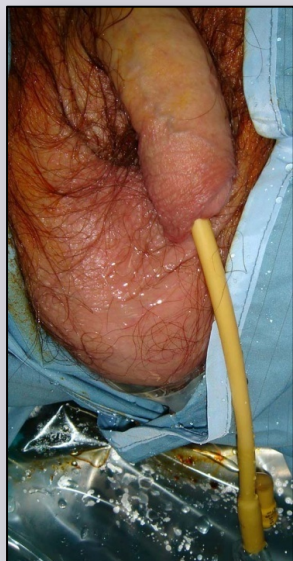

Bulbar

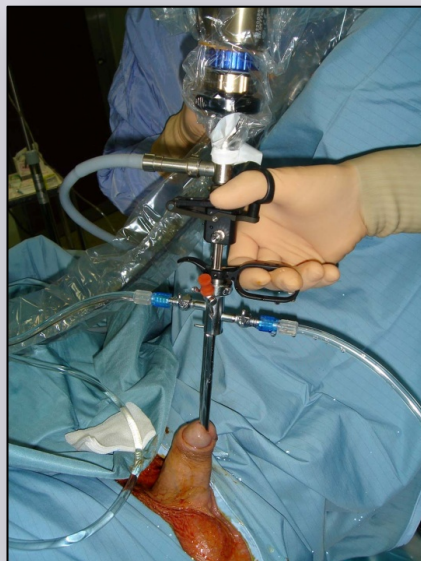Traumatic

Non-traumatic

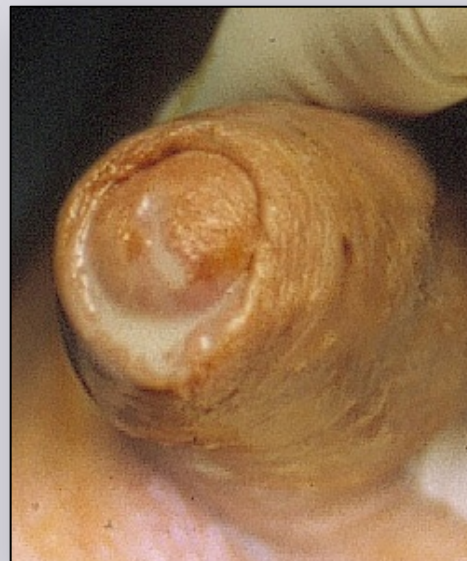Etiology of bulbar urethral stricture



Catheter



Instrumentation



Infection

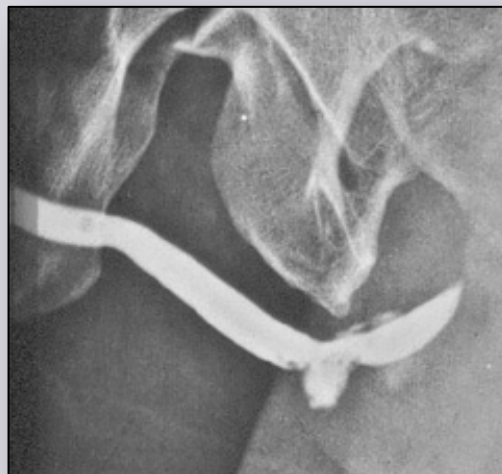
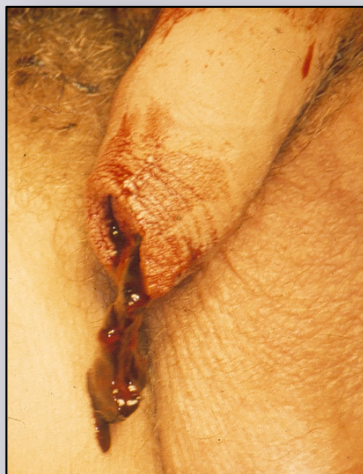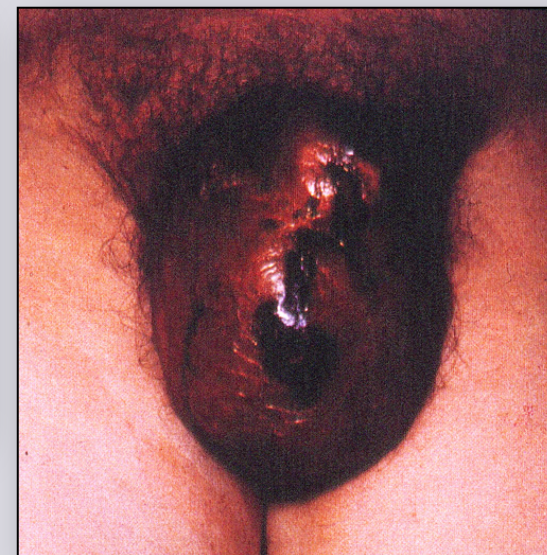
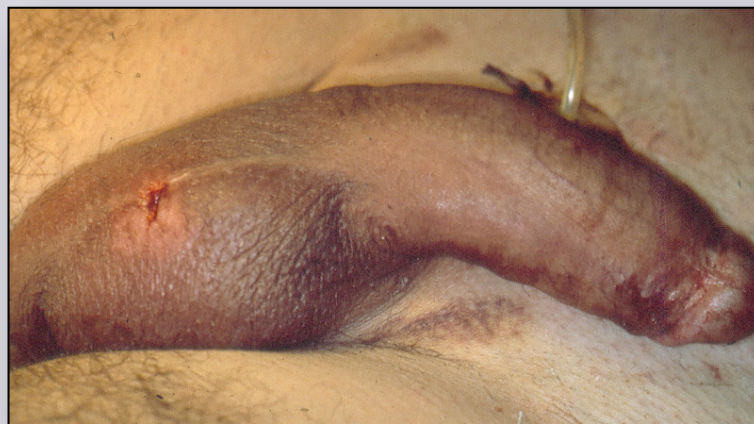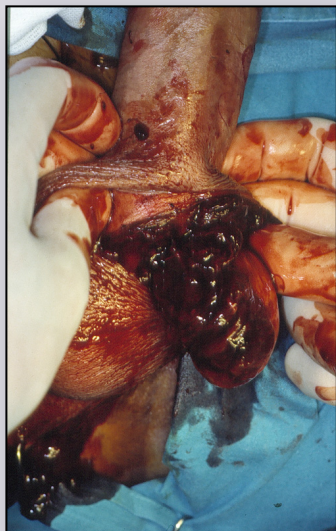


Trauma

Idiopathic
Radiotherapy
Other

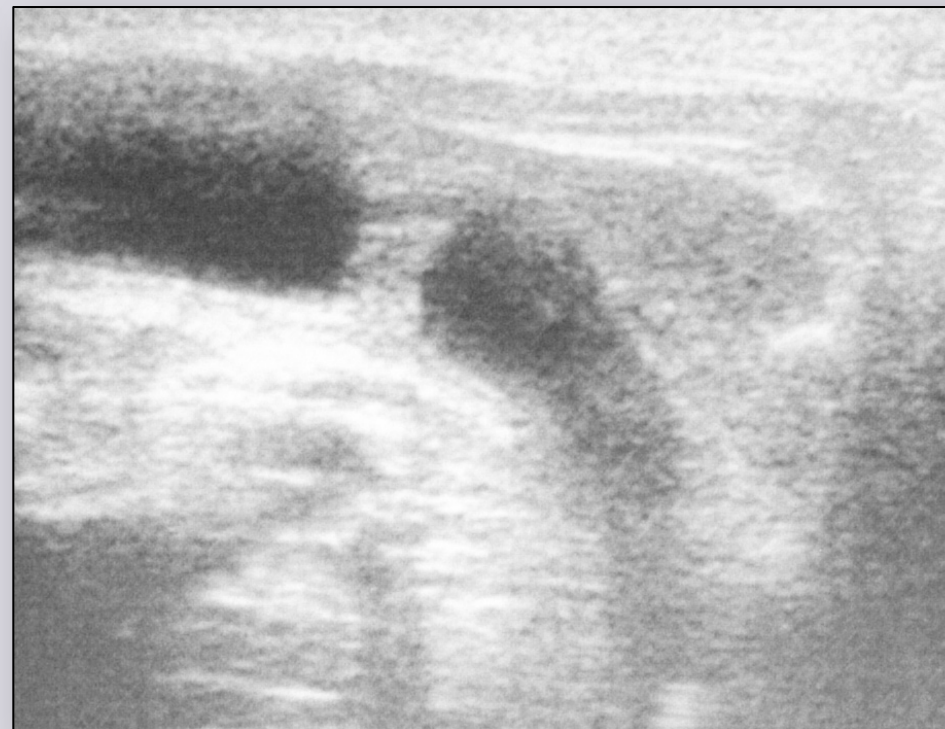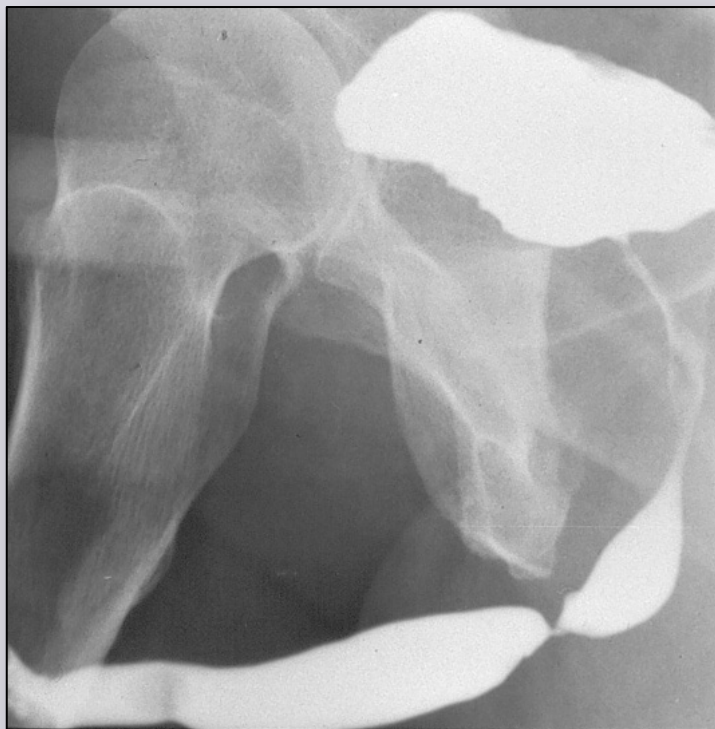Traumatic bulbar urethral stricture

Open or blunt perineal trauma



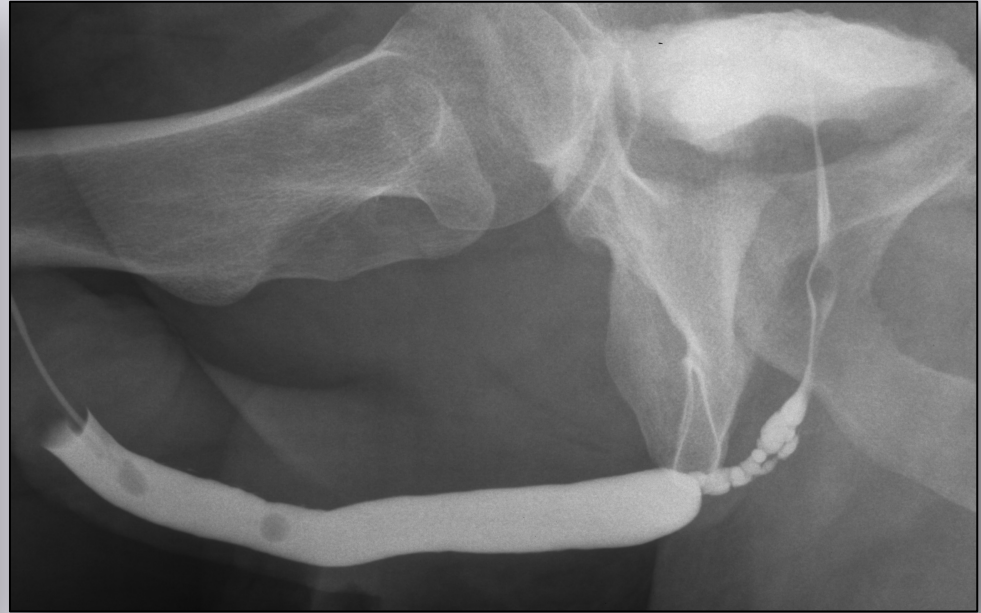
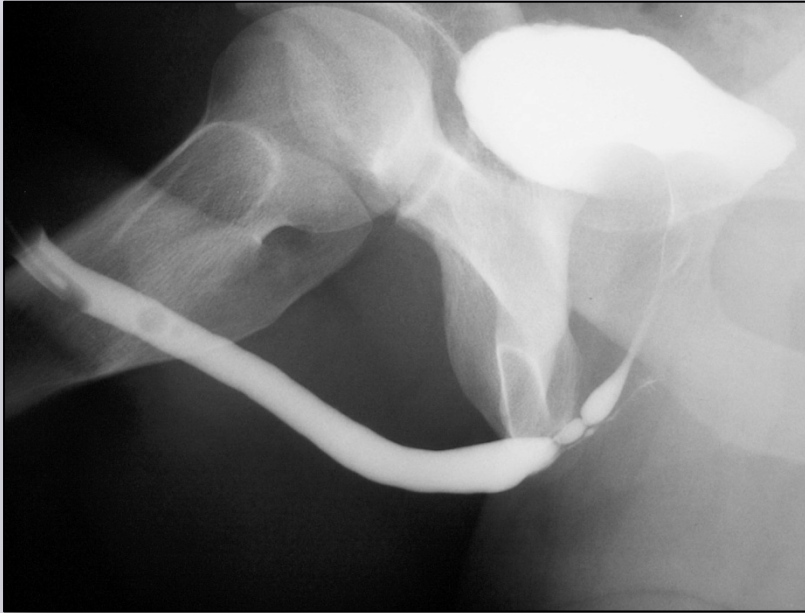
Urethral lesion requiring
emergency treatment

Traumatic bulbar urethral stricture

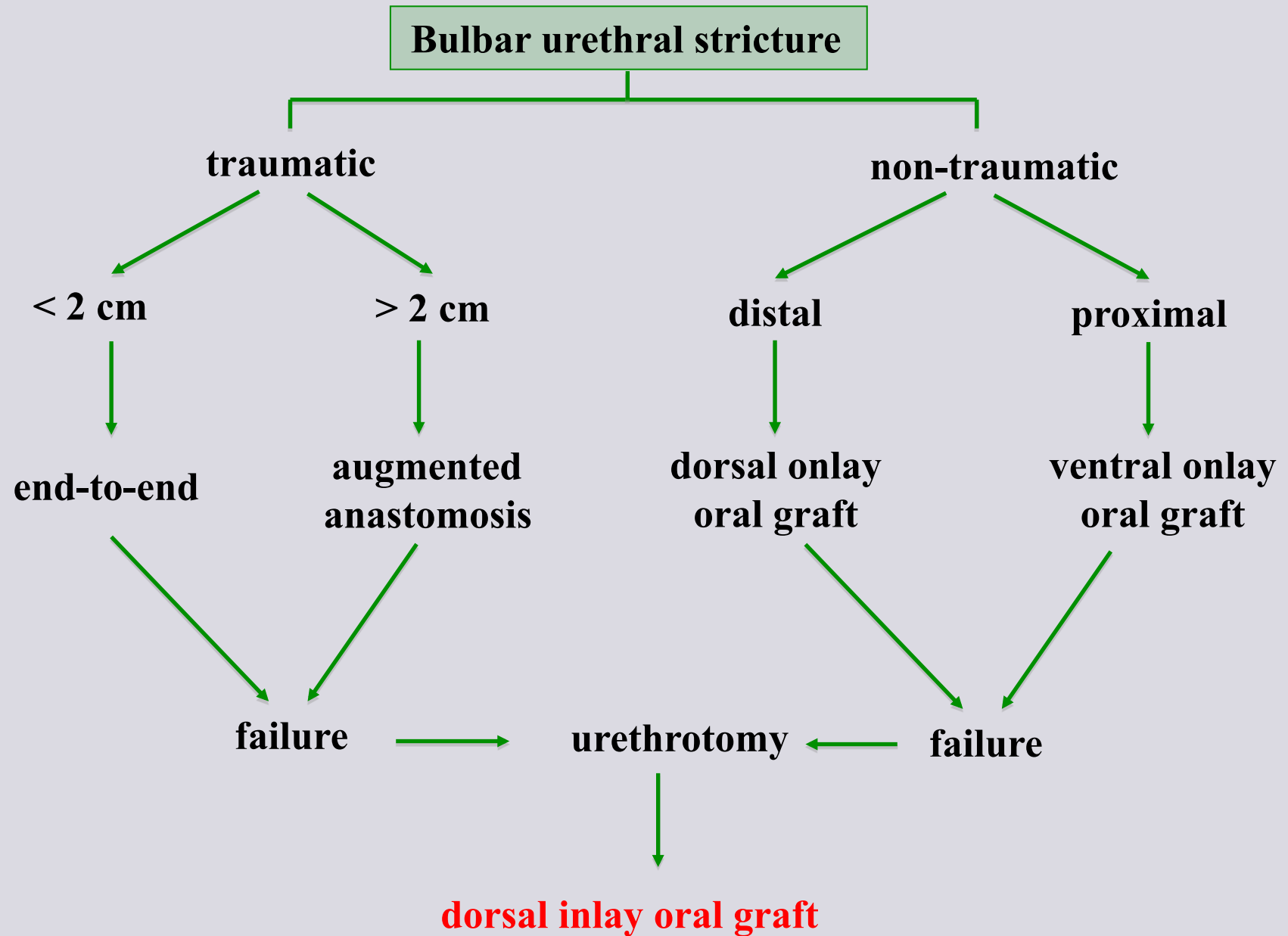


1. Obliterative stricture
2. No practicable urethral plate
3. Scar tissue
4. Short or long fibrous gap

Non-traumatic bulbar urethral stricture



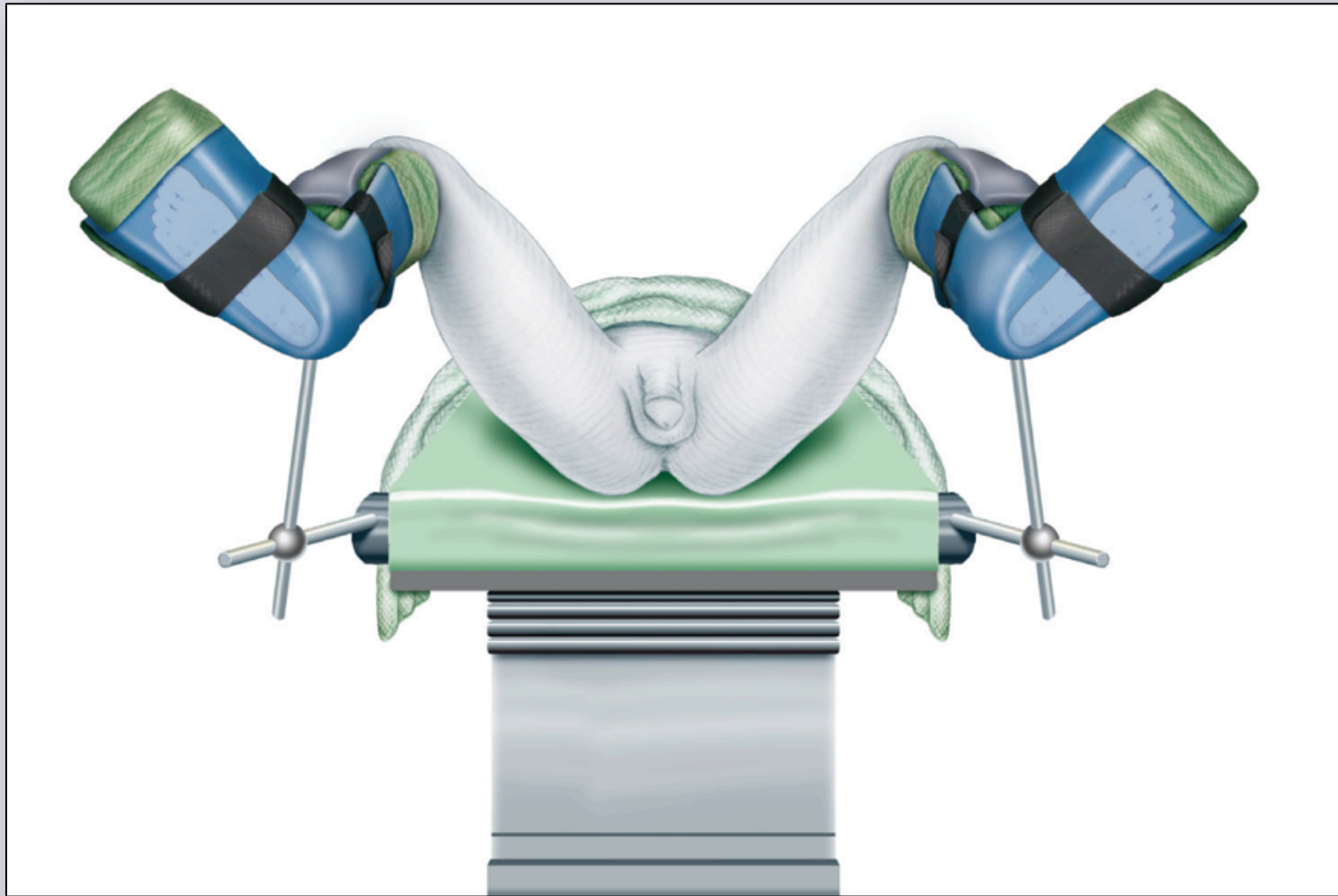
1. Etiology: idiopathic – catheter - instrumentation –infection – other
2. Practicable urethral plate (3 Fr. Sensor guidewire)
3. No fibrous gap



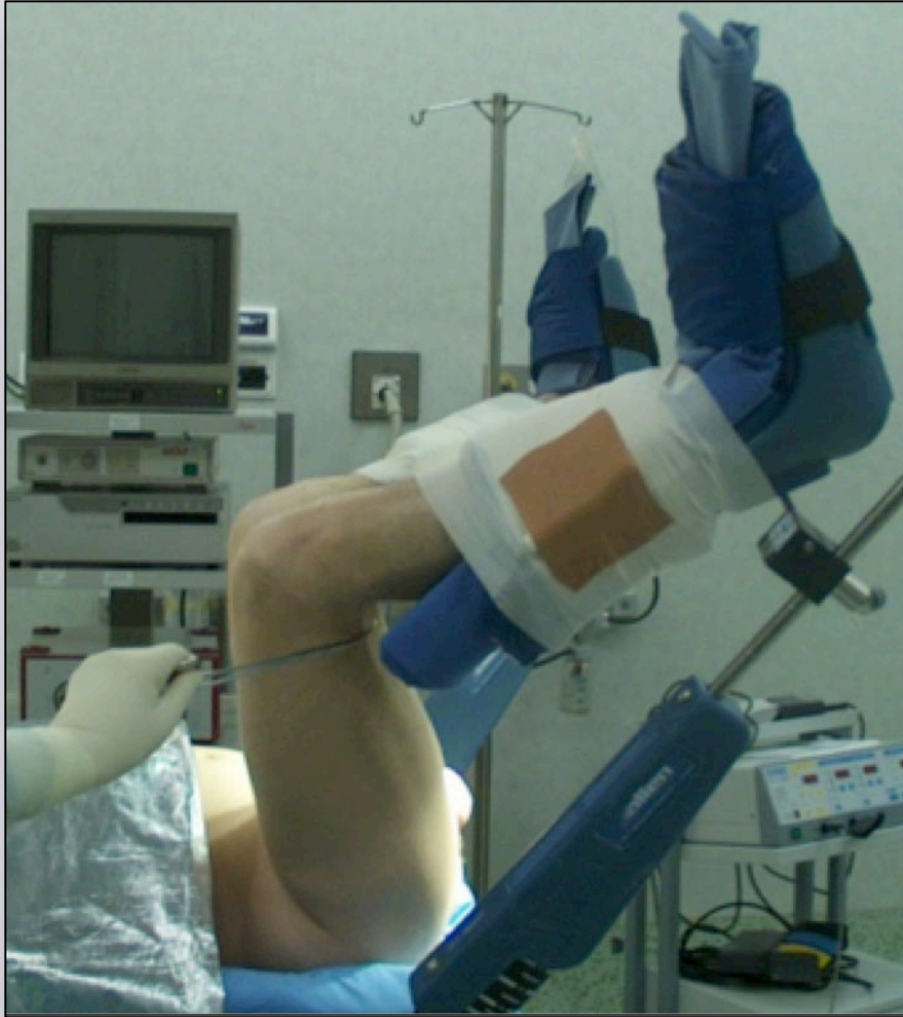Reconstruction of the bulbar urethra in traumatic stricture

e-mail: info@urethralcenter.it

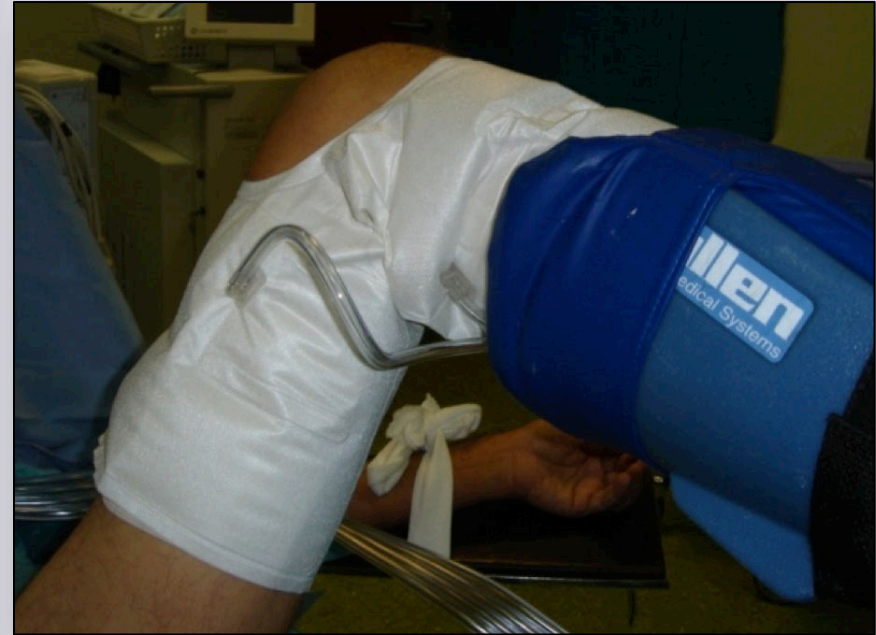Websites: www.uretra.it
www.urethralcenter.it



Simple lithotomy position

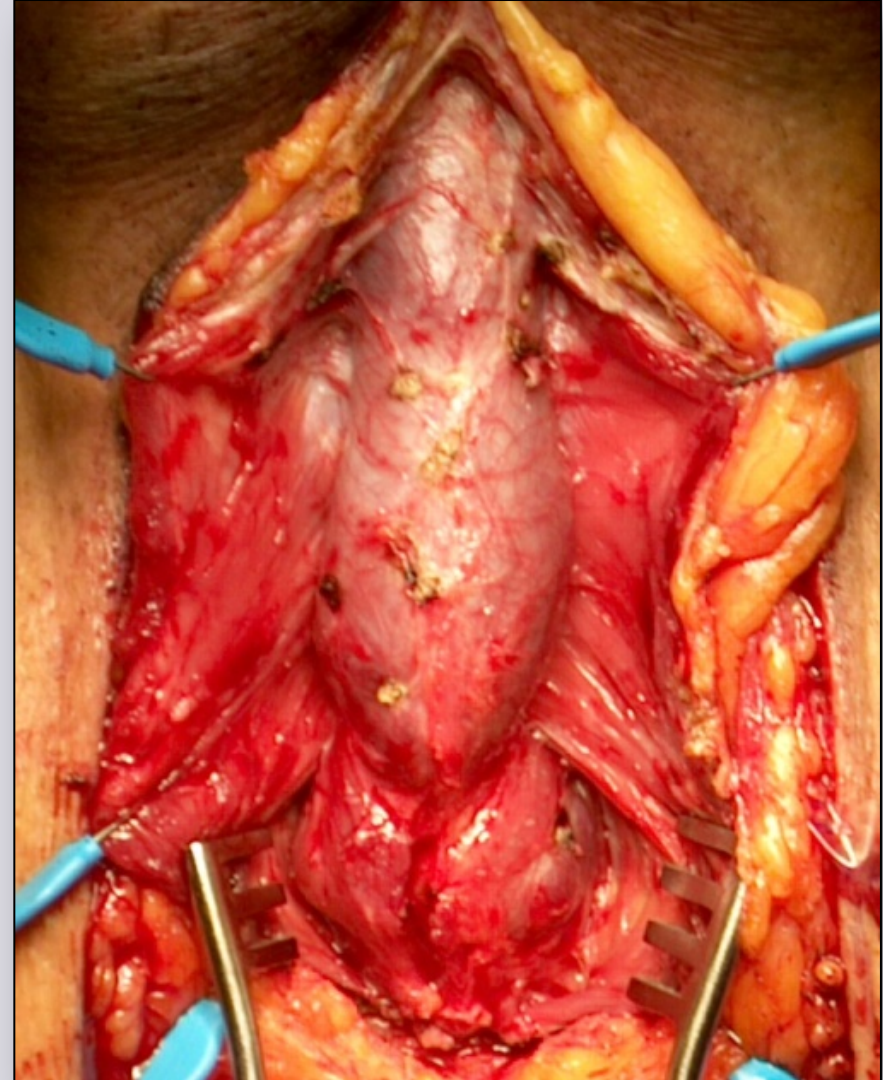
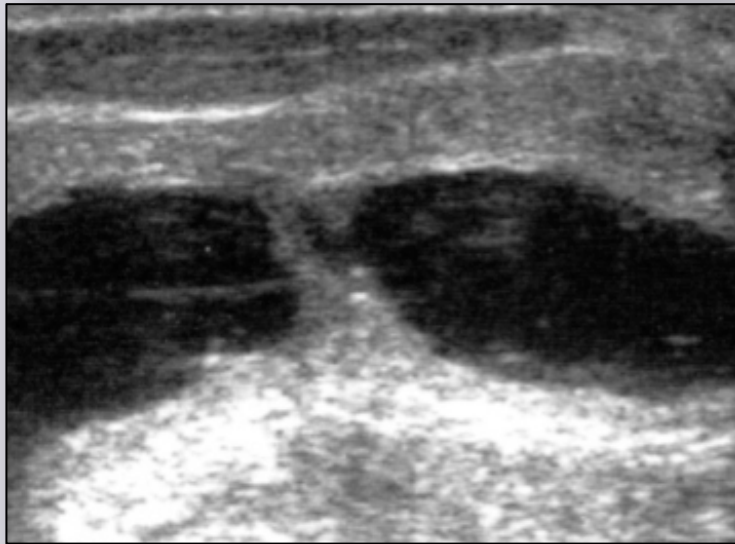
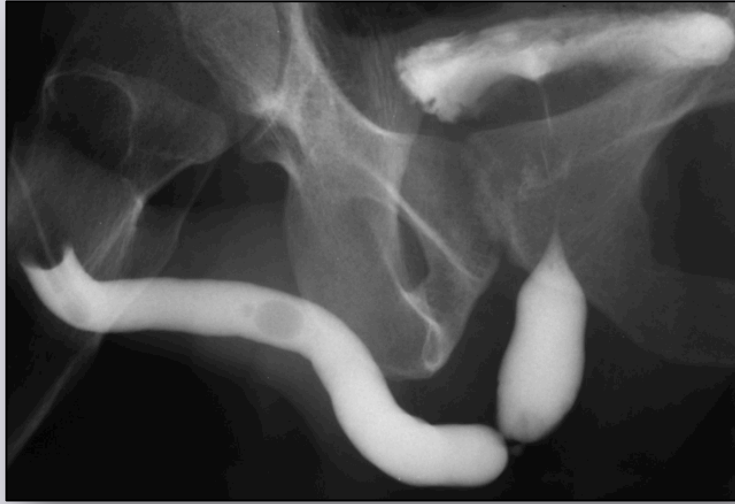

Allen stirrups



**Sequential inflatable
compression sleeves**

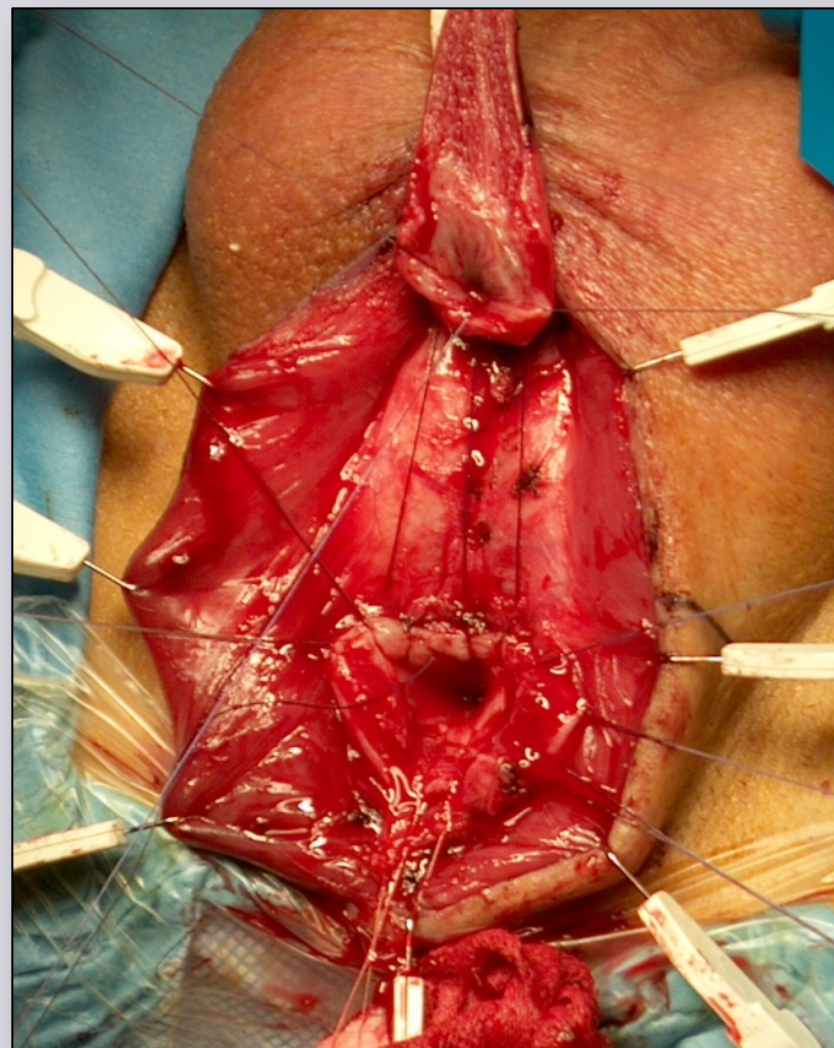
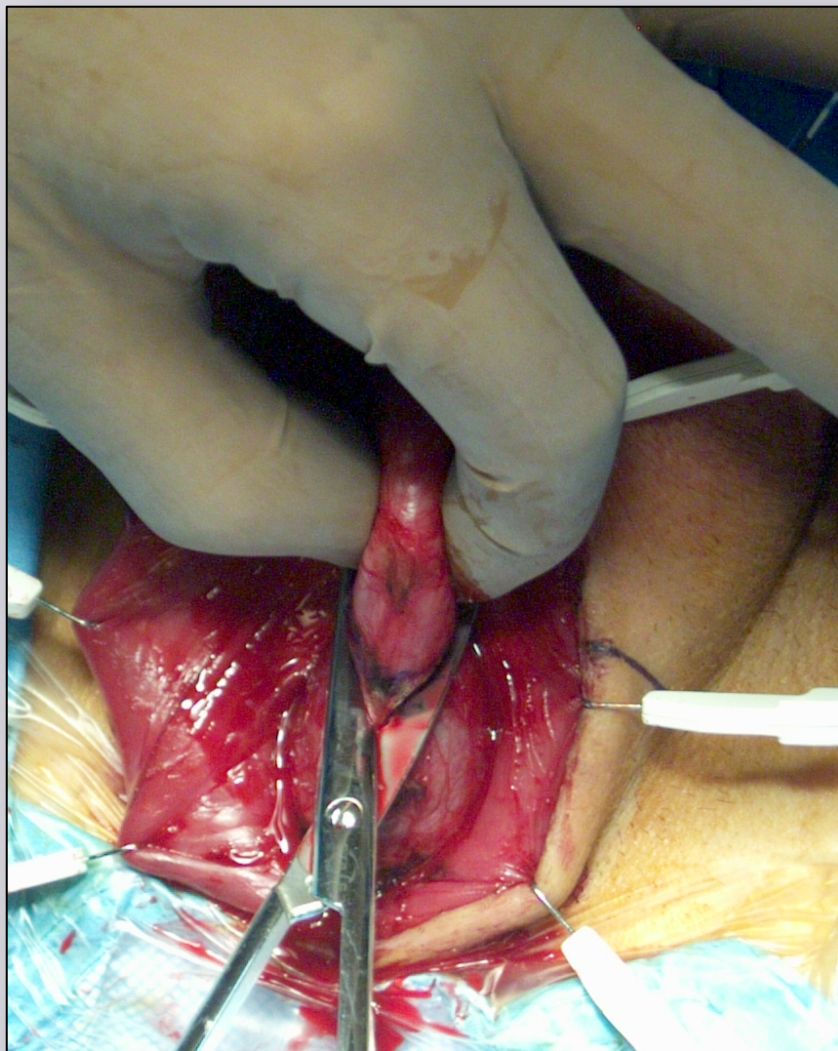
1 - 2 cm traumatic bulbar urethral stricture



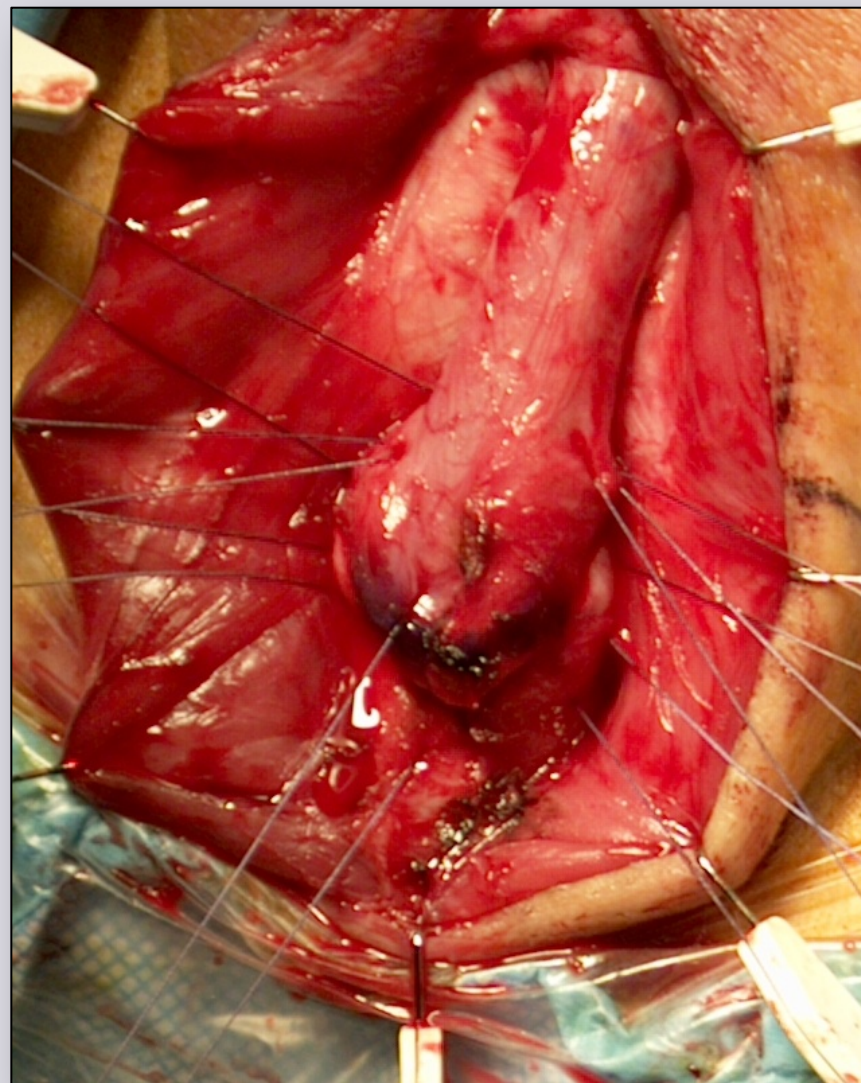
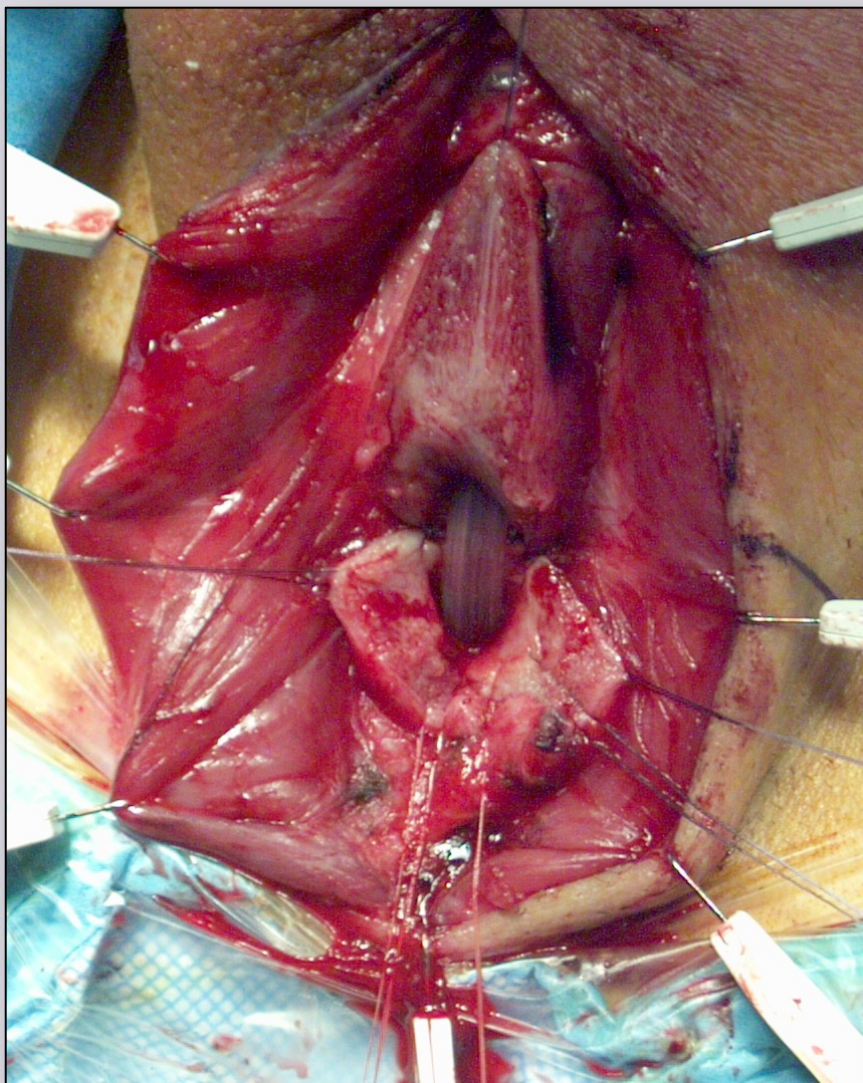
e-mail: info@urethralcenter.it

Websites: www.uretra.it
www.urethralcenter.it

End-to-end anastomosis



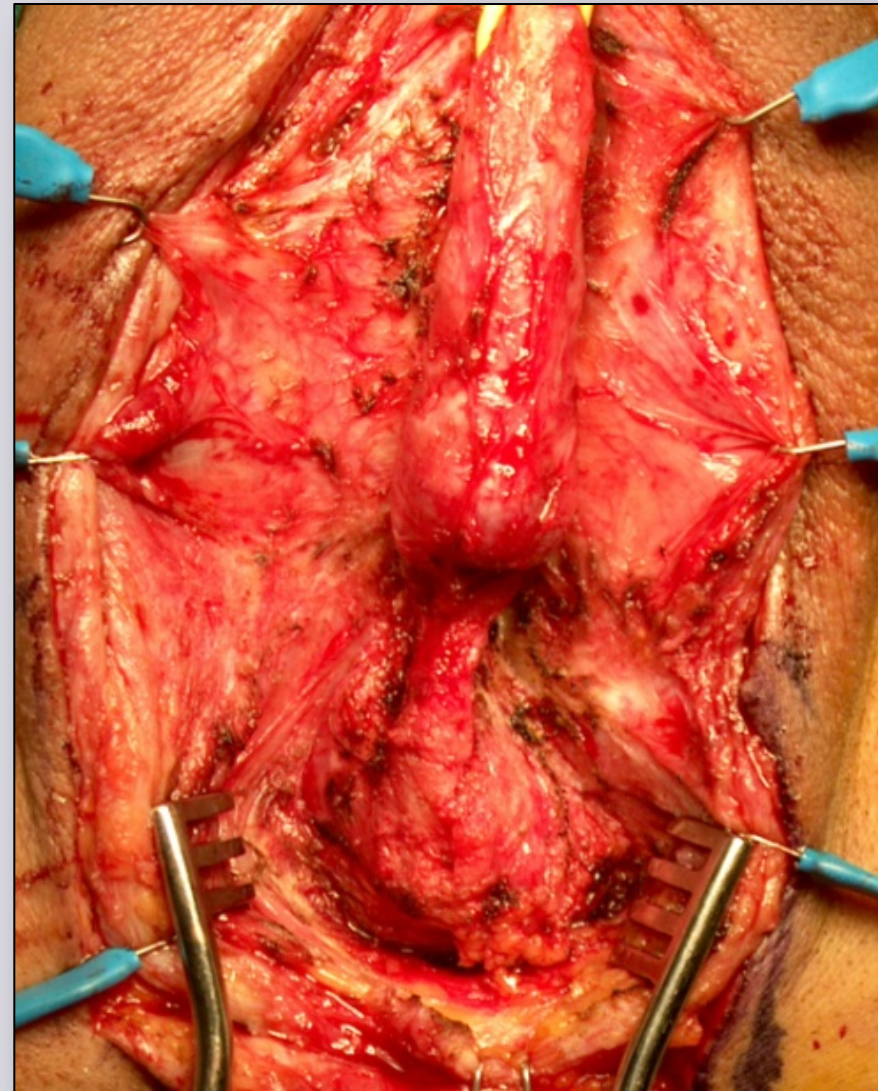
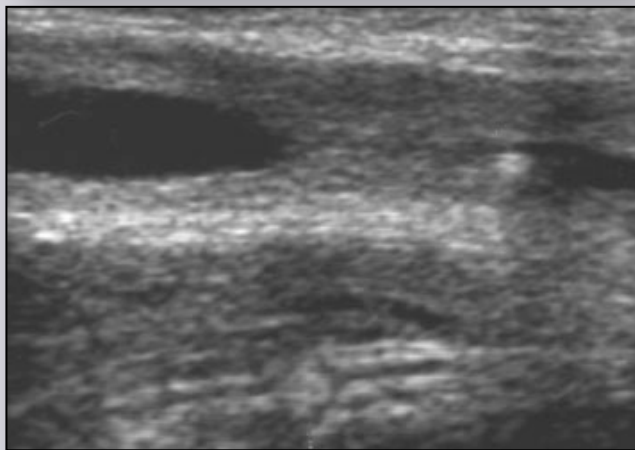
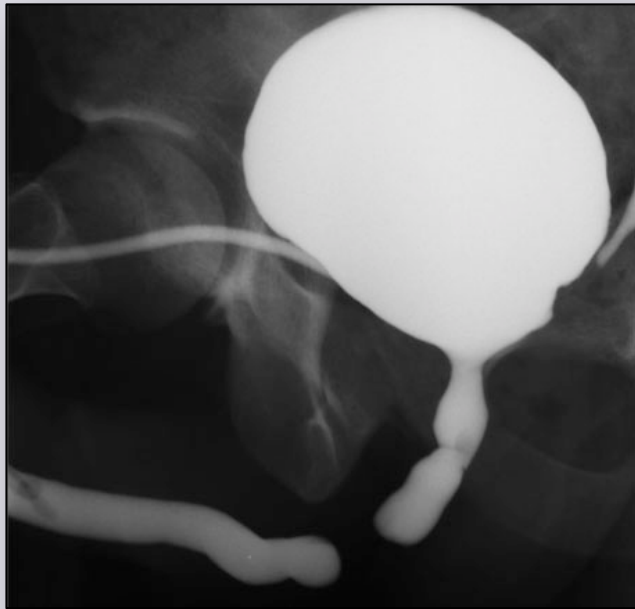
End-to-end anastomosis



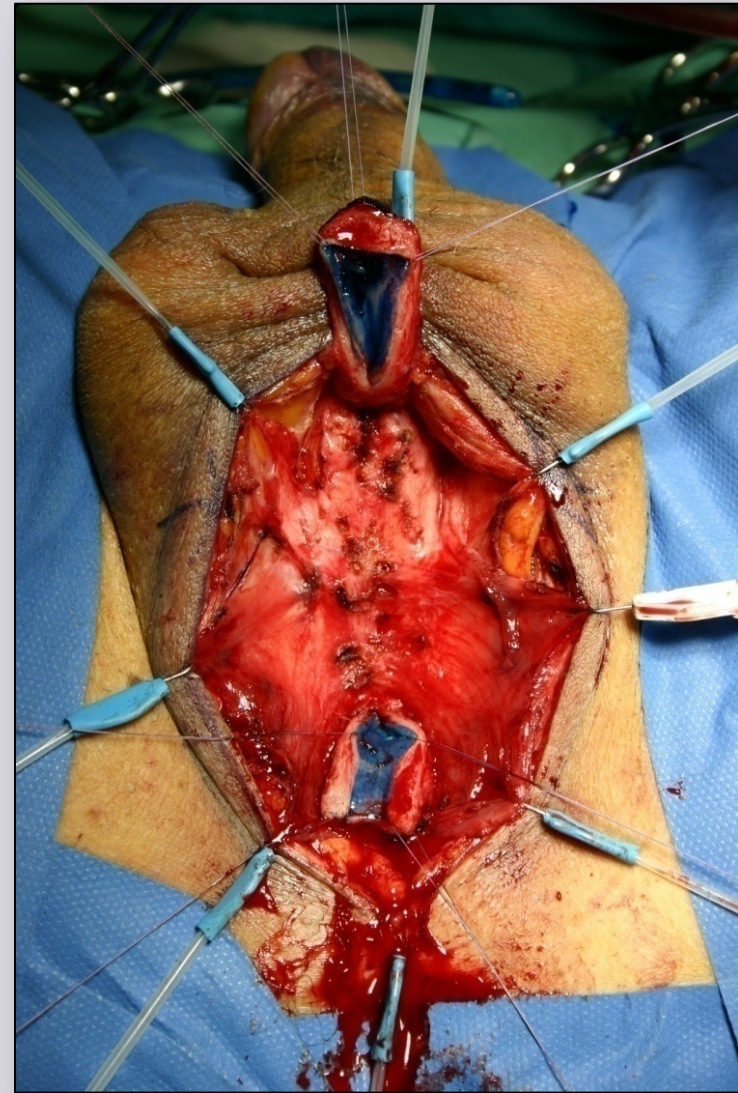
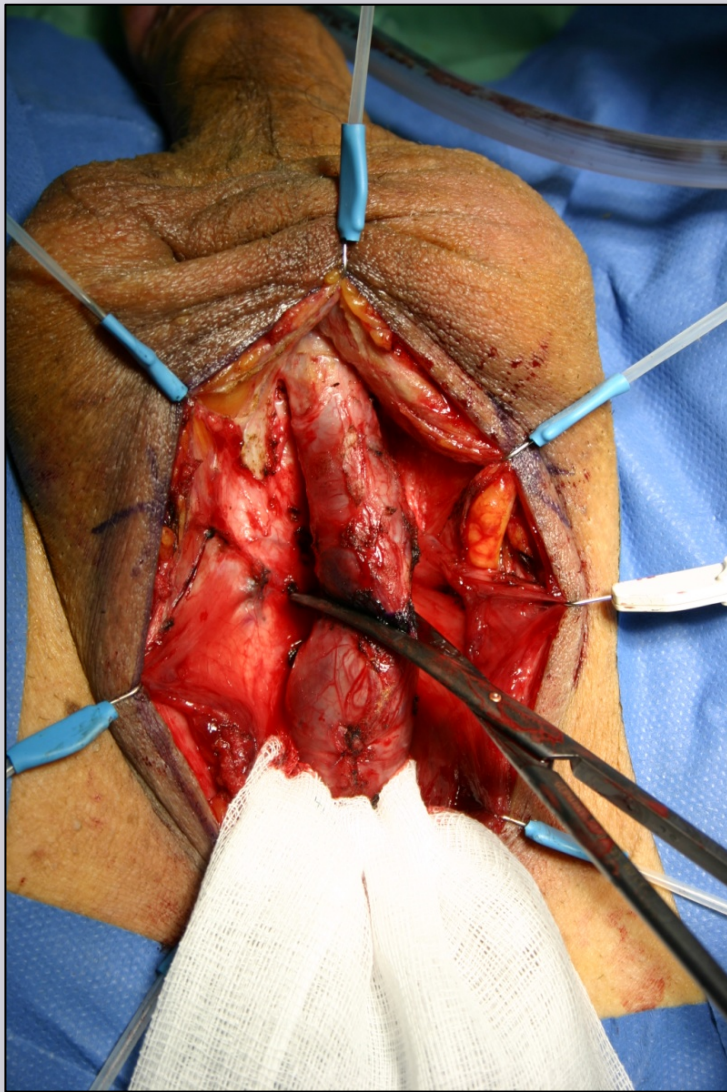
e-mail: info@urethralcenter.it

Websites: www.uretra.it
www.urethralcenter.it

2 - 4 cm traumatic bulbar urethral stricture



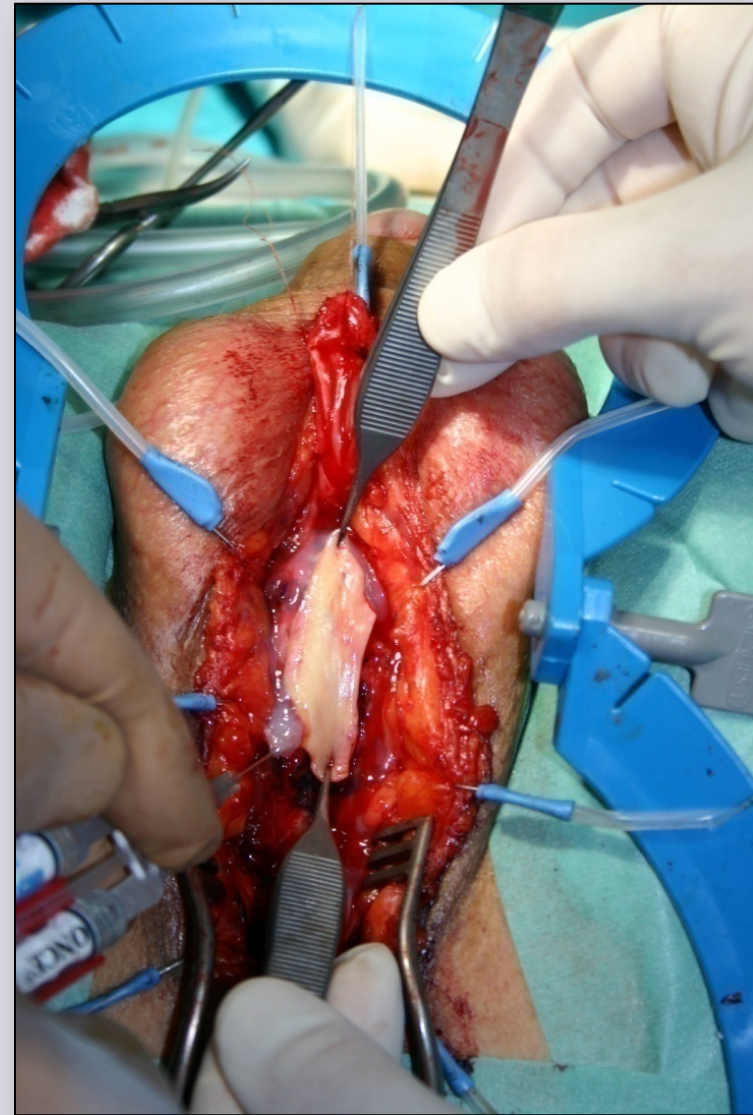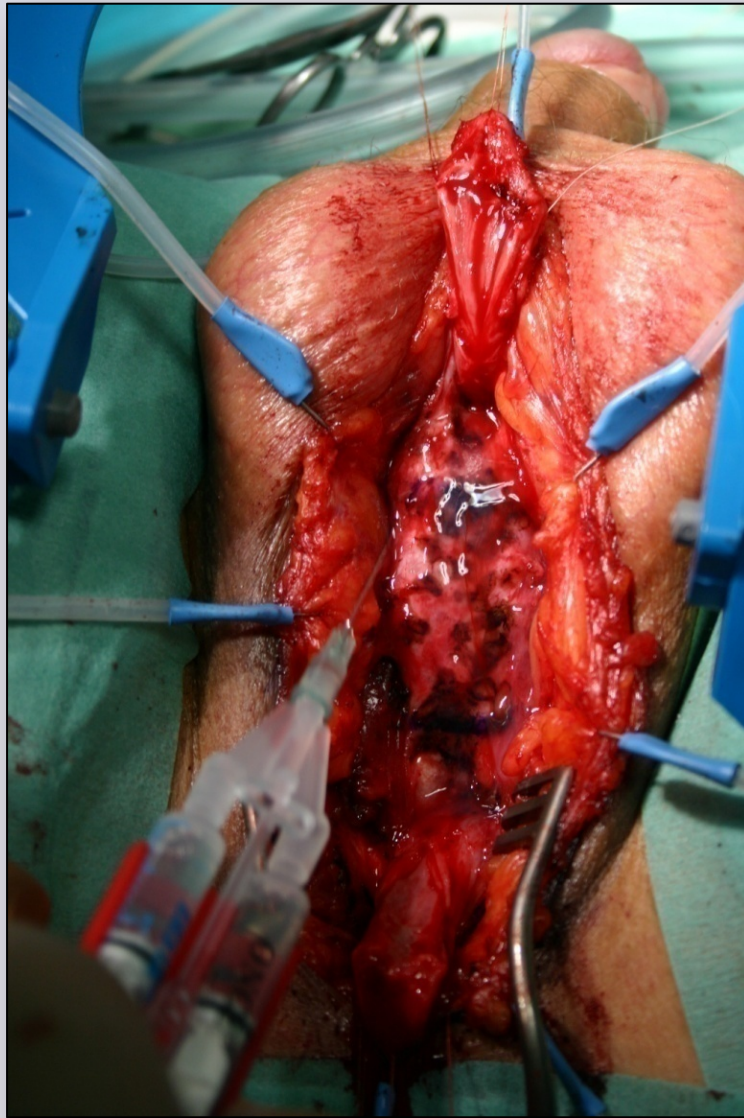Augmented anastomotic repair



e-mail: info@urethralcenter.it

Websites: www.uretra.it
www.urethralcenter.it

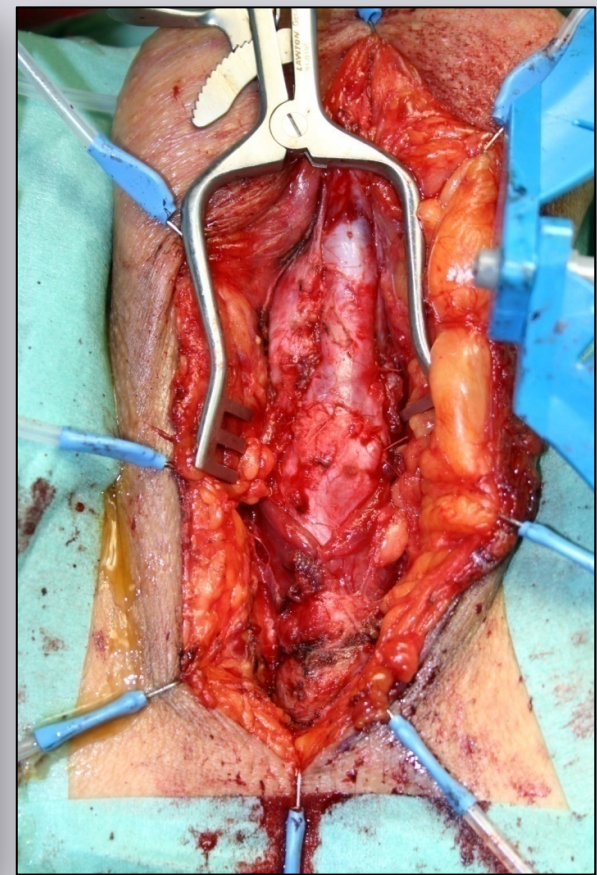
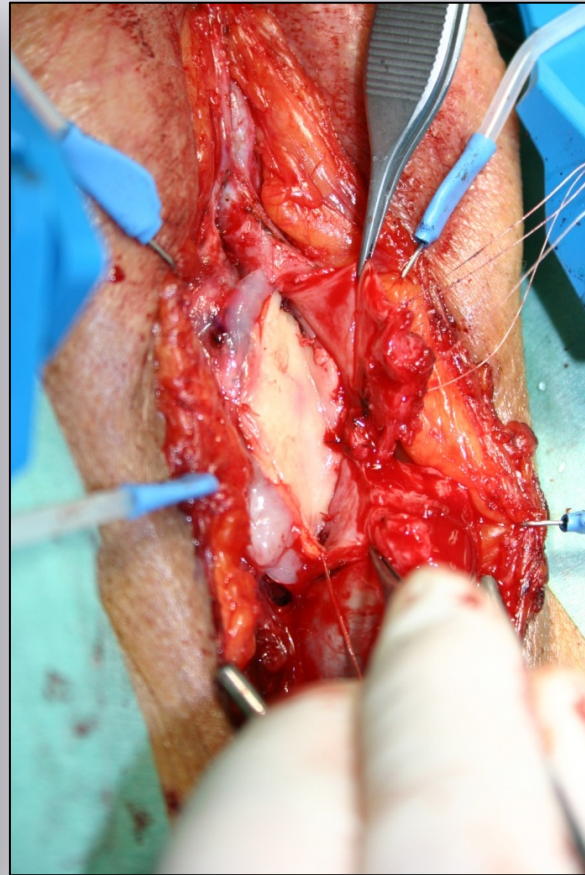
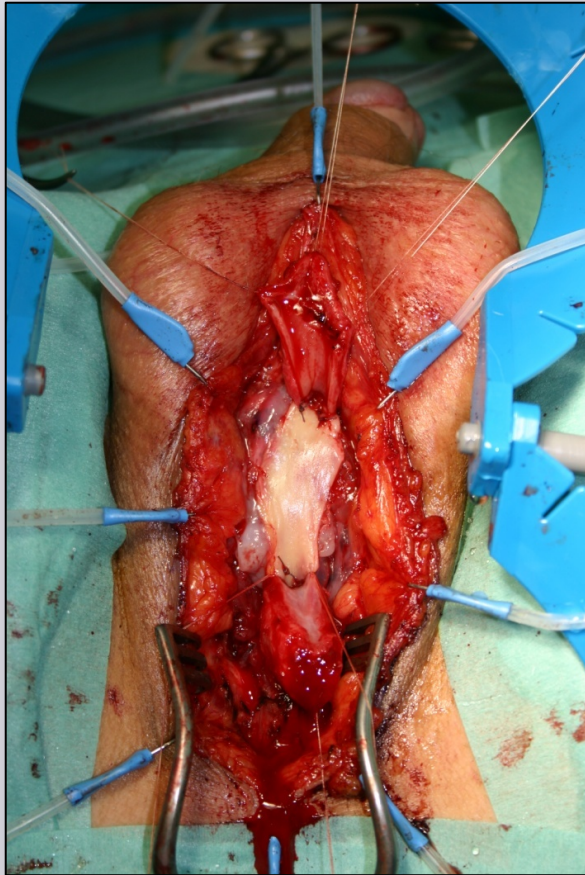
Augmented anastomotic repair



e-mail: info@urethralcenter.it

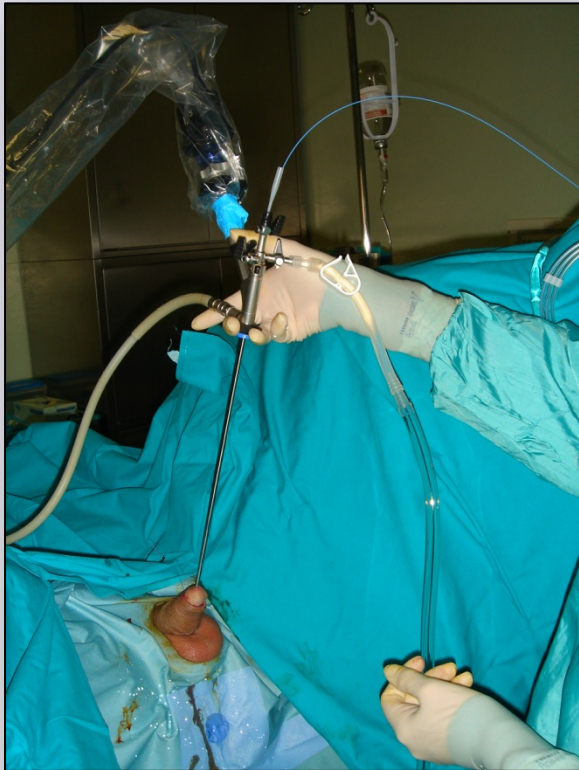
Websites: www.uretra.it
www.urethralcenter.it

Augmented anastomotic repair

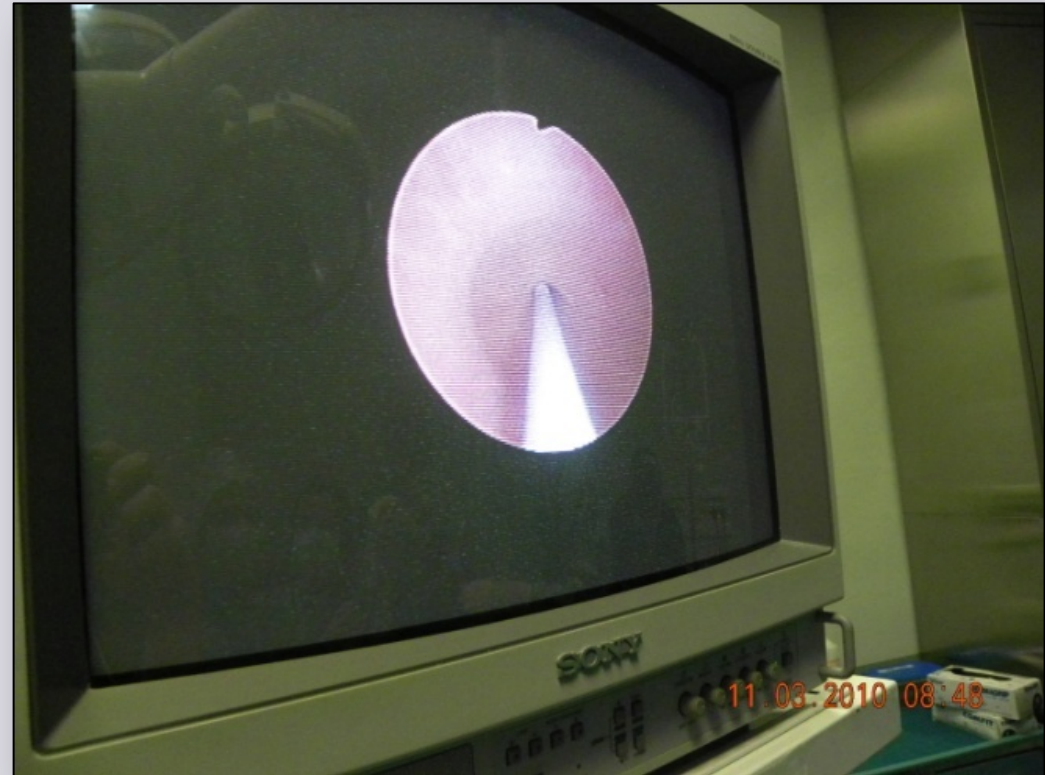

Reconstruction of the bulbar urethra in non-traumatic stricture

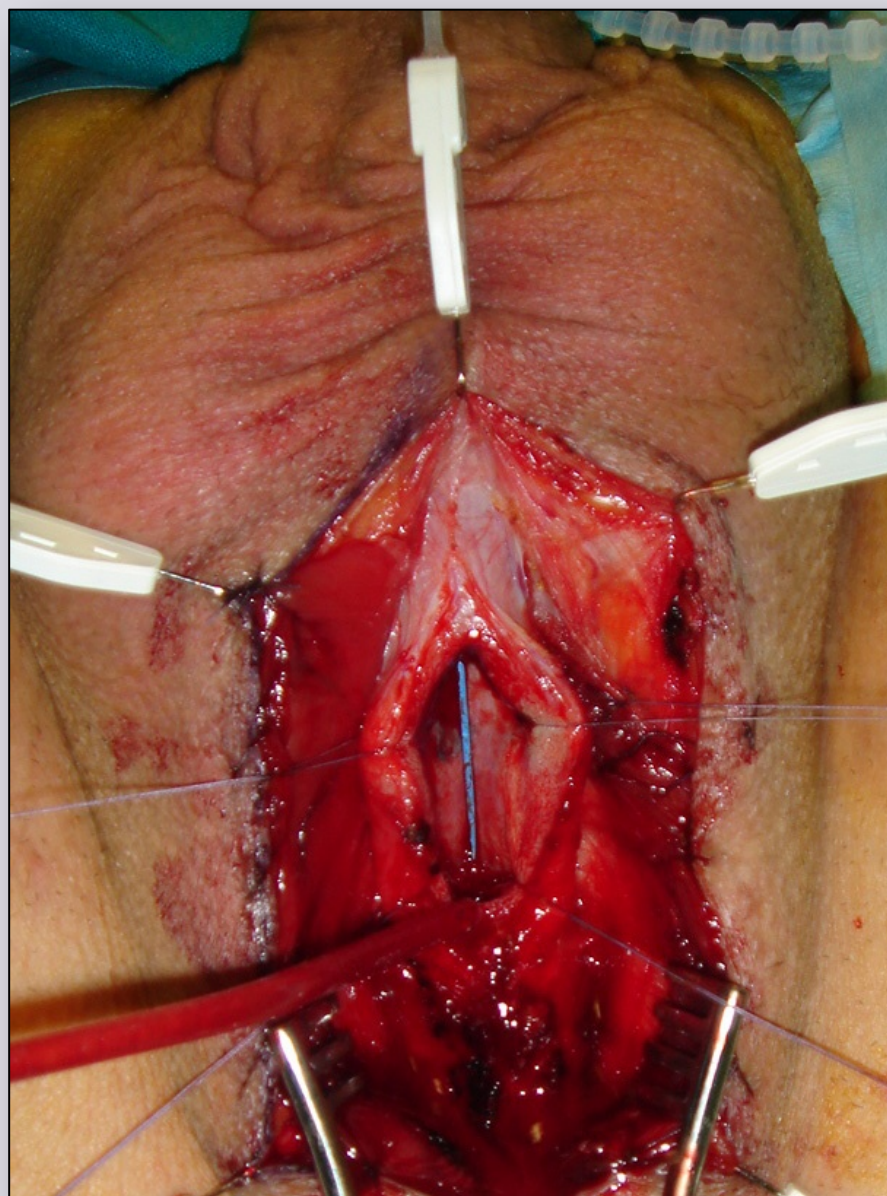
Non-traumatic bulbar urethral stricture



**Pre-operative
urethroscopy**



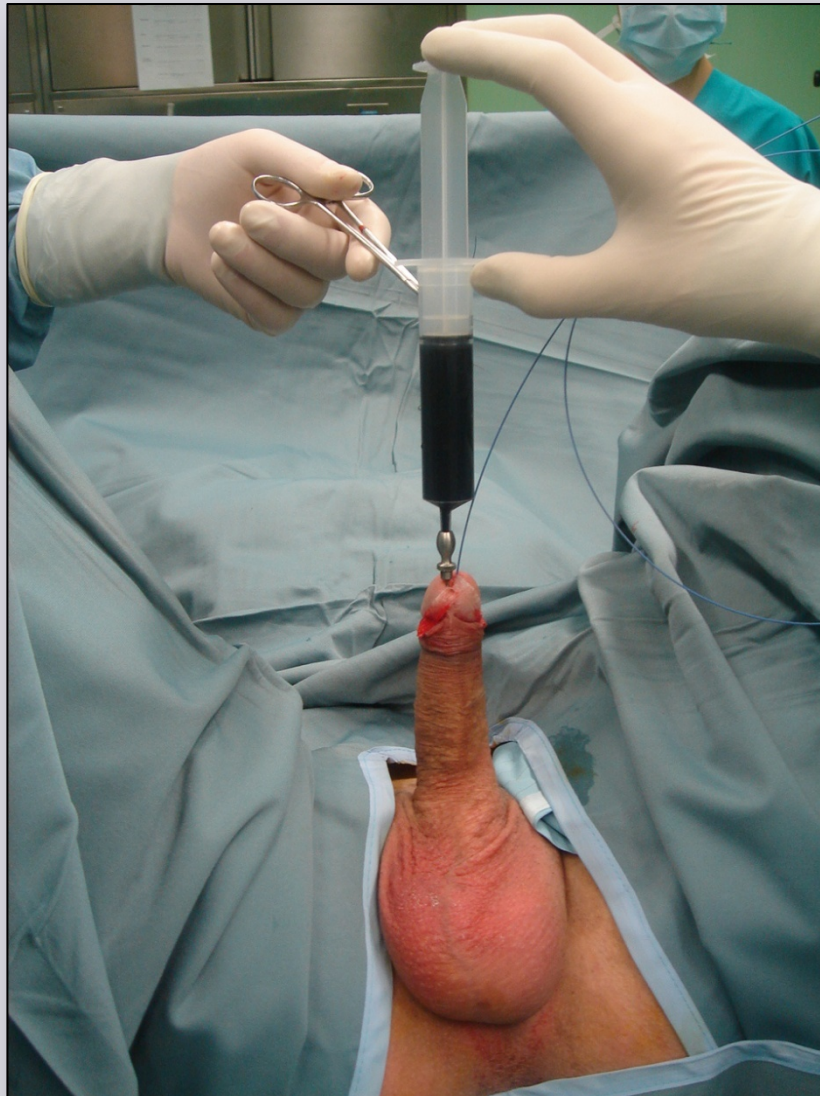
Insert Sensor 3 Fr. guidewire



e-mail: info@urethralcenter.it

Websites: www.uretra.it
www.urethralcenter.it

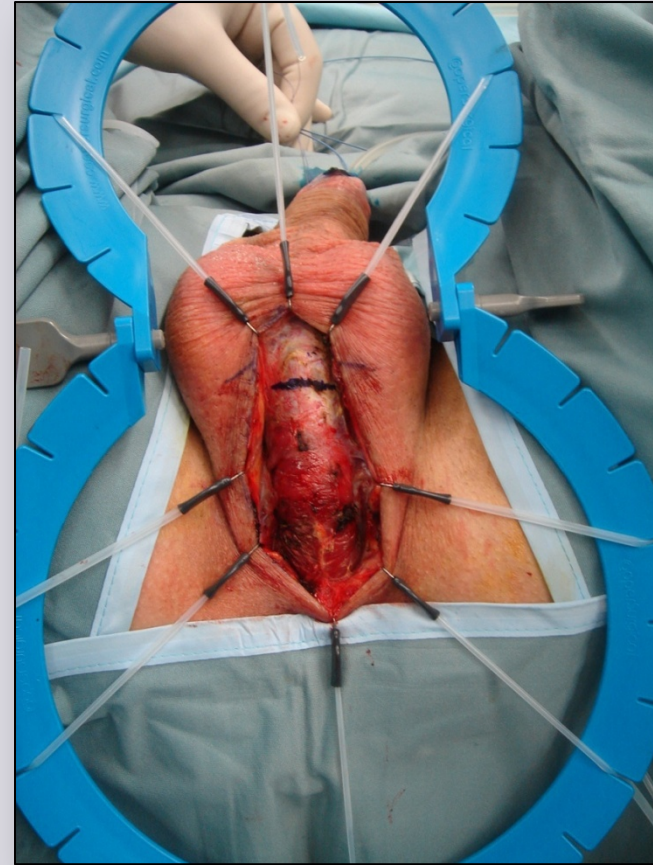
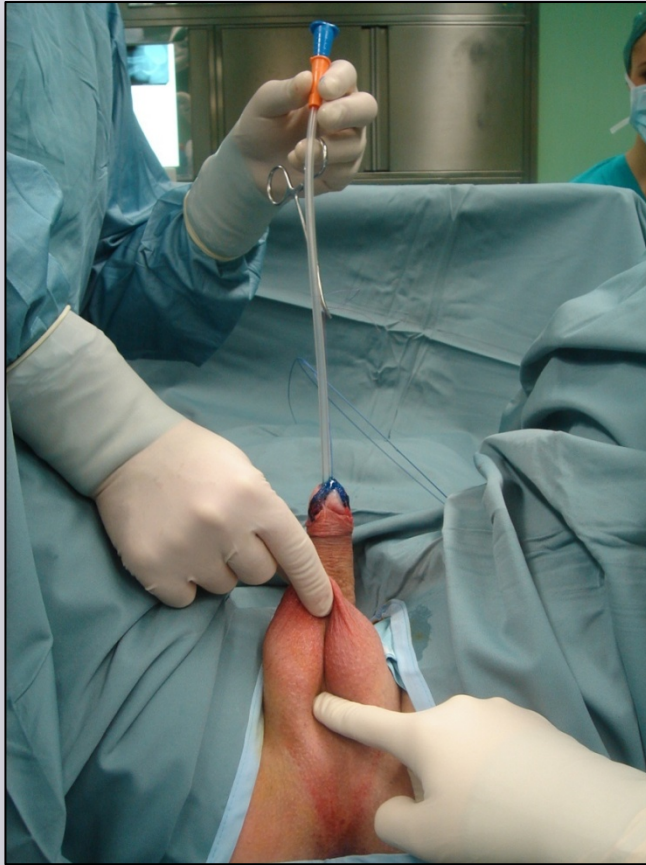Non-traumatic bulbar urethral stricture



**Inject methylene blue
inside the urethra**

(G. Webster)

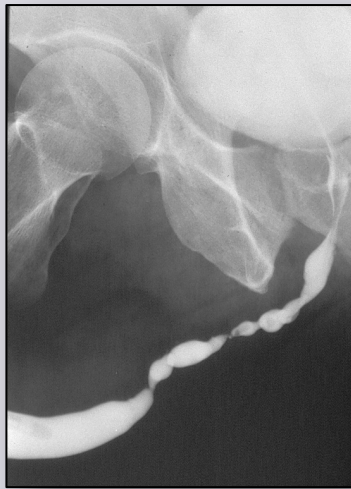Non-traumatic bulbar urethral stricture



Calibrate the distal urethra and identify the distal stop

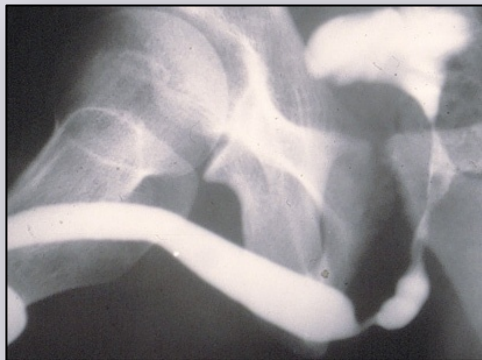Non-traumatic bulbar urethral stricture

Ventral or dorsal graft?



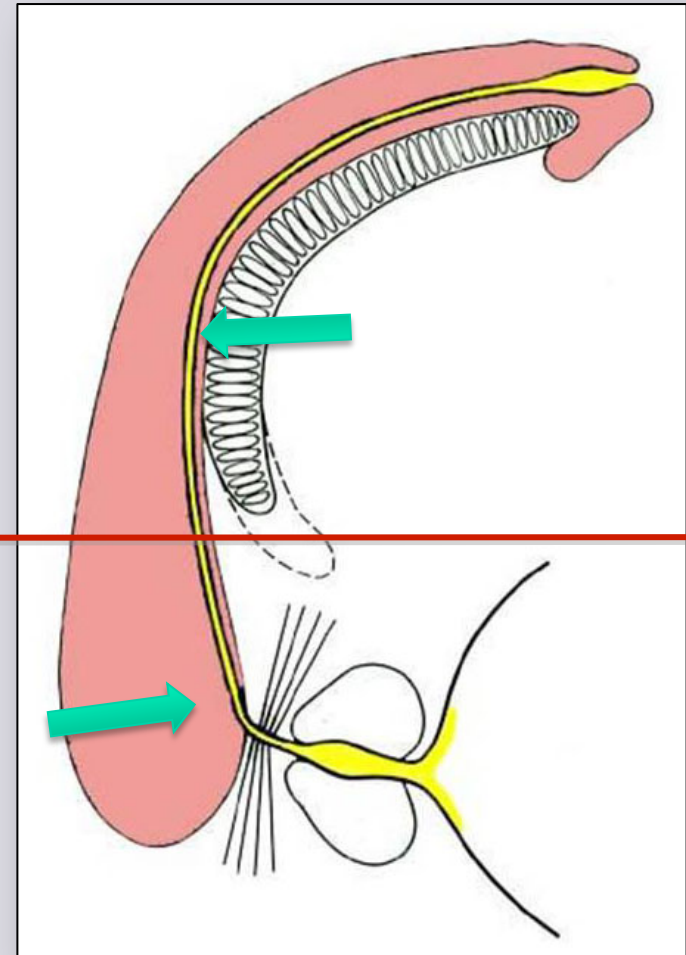
Distal

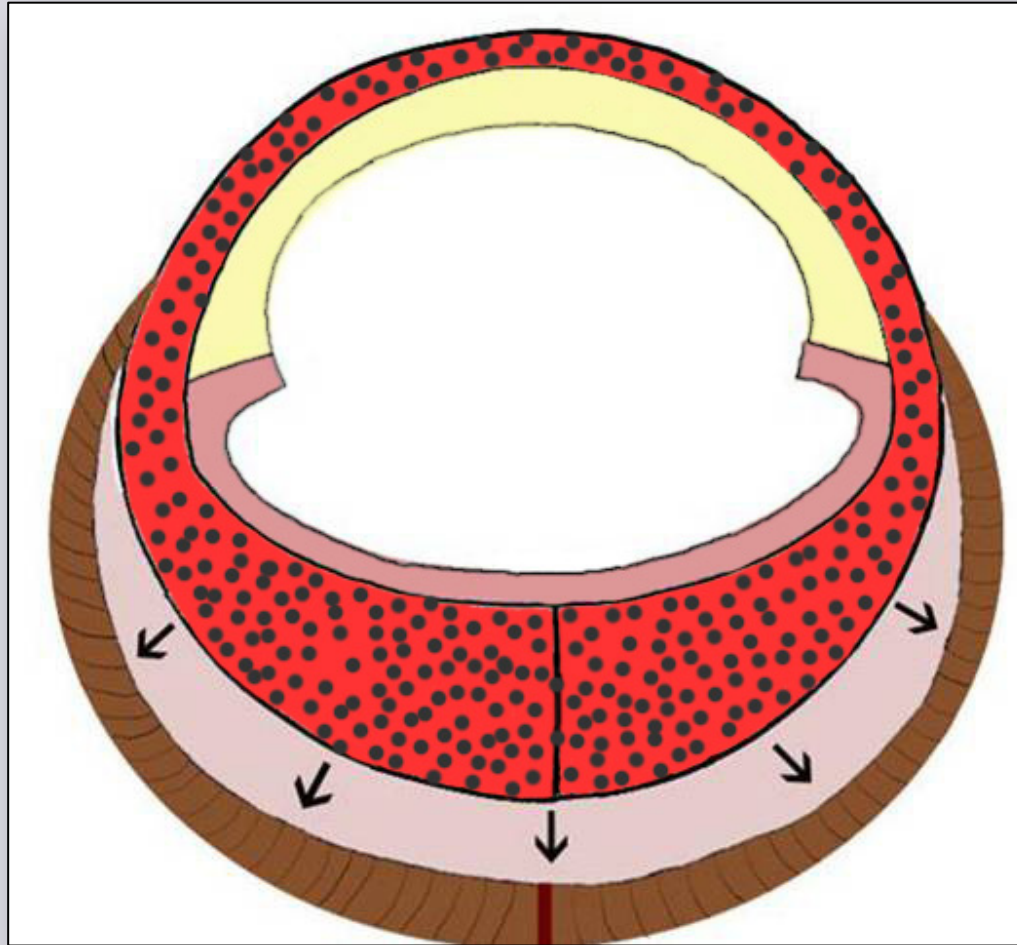
Dorsal onlay



Proximal

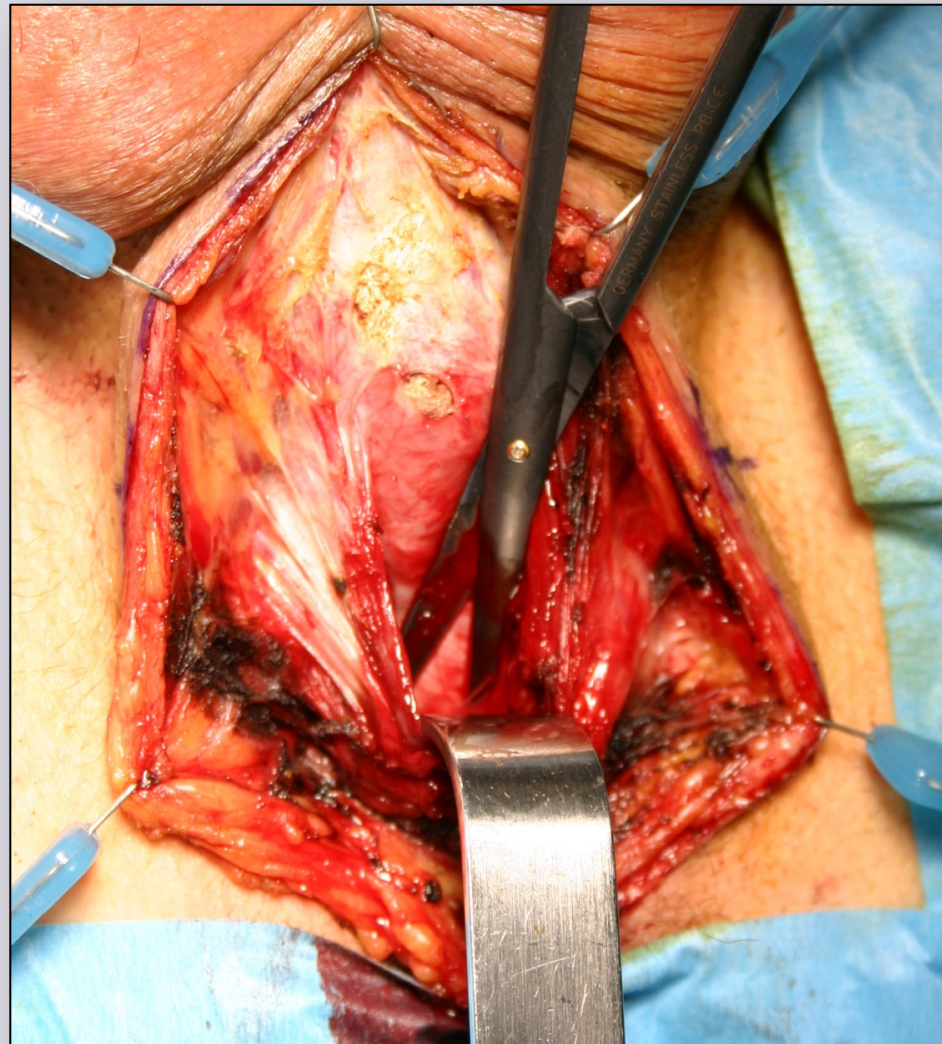
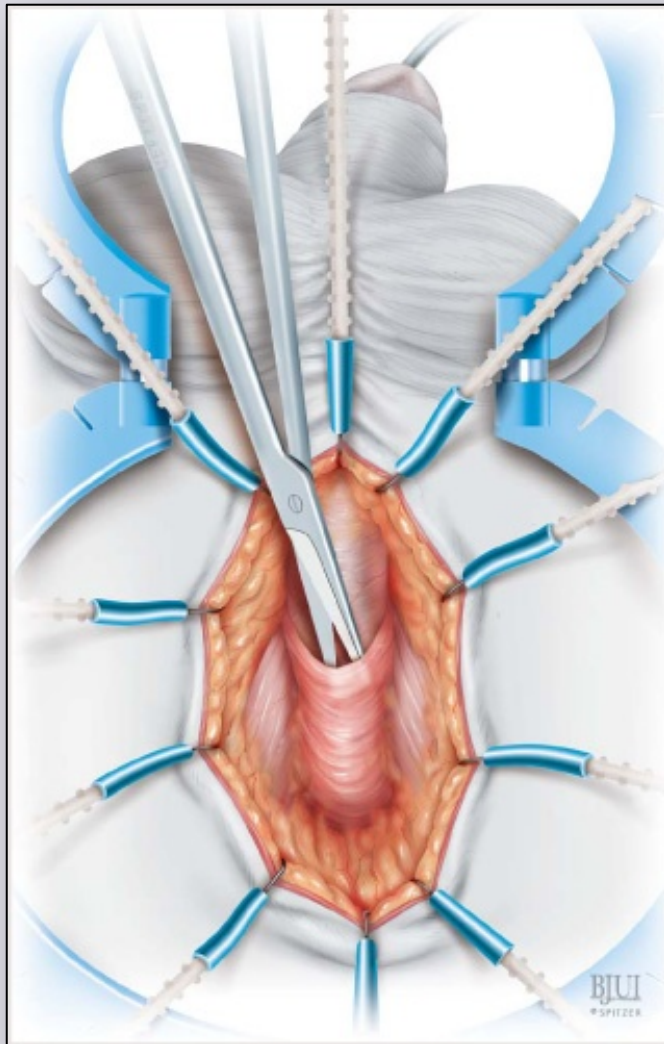
Ventral onlay





Muscle and nerve-sparing **ventral onlay graft bulbar urethroplasty**

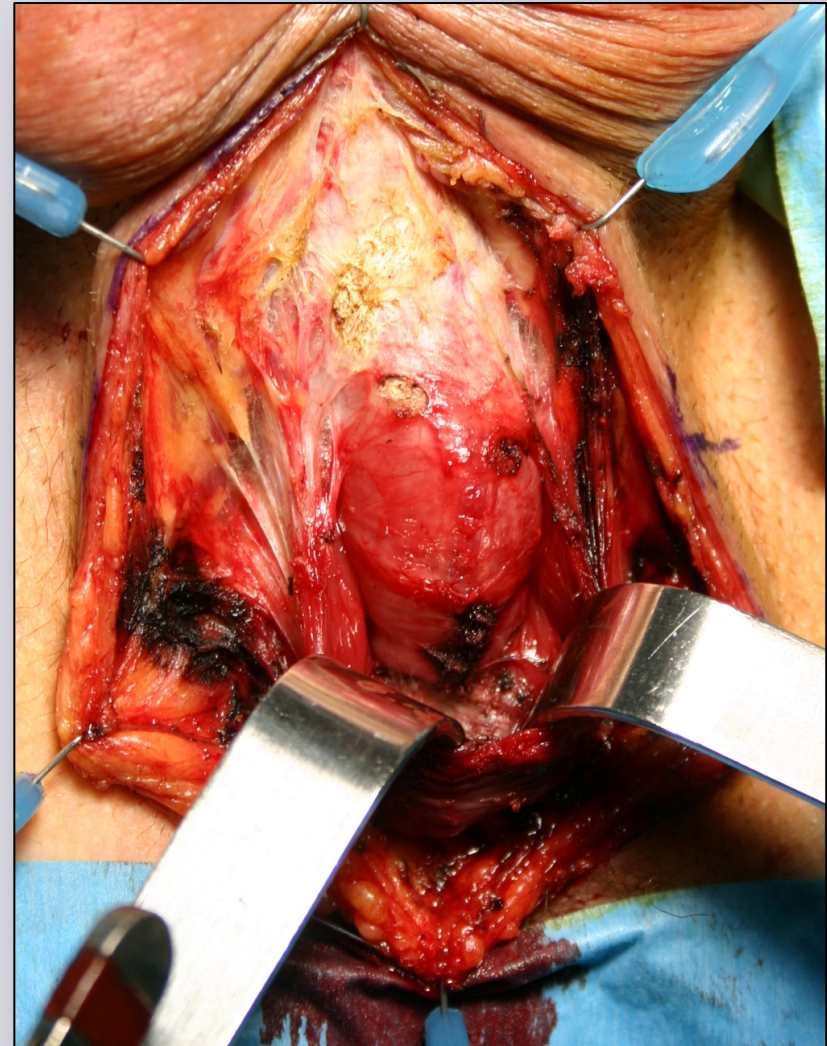
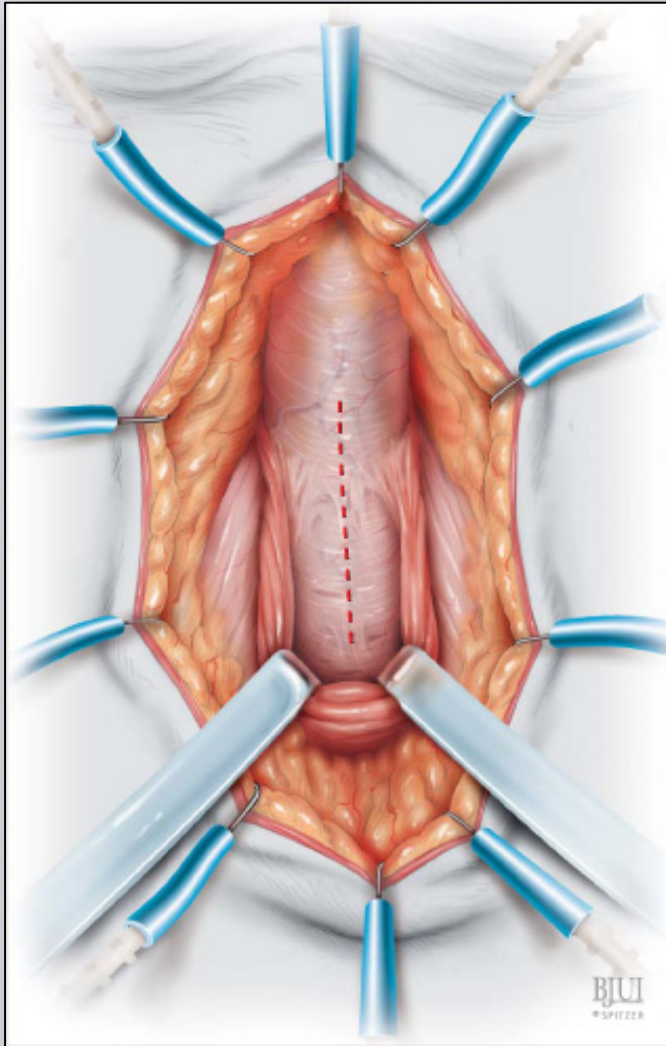
Muscle and nerve-sparing **ventral** onlay graft bulbar urethroplasty



e-mail: info@urethralcenter.it

Websites: www.uretra.it
www.urethralcenter.it

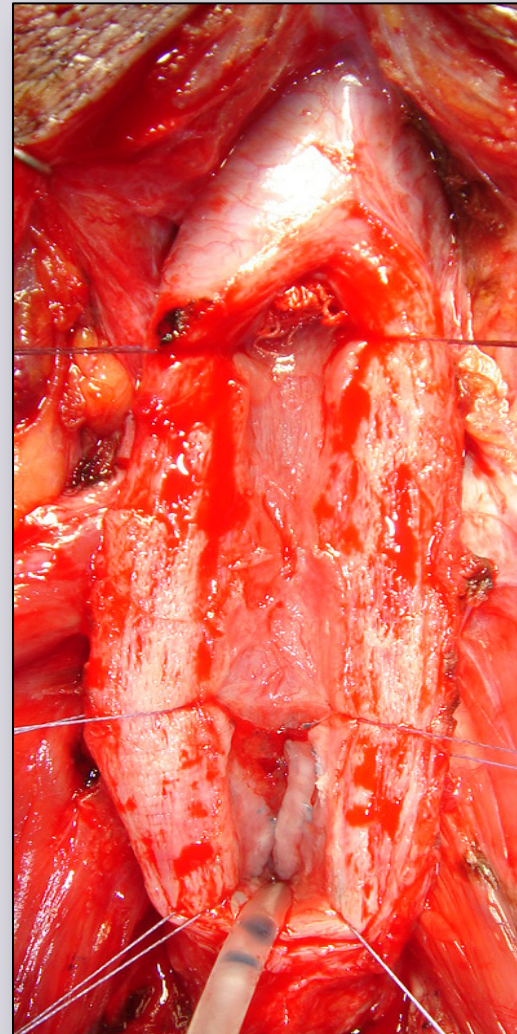
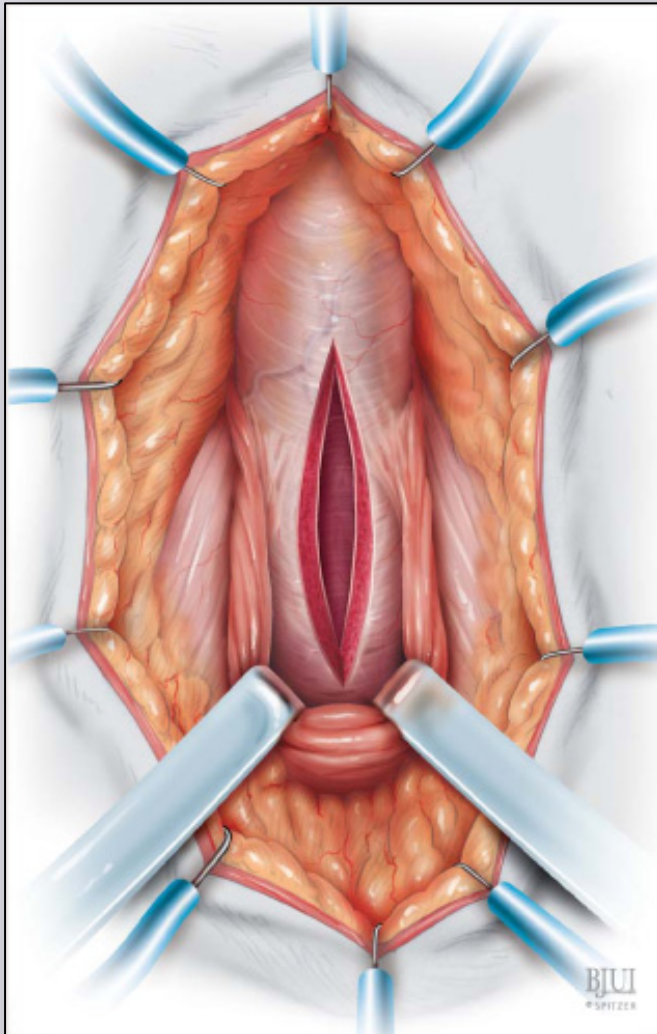
Muscle and nerve-sparing **ventral** onlay graft bulbar urethroplasty



e-mail: info@urethralcenter.it

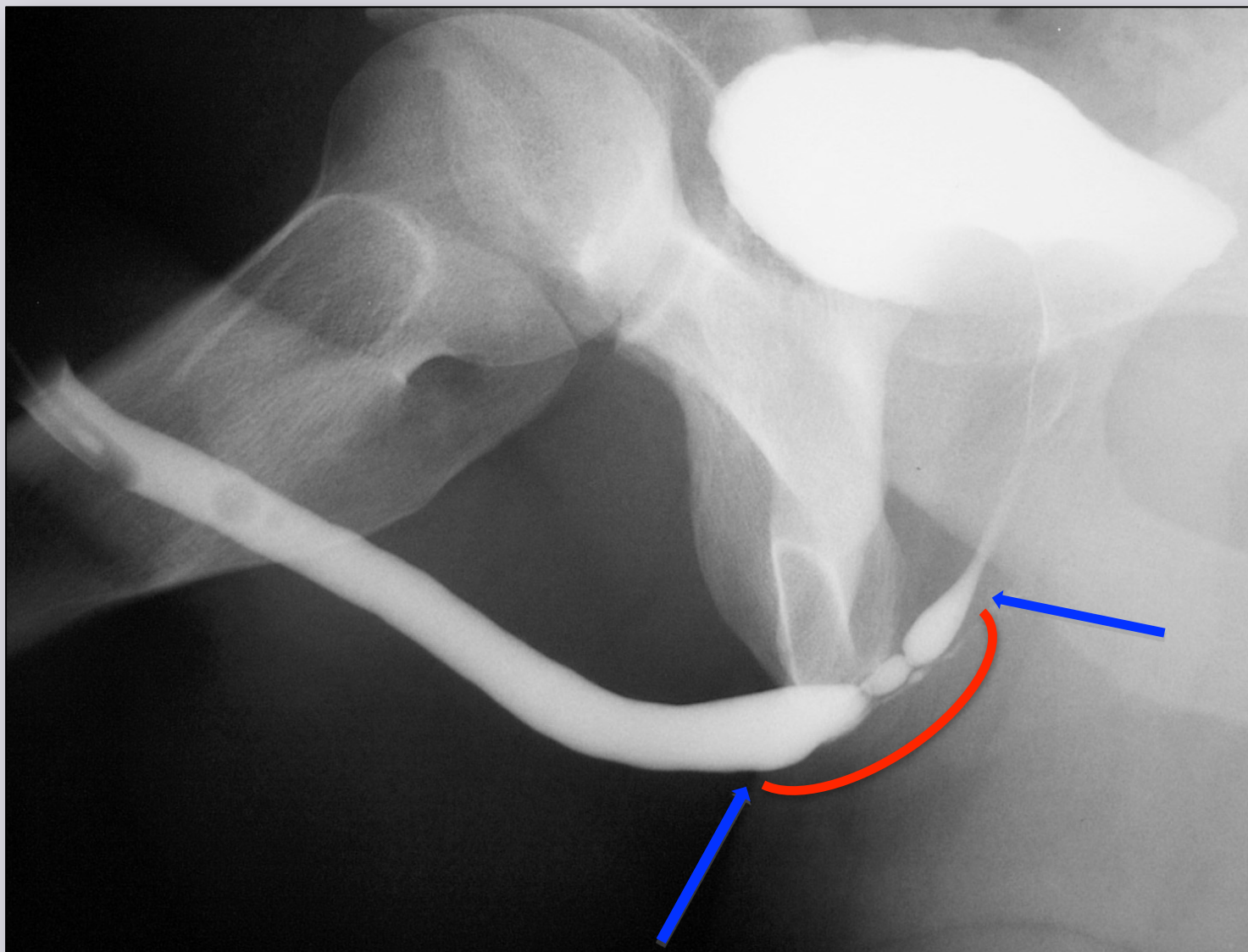
Websites: www.uretra.it
www.urethralcenter.it

Muscle and nerve-sparing **ventral** onlay graft bulbar urethroplasty



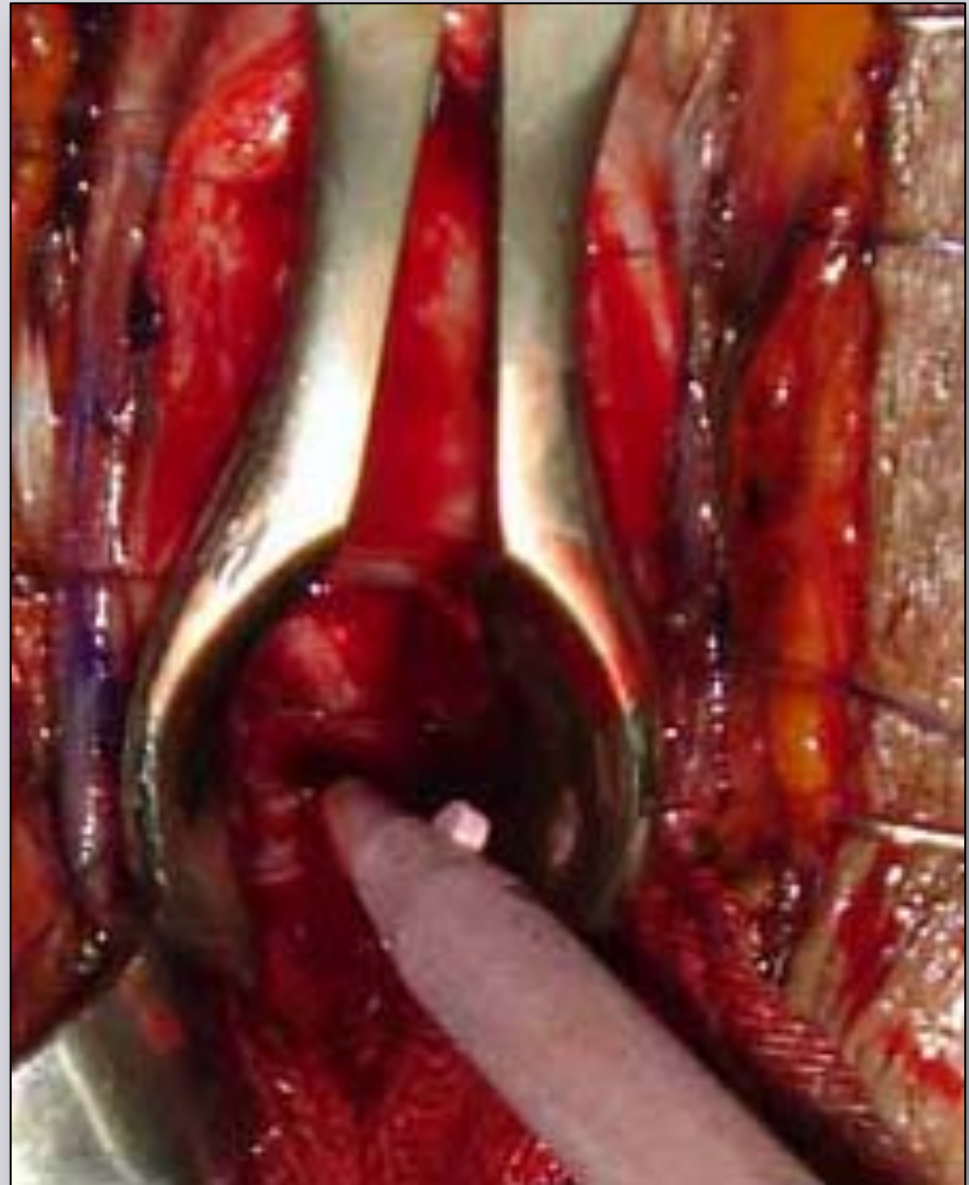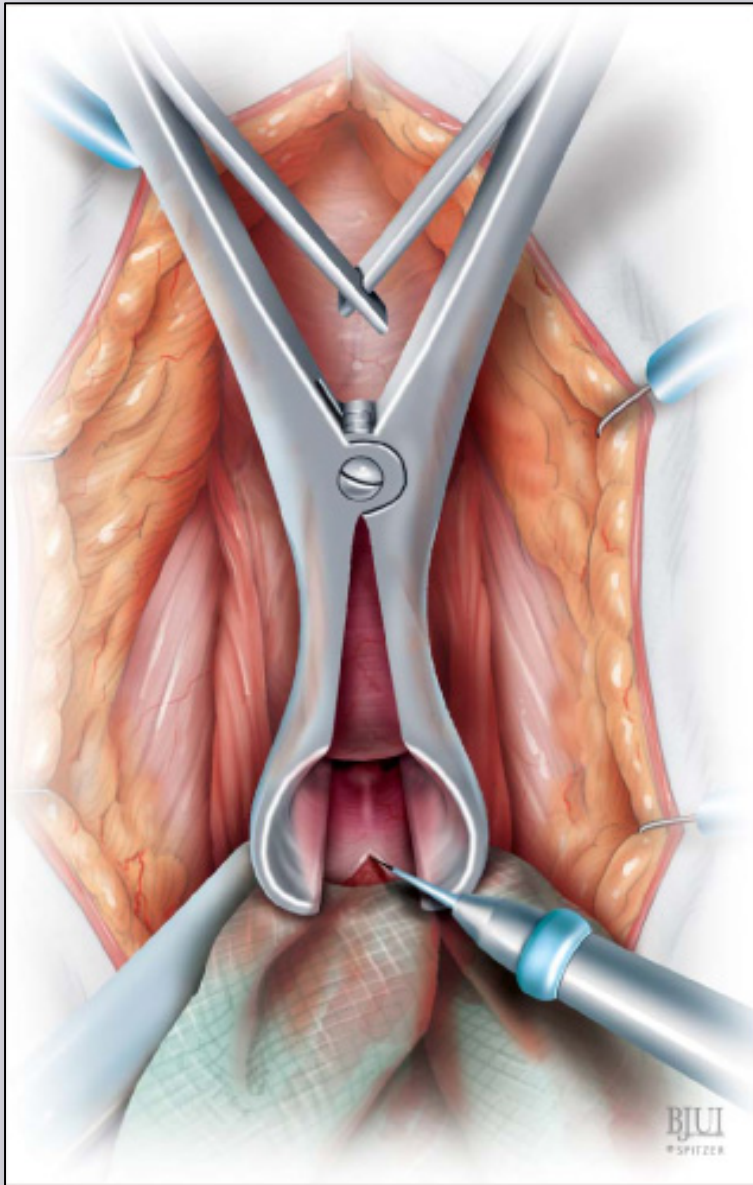
e-mail: info@urethralcenter.it

Websites: www.uretra.it
www.urethralcenter.it



e-mail: info@urethralcenter.it

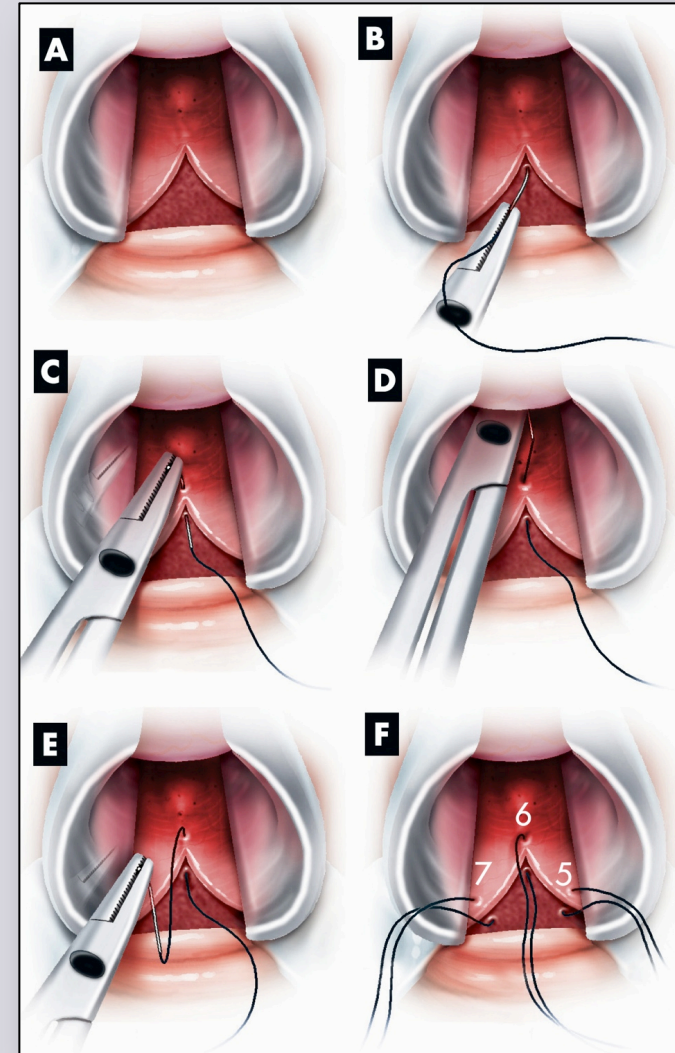
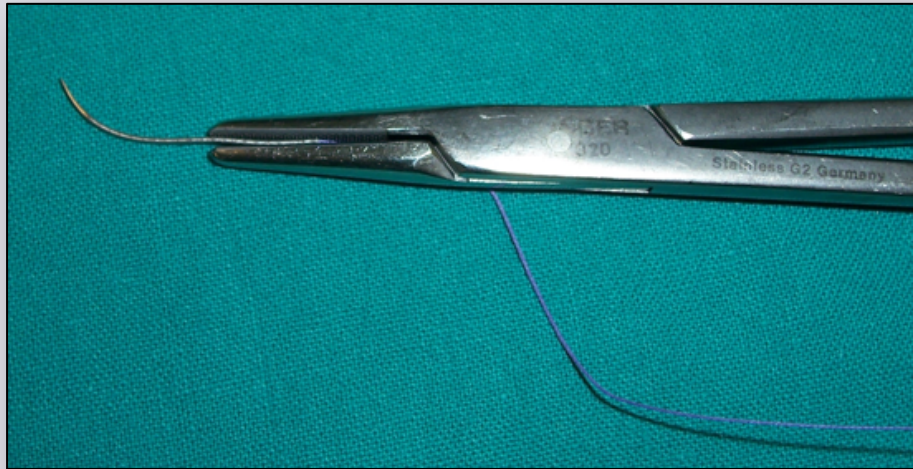
Websites: www.uretra.it
www.urethralcenter.it



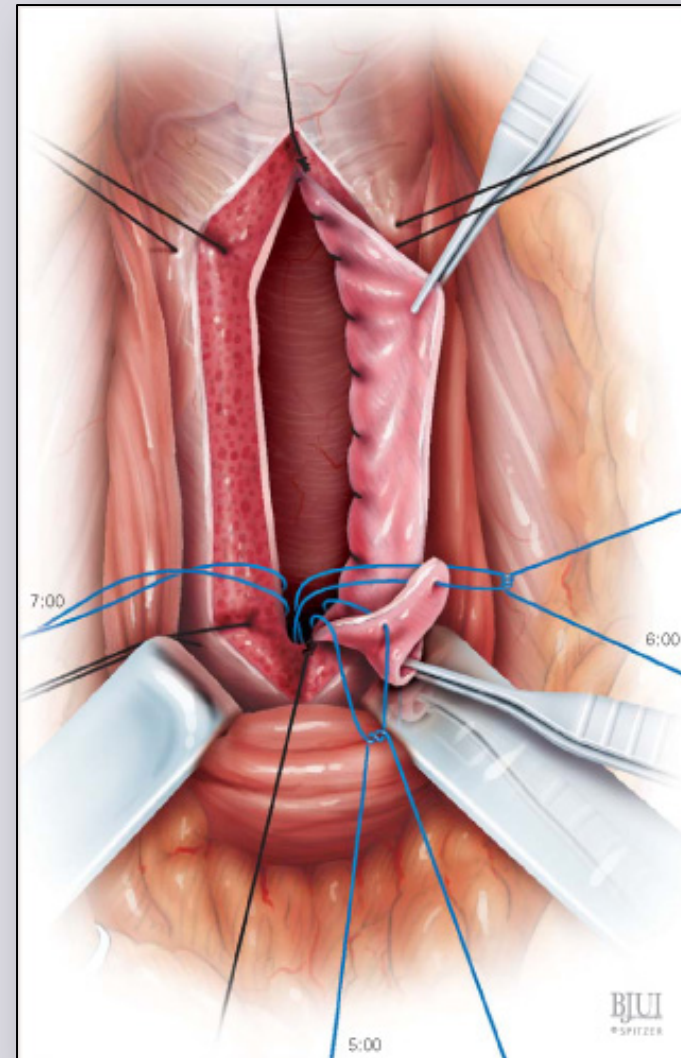
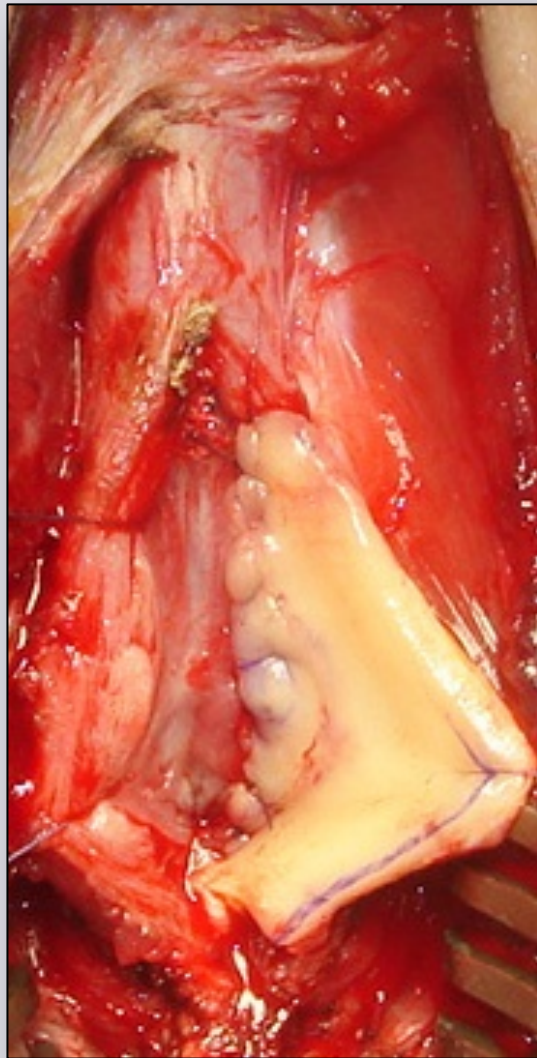
e-mail: info@urethralcenter.it

Websites: www.uretra.it
www.urethralcenter.it

Webster's technique



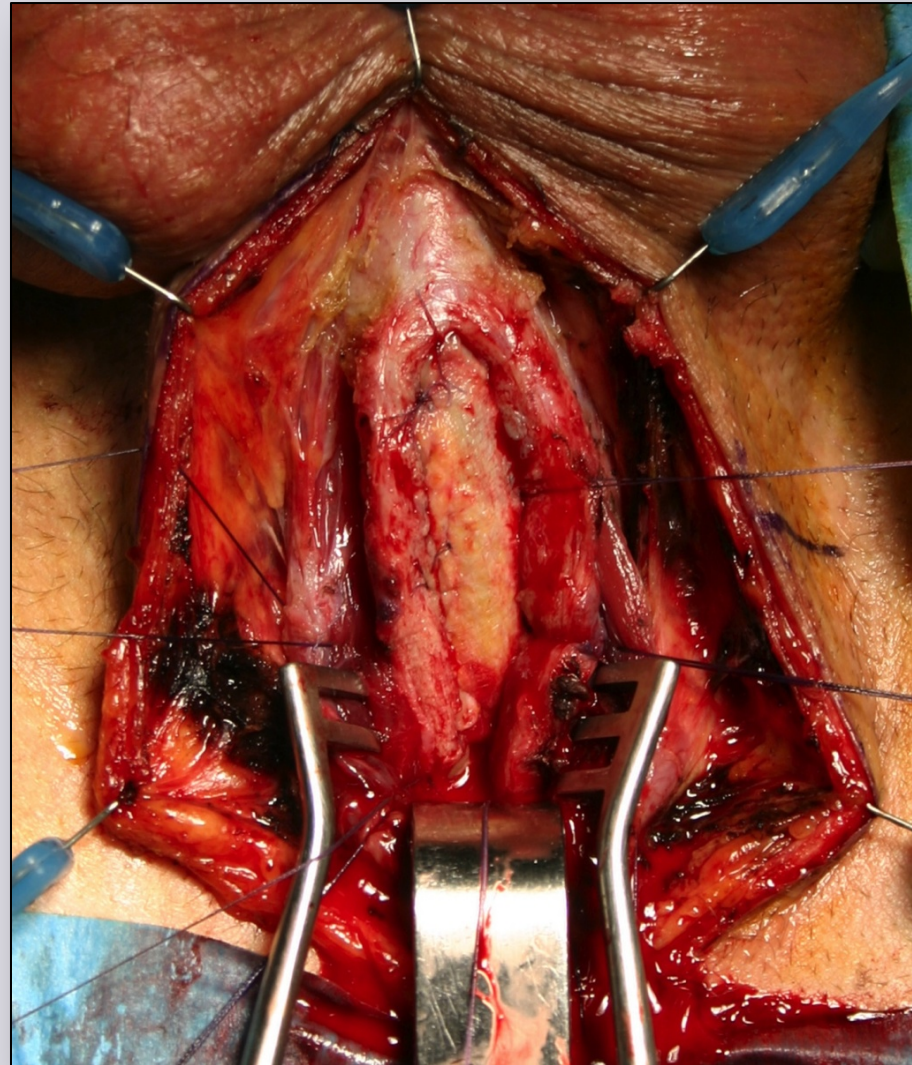
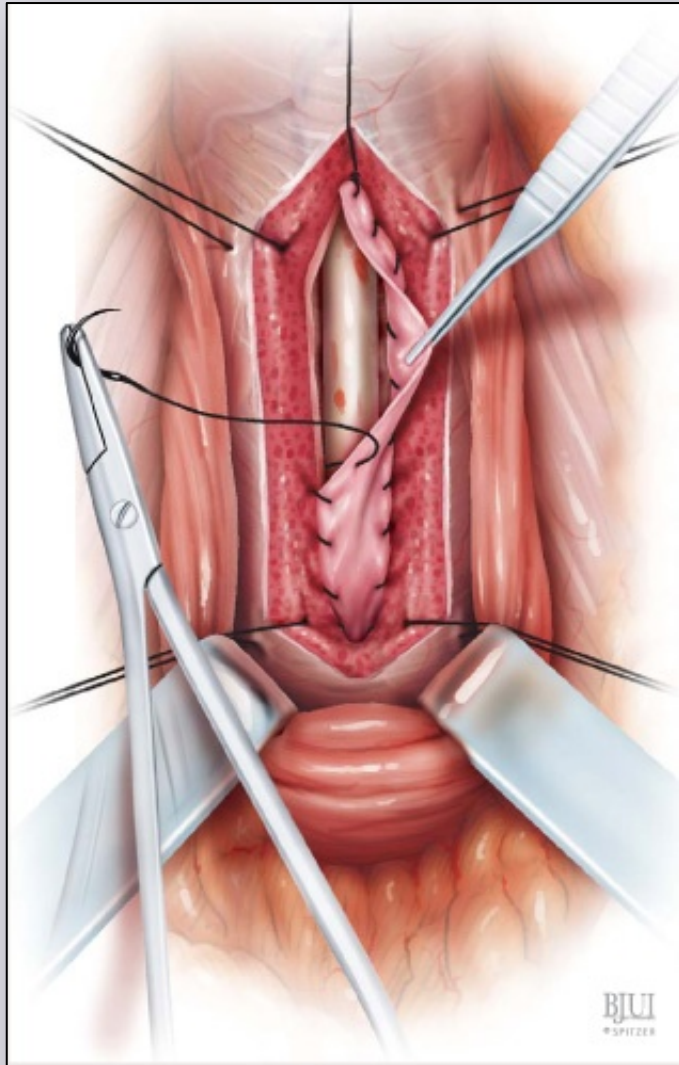
Muscle and nerve-sparing **ventral** onlay graft bulbar urethroplasty



e-mail: info@urethralcenter.it

Websites: www.uretra.it
www.urethralcenter.it

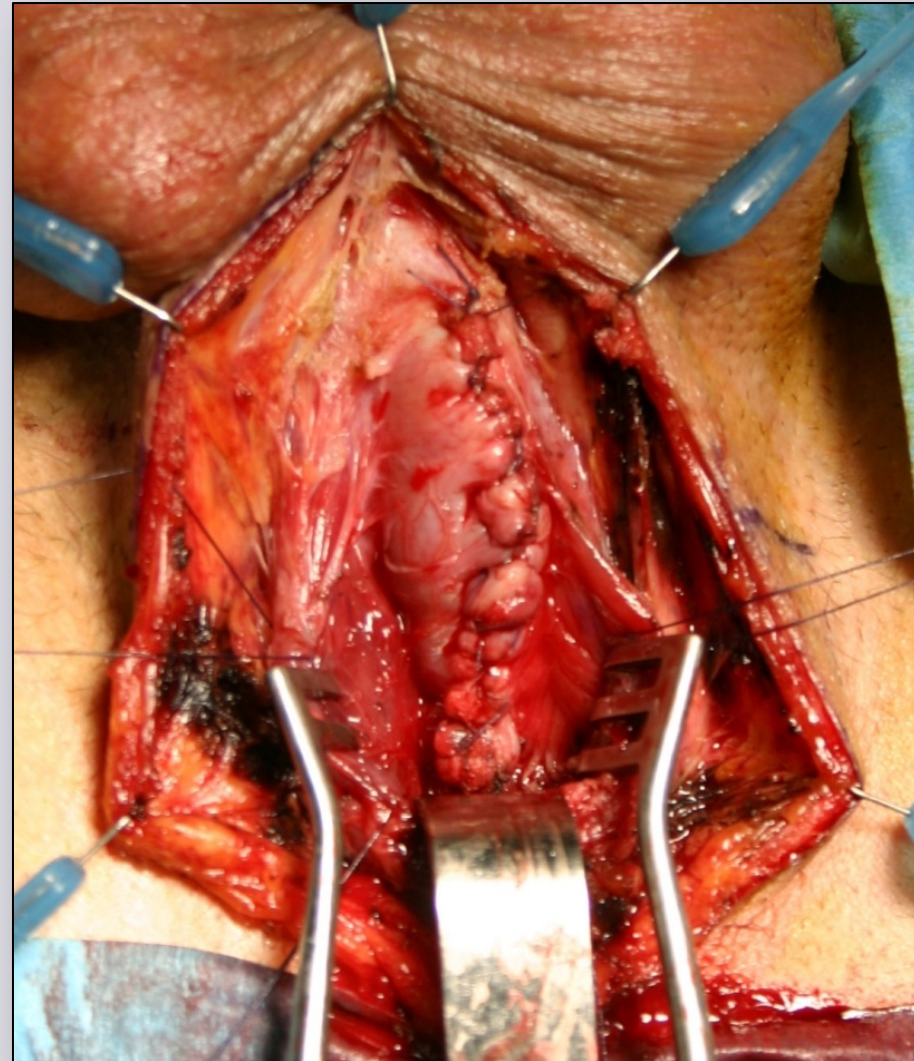
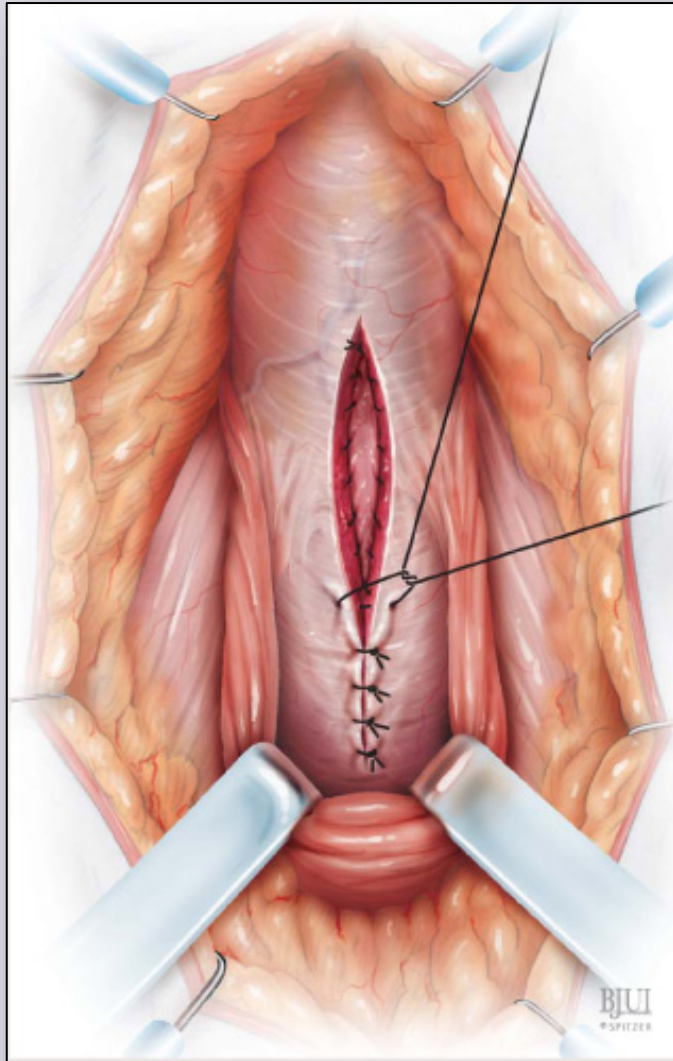
Muscle and nerve-sparing **ventral** onlay graft bulbar urethroplasty



e-mail: info@urethralcenter.it

Websites: www.uretra.it
www.urethralcenter.it

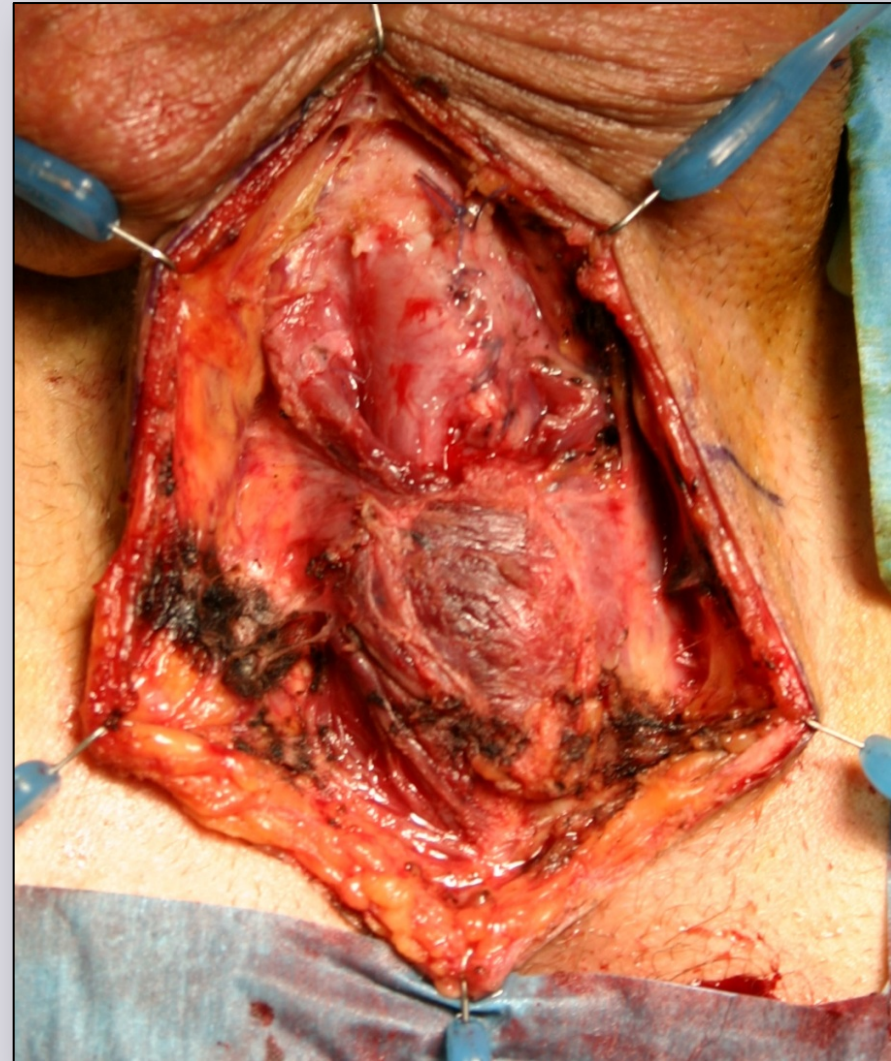
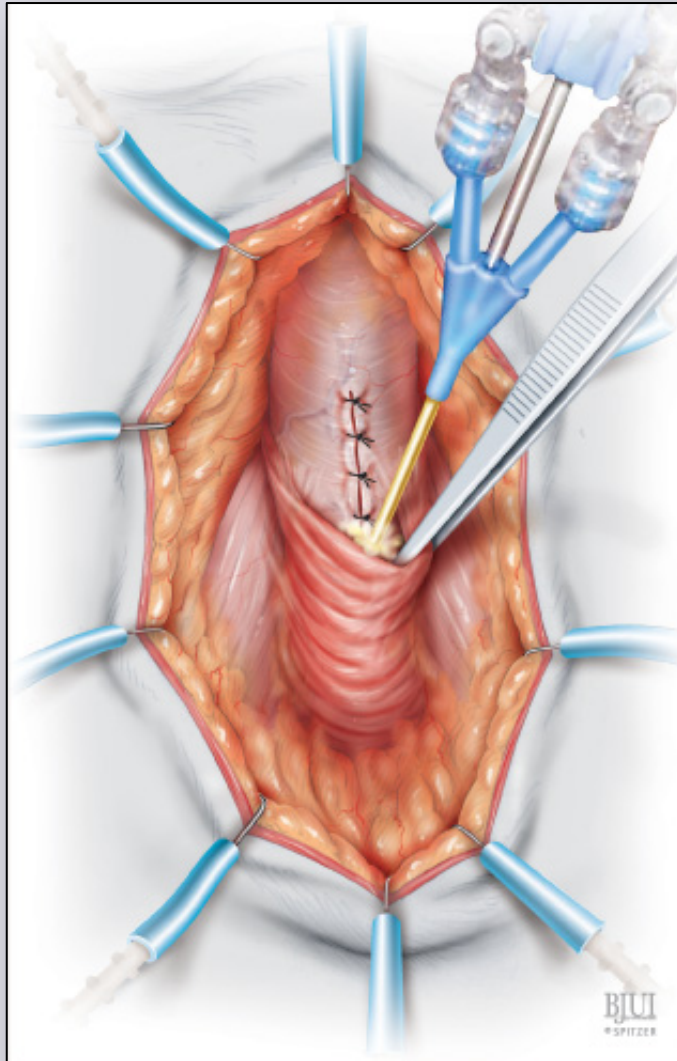
Muscle and nerve-sparing **ventral** onlay graft bulbar urethroplasty



e-mail: info@urethralcenter.it

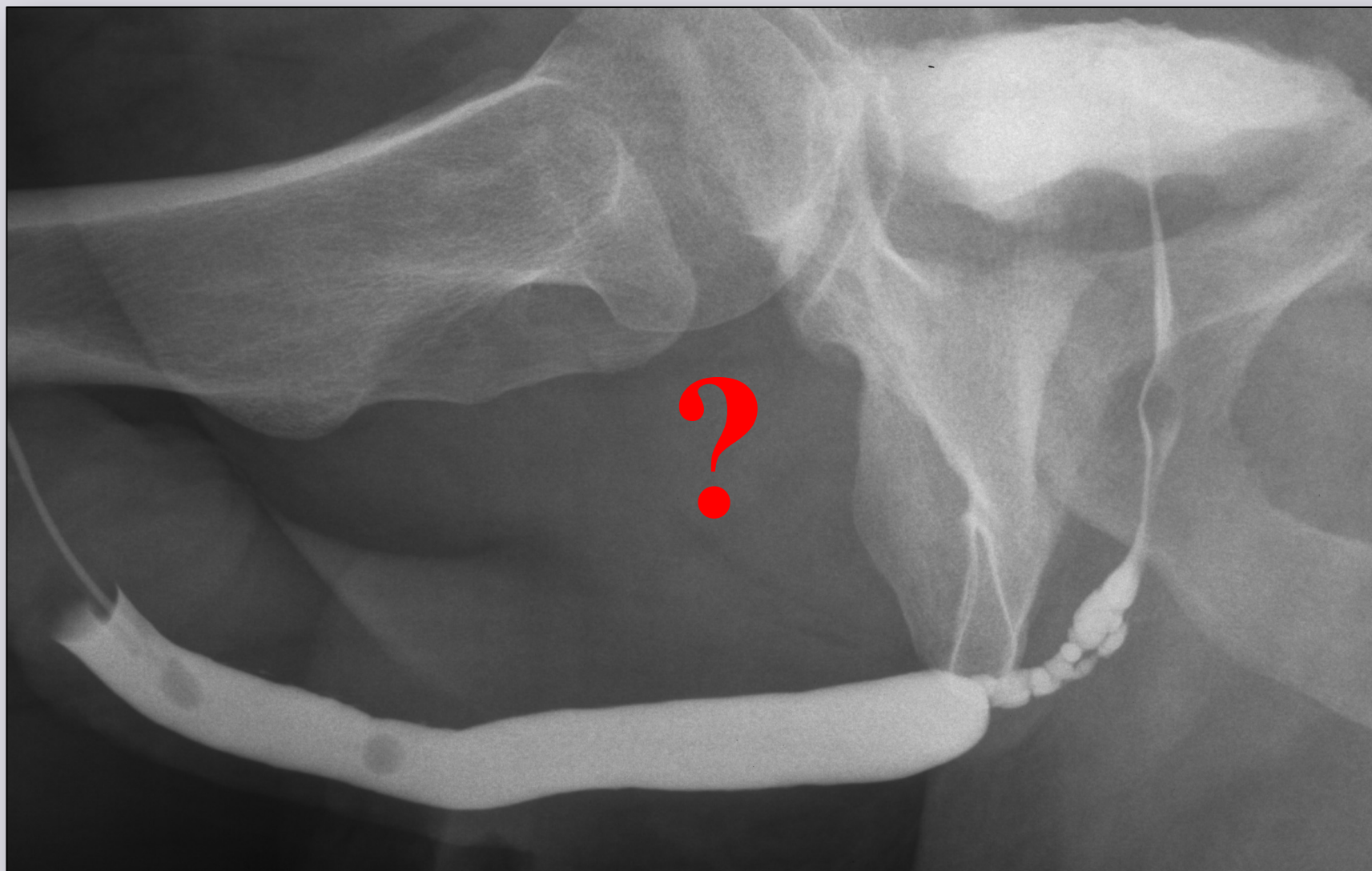
Websites: www.uretra.it
www.urethralcenter.it

Muscle and nerve-sparing **ventral** onlay graft bulbar urethroplasty



e-mail: info@urethralcenter.it

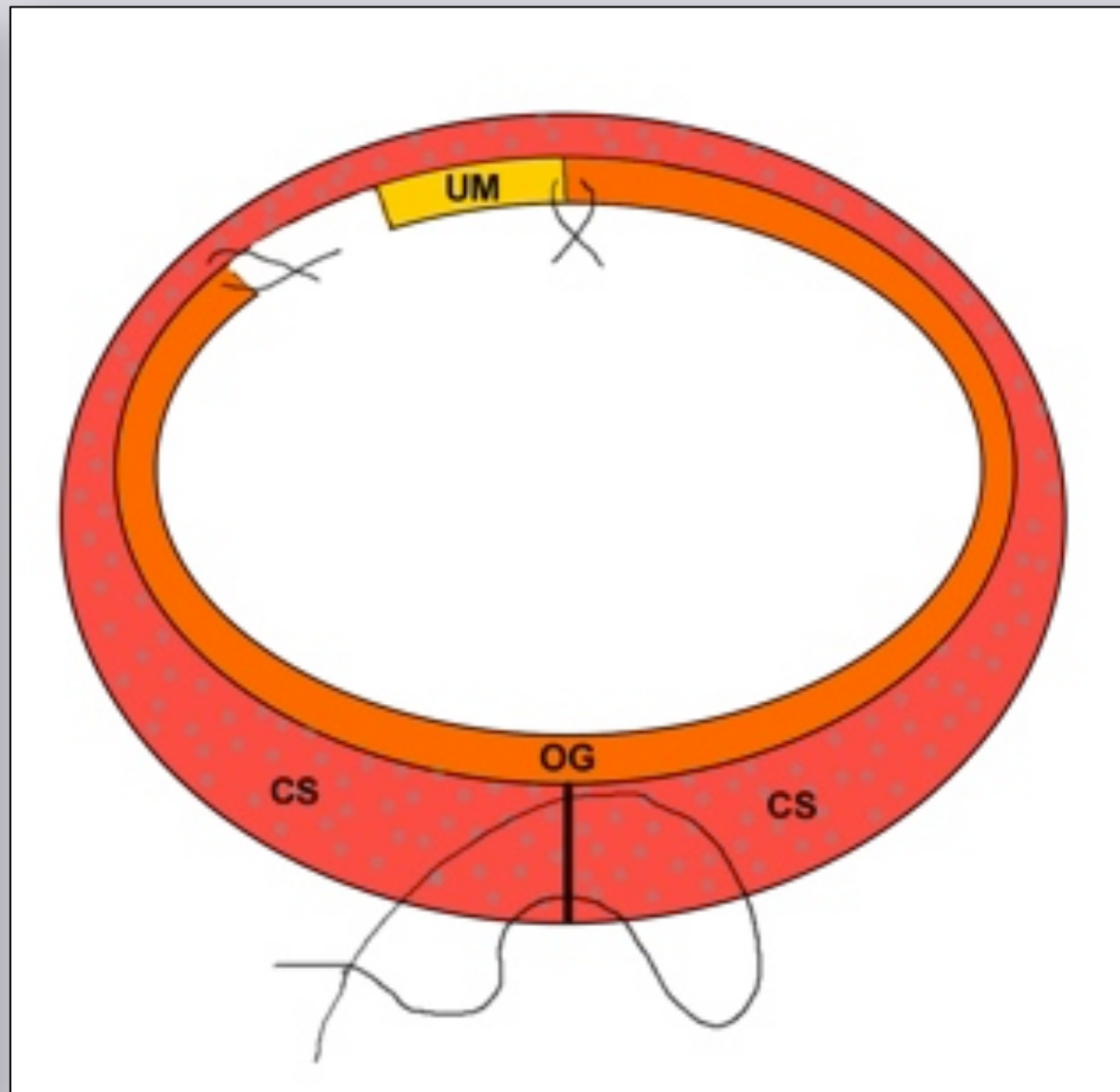
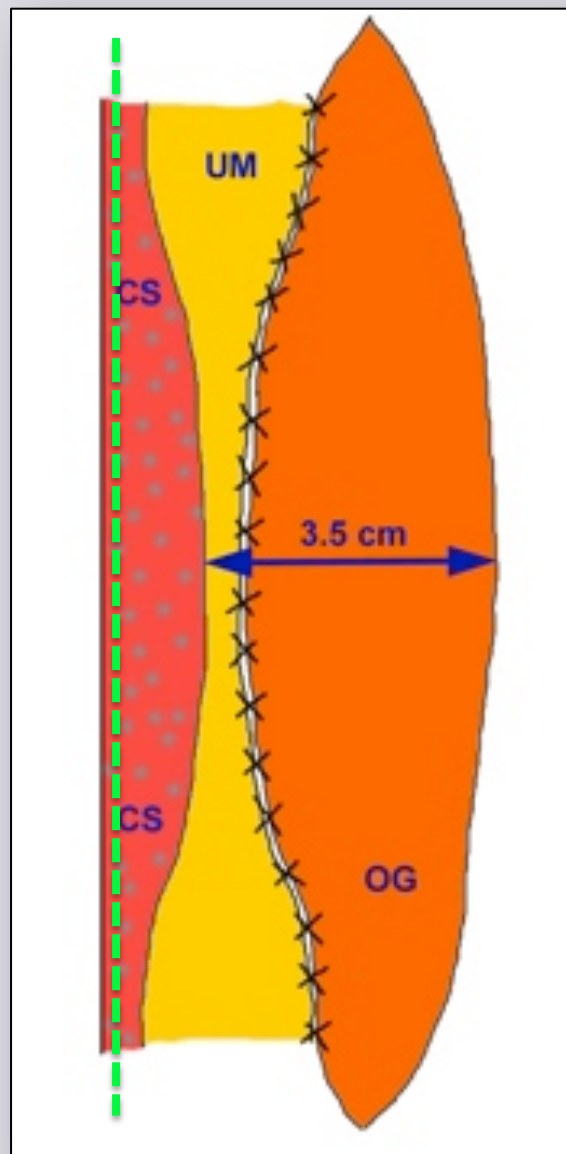
Websites: www.uretra.it
www.urethralcenter.it

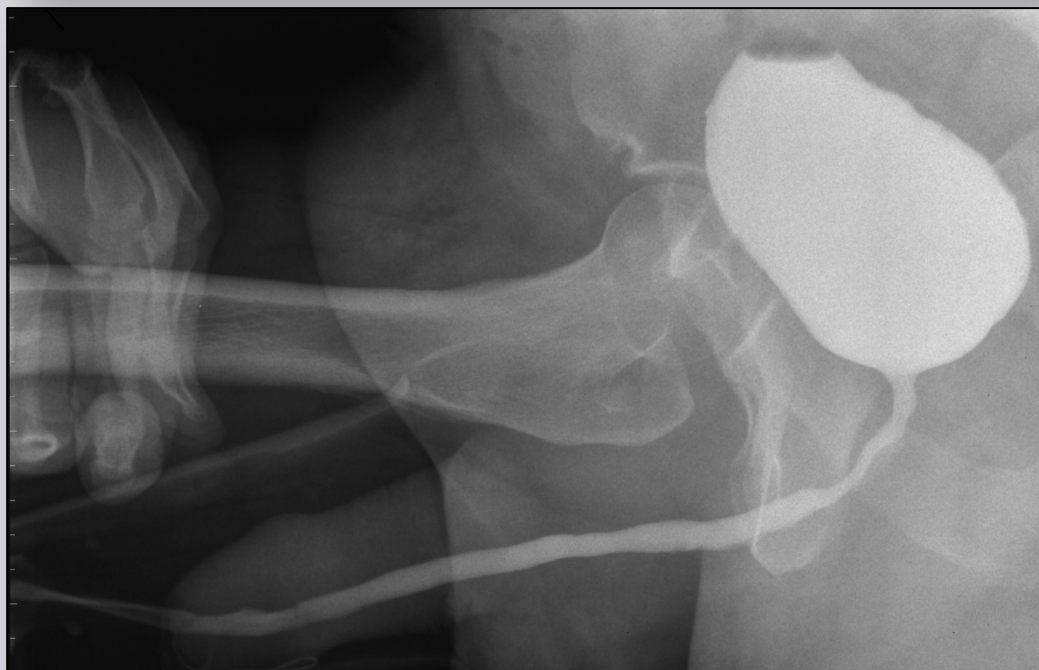
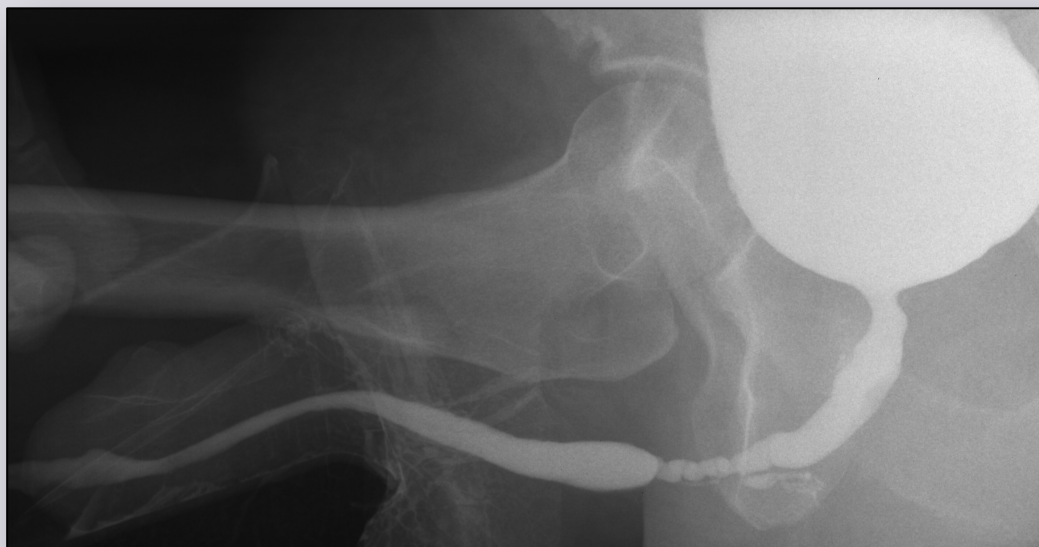

e-mail: info@urethralcenter.it

Websites: www.uretra.it
www.urethralcenter.it

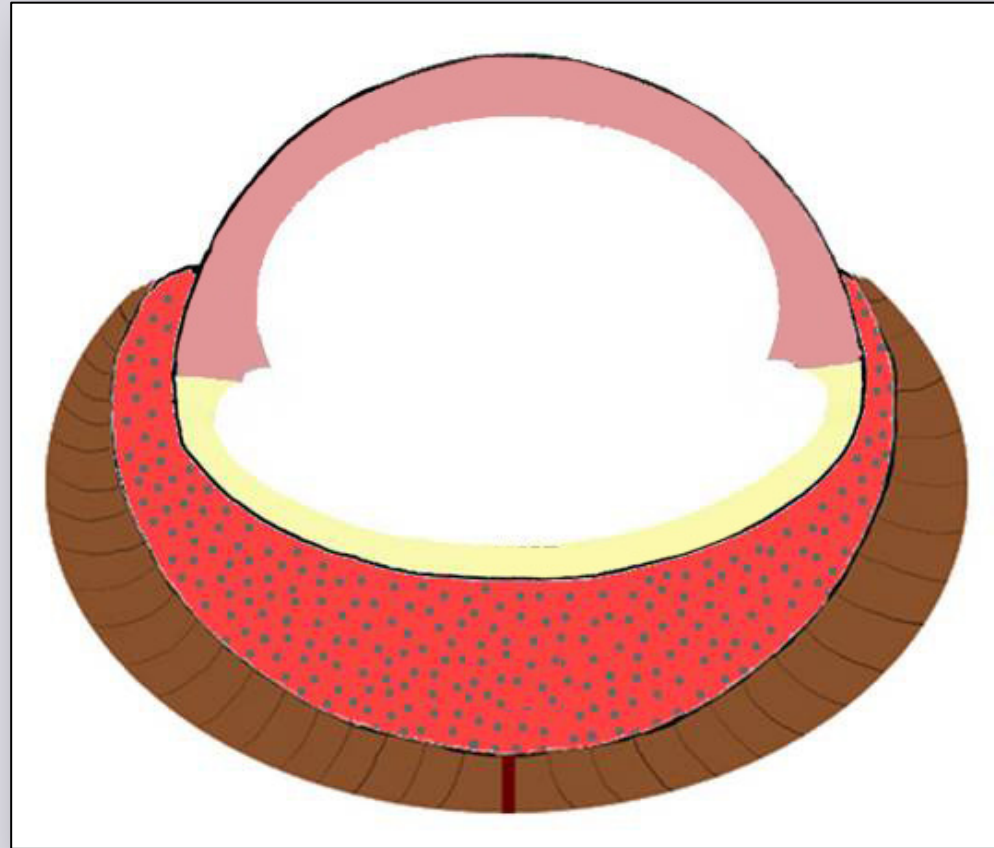
CENTER FOR RECONSTRUCTIVE URETHRAL SURGERY





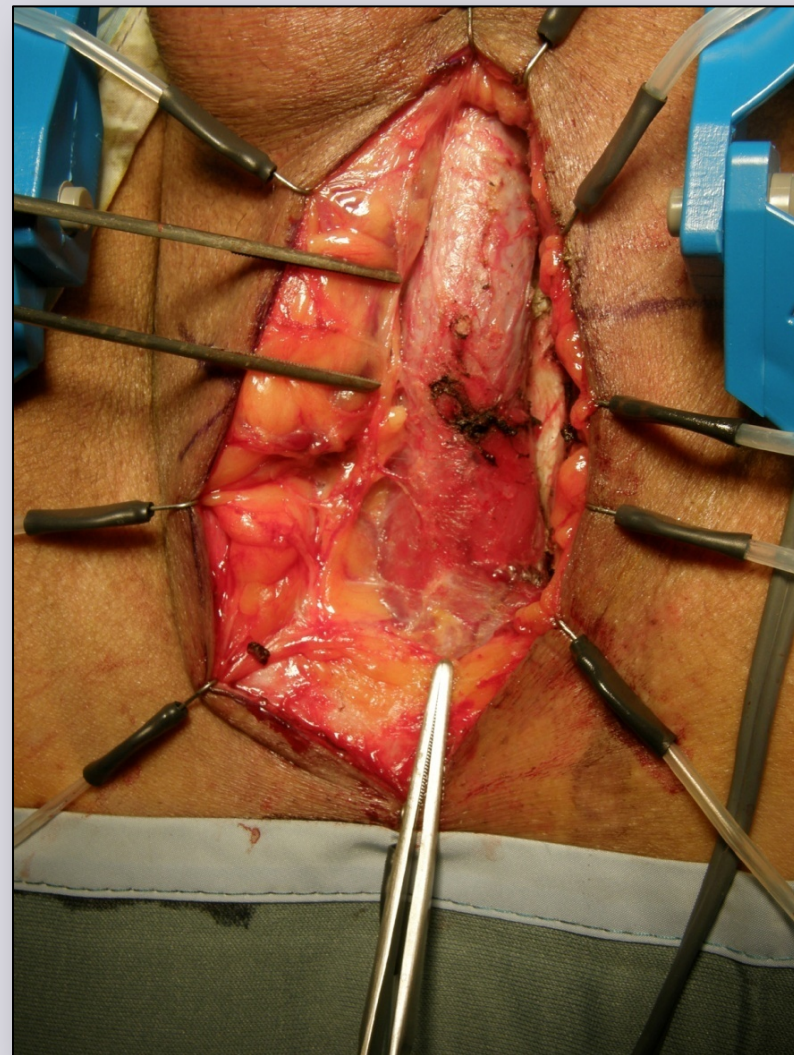
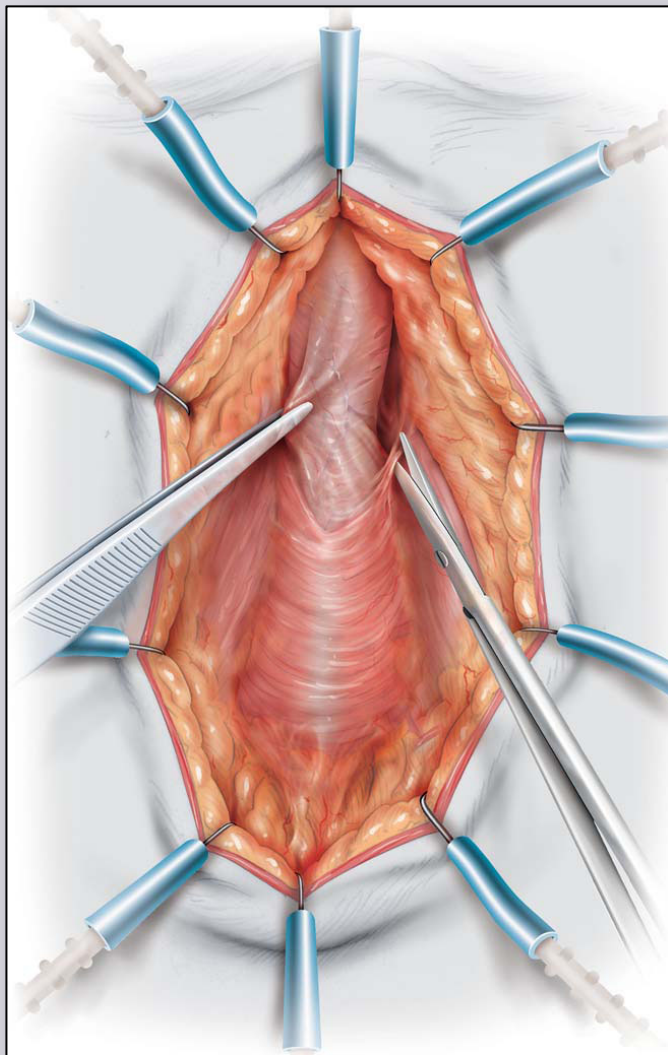
e-mail: info@urethralcenter.it

Websites: www.uretra.it
www.urethralcenter.it



Muscle and nerve-sparing dorsal onlay graft bulbar urethroplasty

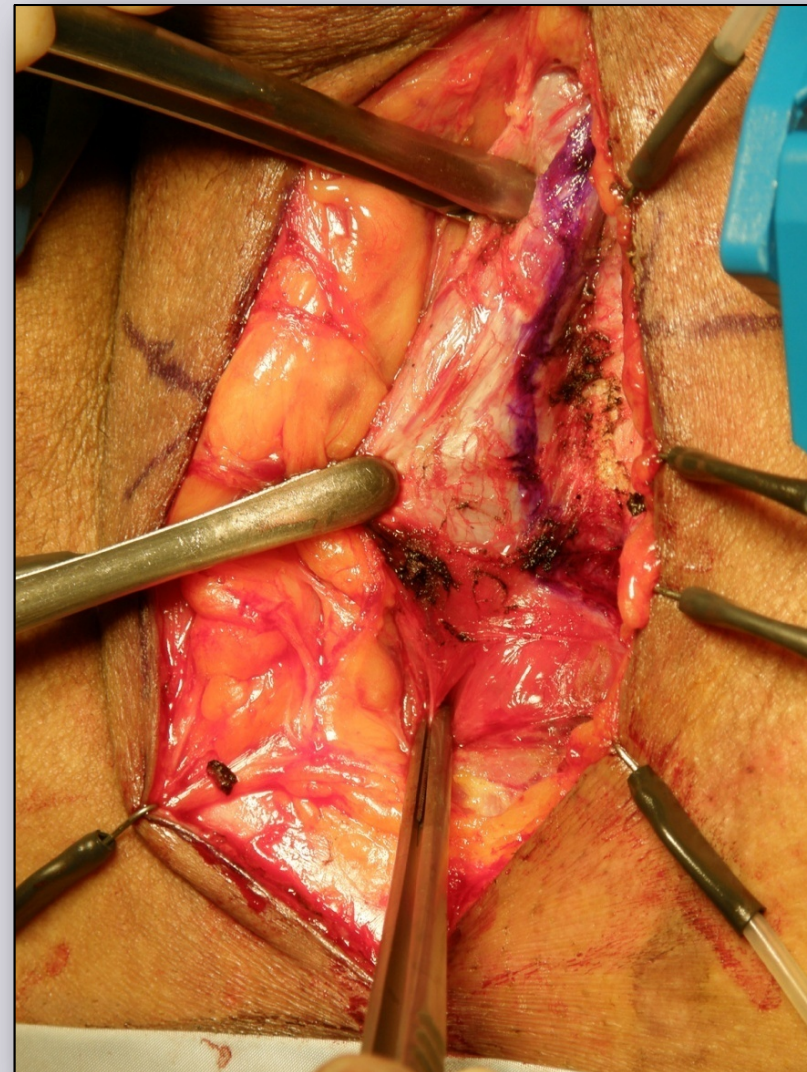
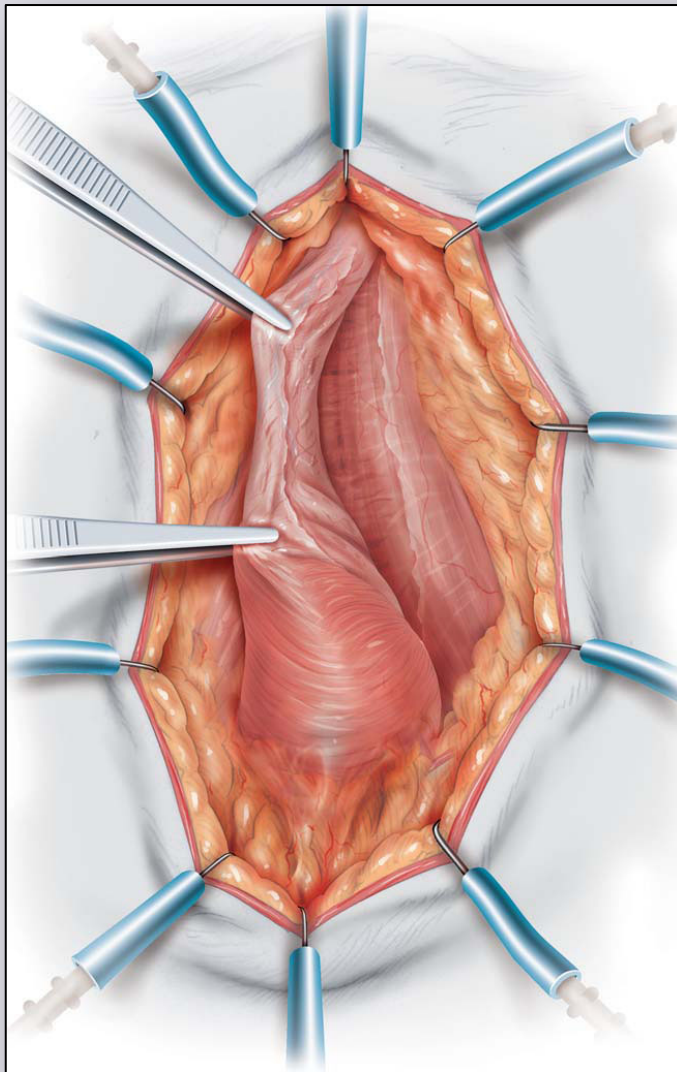
Muscle and nerve-sparing **dorsal** onlay graft bulbar urethroplasty



e-mail: info@urethralcenter.it

Websites: www.uretra.it
www.urethralcenter.it

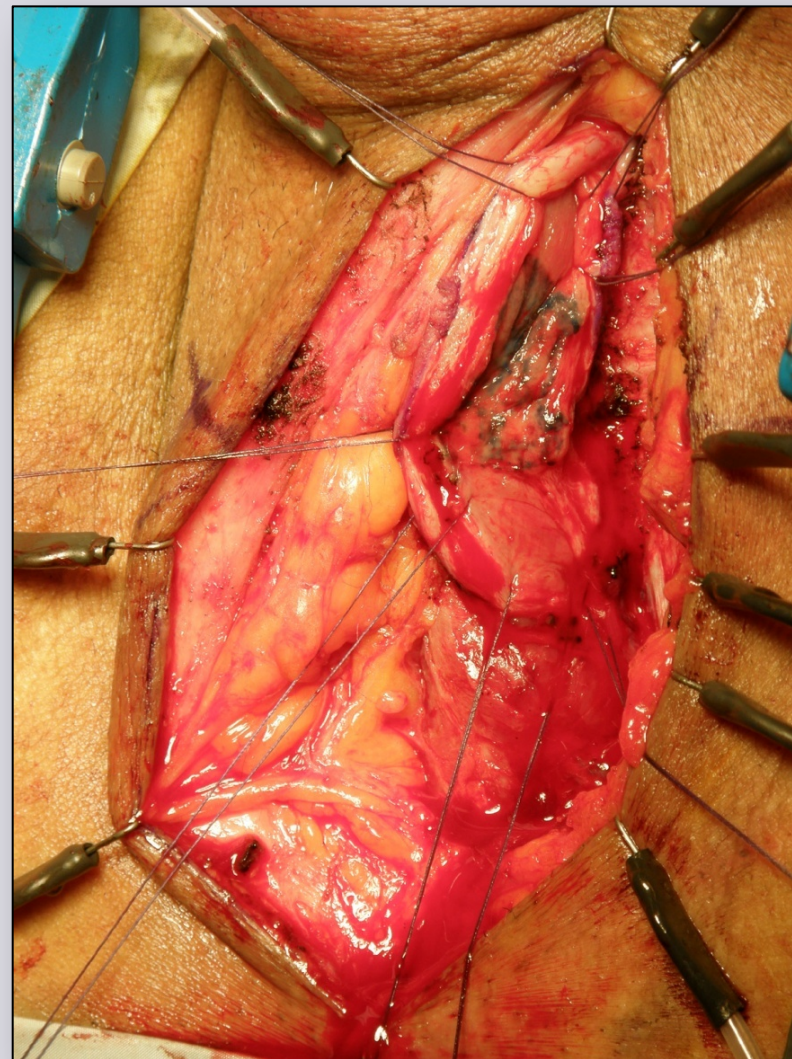
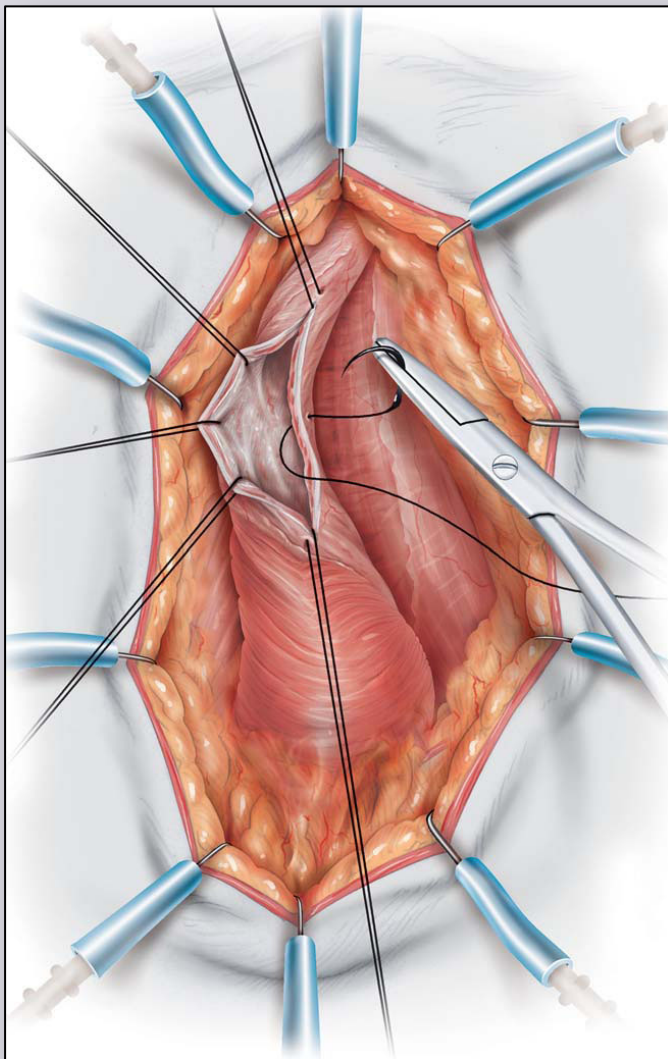
Muscle and nerve-sparing **dorsal** onlay graft bulbar urethroplasty



e-mail: info@urethralcenter.it

Websites: www.uretra.it
www.urethralcenter.it

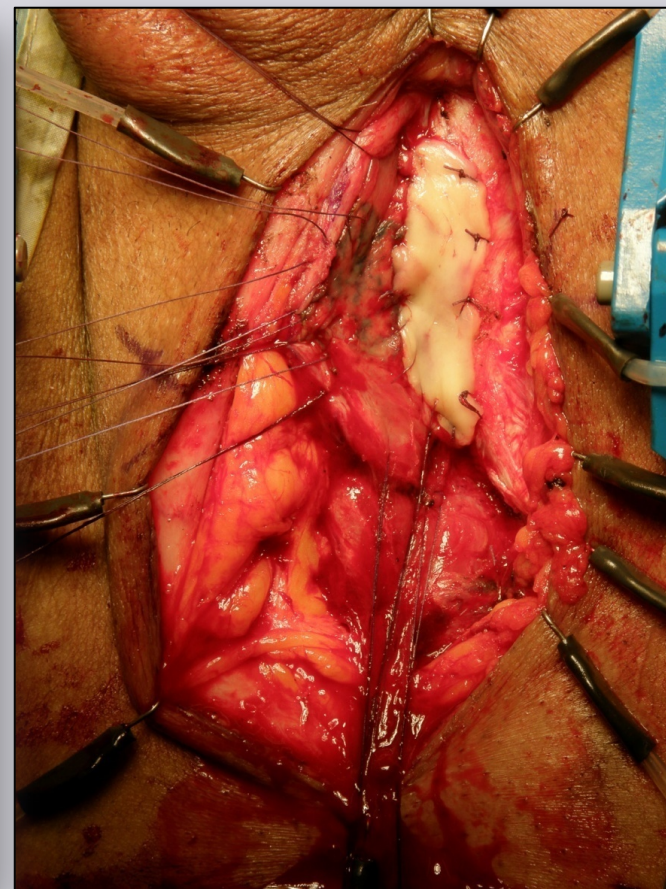
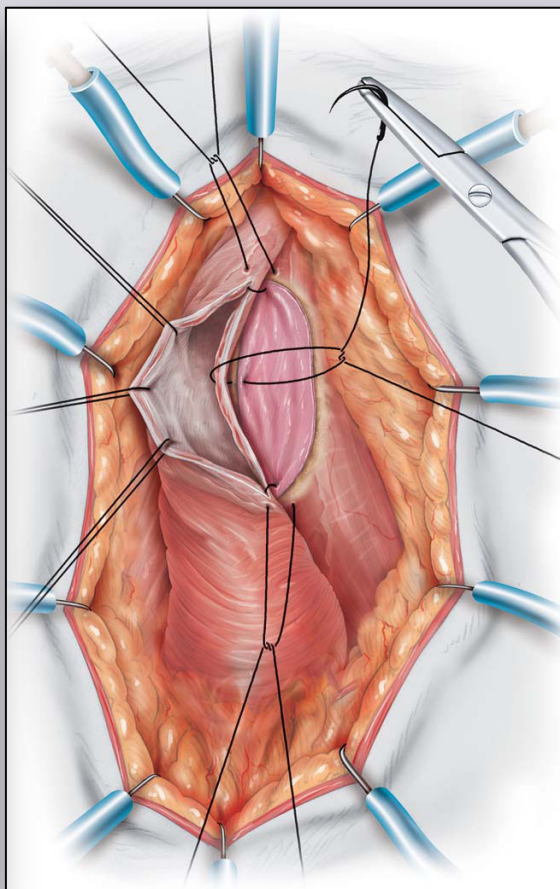
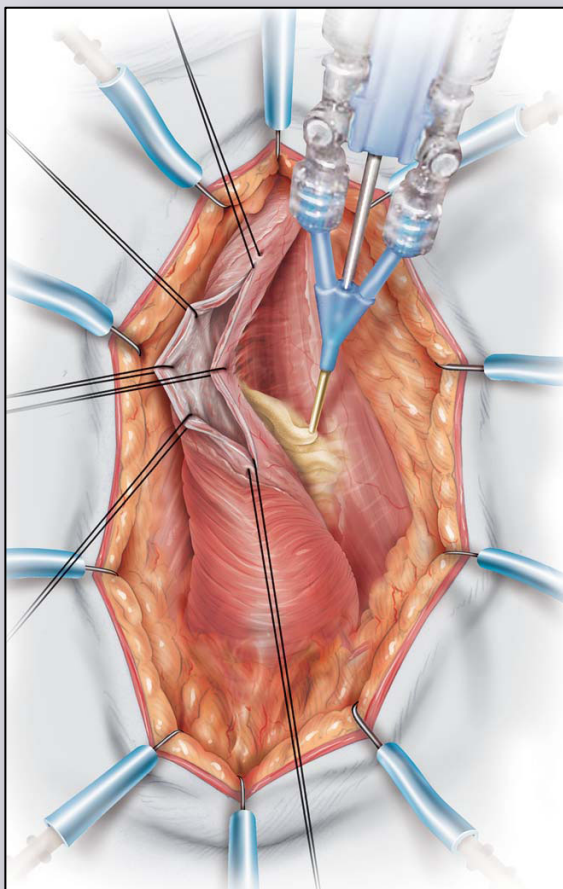
Muscle and nerve-sparing **dorsal** onlay graft bulbar urethroplasty



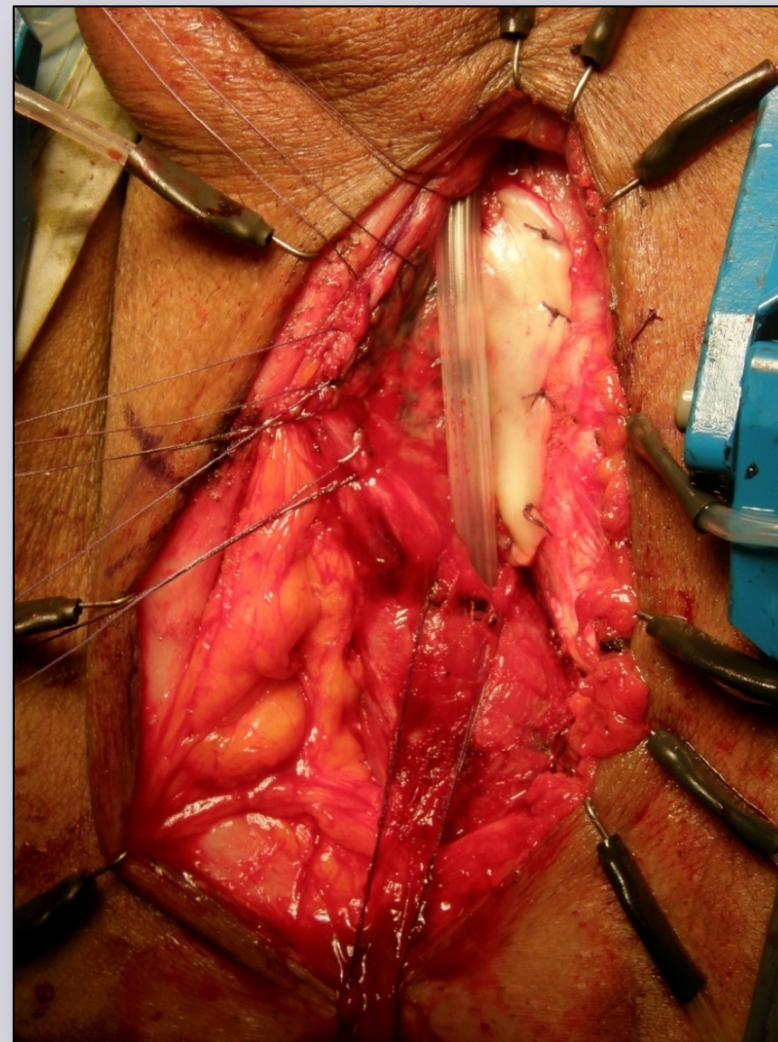
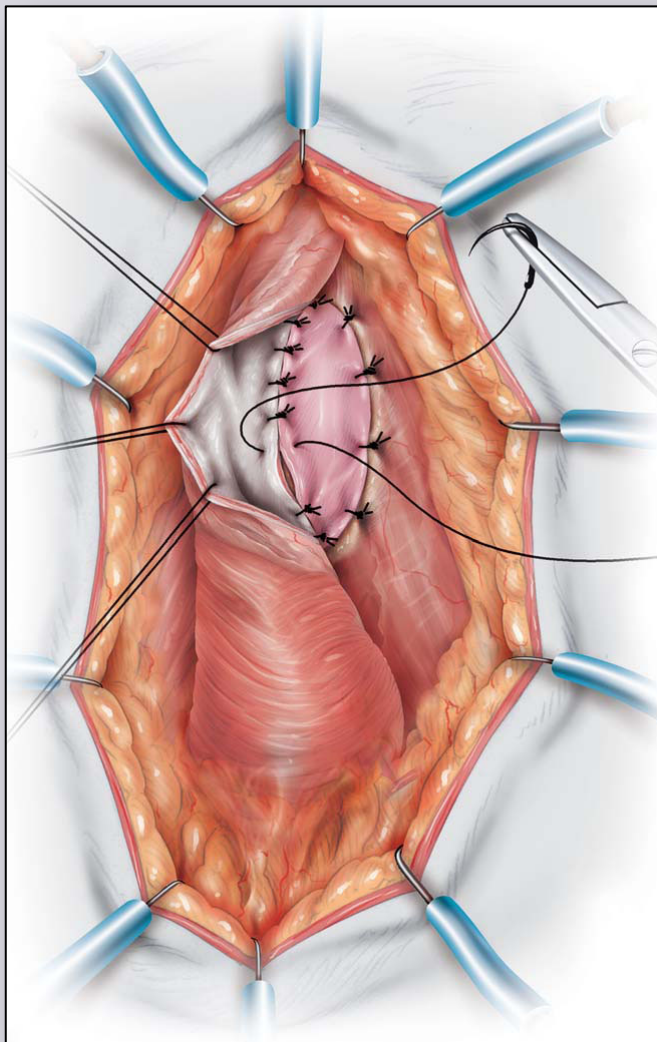
e-mail: info@urethralcenter.it

Websites: www.uretra.it
www.urethralcenter.it

Muscle and nerve-sparing **dorsal** onlay graft bulbar urethroplasty



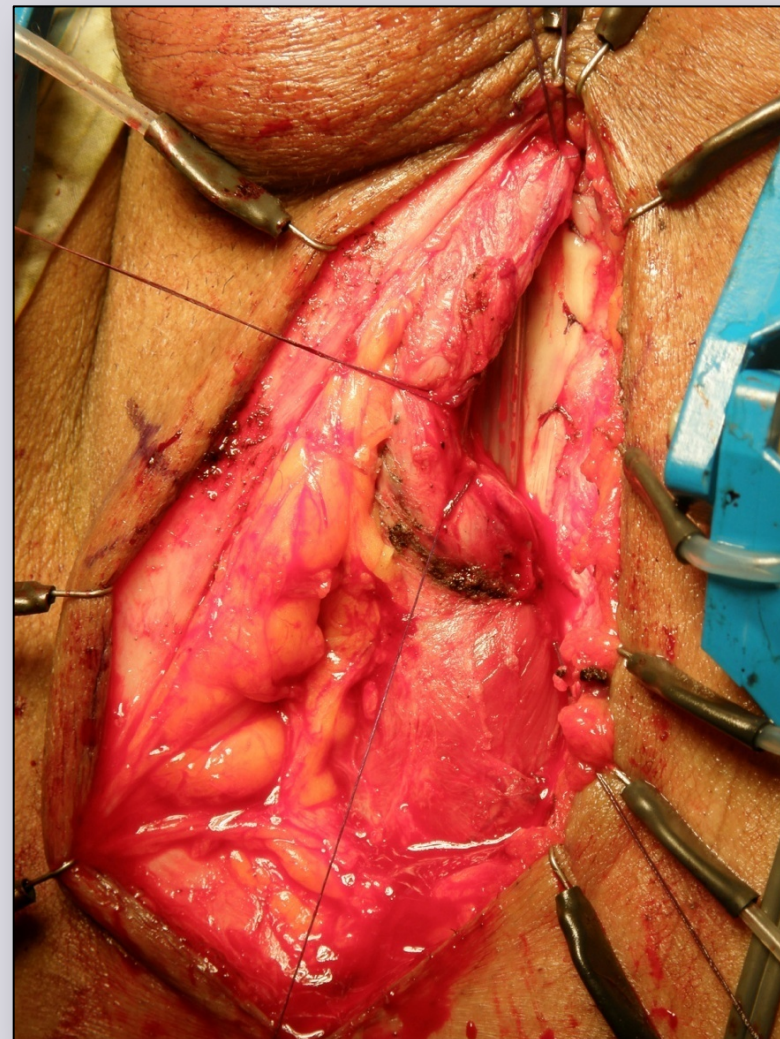
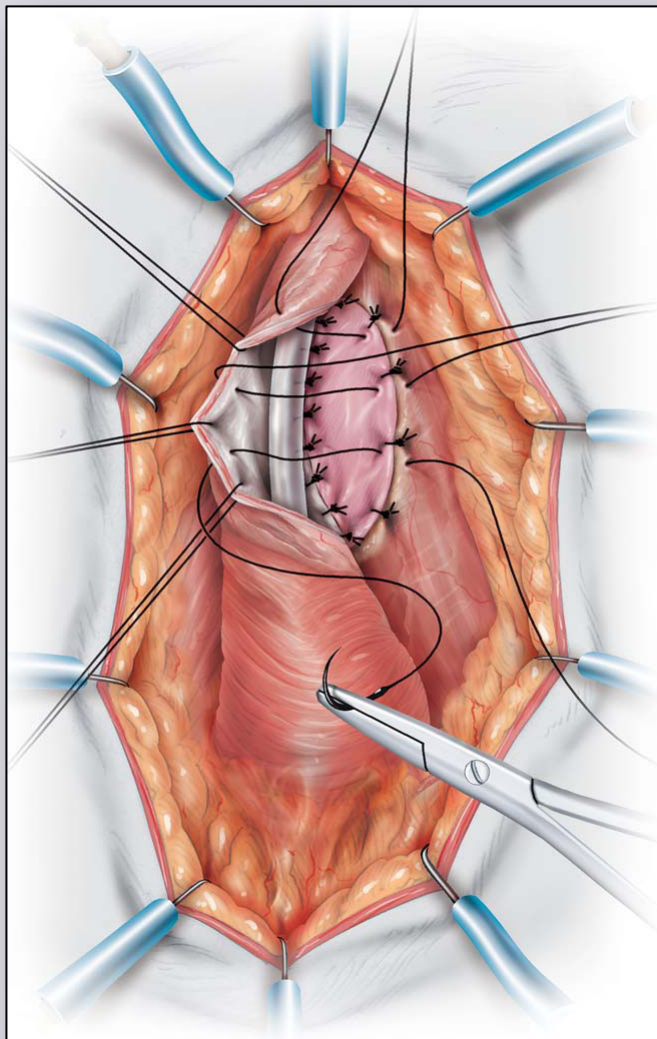
Muscle and nerve-sparing **dorsal** onlay graft bulbar urethroplasty



e-mail: info@urethralcenter.it

Websites: www.uretra.it
www.urethralcenter.it

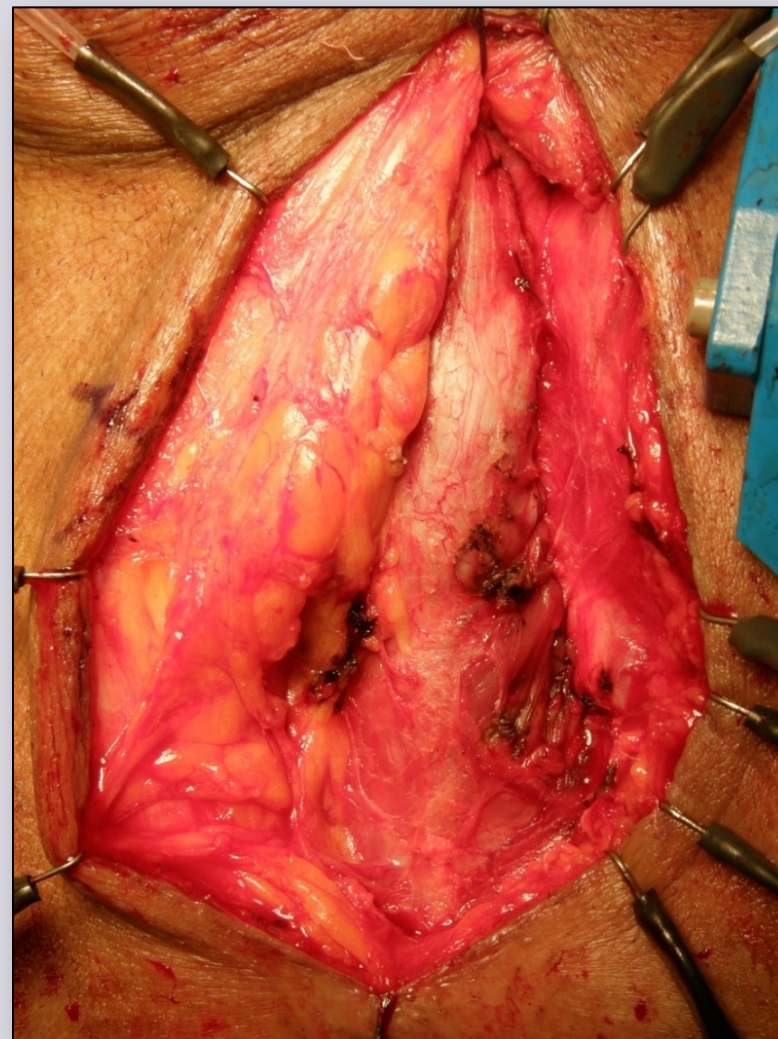
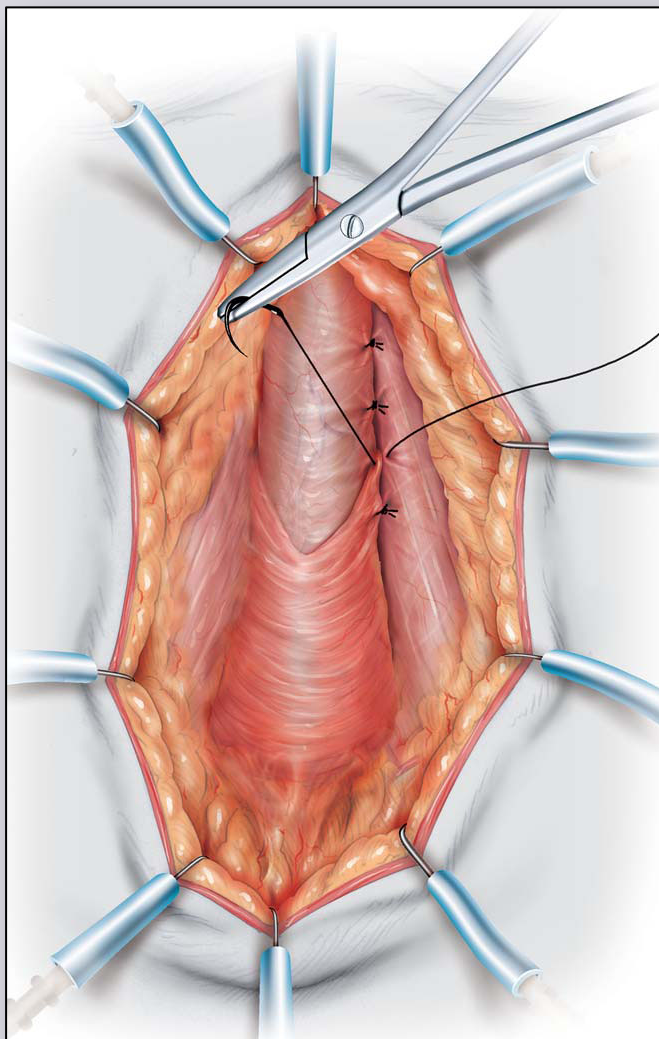
Muscle and nerve-sparing **dorsal** onlay graft bulbar urethroplasty



e-mail: info@urethralcenter.it

Websites: www.uretra.it
www.urethralcenter.it

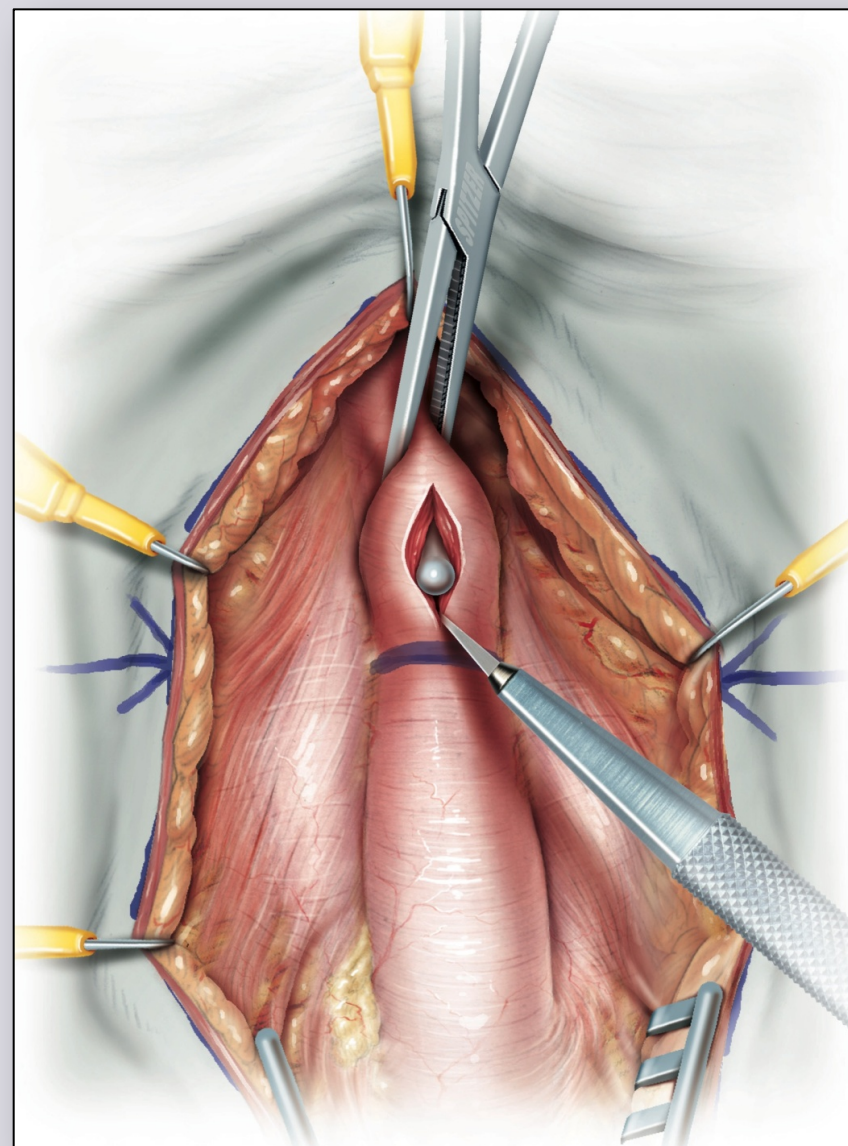
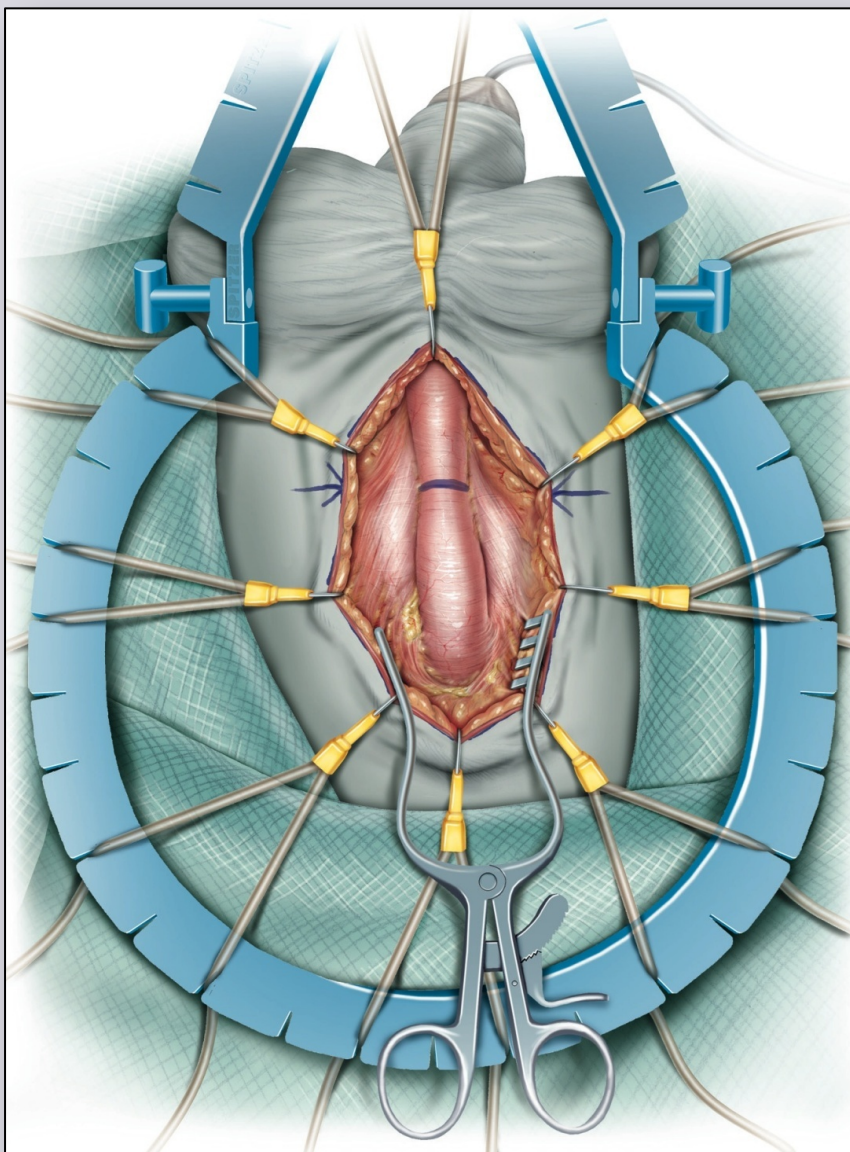
Muscle and nerve-sparing **dorsal** onlay graft bulbar urethroplasty



e-mail: info@urethralcenter.it

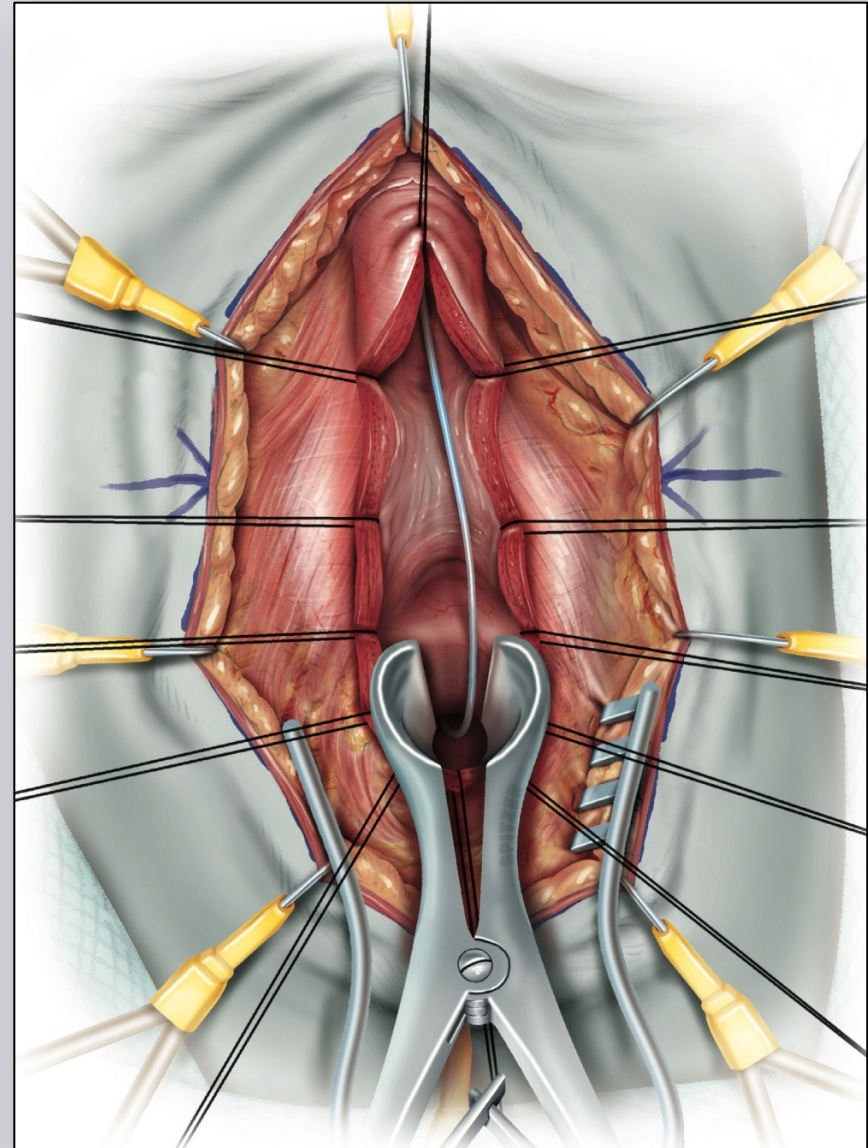
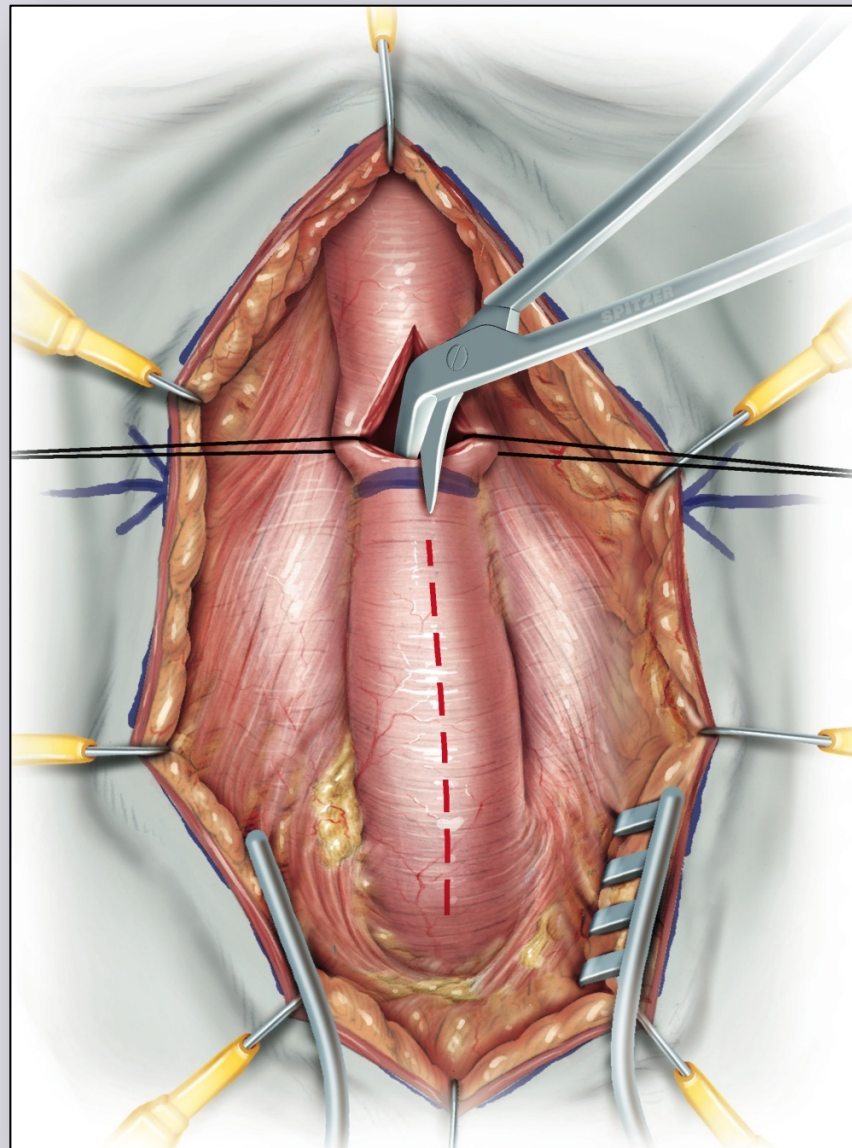
Websites: www.uretra.it
www.urethralcenter.it

Reconstruction of the bulbar urethra after previous failed urethroplasty



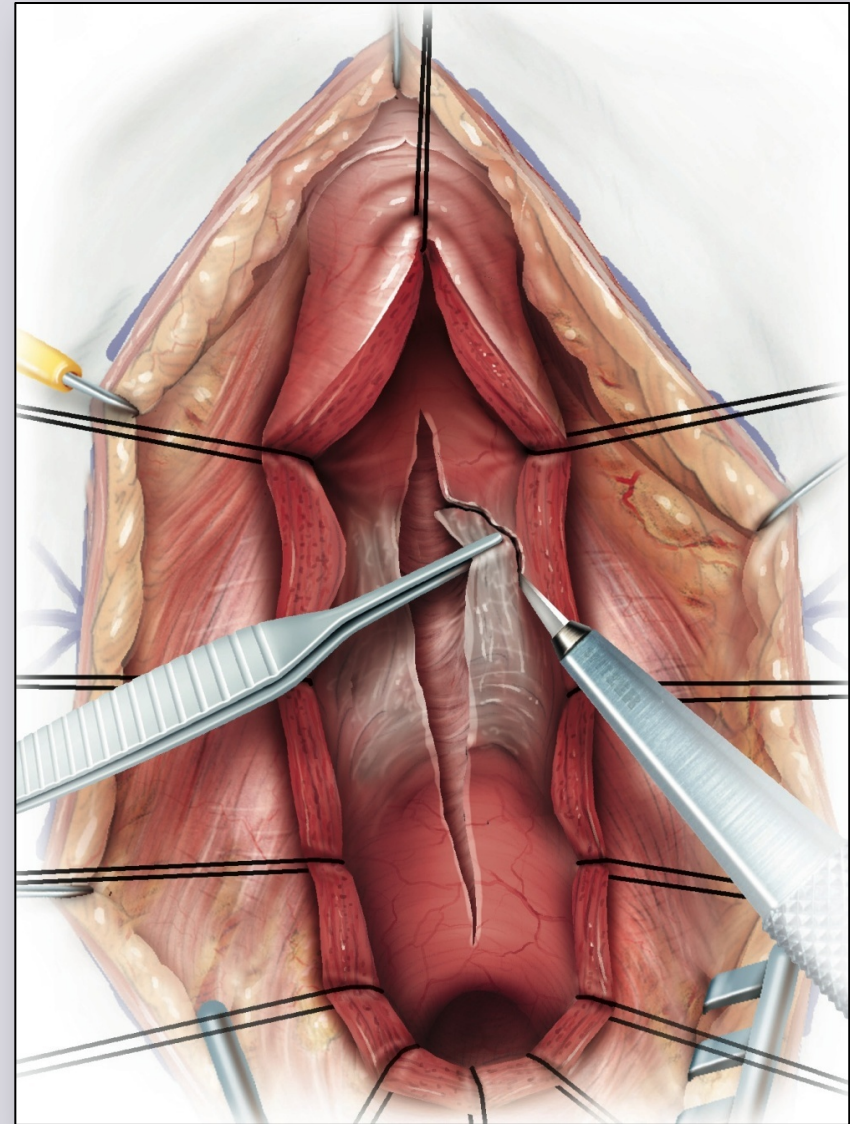
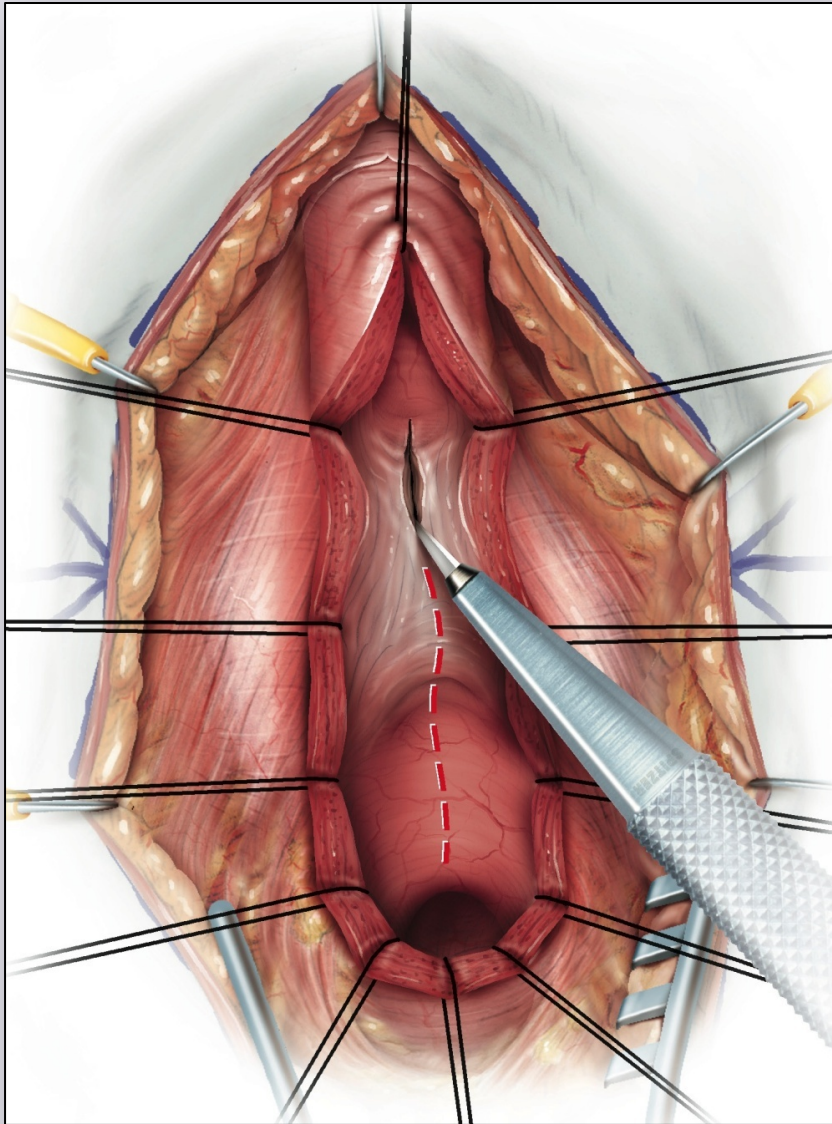
e-mail: info@urethralcenter.it

Websites: www.uretra.it
www.urethralcenter.it



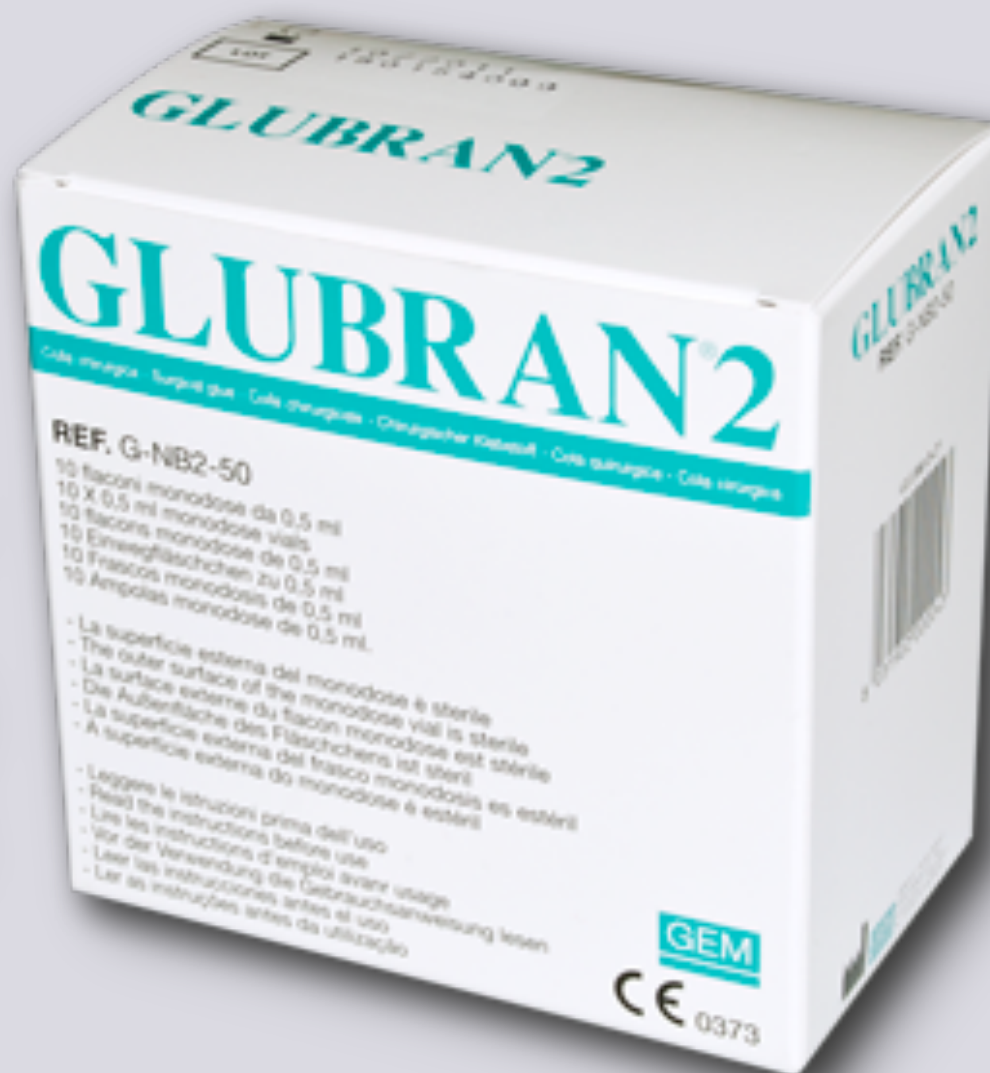e-mail: info@urethralcenter.it

Websites: www.uretra.it
www.urethralcenter.it



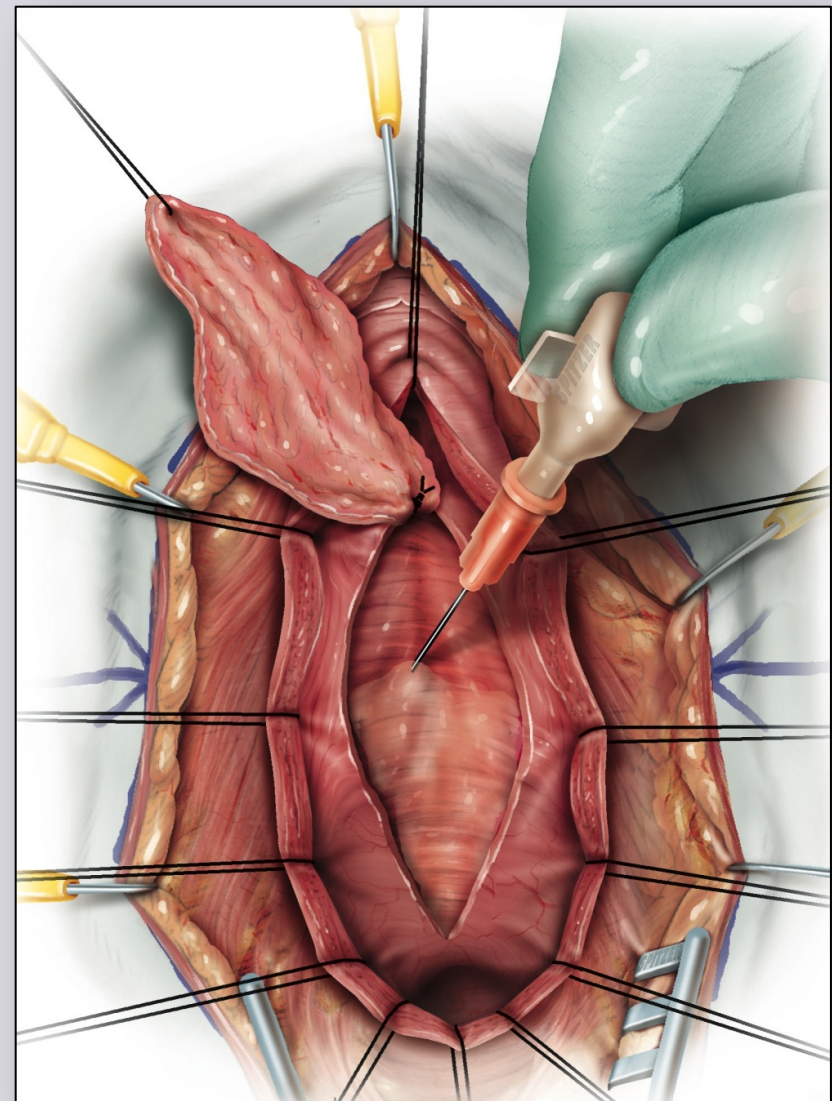
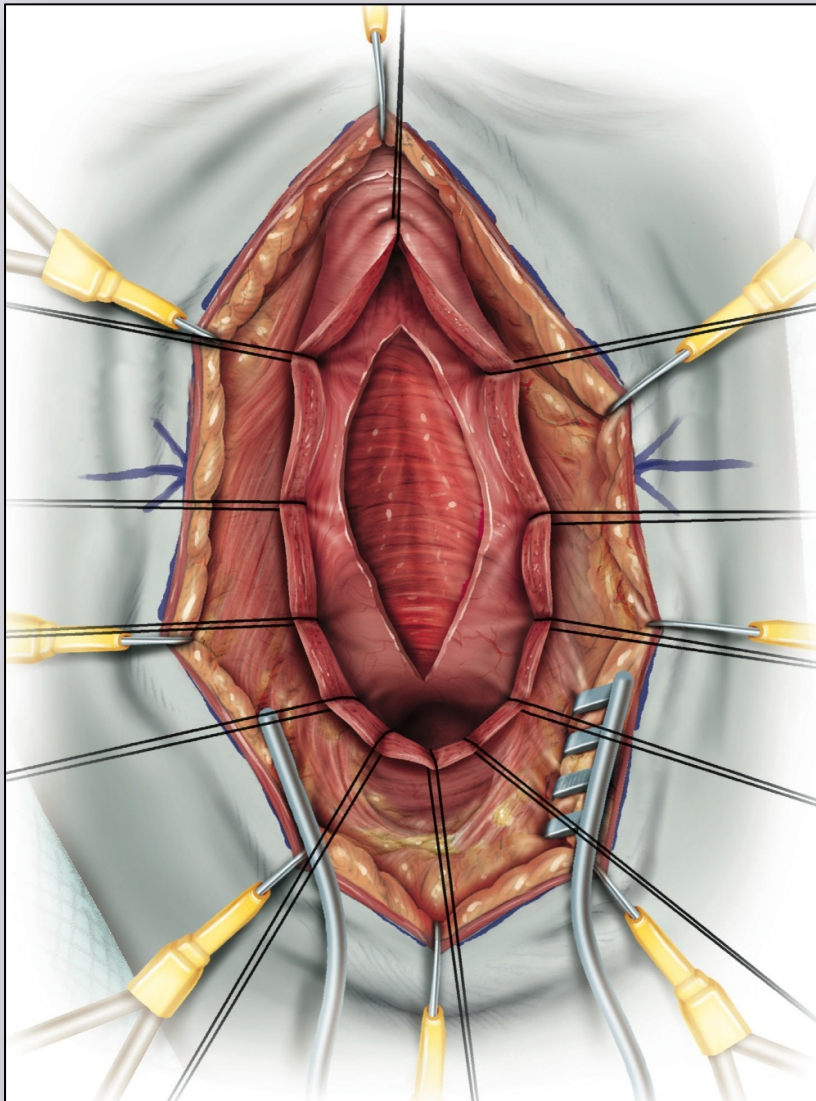
e-mail: info@urethralcenter.it

Websites: www.uretra.it
www.urethralcenter.it



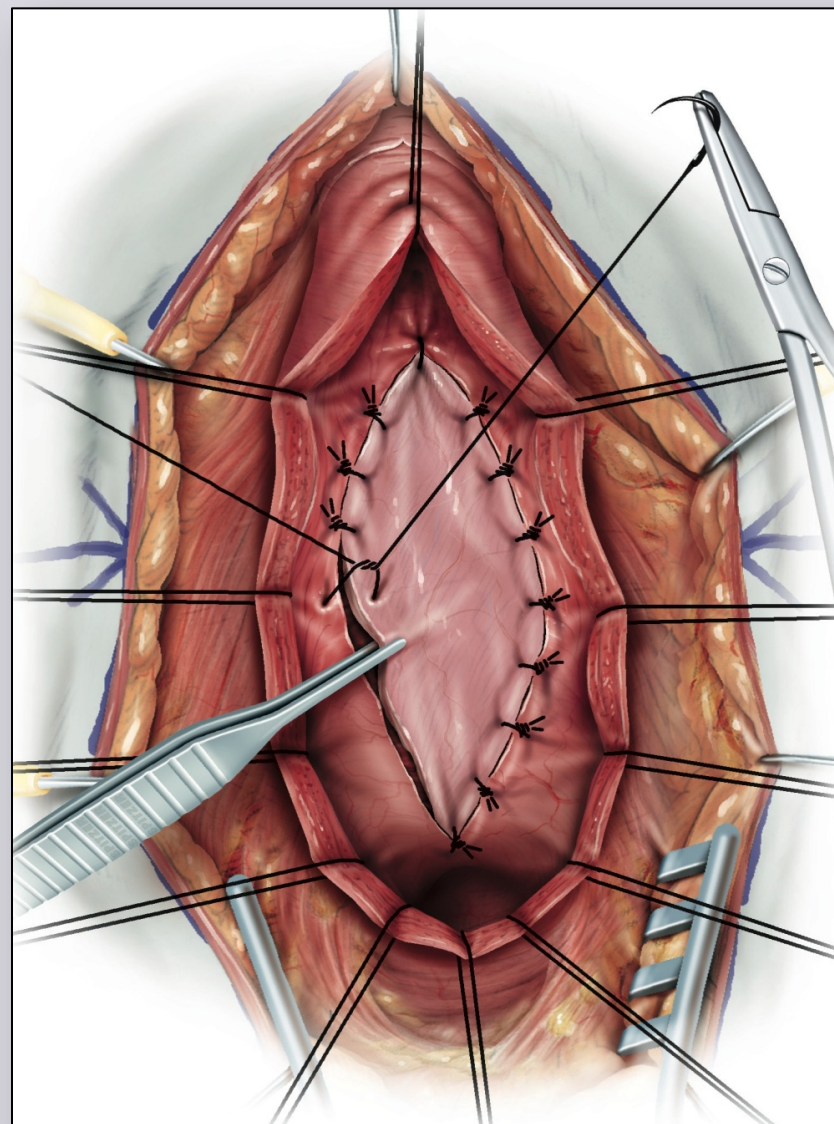
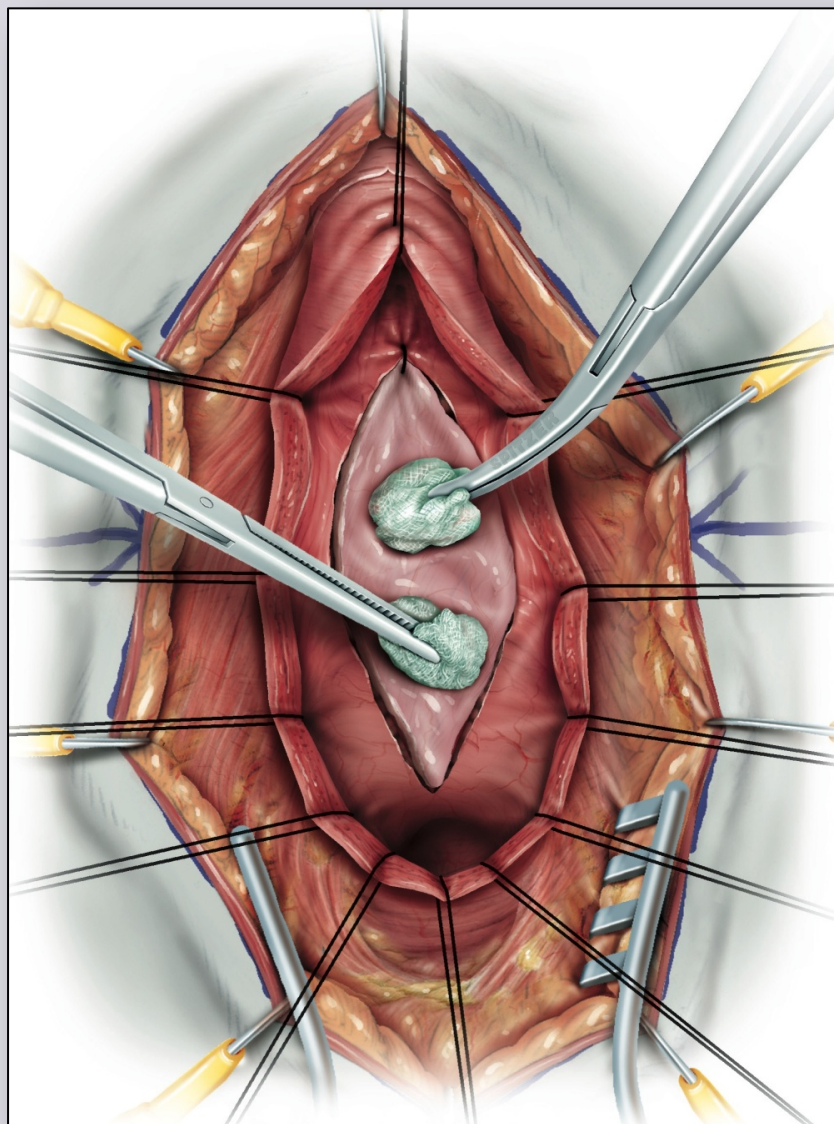
e-mail: info@urethralcenter.it

Websites: www.uretra.it
www.urethralcenter.it



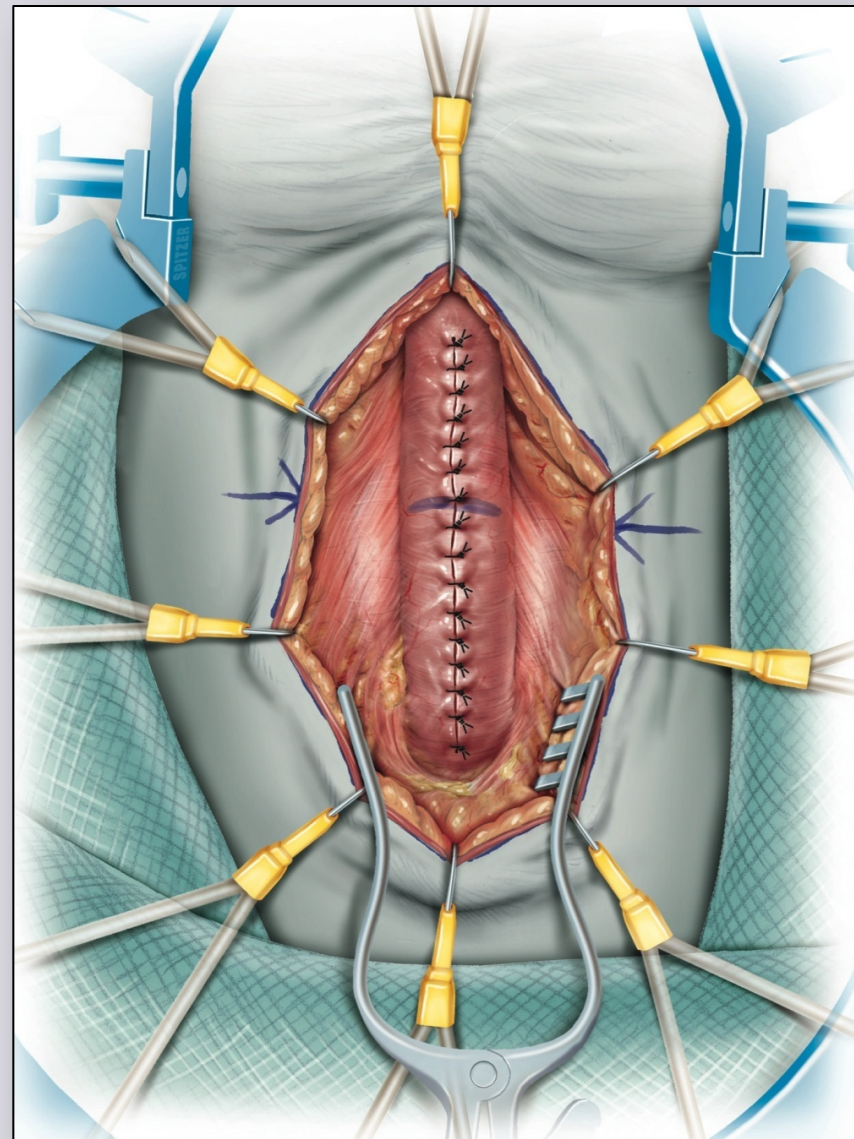
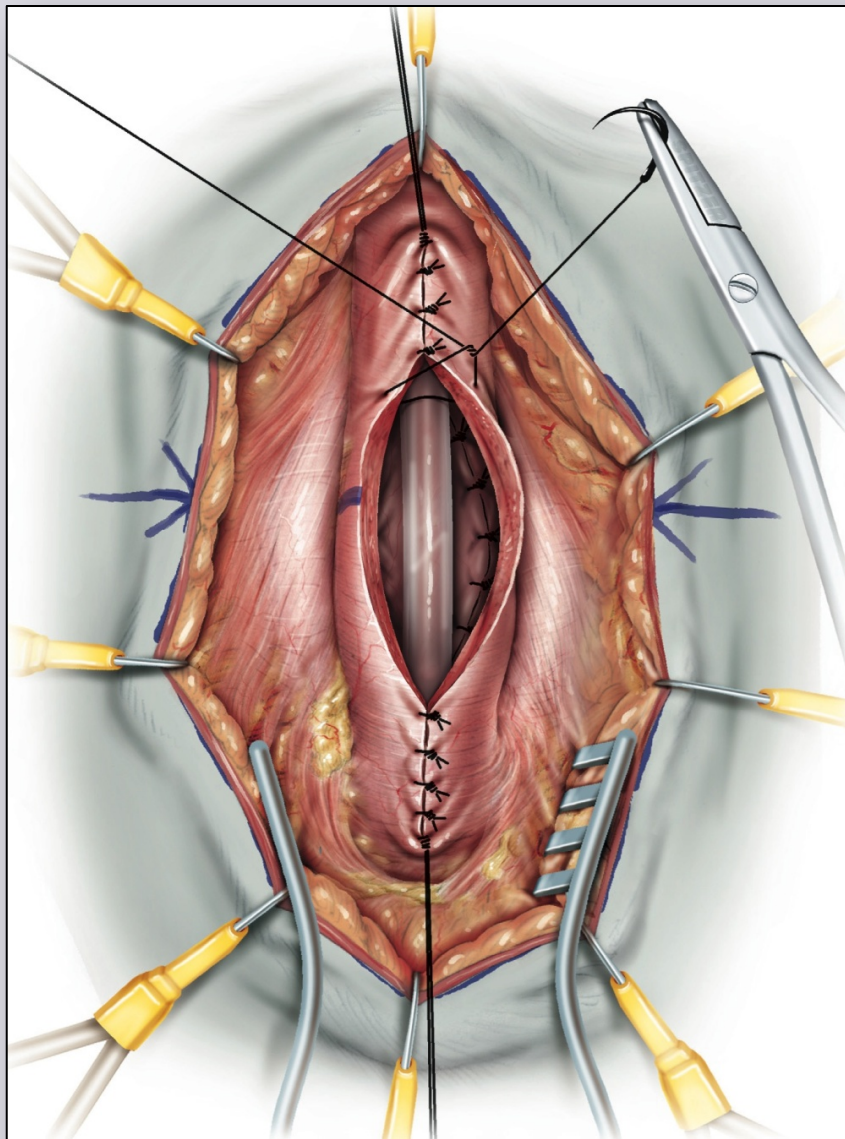
e-mail: info@urethralcenter.it

Websites: www.uretra.it
www.urethralcenter.it



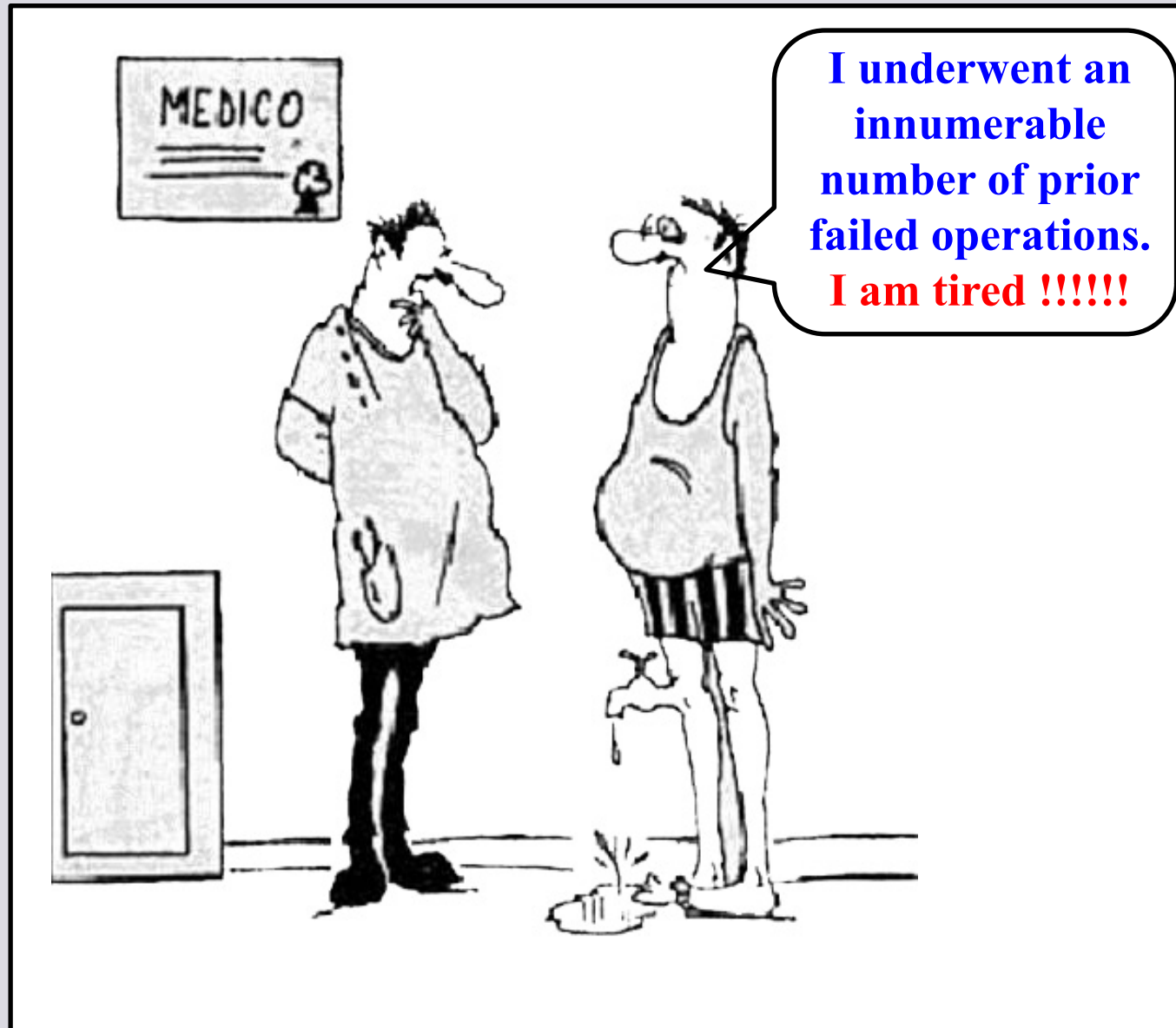e-mail: info@urethralcenter.it

Websites: www.uretra.it
www.urethralcenter.it

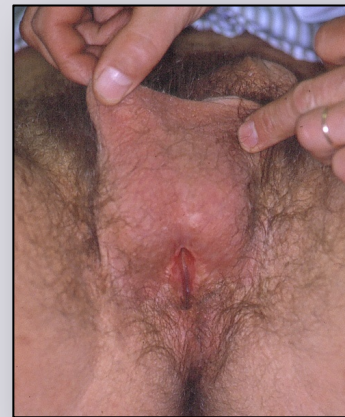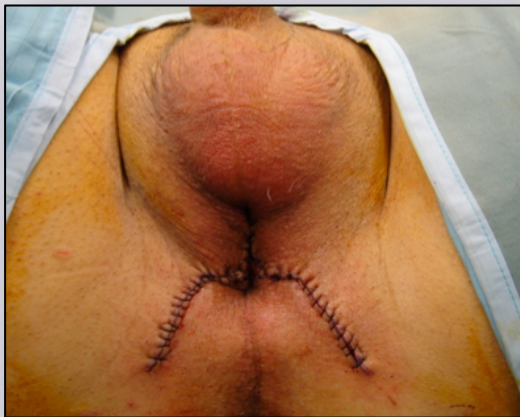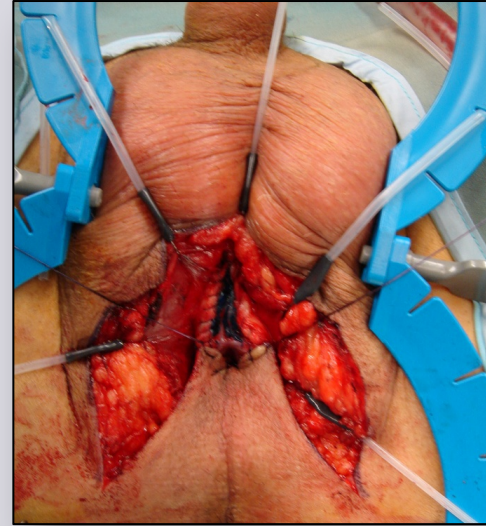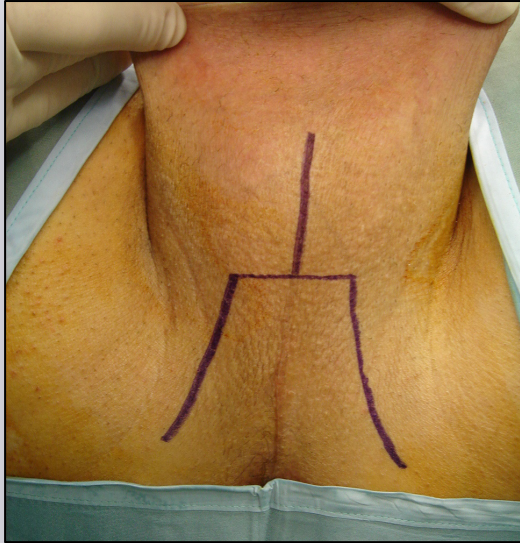


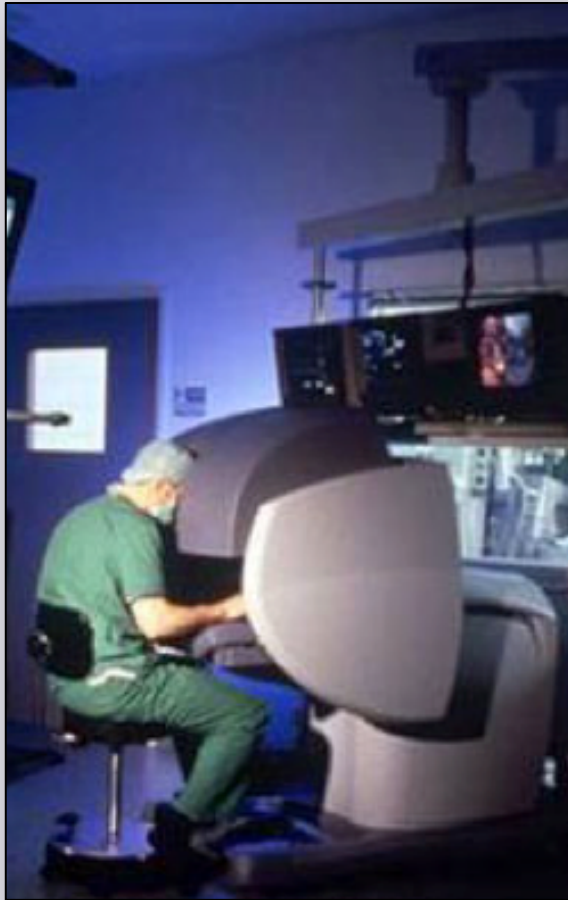e-mail: info@urethralcenter.it

Websites: www.uretra.it
www.urethralcenter.it



Definitive perineal urethrostomy





Conclusions

In the era of robotic surgery, it is also time to change urethral surgery!

- ❖ **Increase the use of minimally invasive techniques in urethroplasty, reducing the incidence of complications and improving patient quality of life.**



Register now !

www.webon.uretra.it

e-mail: info@urethralcenter.it

Websites: www.uretra.it
www.urethralcenter.it