

Center for Reconstructive Urethral Surgery



GUIDO BARBAGLI M.D.

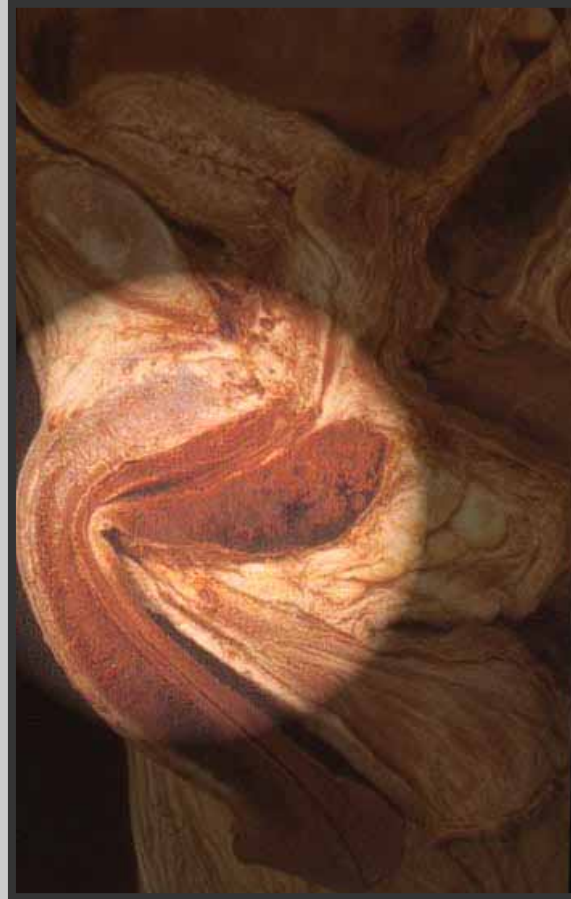Arezzo - ITALY

e-mail: info@urethralcenter.it

Website: www.urethralcenter.it

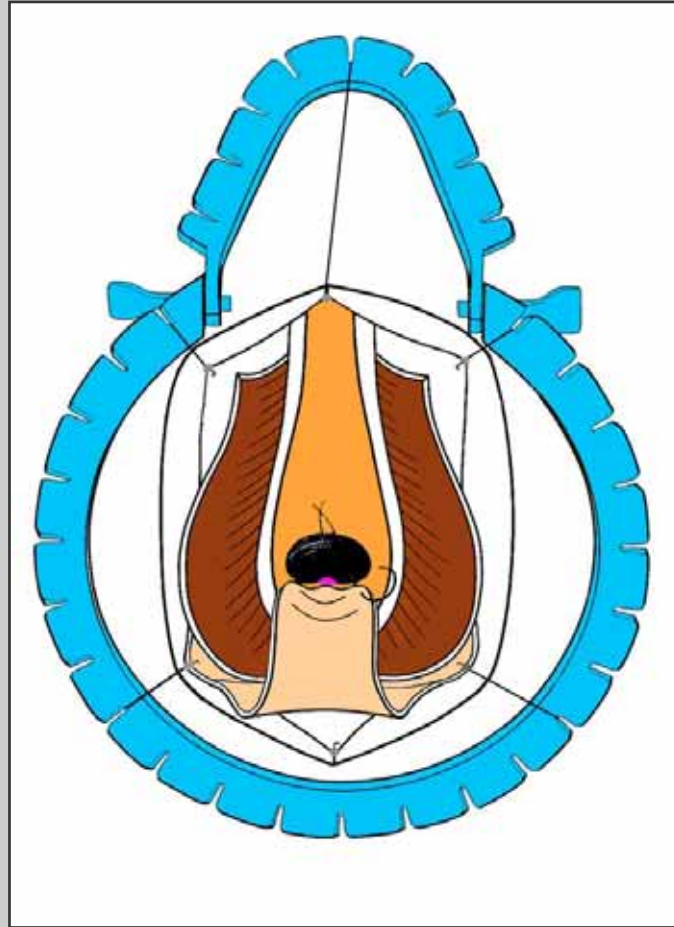
Definitive perineal urethrostomy

Definitive perineal urethroscopy



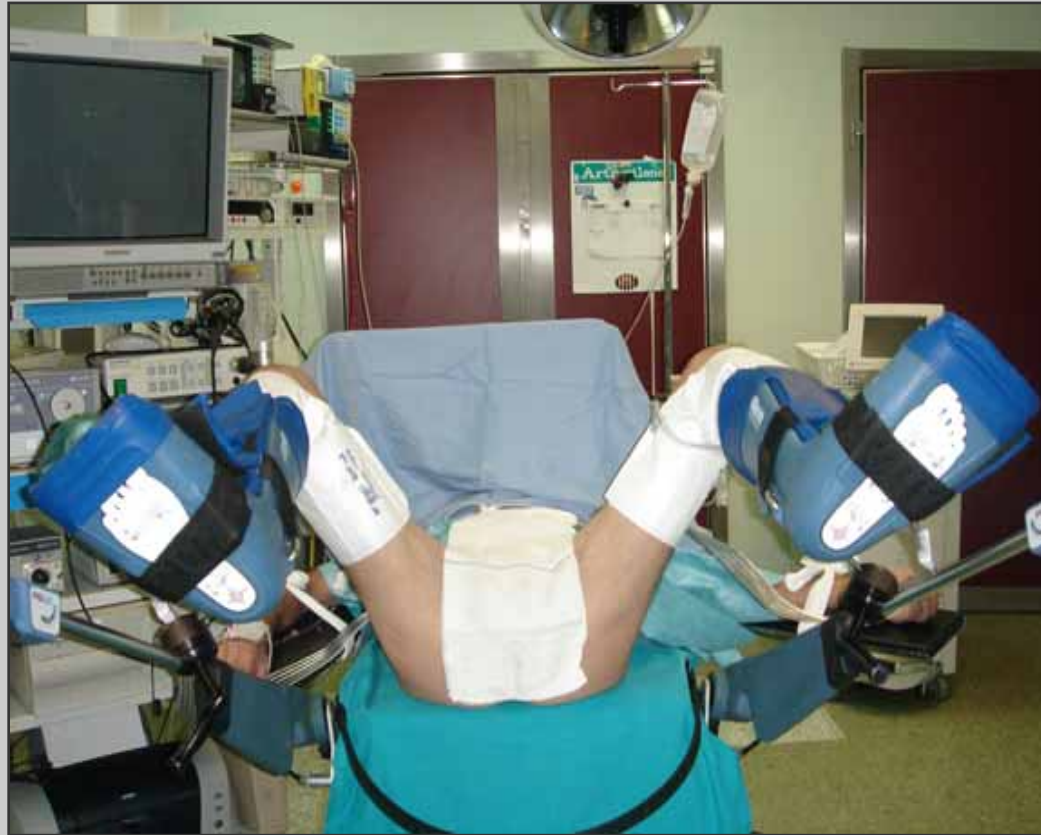Bulbar urethra

Definitive perineal urethroostomy



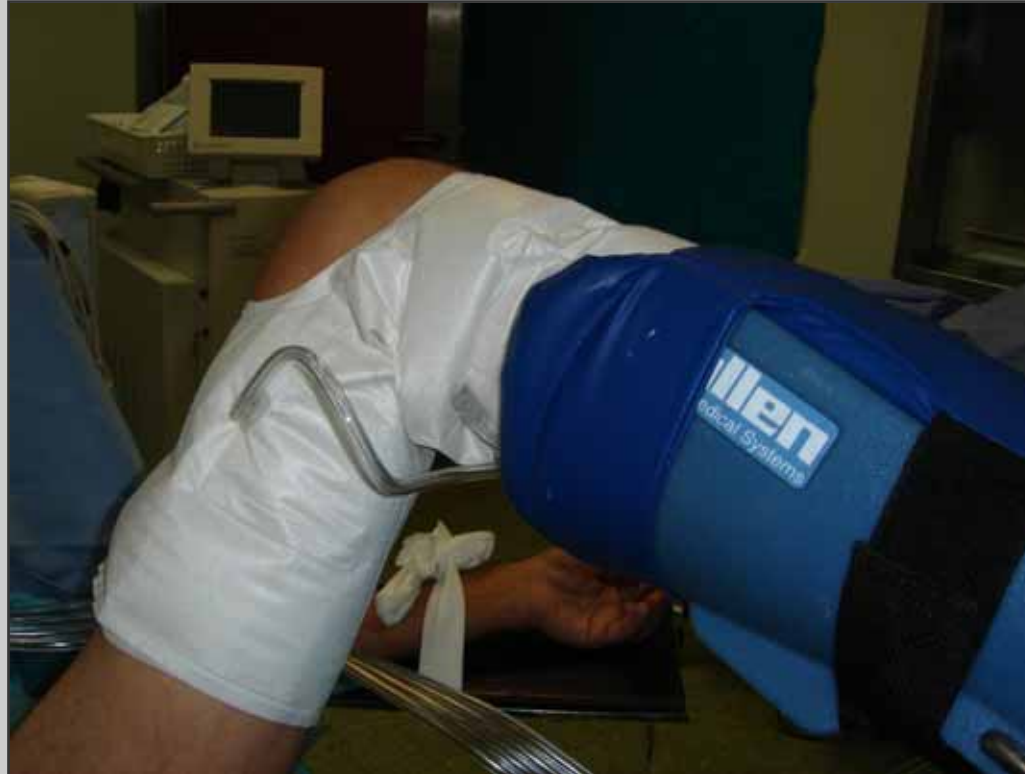Surgical technique: step by step

Preparation of the patient

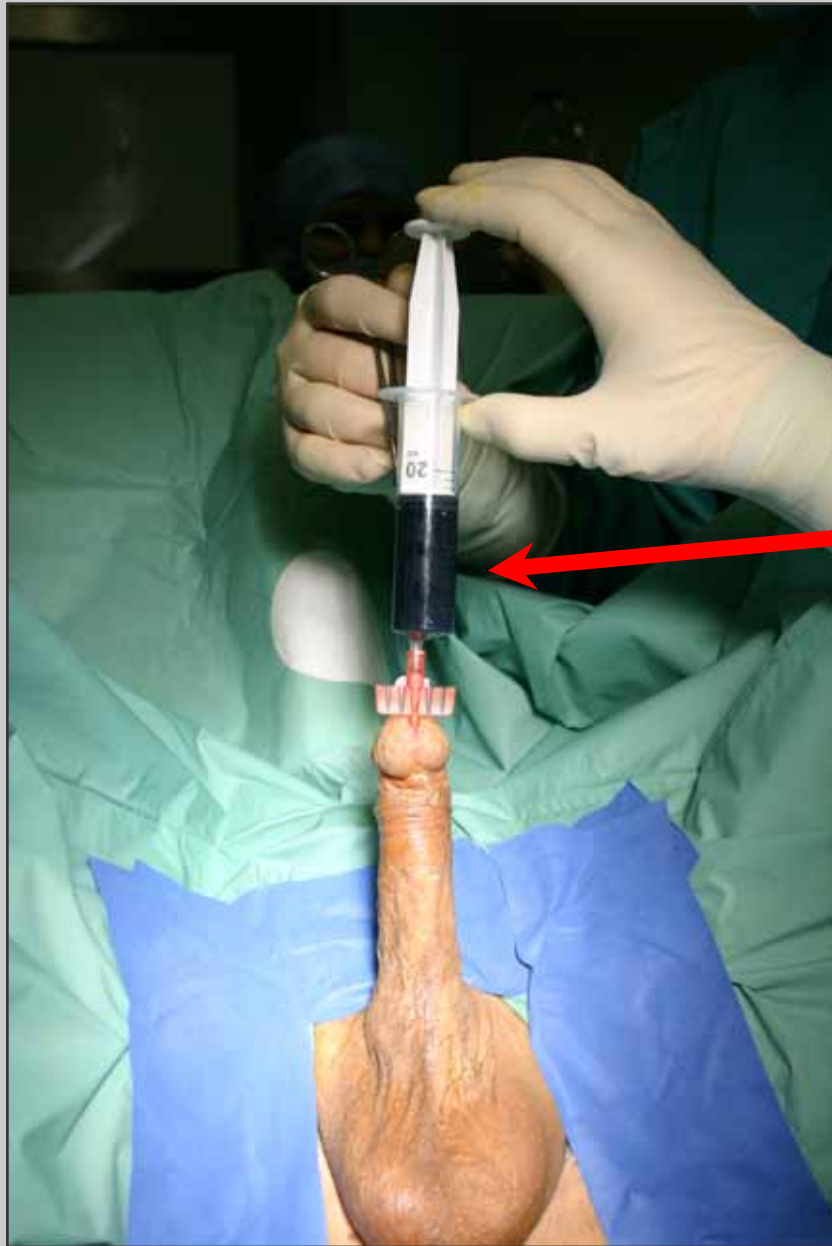

Simple lithotomy position

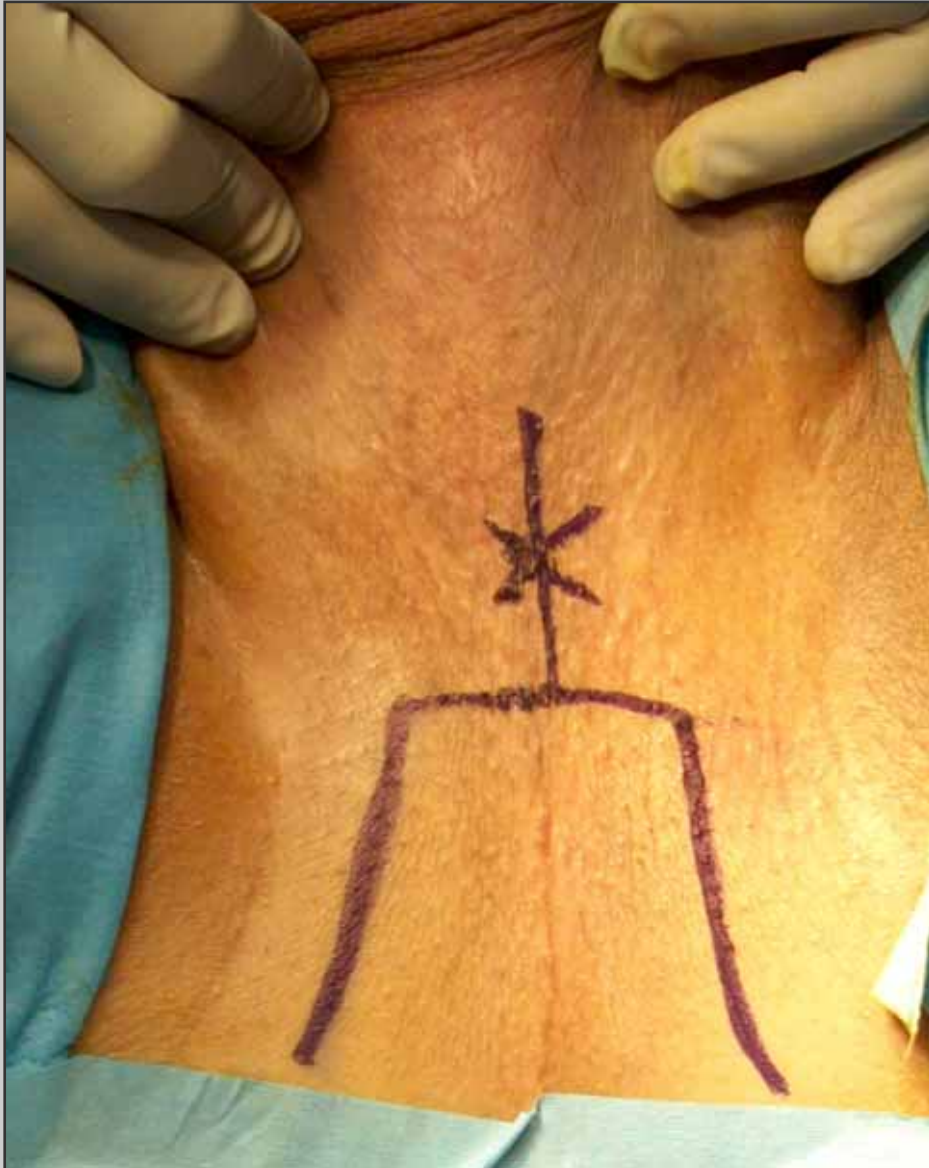
Preparation of the patient



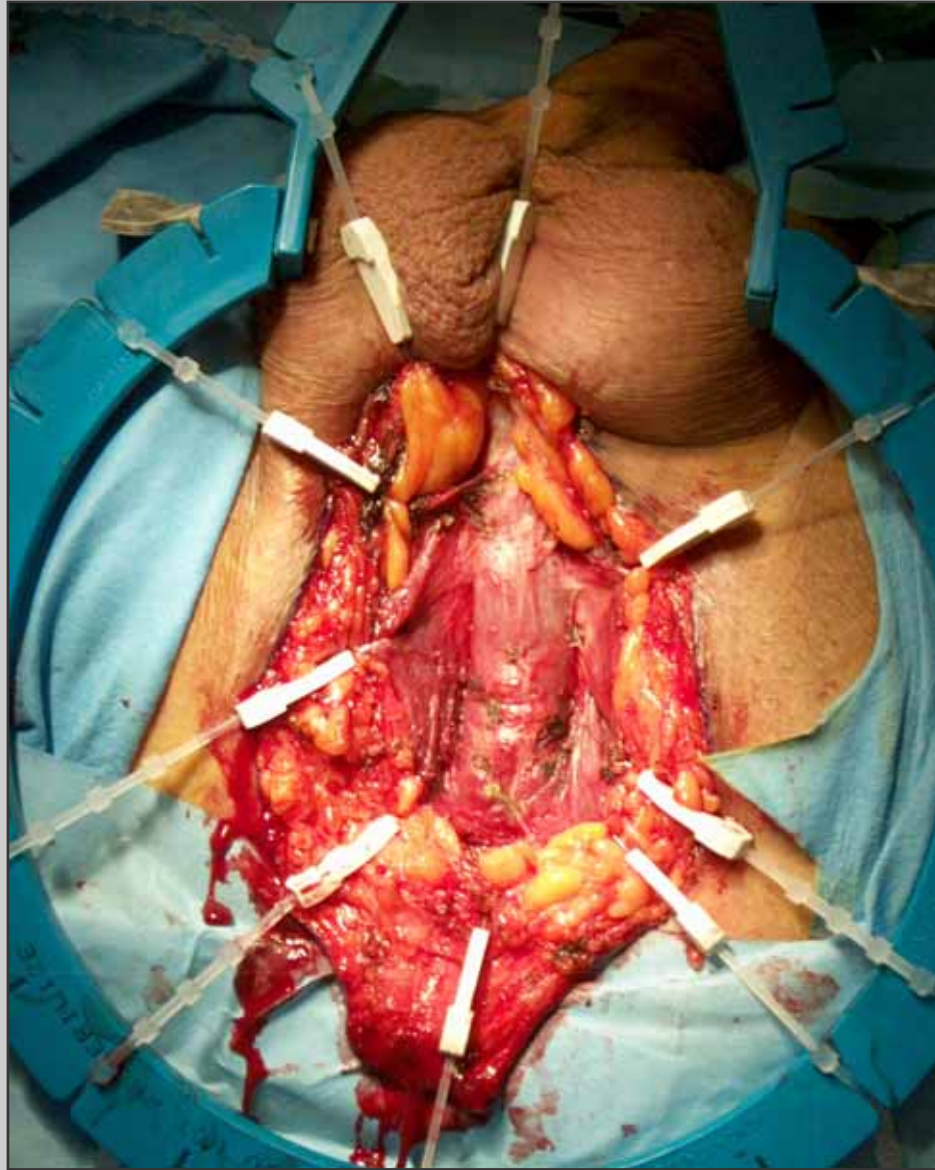
Allen stirrups with sequential inflatable compression sleeves



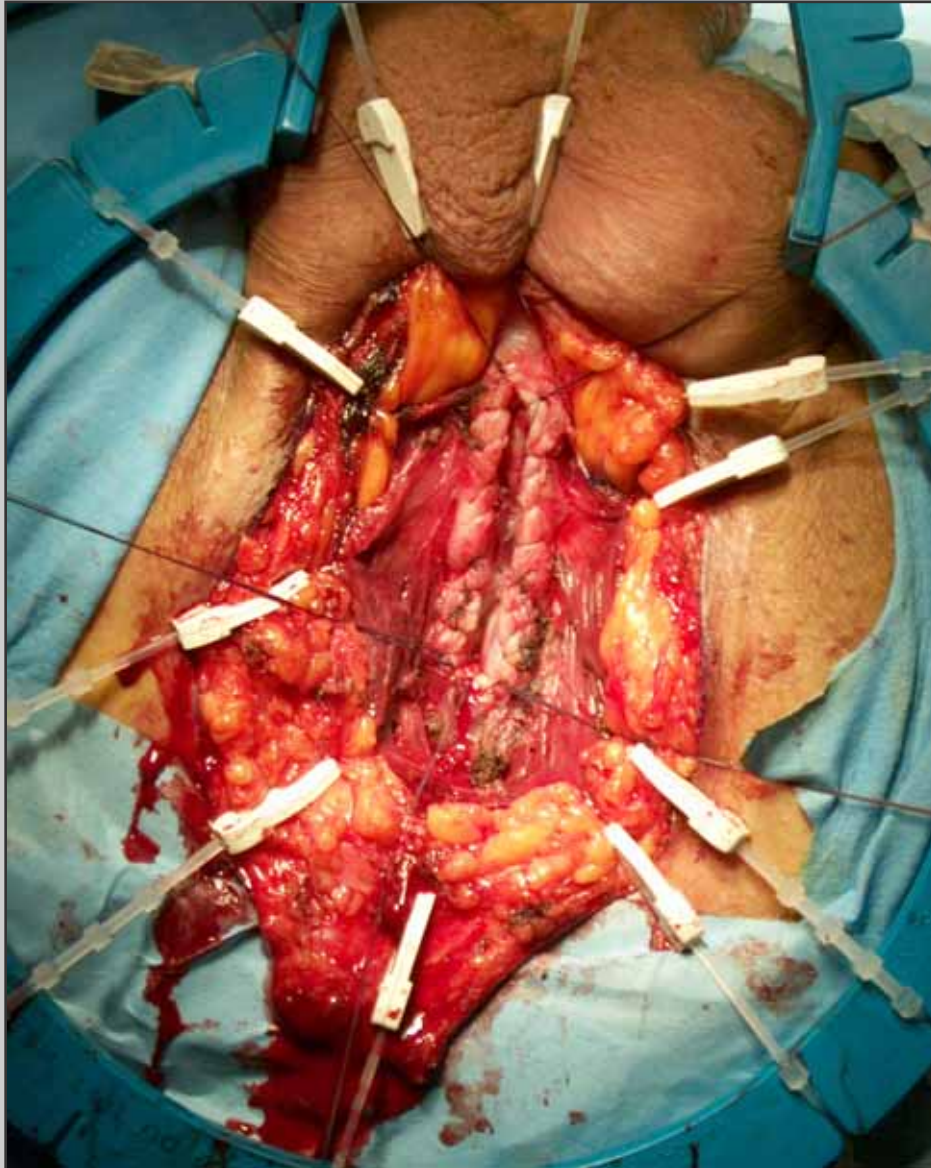
**Methylene blue is injected
into the urethra**



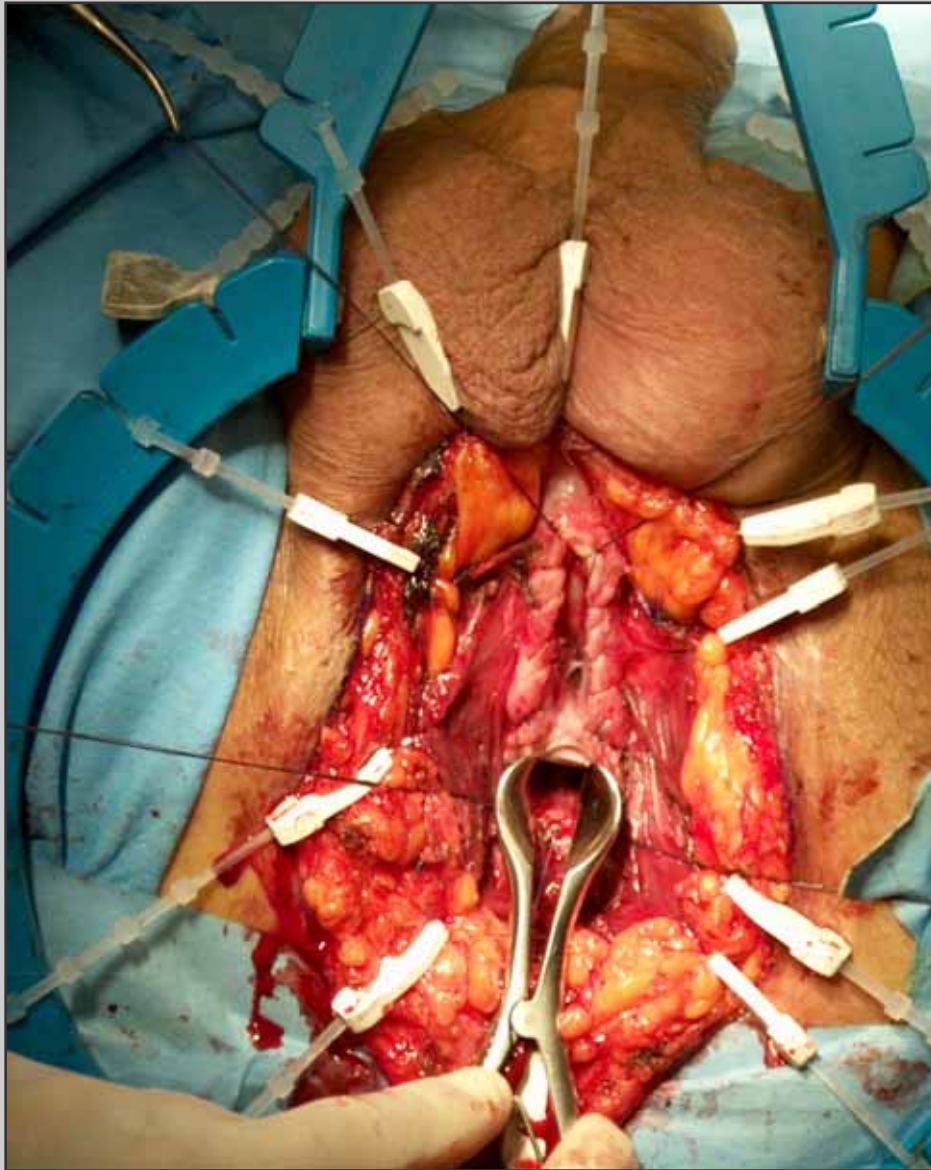
**“U” inverted
perineal incision**



**Opening of the
bulbospongiosum
muscle**



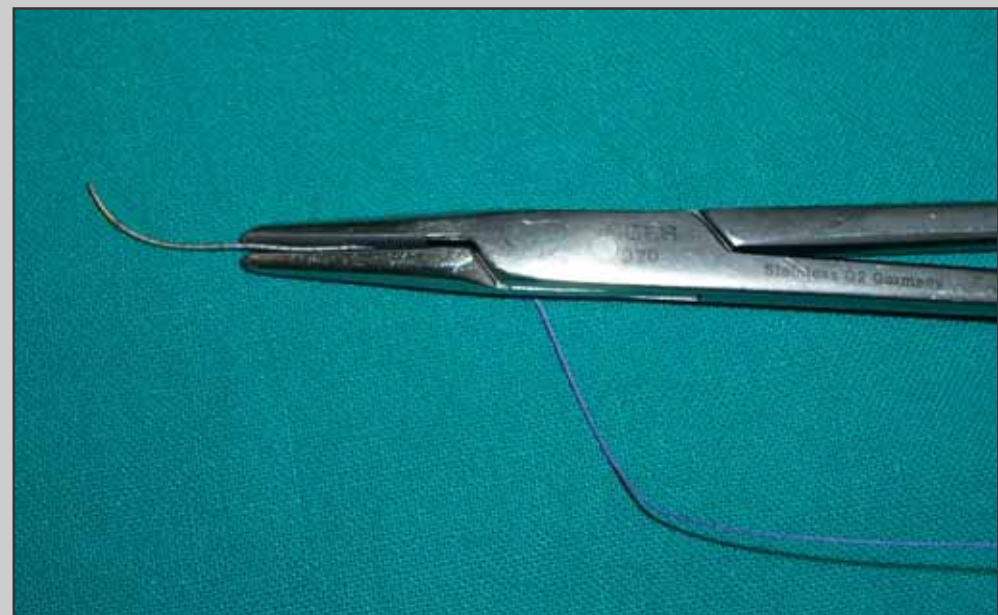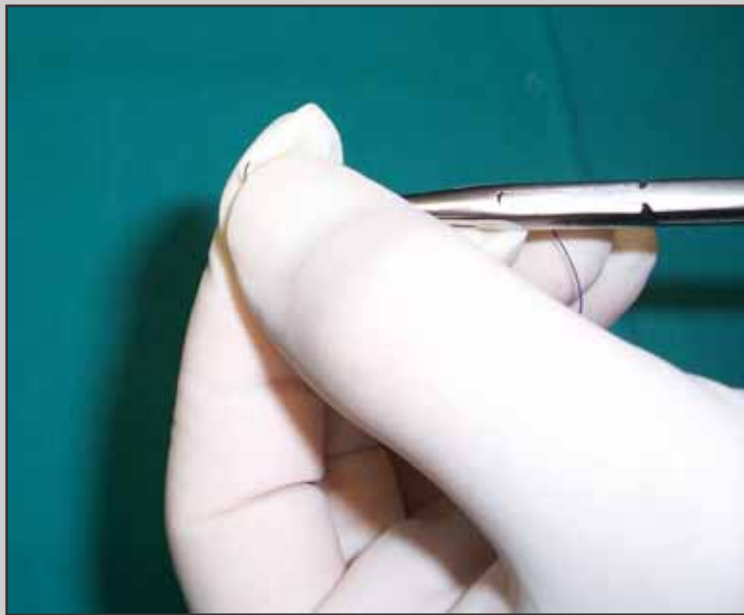
**Opening of the ventral
urethral surface and
suture of the
spongiosum tissue**

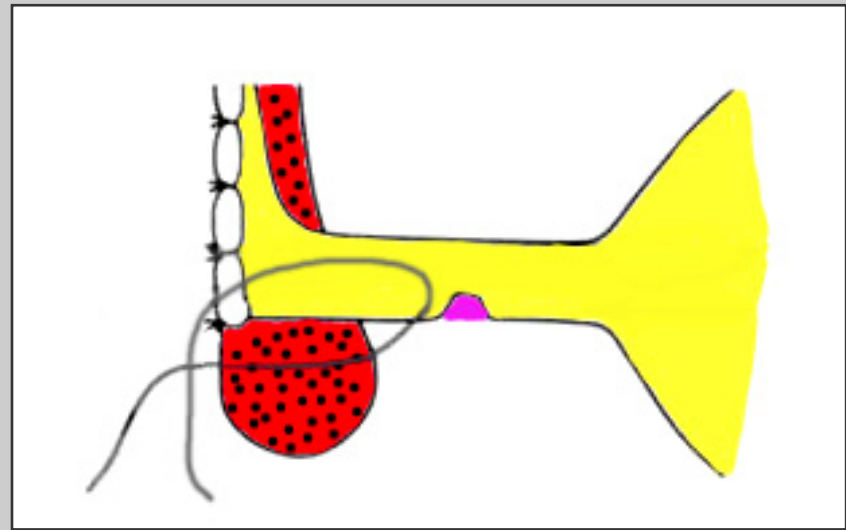
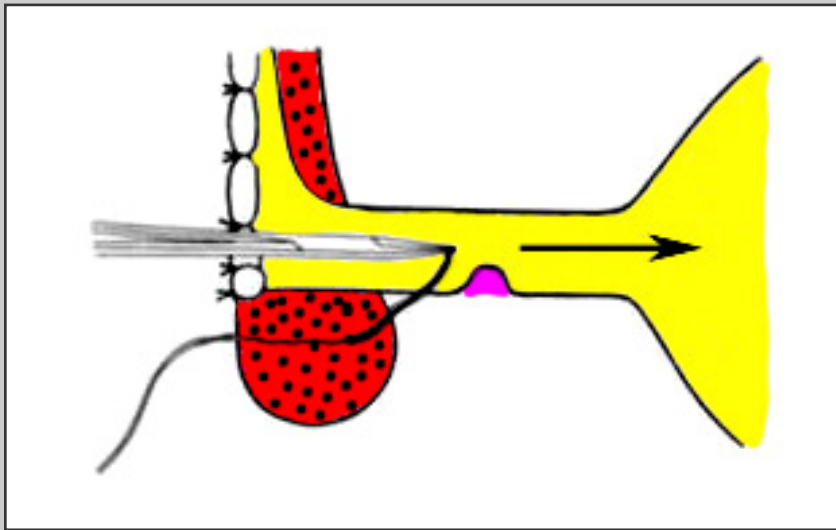
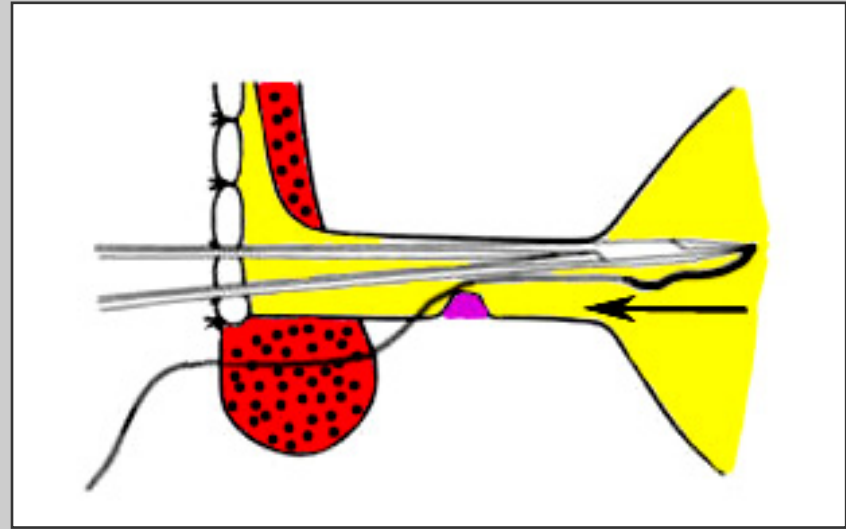
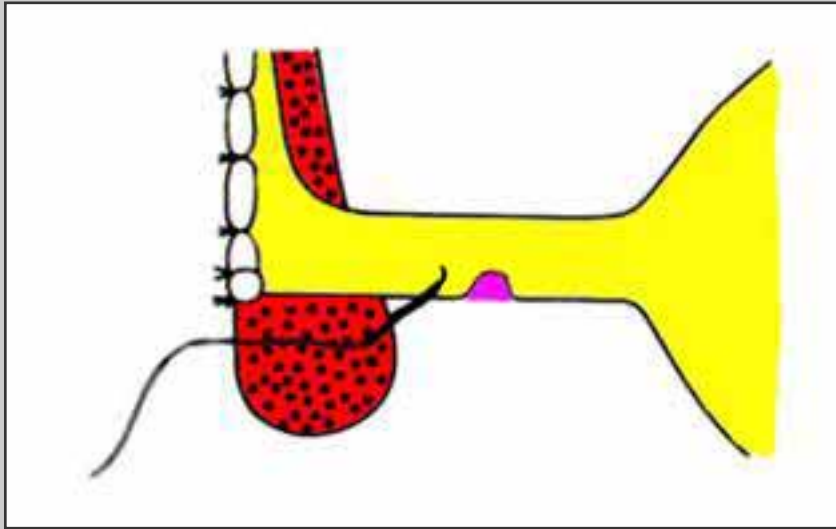


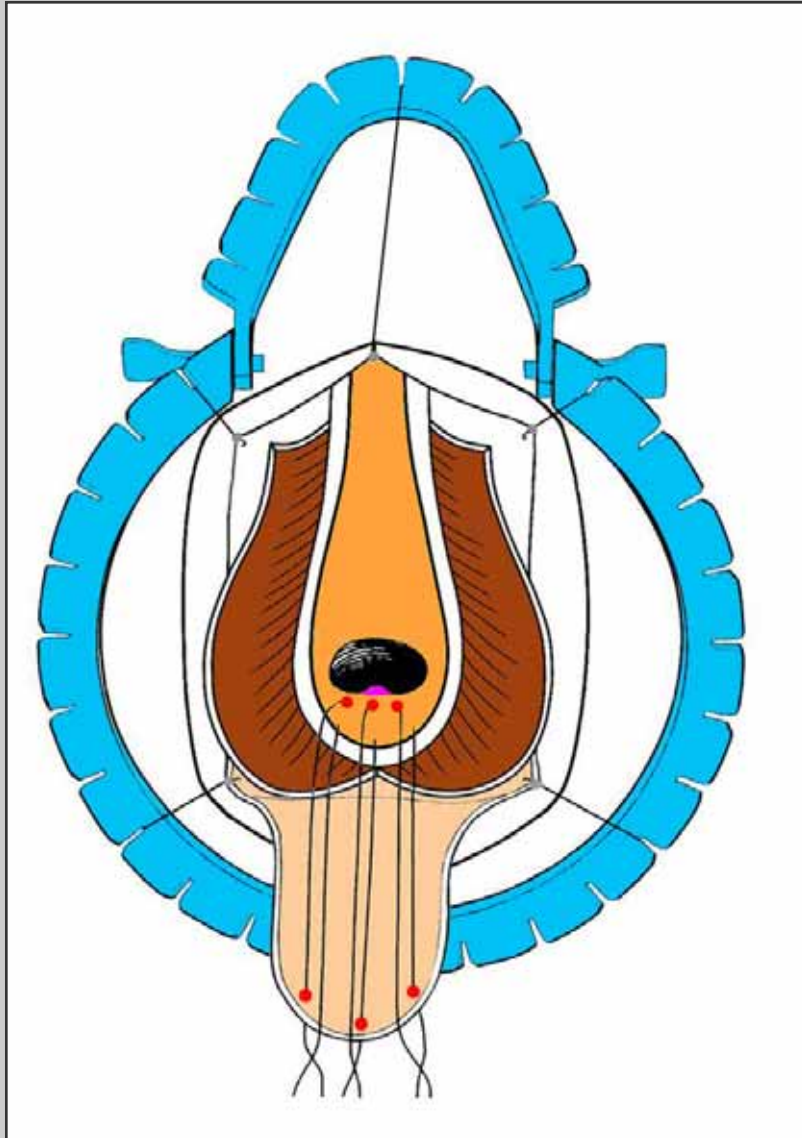
**Nasal speculum is
inserted in the proximal
urethral stoma**



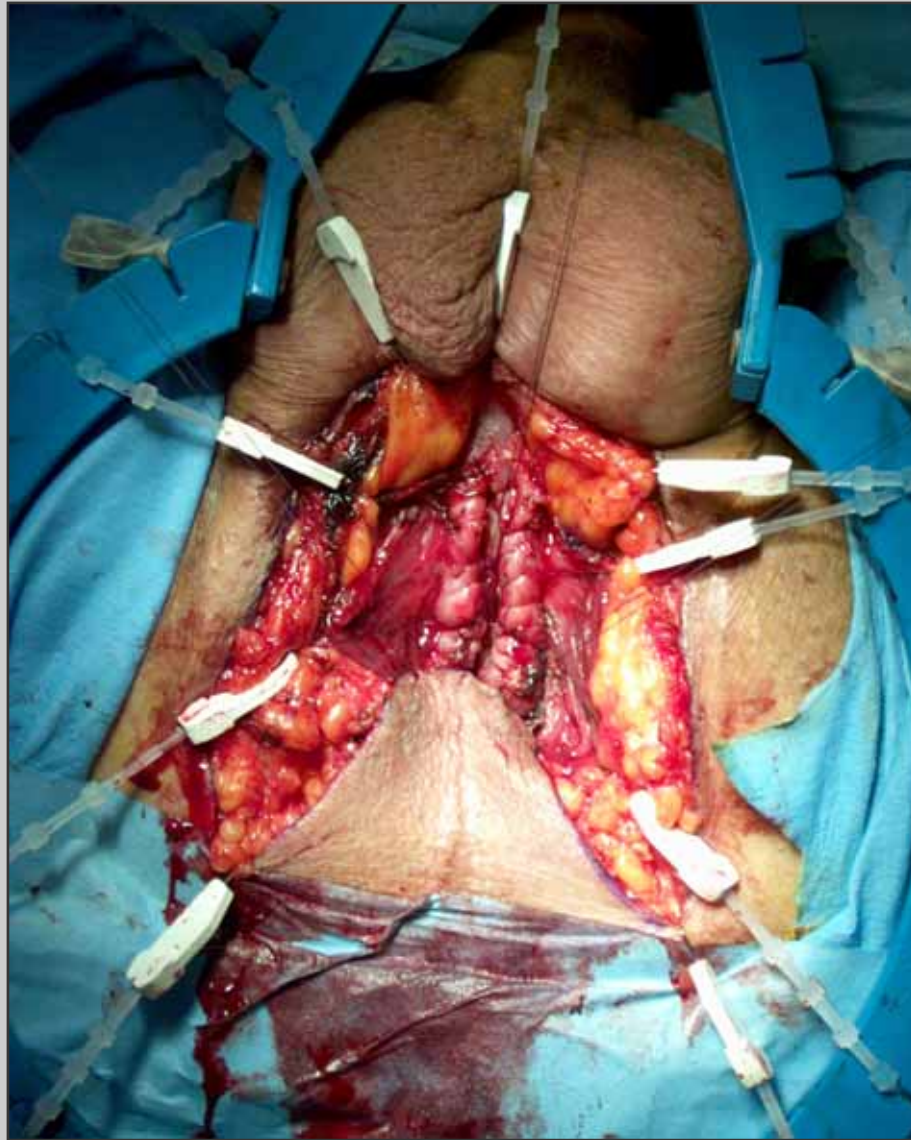
**The needle in
modified according
the Webster's
technique**



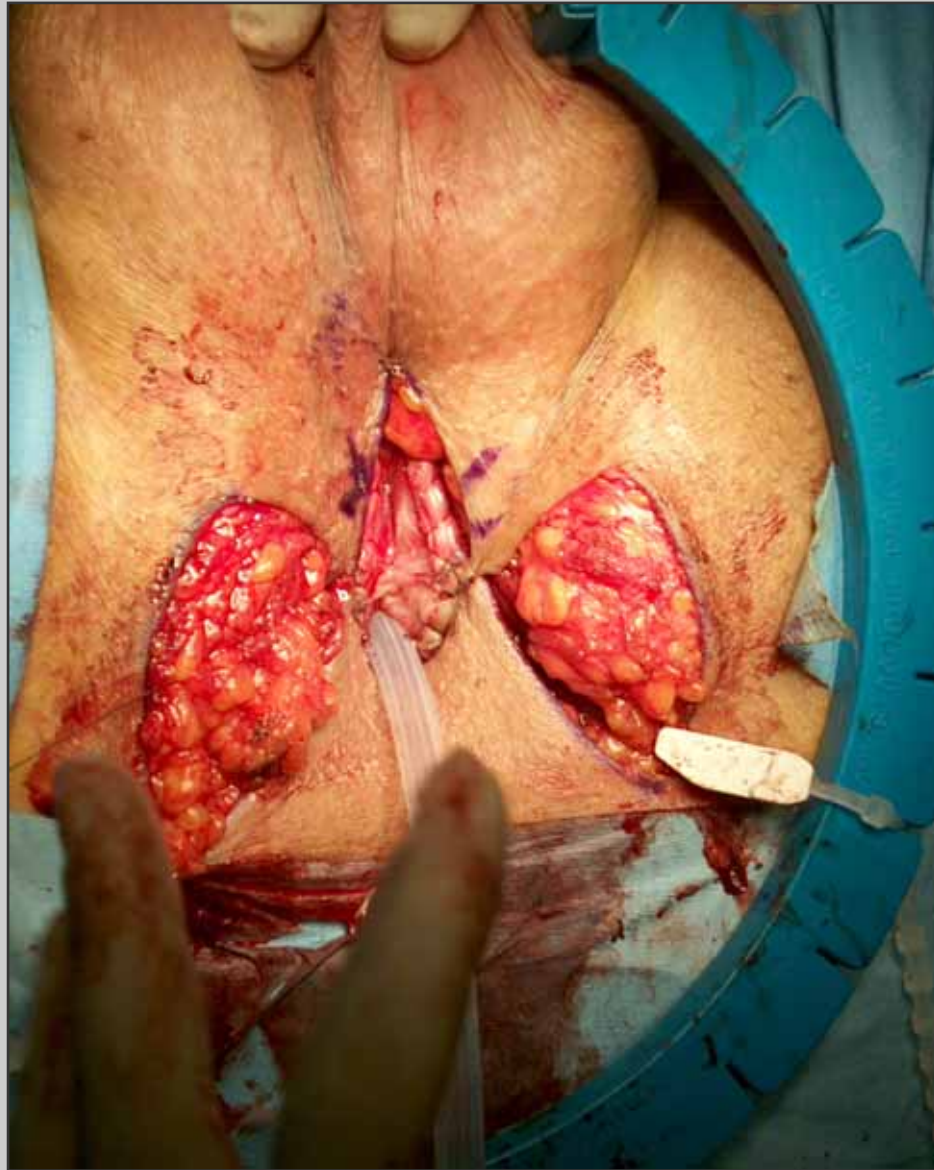



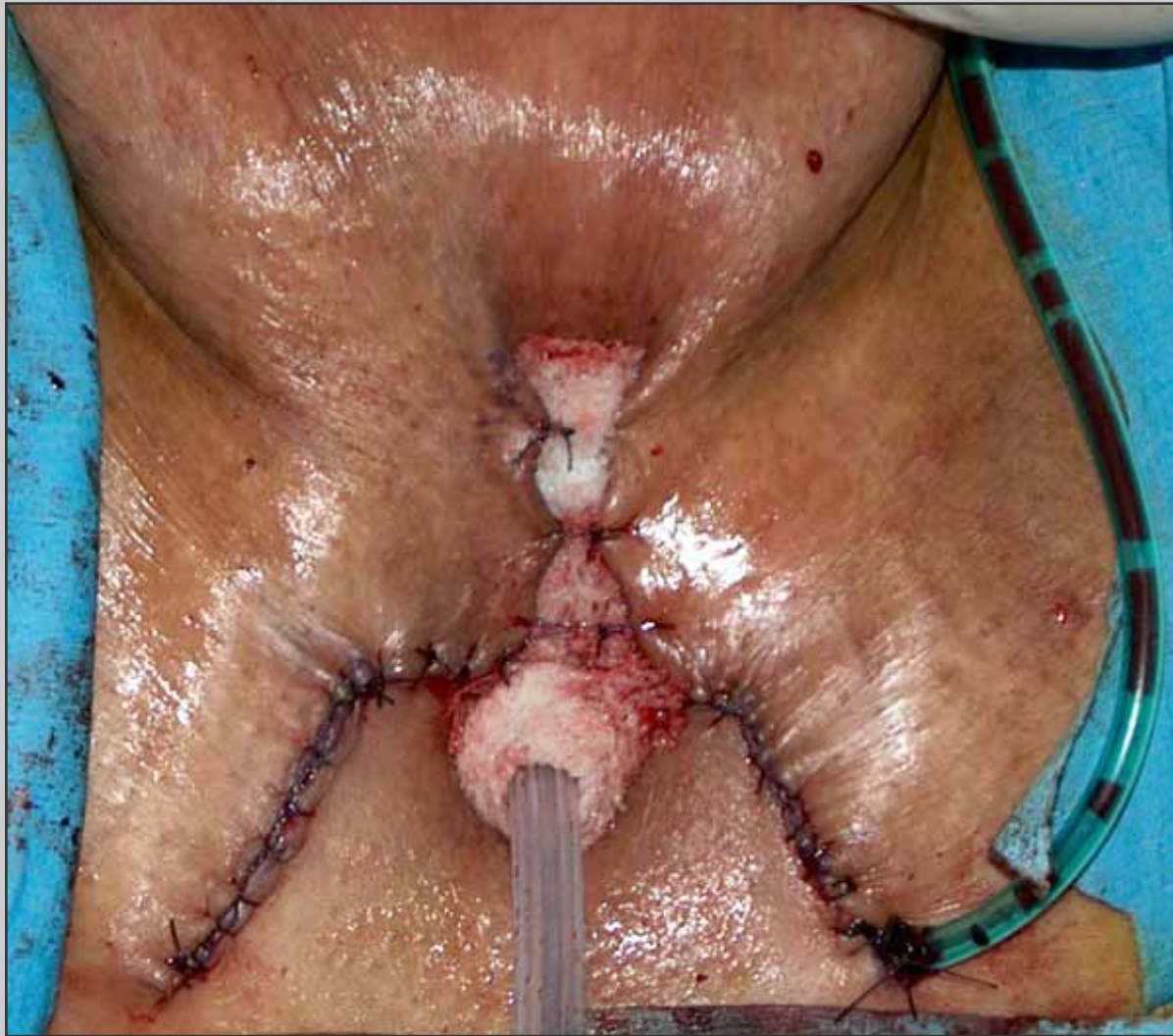**Three stitches are
passed through the apex
of the scrotal flap**



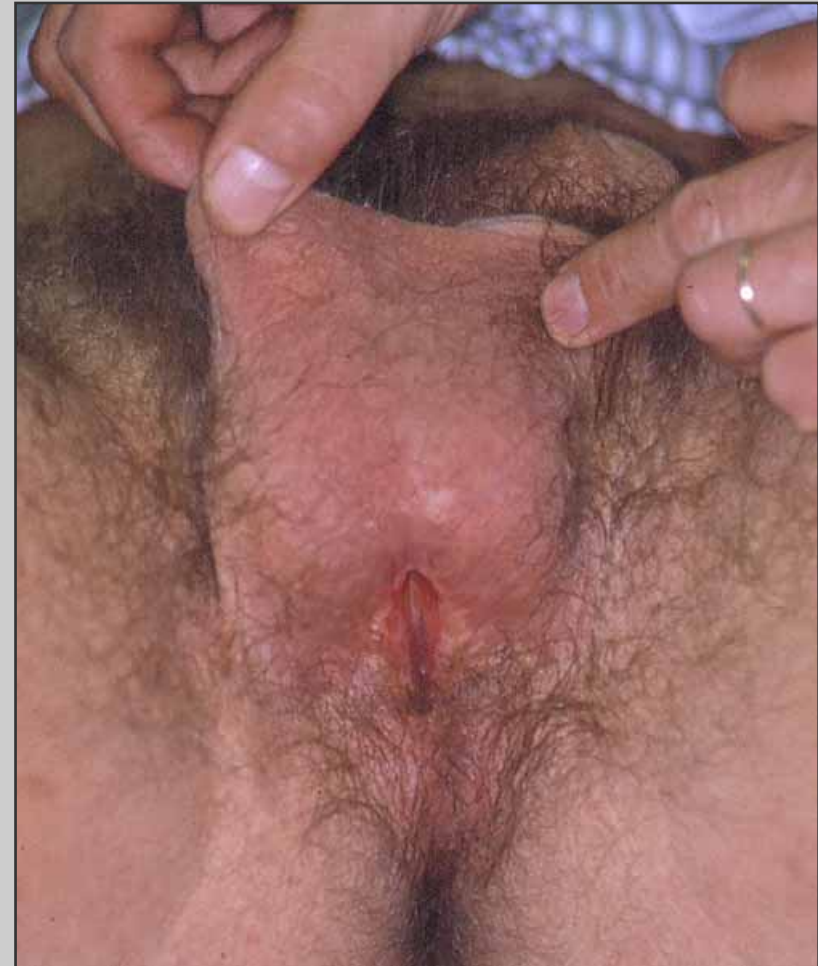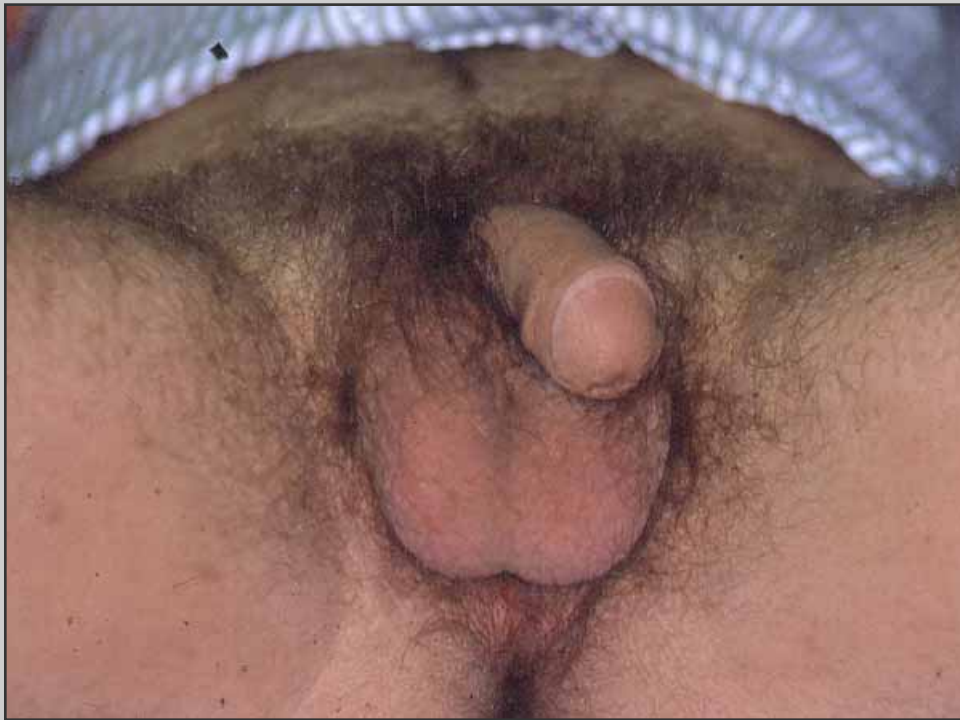**The scrotal flap is
sutured to the proximal
urethral opening**



**Two scrotal flaps are
sutured to the urethral
plate**



Final view of the perineal urethroostomy



View of the perineal urethrostomy one year later

Post-operative care

- **Patient is discharged from the hospital three days after surgery**
- **Patient is maintained on oral antibiotics until the catheter is removed**
- **Two months following surgery, the patient is evaluated at follow-up visit in outpatient service**

Post-operative complications

- **Dehiscence of the surgical wound**
- **Temporary numbness or dysesthesia to the perineum**
- **Scrotal swelling**