



Guido Barbagli

Center for Reconstructive Urethral Surgery

Arezzo - Italy

E-mail: info@urethralcenter.it

Website: www.urethralcenter.it


28th Congress of the Société Internationale d'Urologie

November 12 – 16, 2006

Cape Town – South Africa



Dedicated to John Quartey, respected colleague and friend. His passing is a great personal as well as professional loss



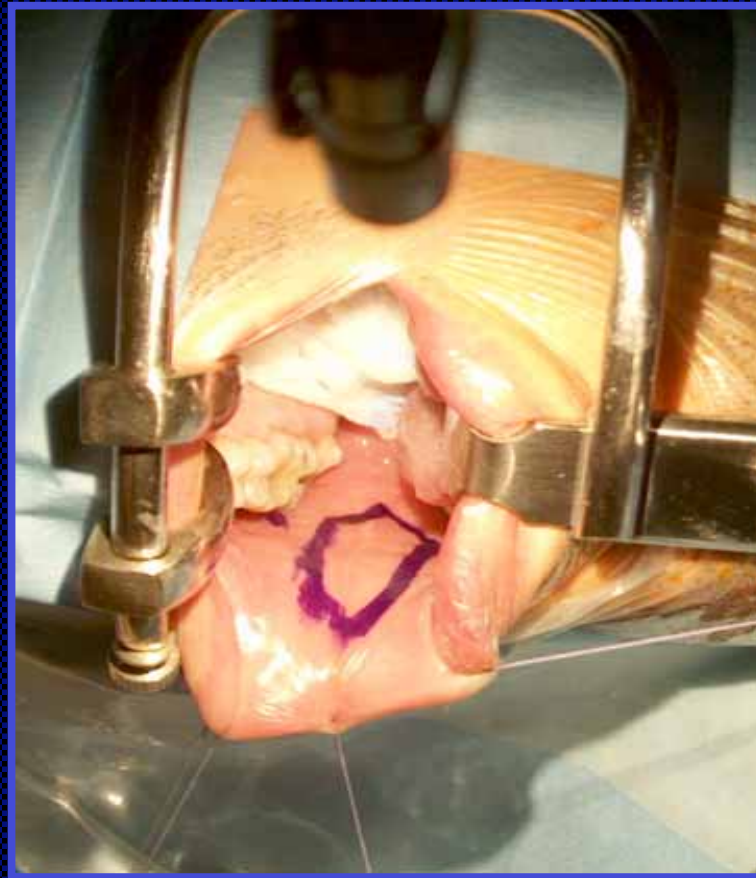
Professor John Quartey, FRCS



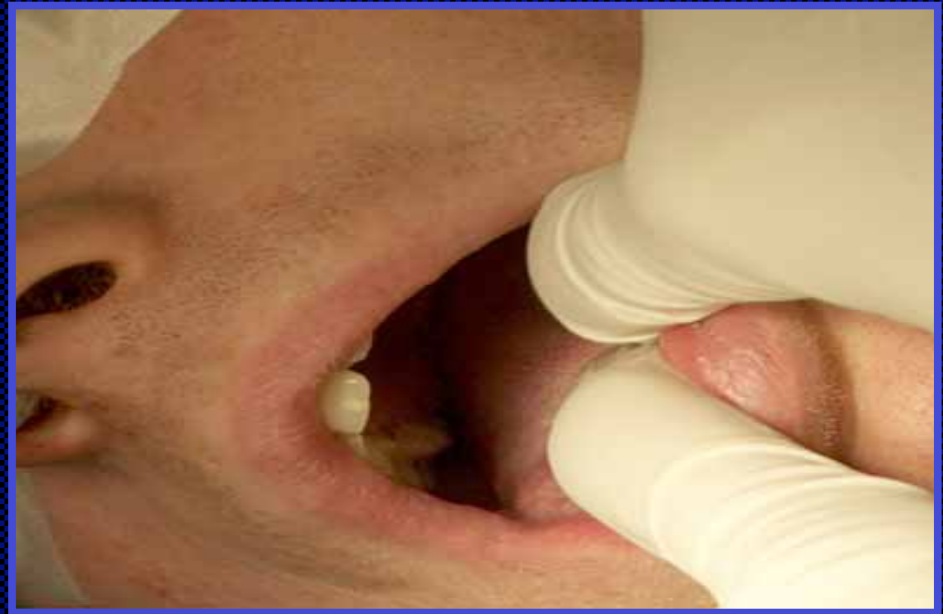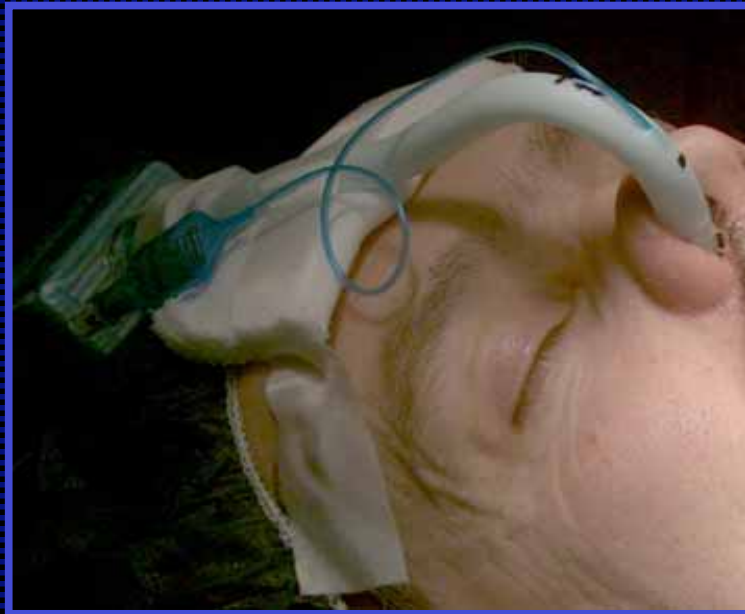Buccal mucosal urethroplasty: how to do it



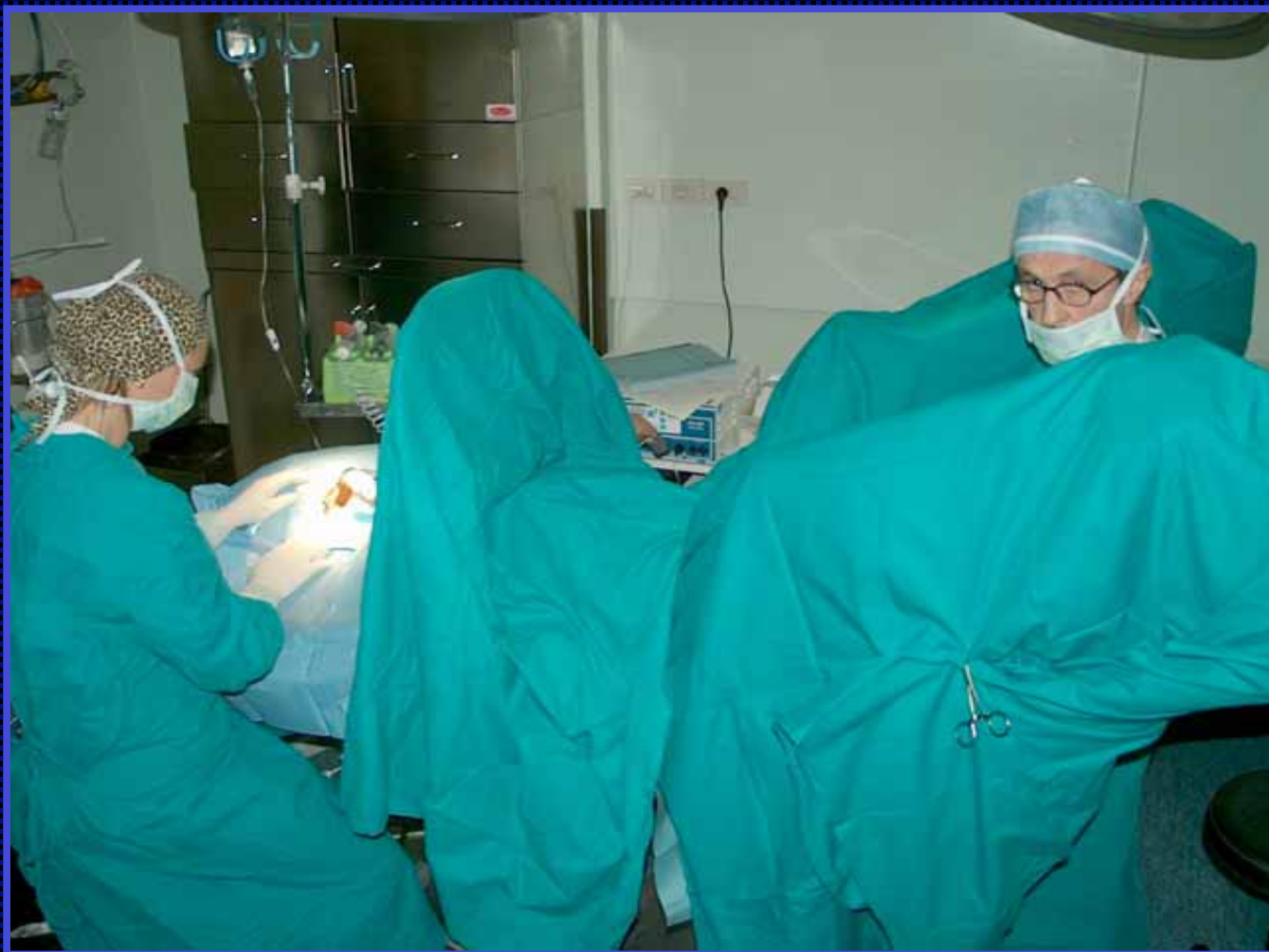Harvesting buccal mucosal graft from the inner cheek



**The patient is intubated through the nose,
allowing the mouth to be completely free**



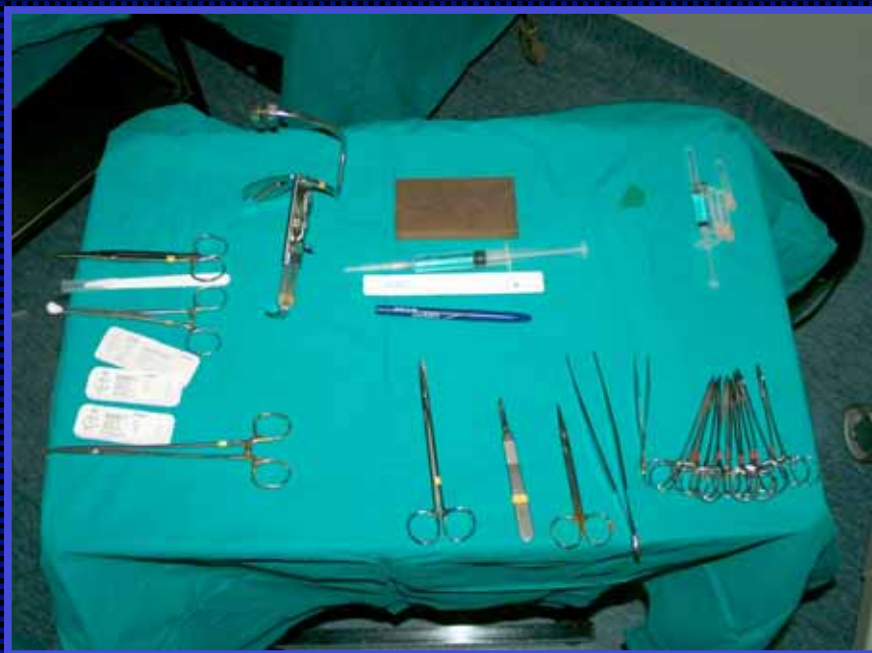Two surgical teams work simultaneously



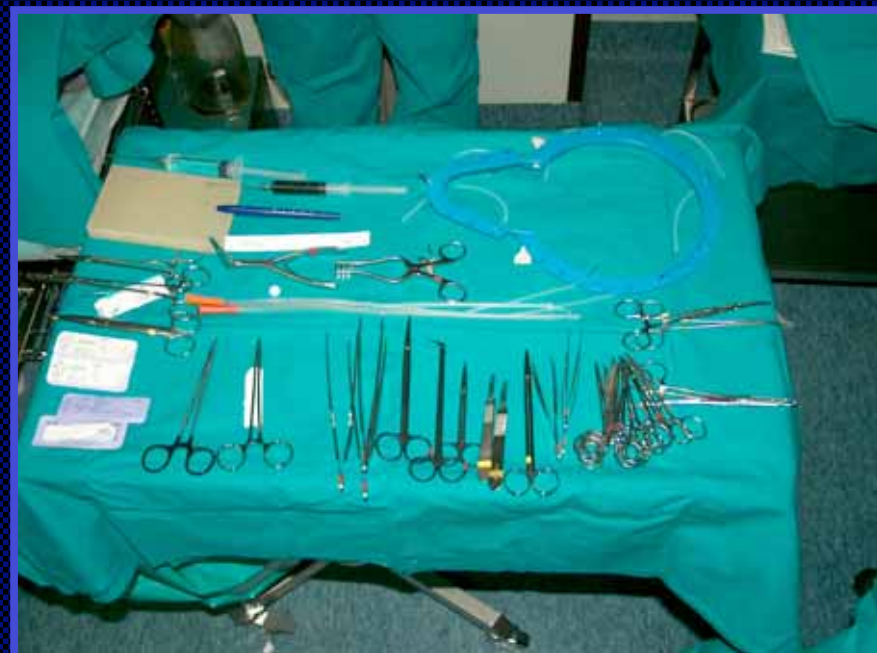Center for Reconstructive Urethral Surgery



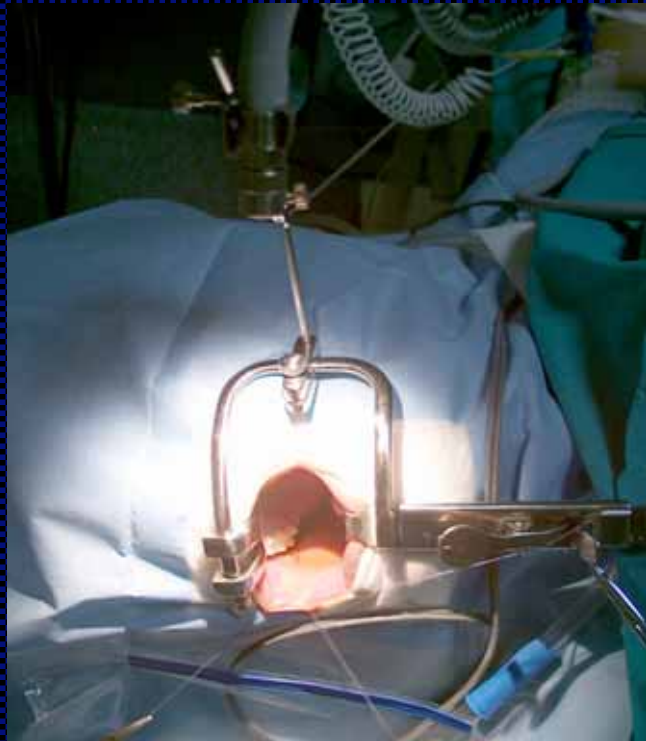
Two sets of surgical instruments



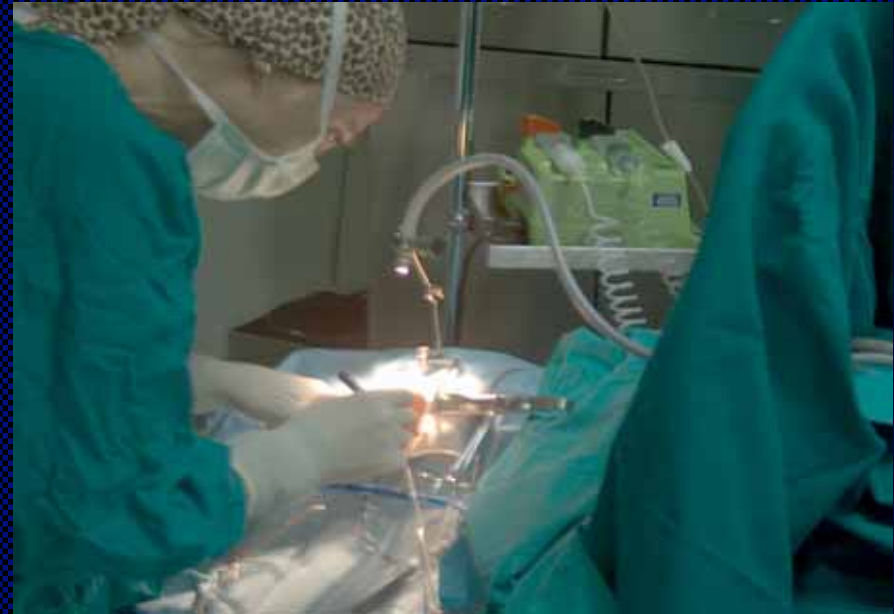Buccal mucosa



Urethroplasty

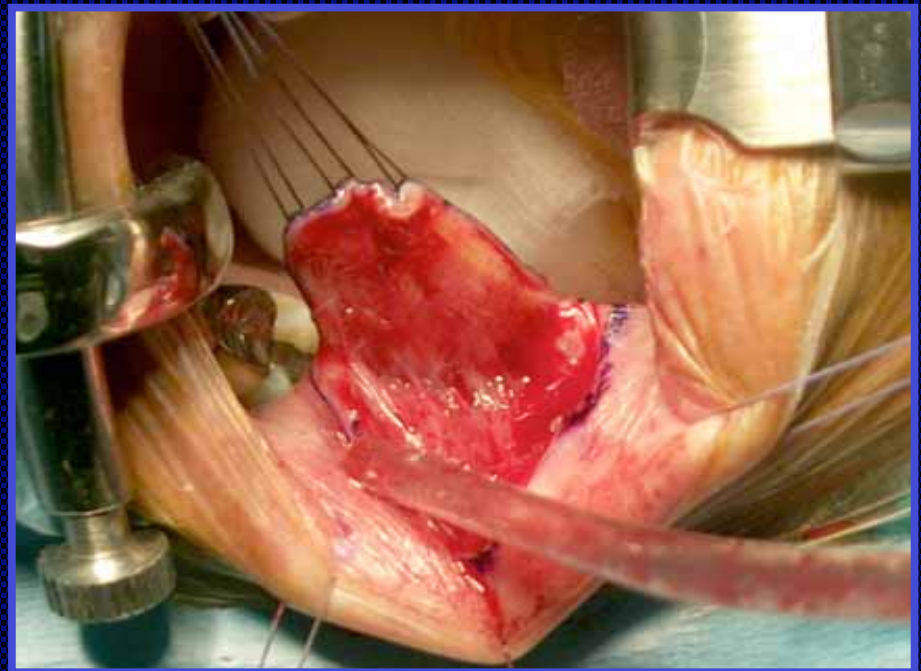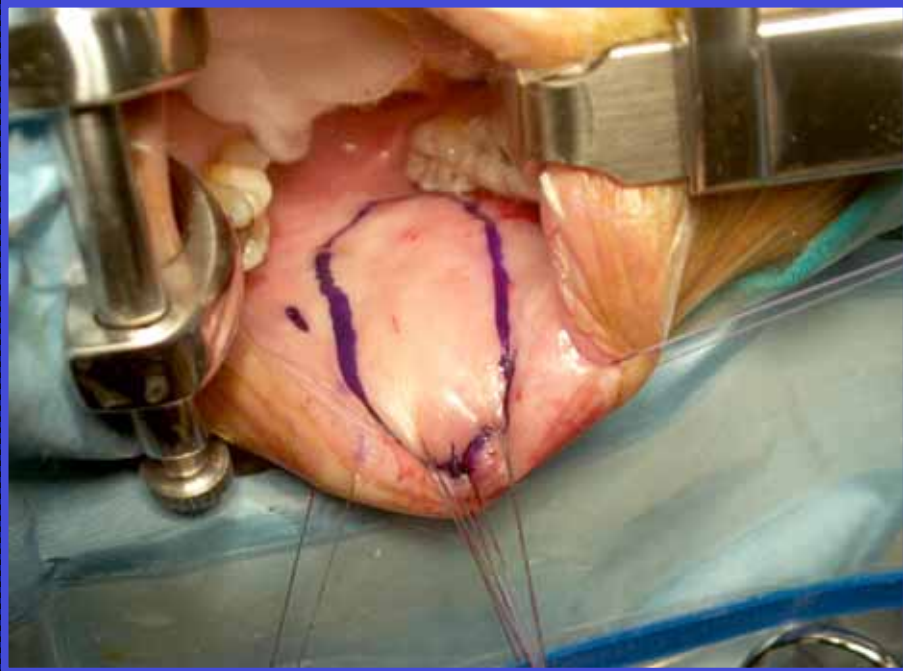


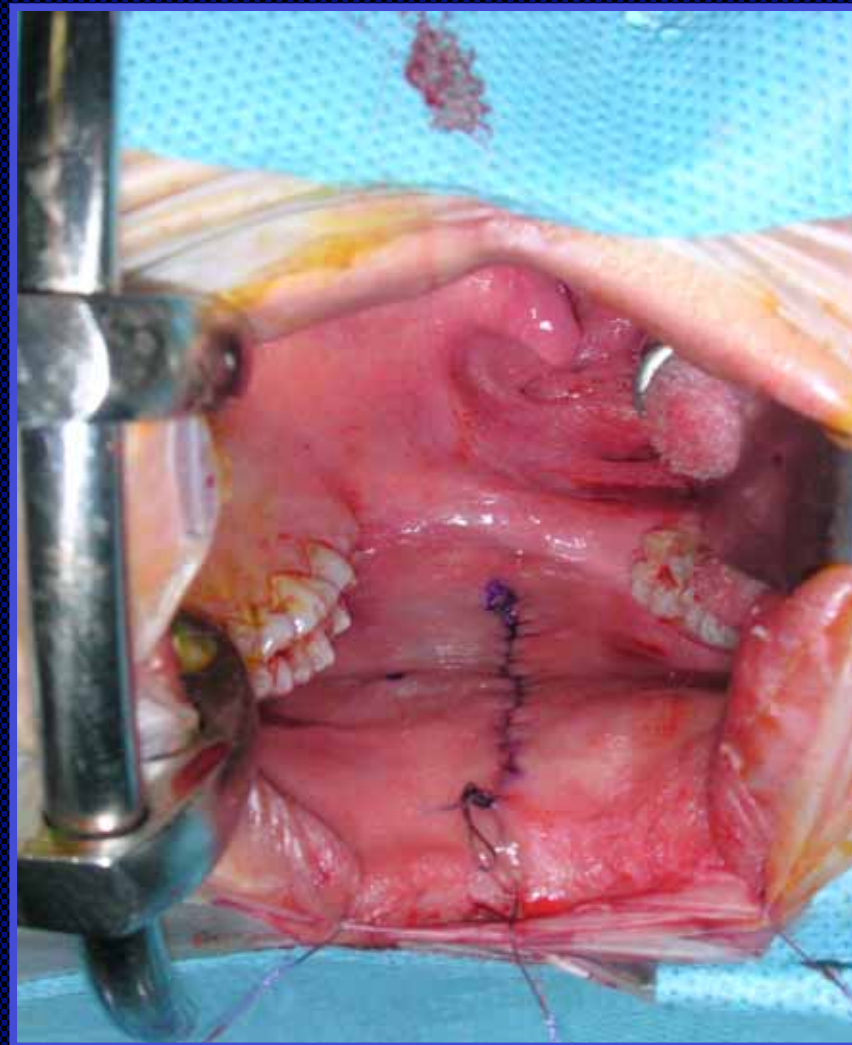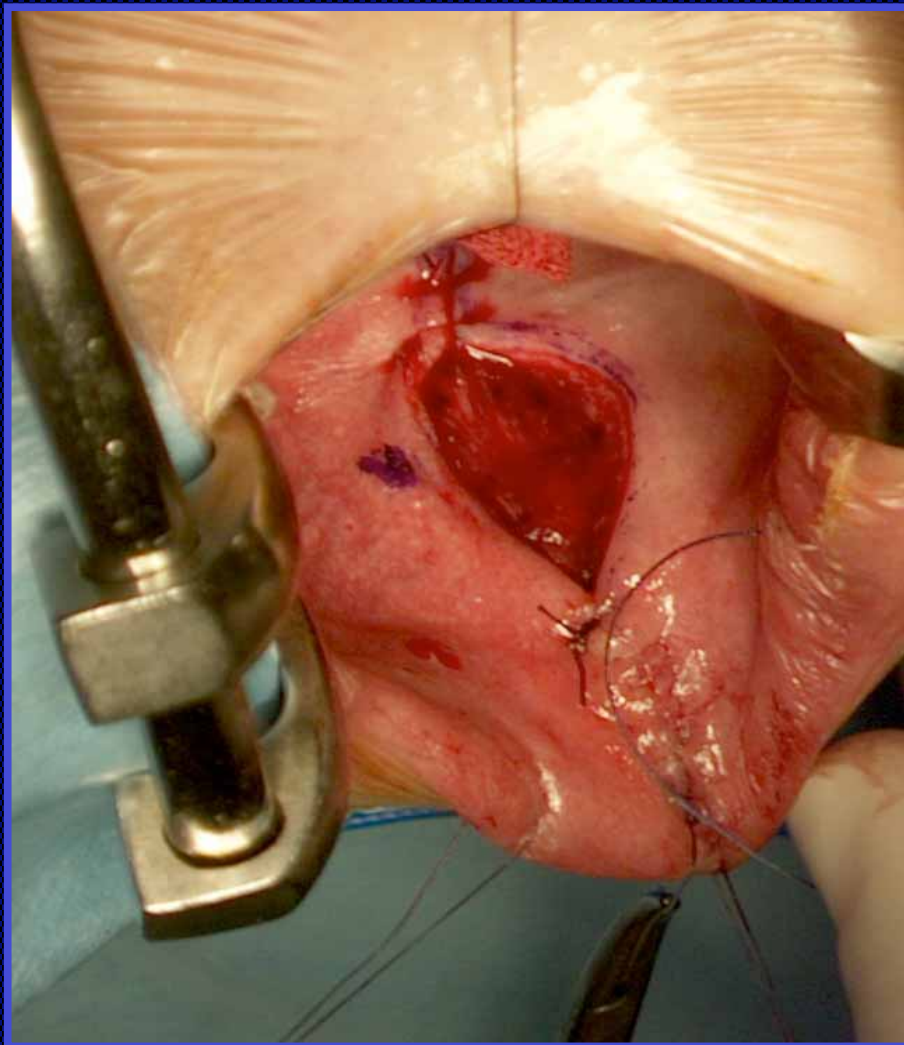
**Appropriate mouth
retractor**

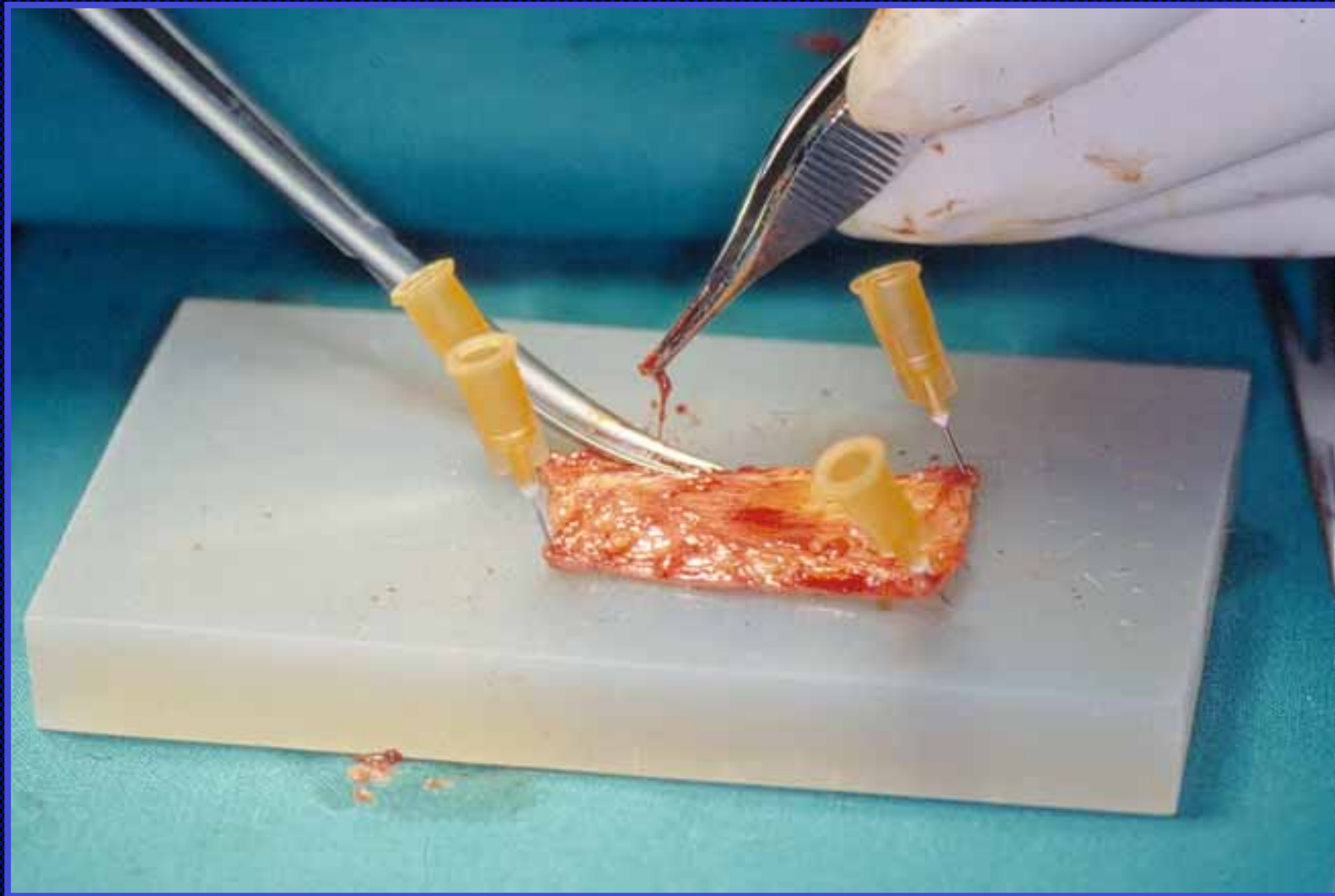


**Only one assistant is
needed to harvest the
buccal graft**

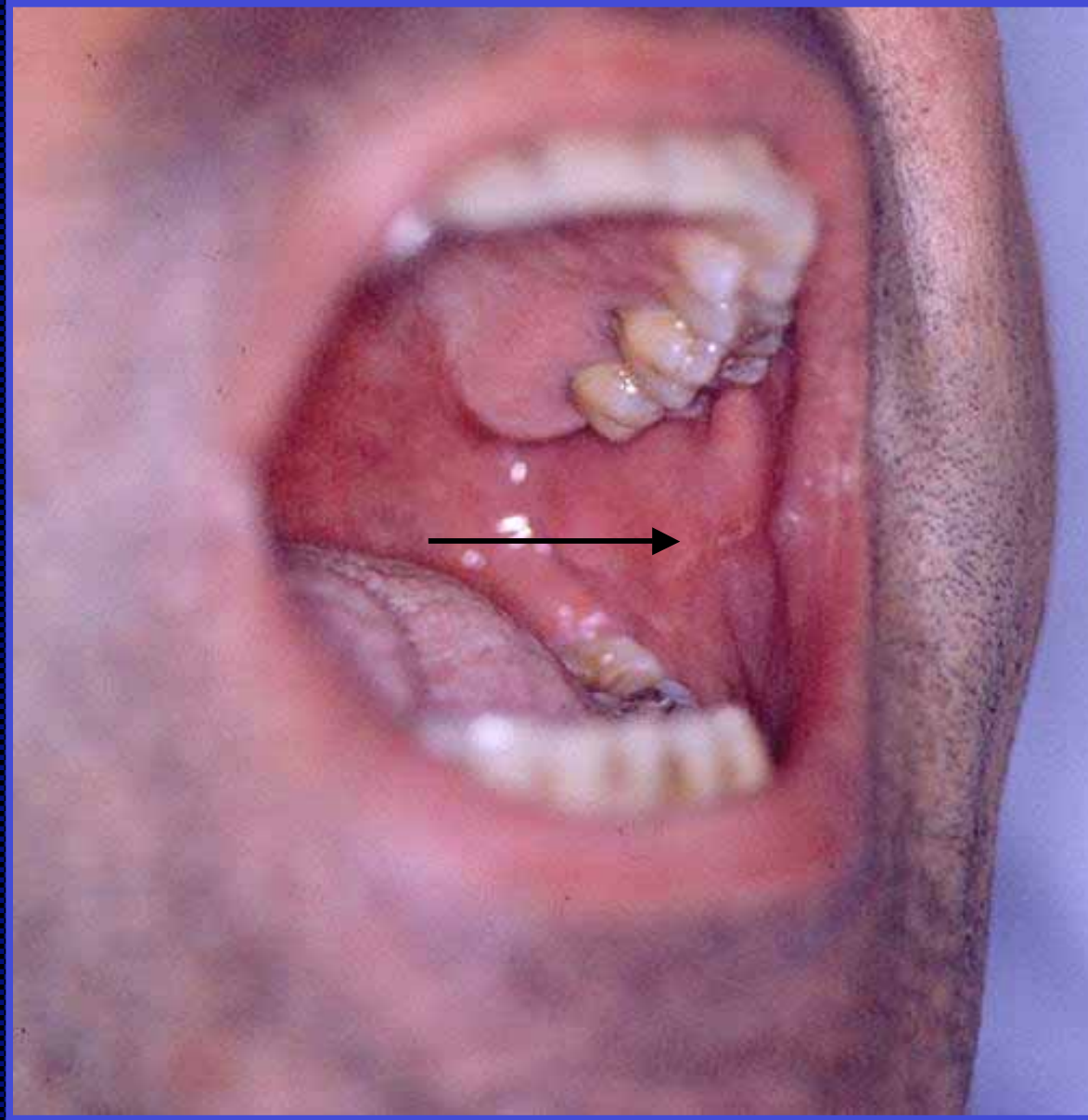








length 4 cm – width 2.5 cm



Center for Reconstructive Urethral Surgery



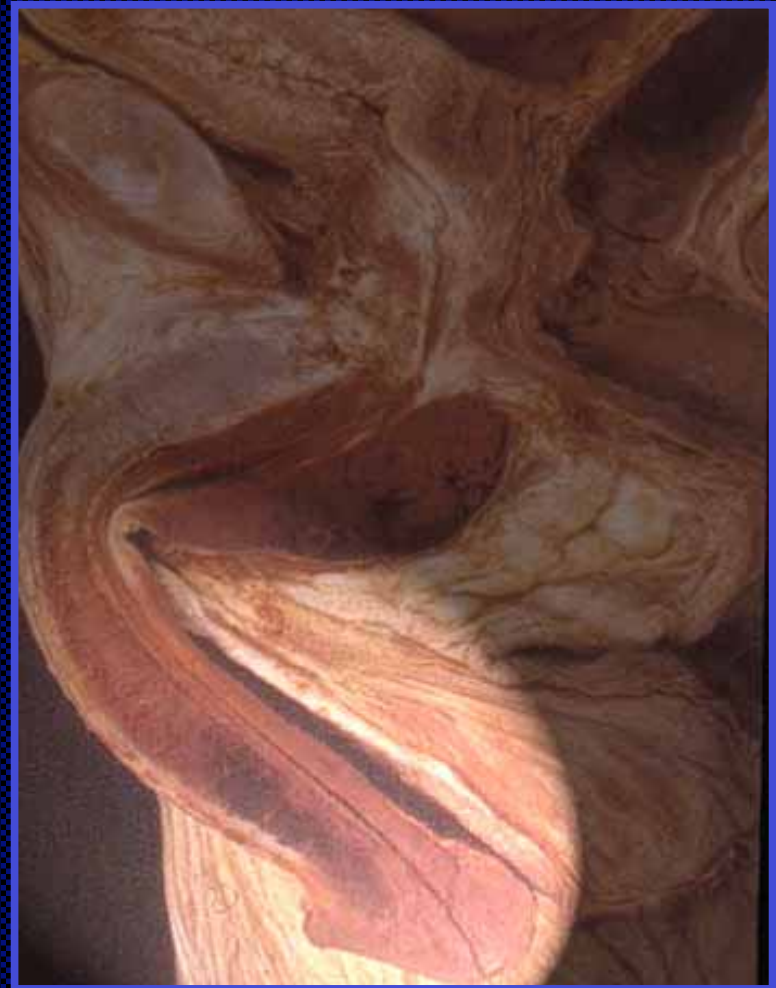Advantages of the double team

- decrease of contamination in surgery
- decrease of surgical time to ~ one hour
- provides training opportunity for a young assistant
interested in learning urethral surgery

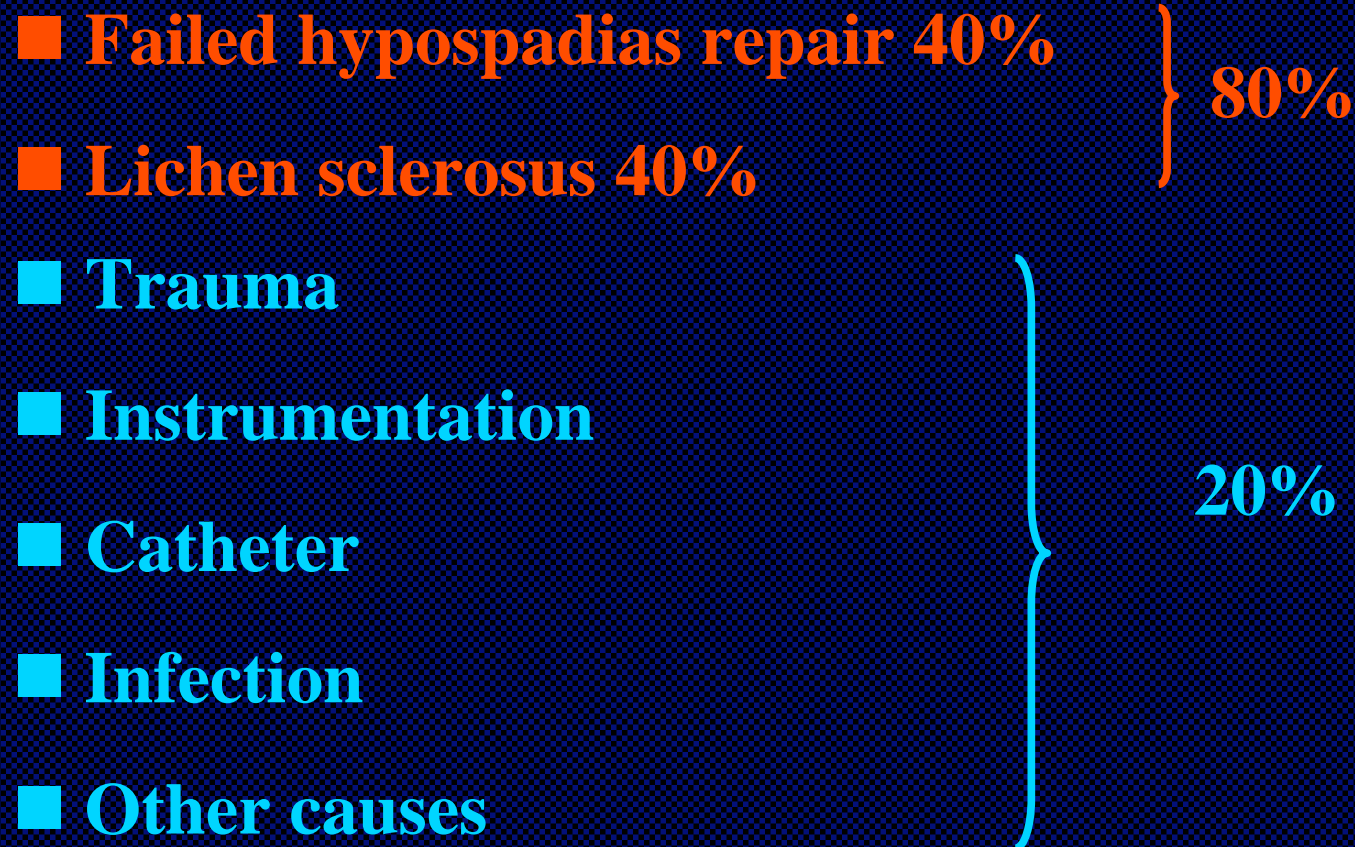


Penile urethroplasty

**The surgical technique
for the repair of penile
urethral strictures is
selected according to the
stricture etiology**



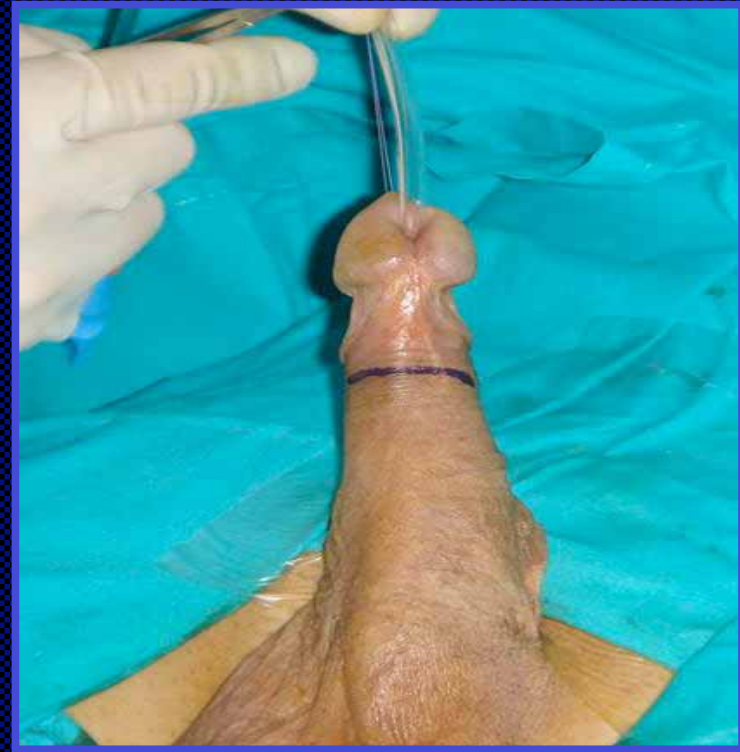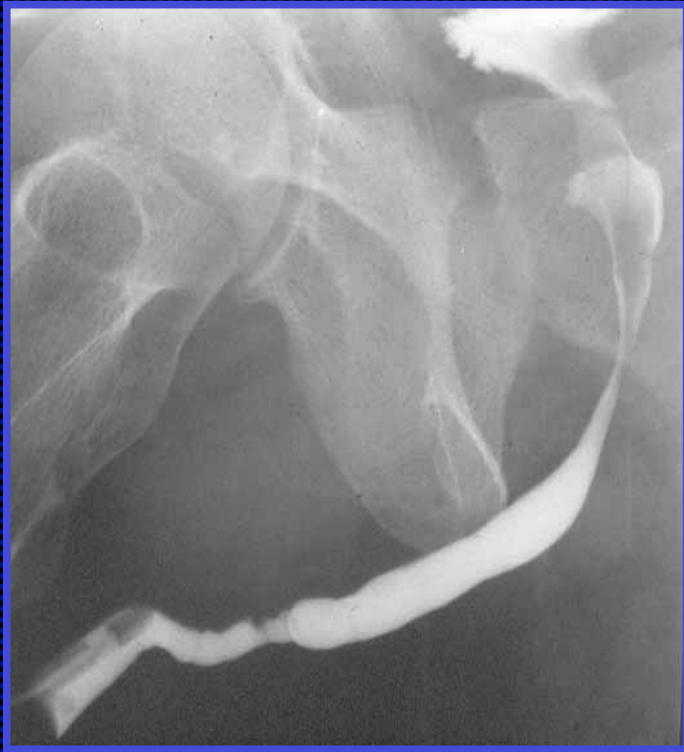Etiology of penile urethral strictures in 404 patients



Barbagli 2006, unpublished data



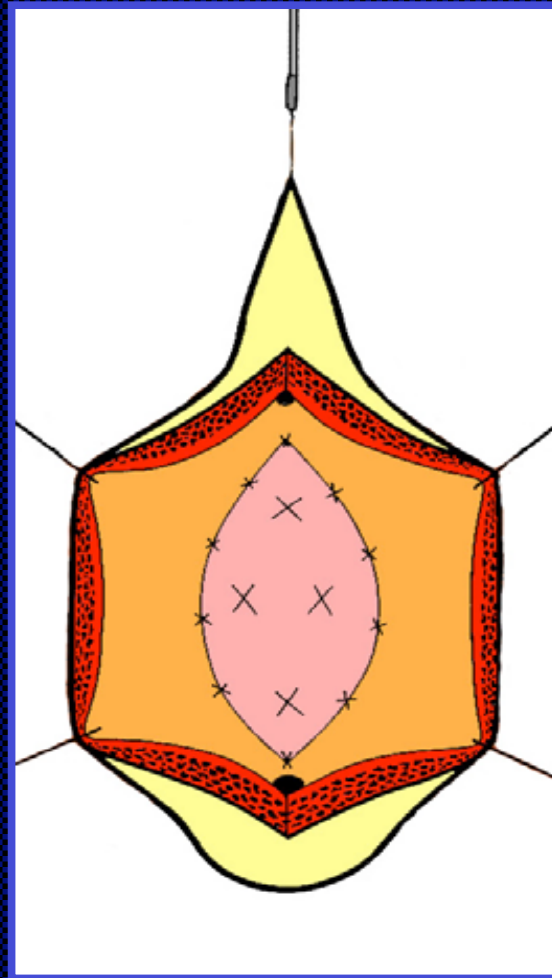
**In patients with penile urethral strictures due to:
trauma, instrumentation, catheter, infection and other causes**

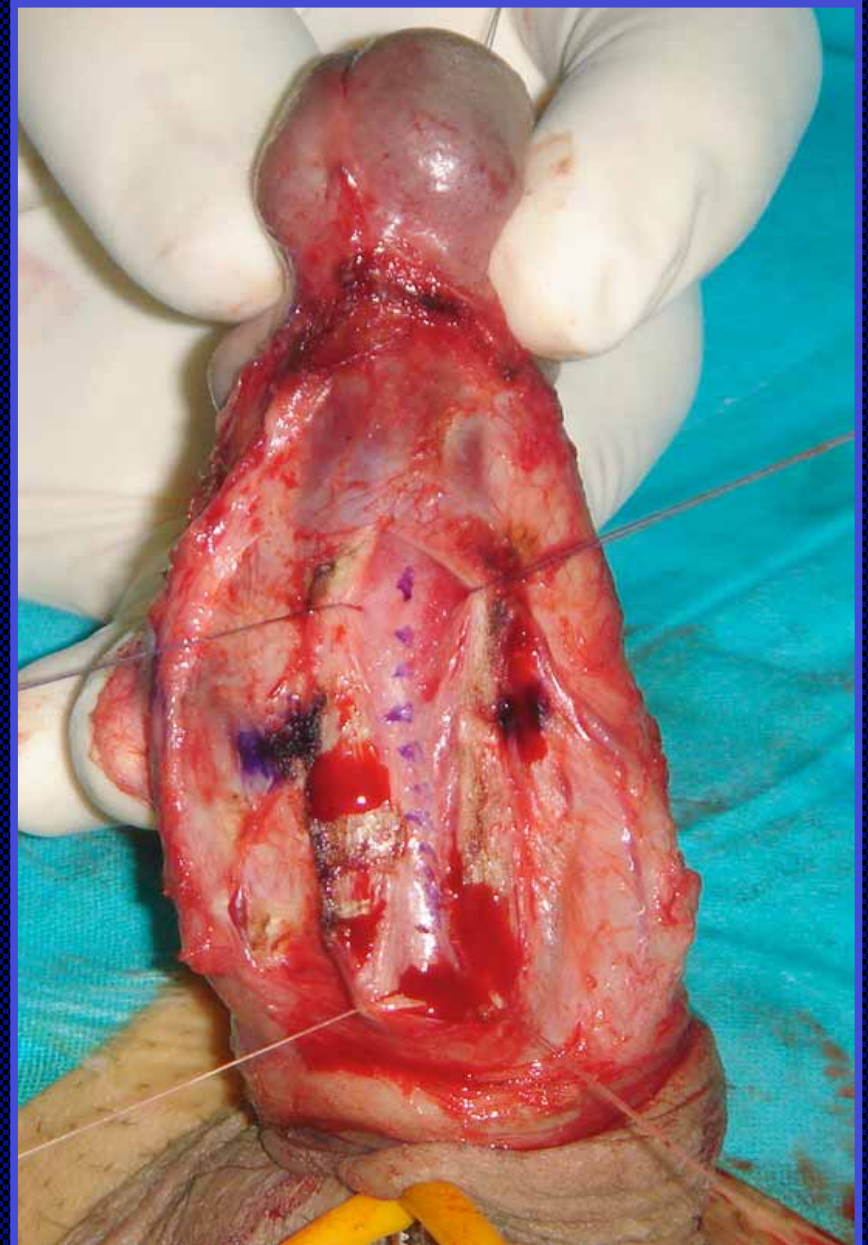
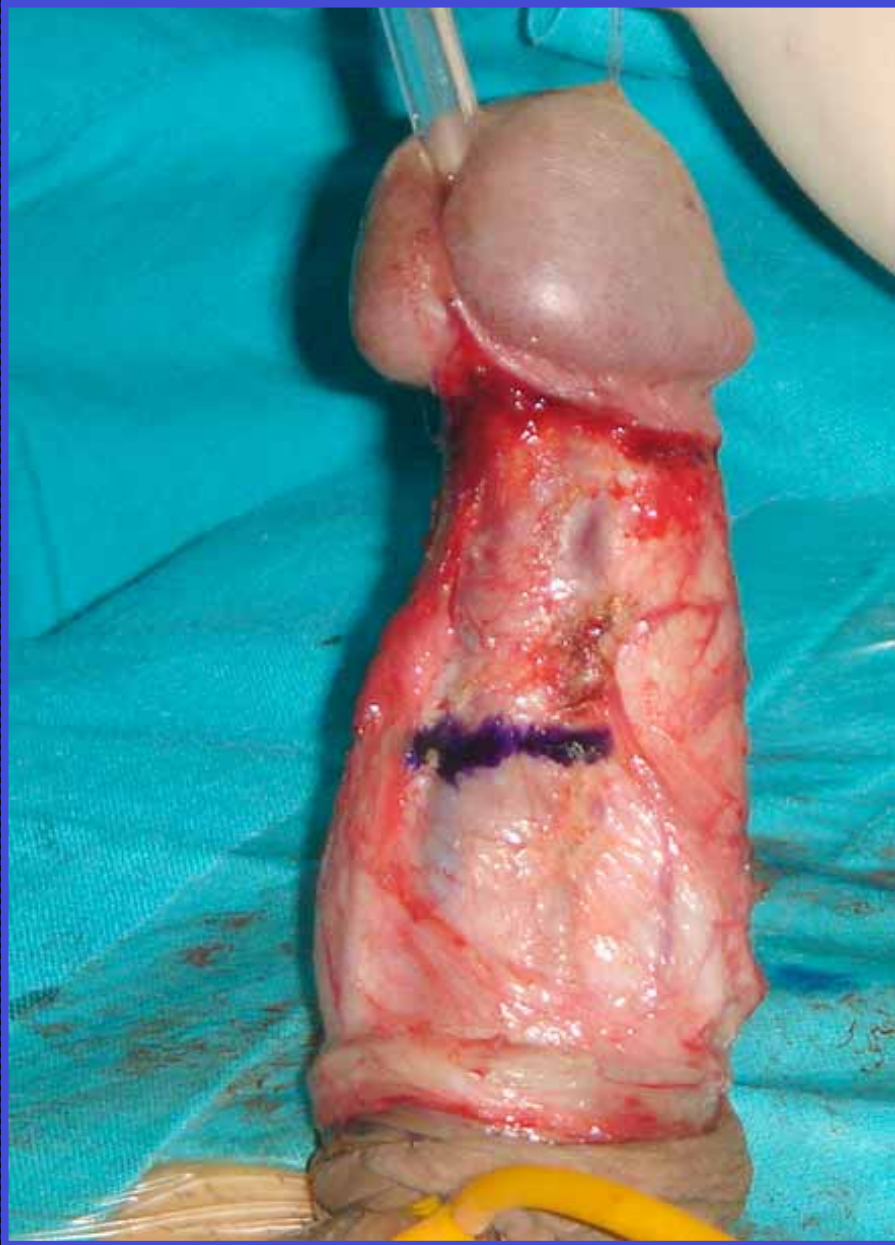

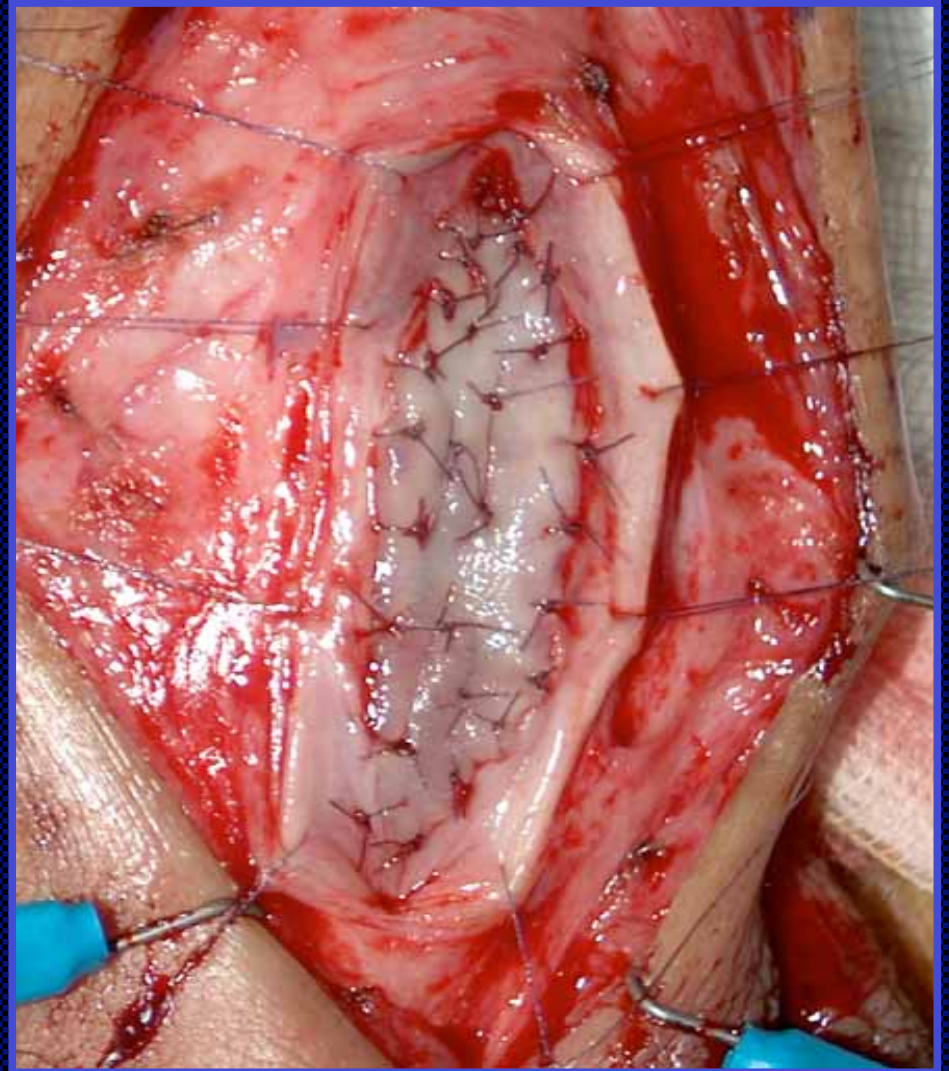
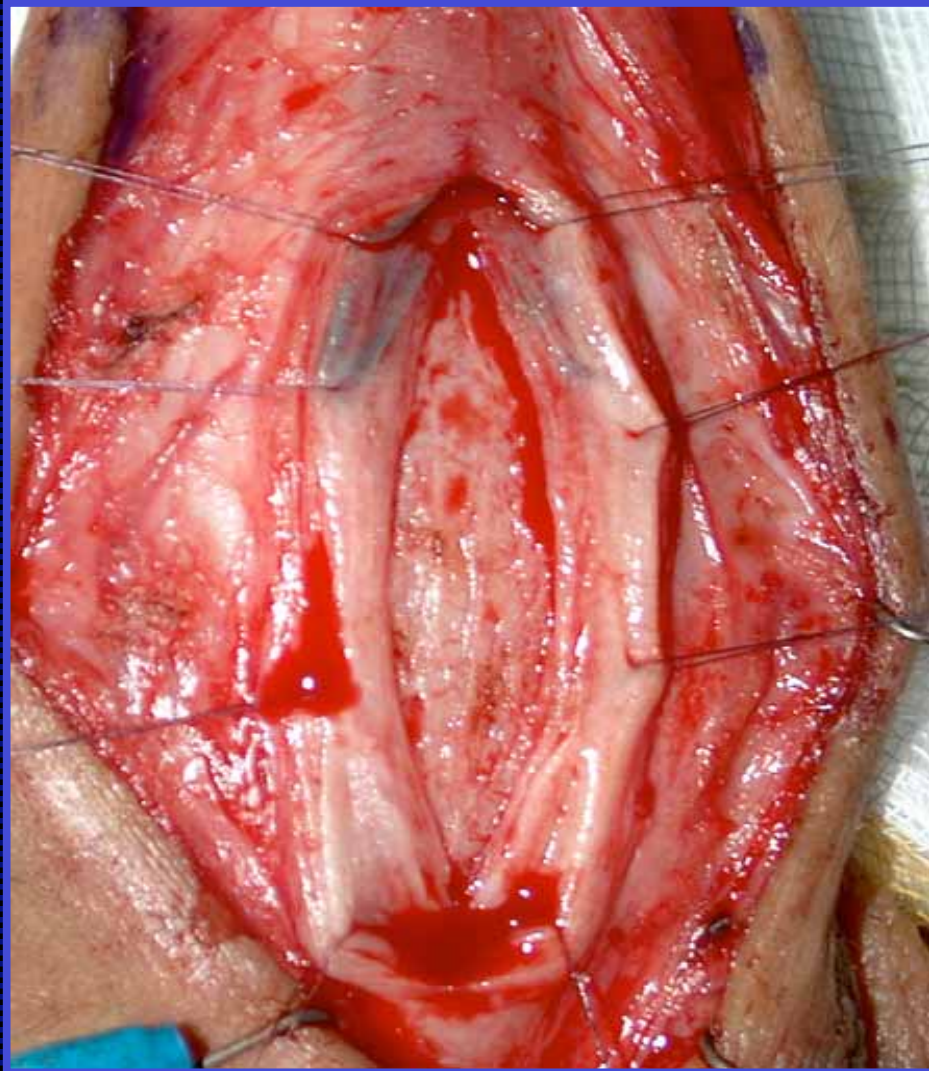
penis is normal

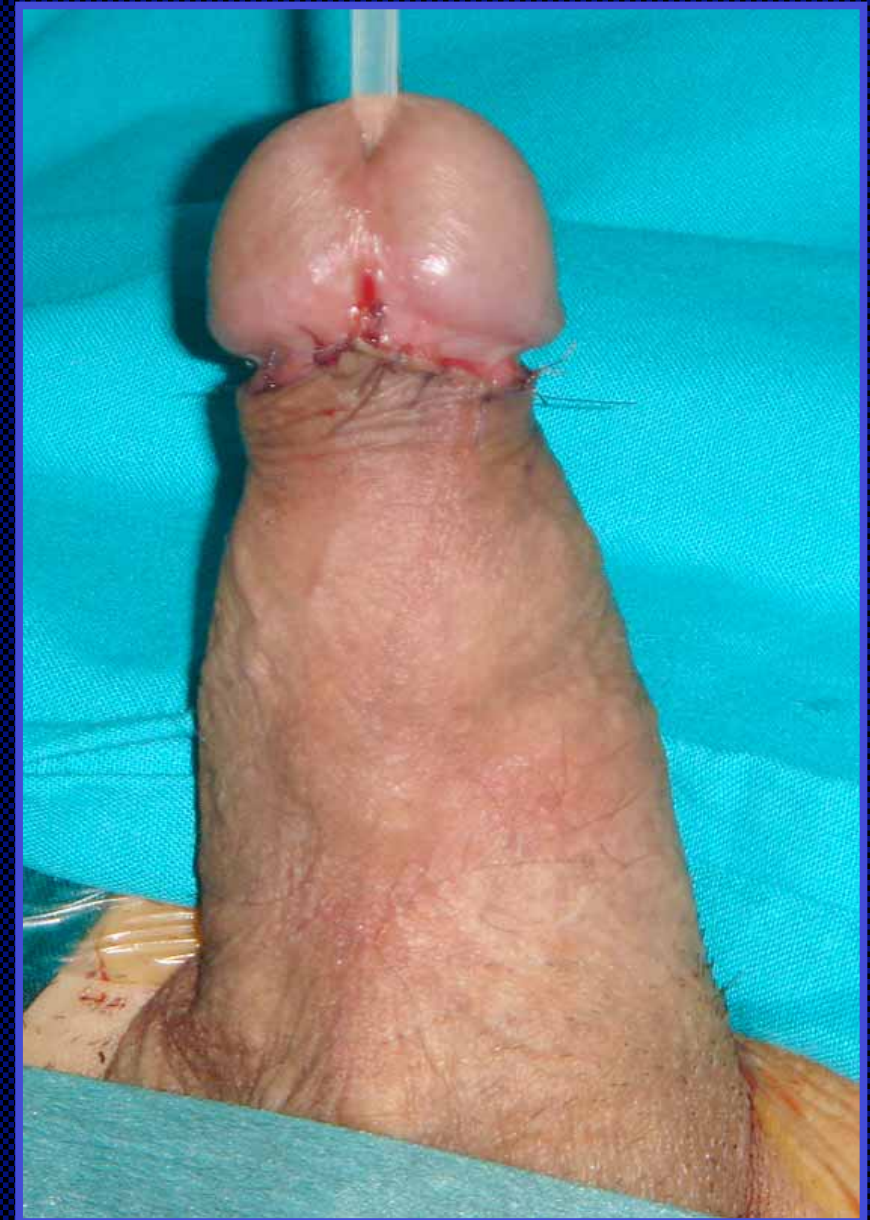
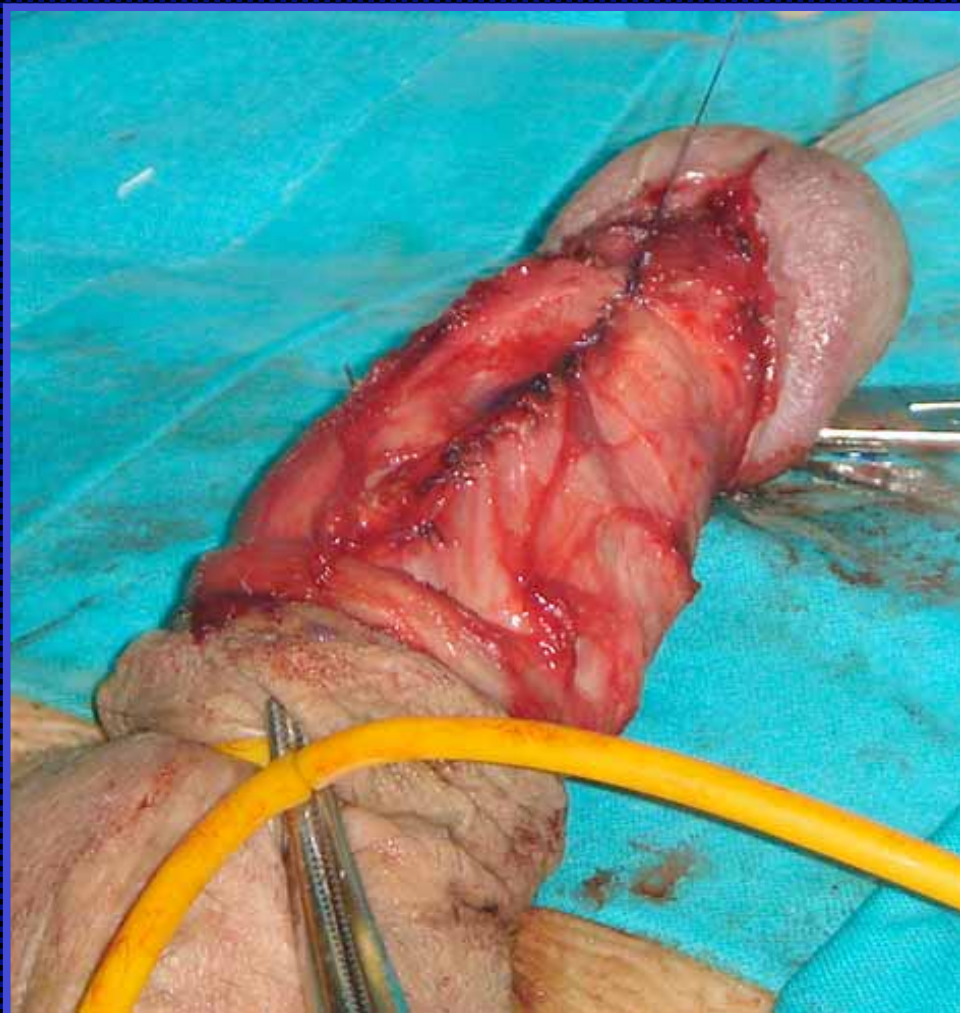
One-stage dorsal inlay buccal mucosal graft urethroplasty

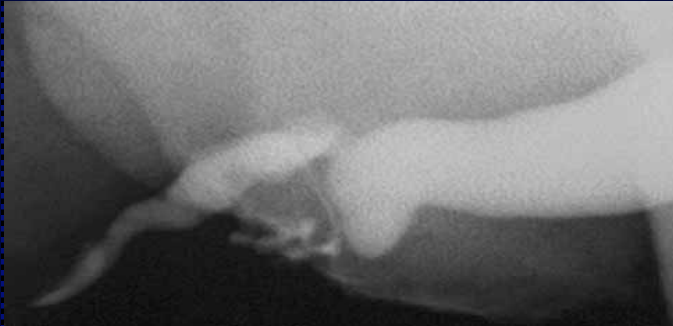




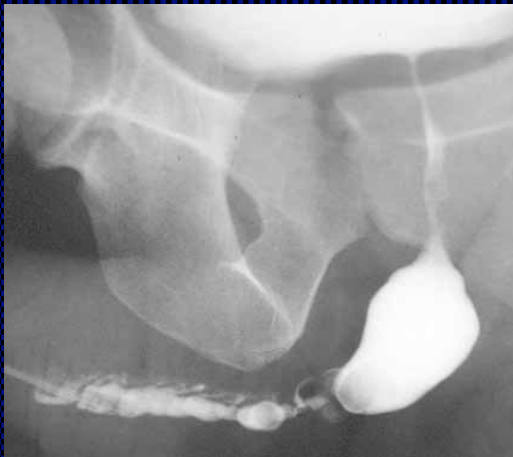
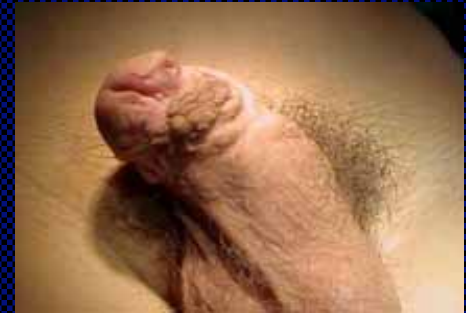

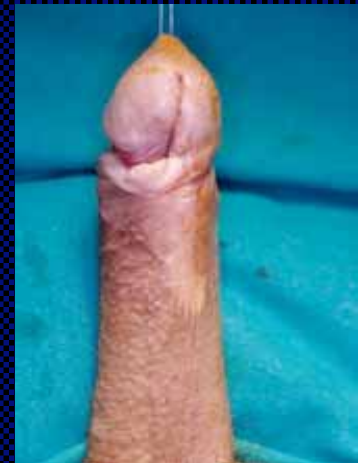In patients with penile urethral strictures due to:



**failed hypospadias
repair**



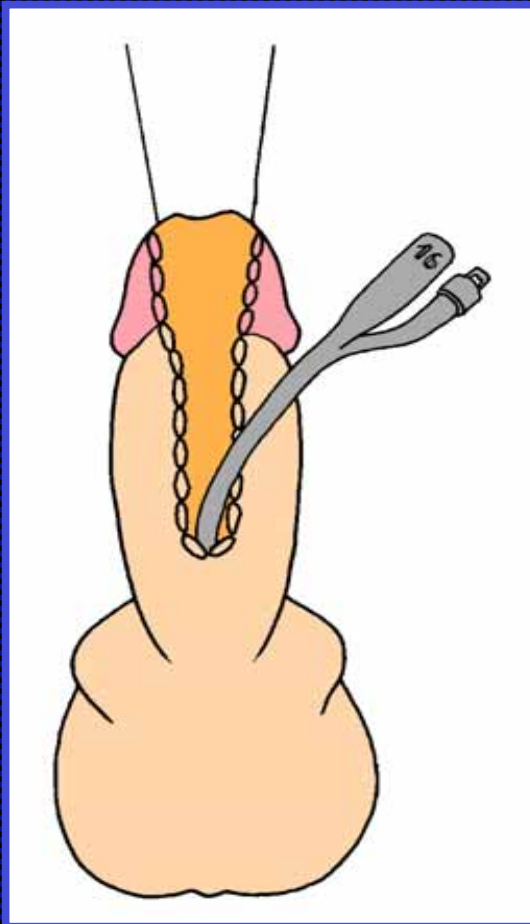
lichen sclerosus

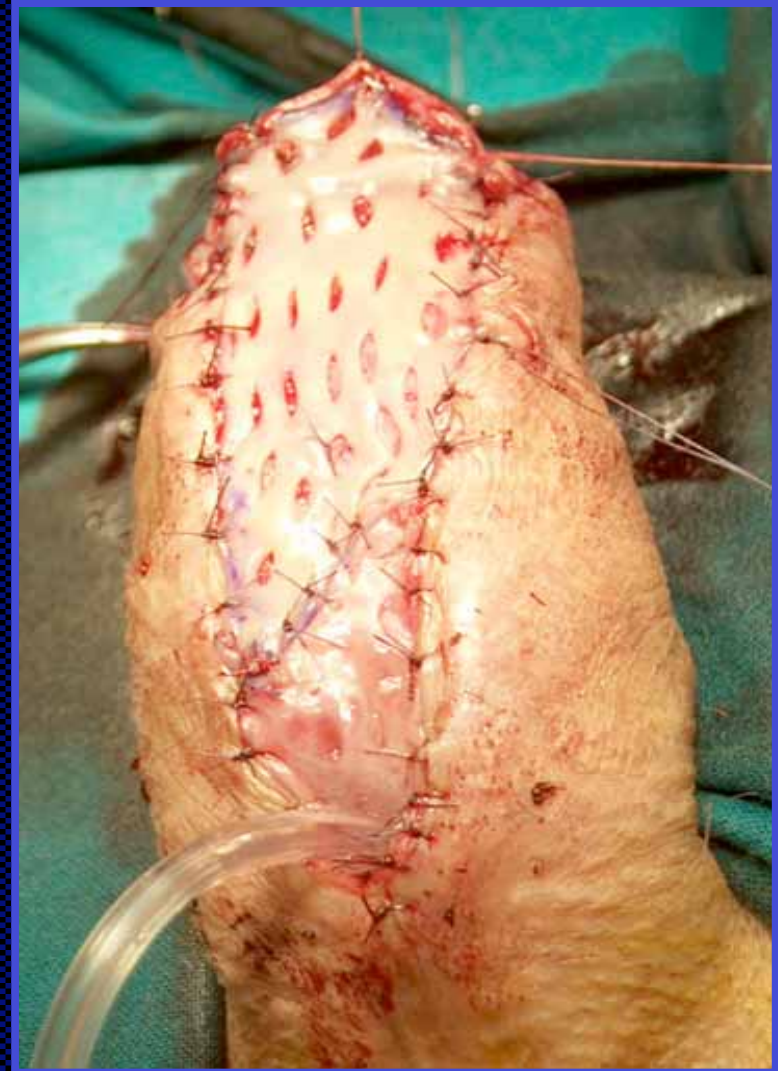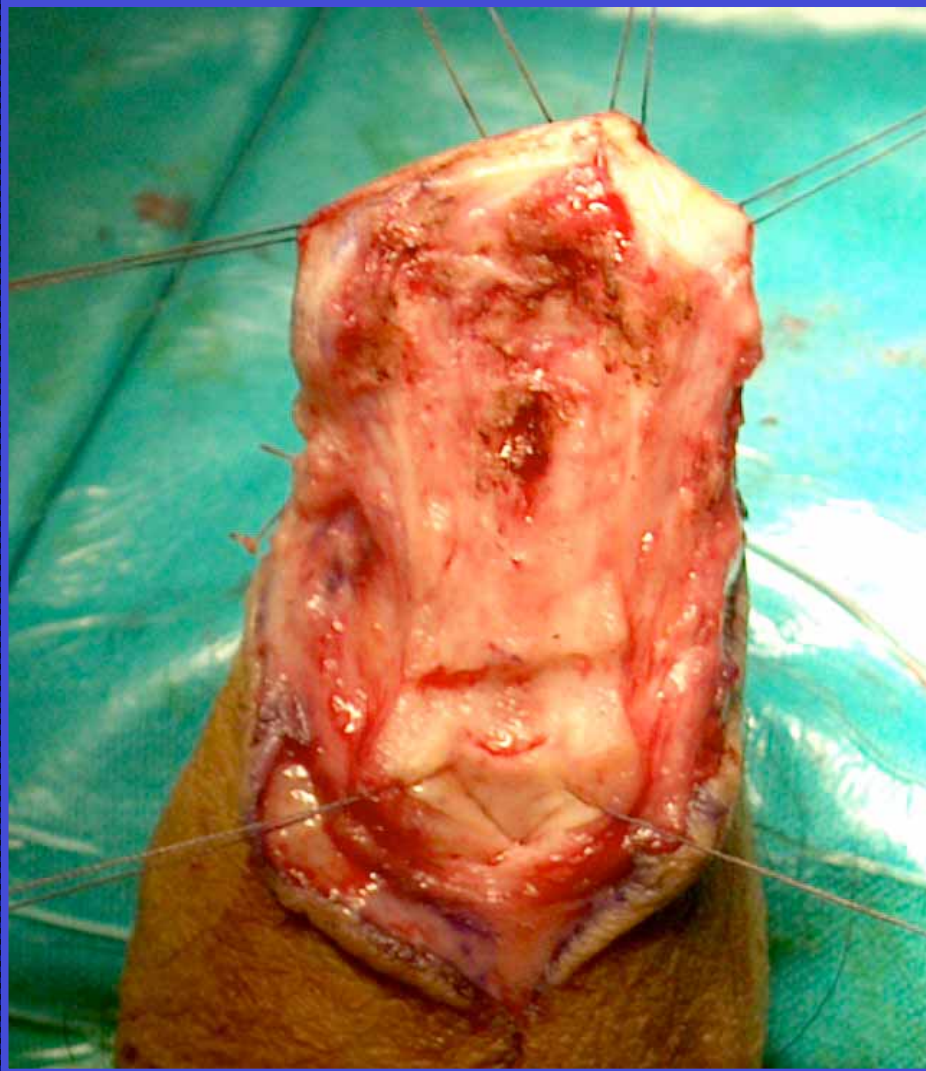


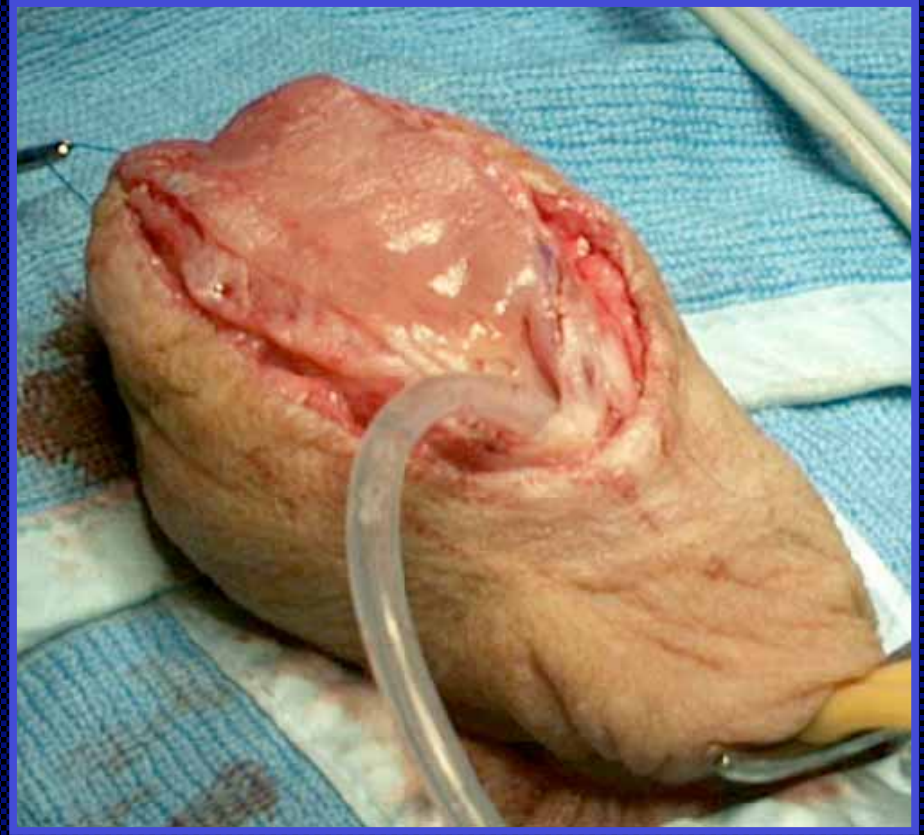
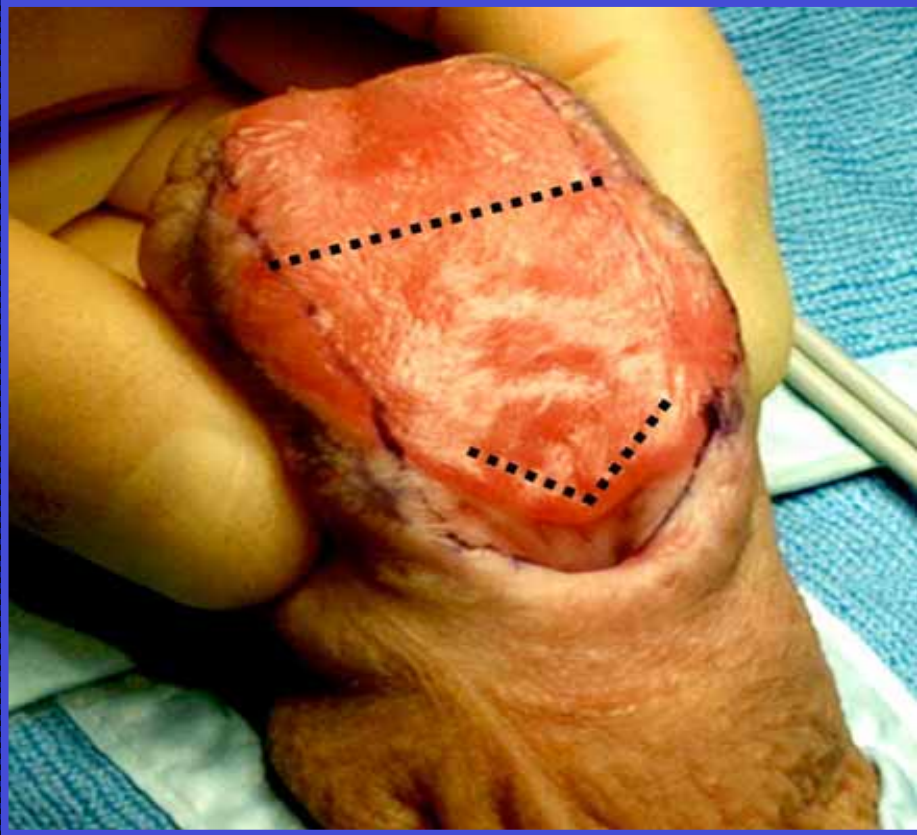penis is abnormal

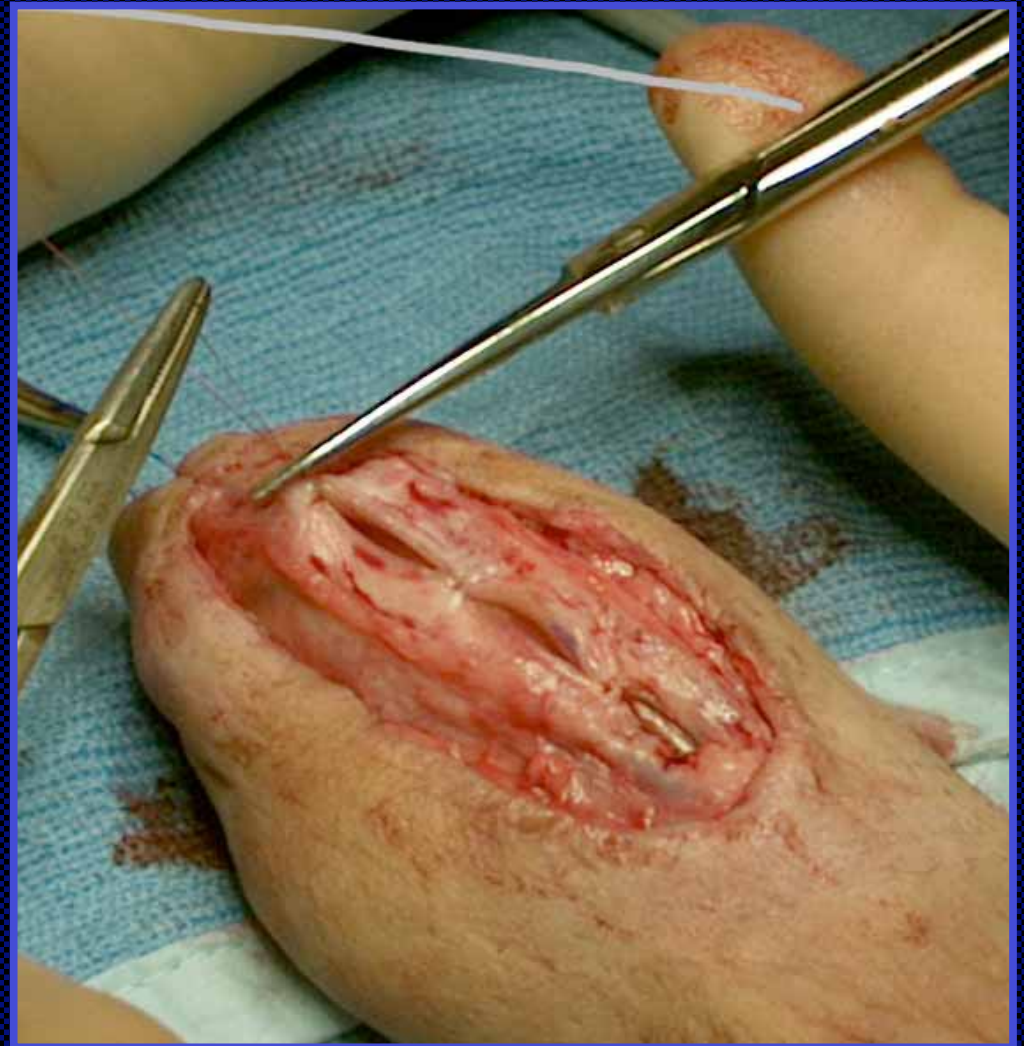
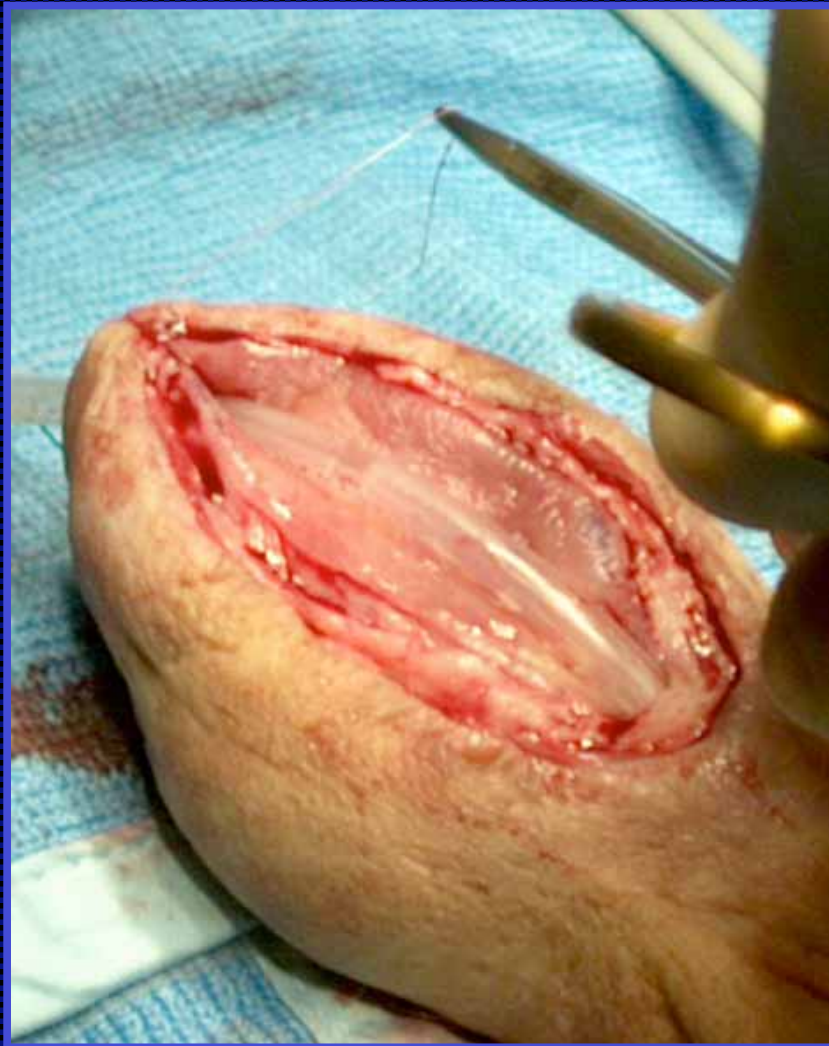
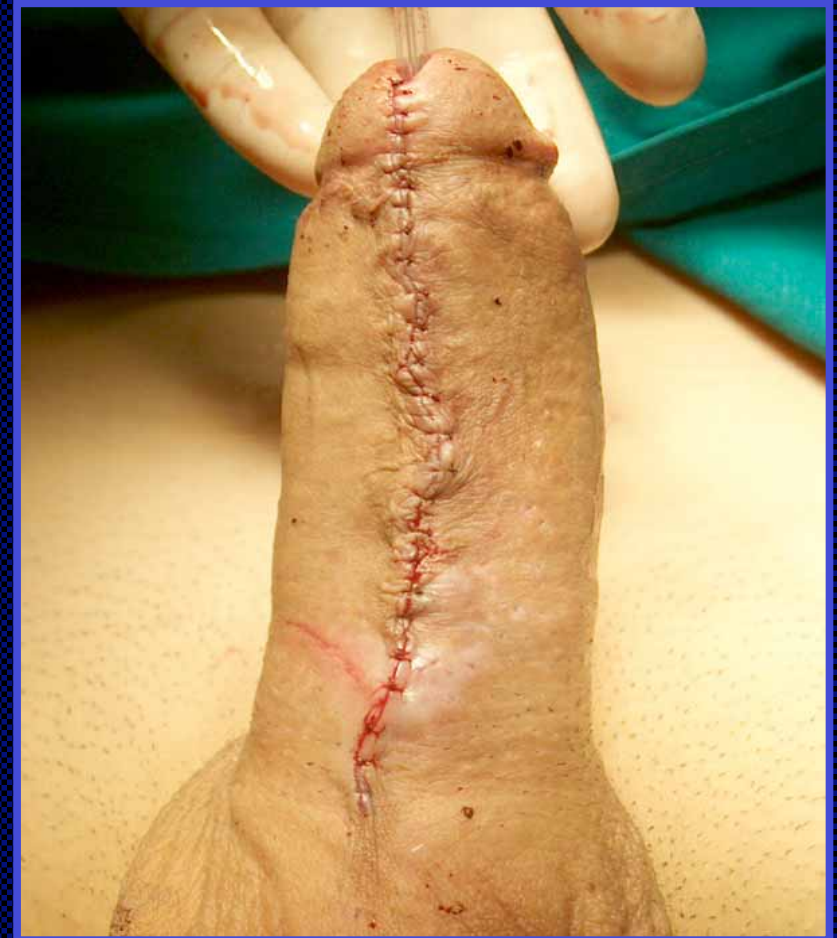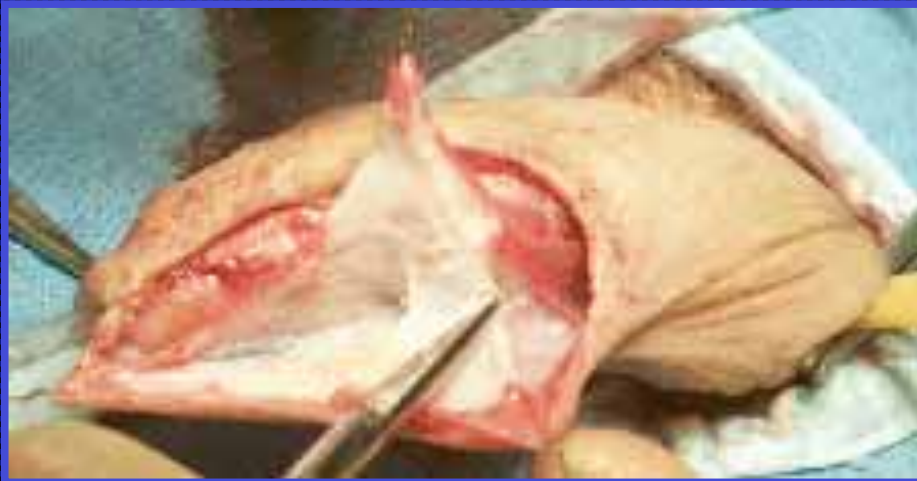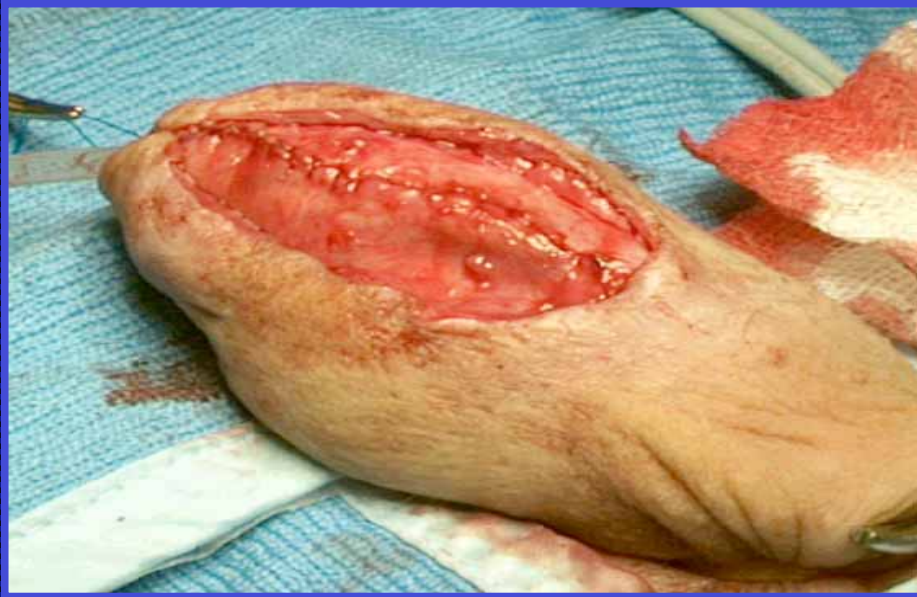Multi-stage buccal mucosal graft urethroplasty





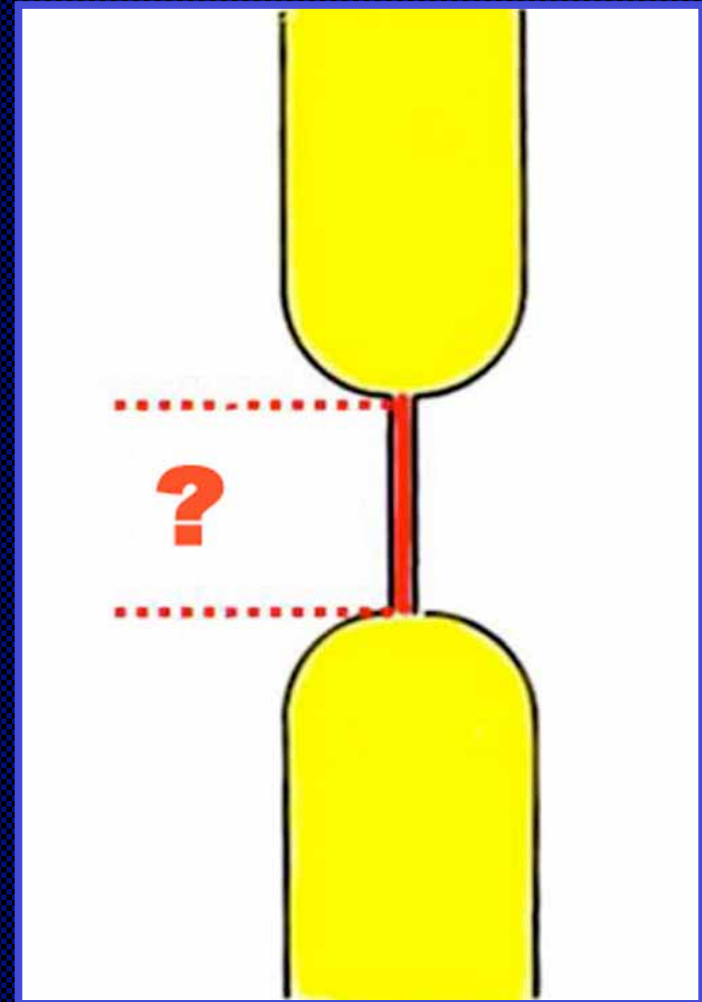






Bulbar urethroplasty

The surgical technique
for the repair of bulbar
urethral strictures is
selected according to
stricture length



Bulbar urethroplasty using buccal mucosal graft

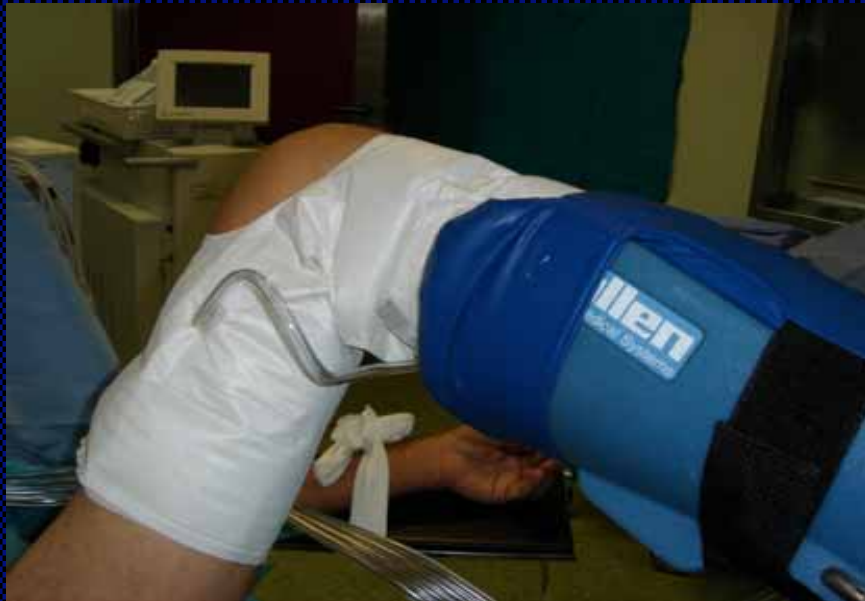■ Dorsal onlay techniques:

- Augmented roof-strip anastomosis
- Dorsal onlay graft urethroplasty

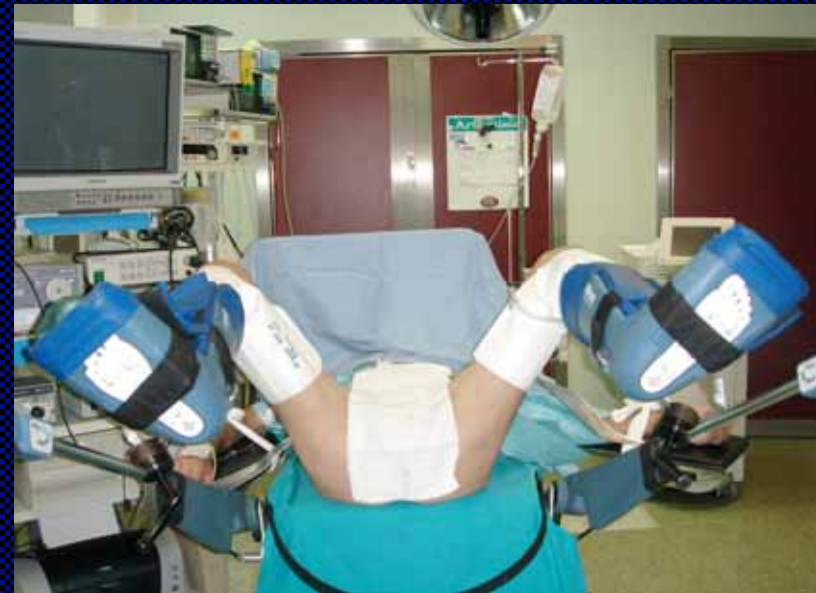■ Ventral onlay technique



Preparation of the patient

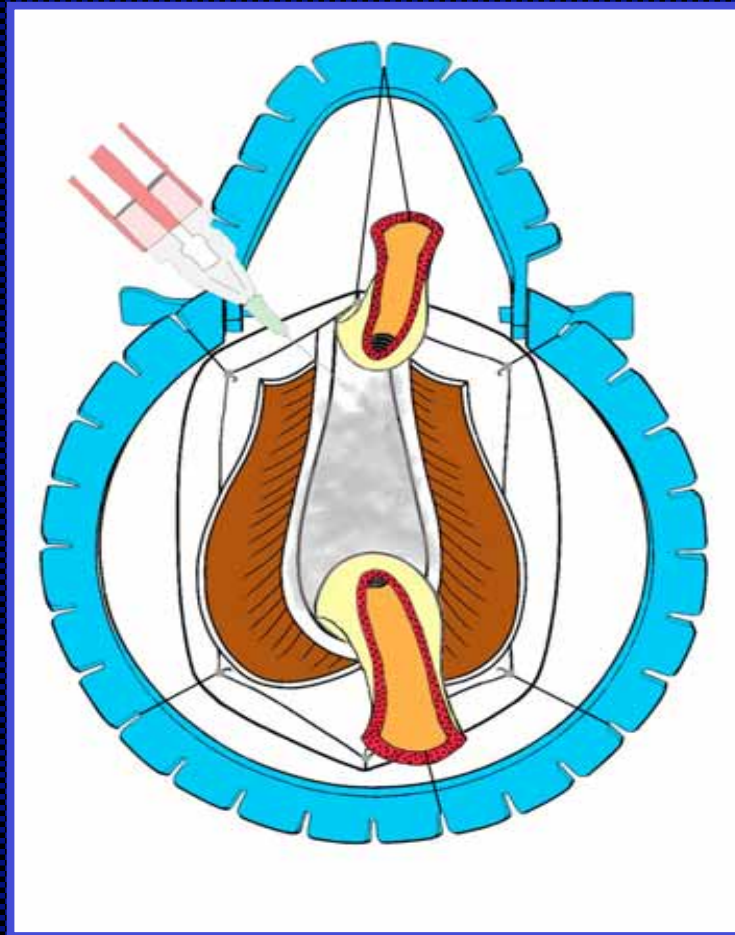


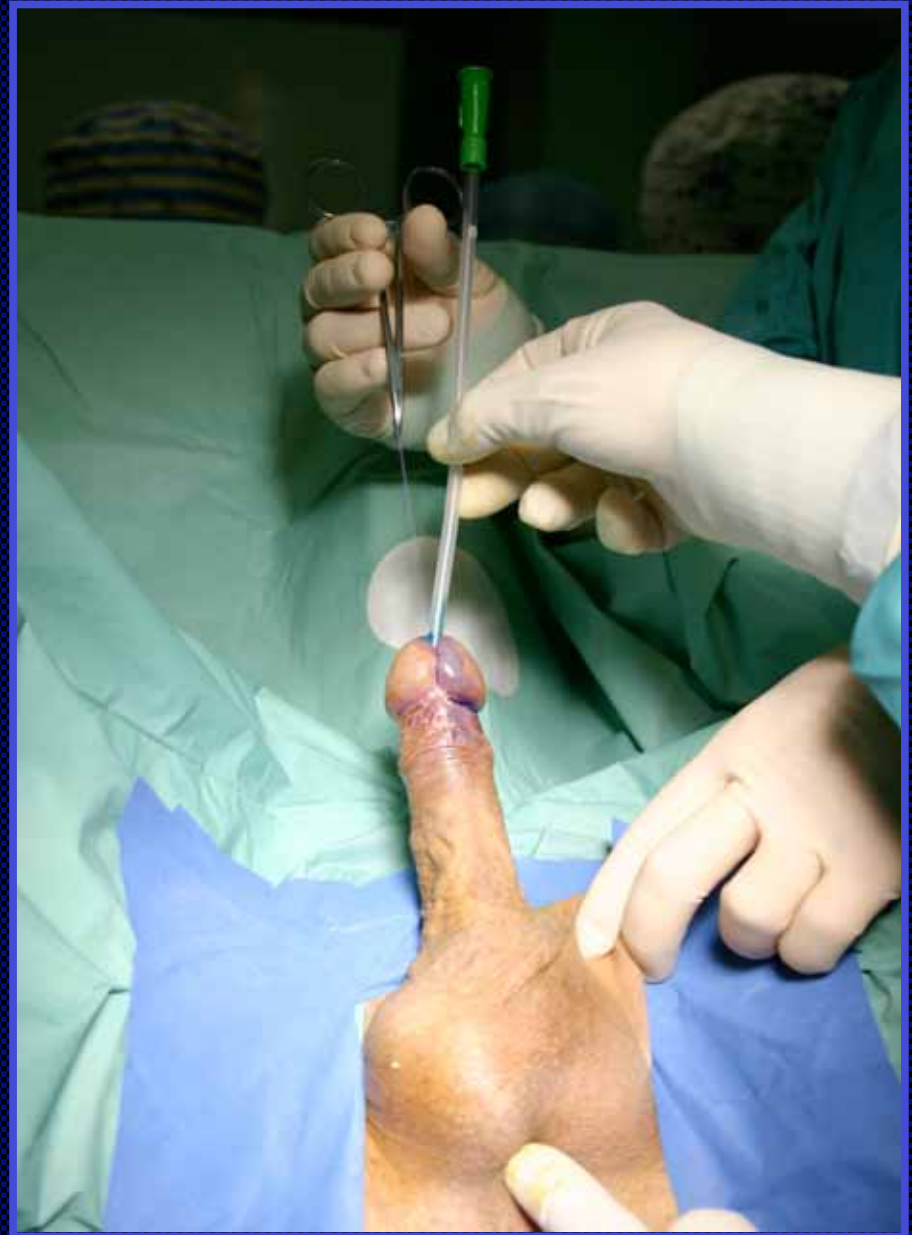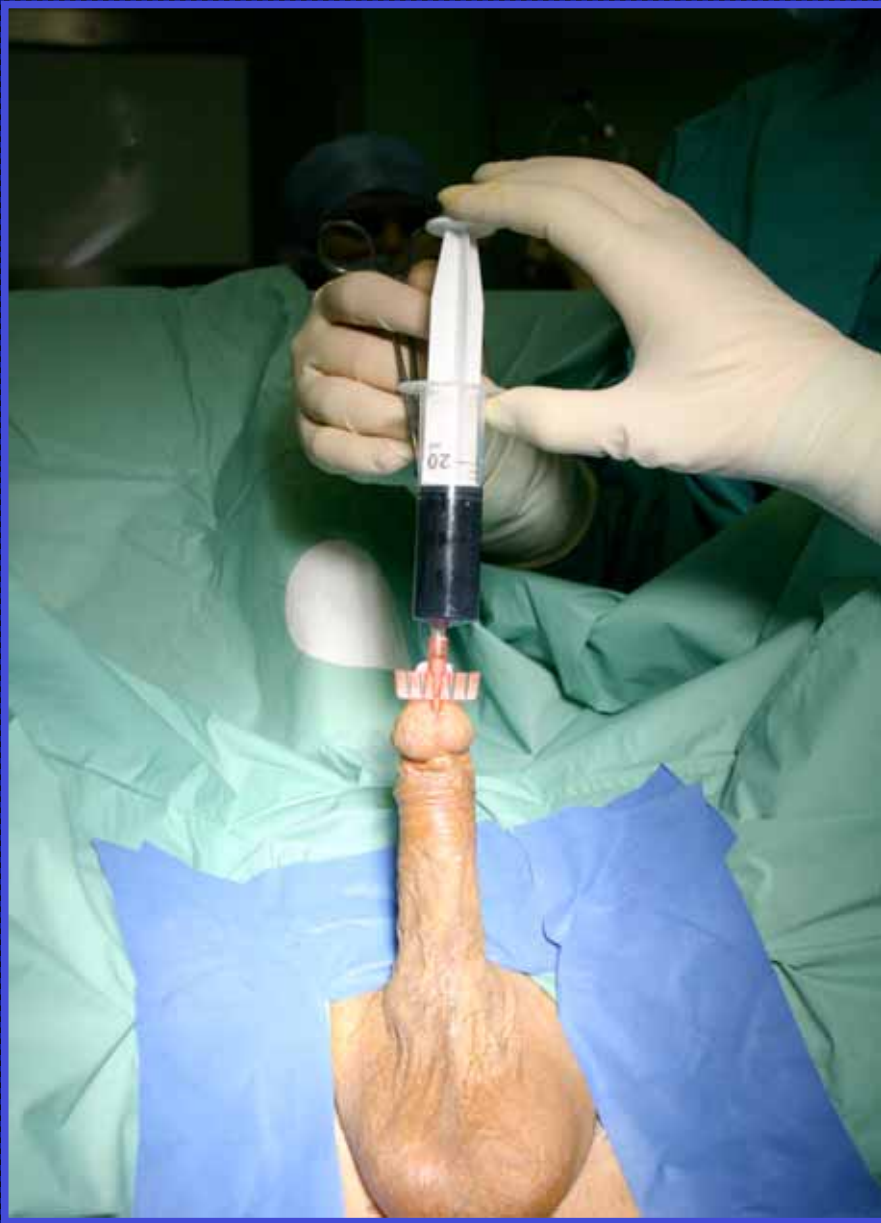
Allen stirrups with sequential inflatable compression sleeves

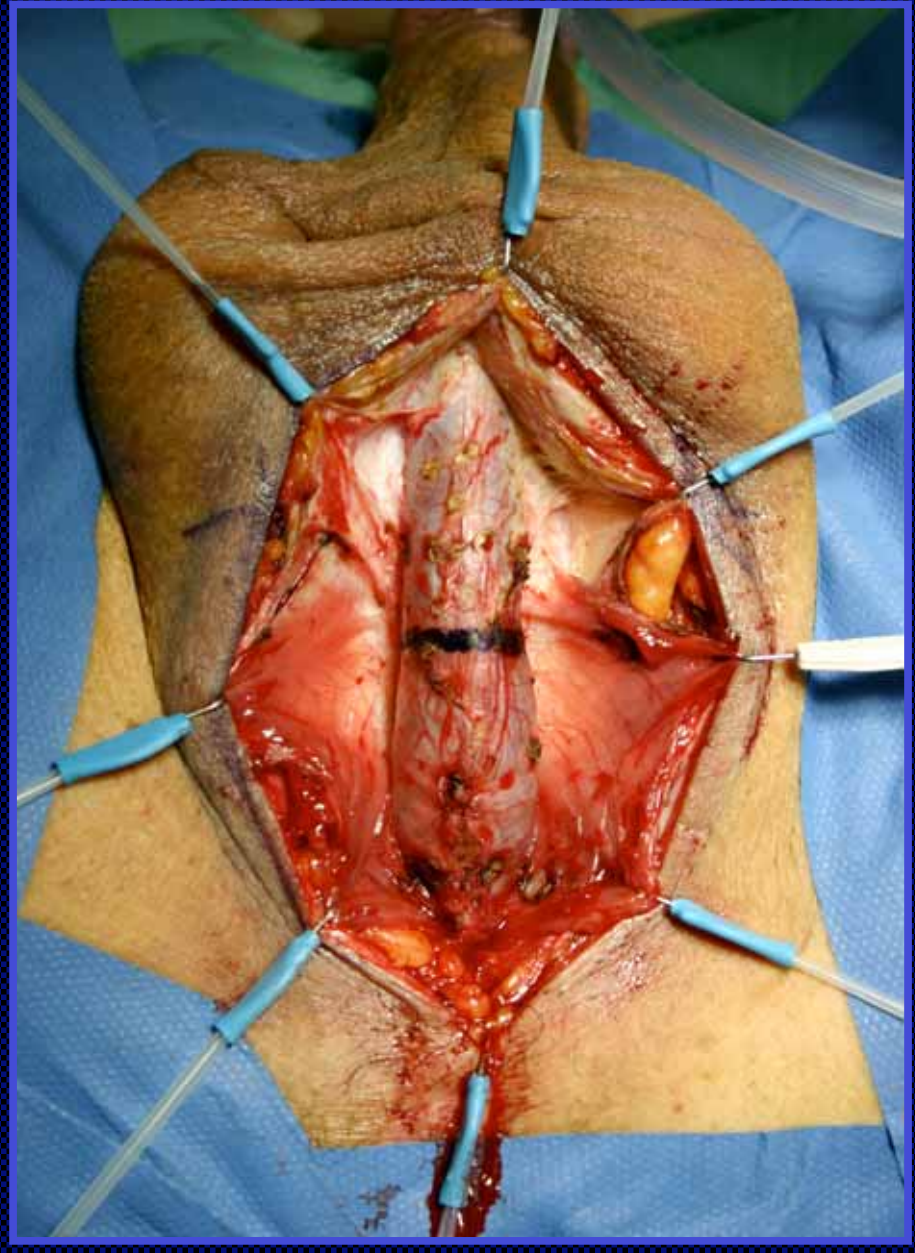
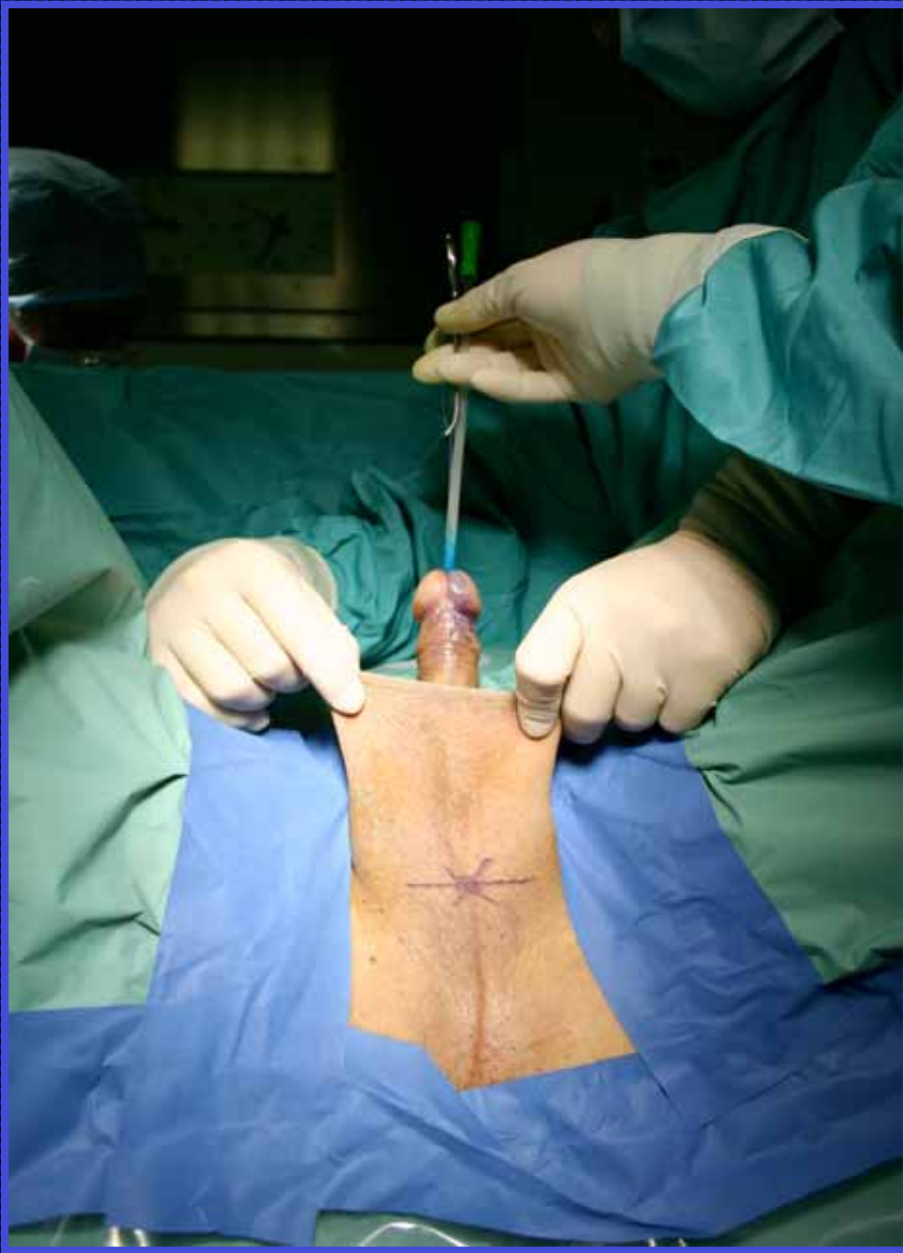

Simple lithotomy position

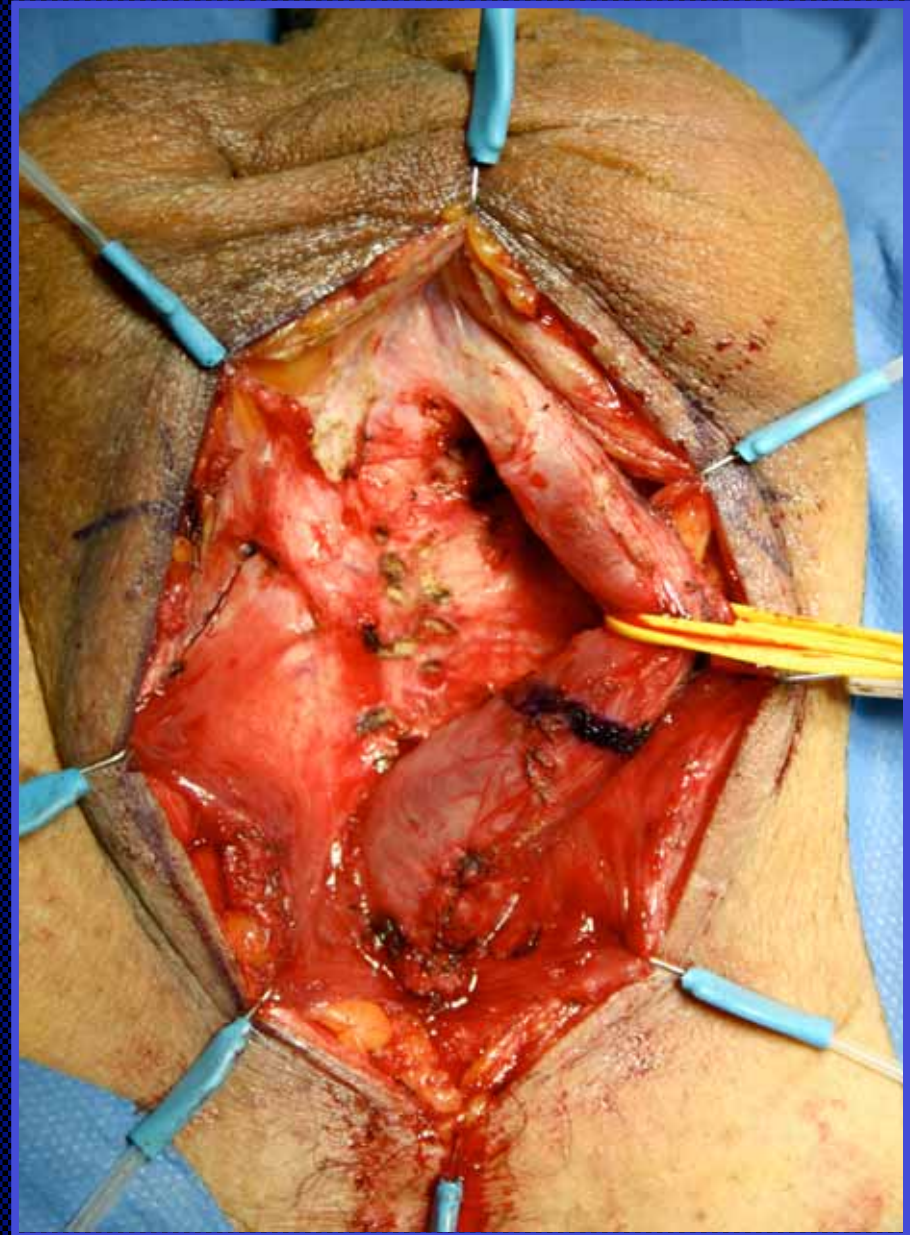
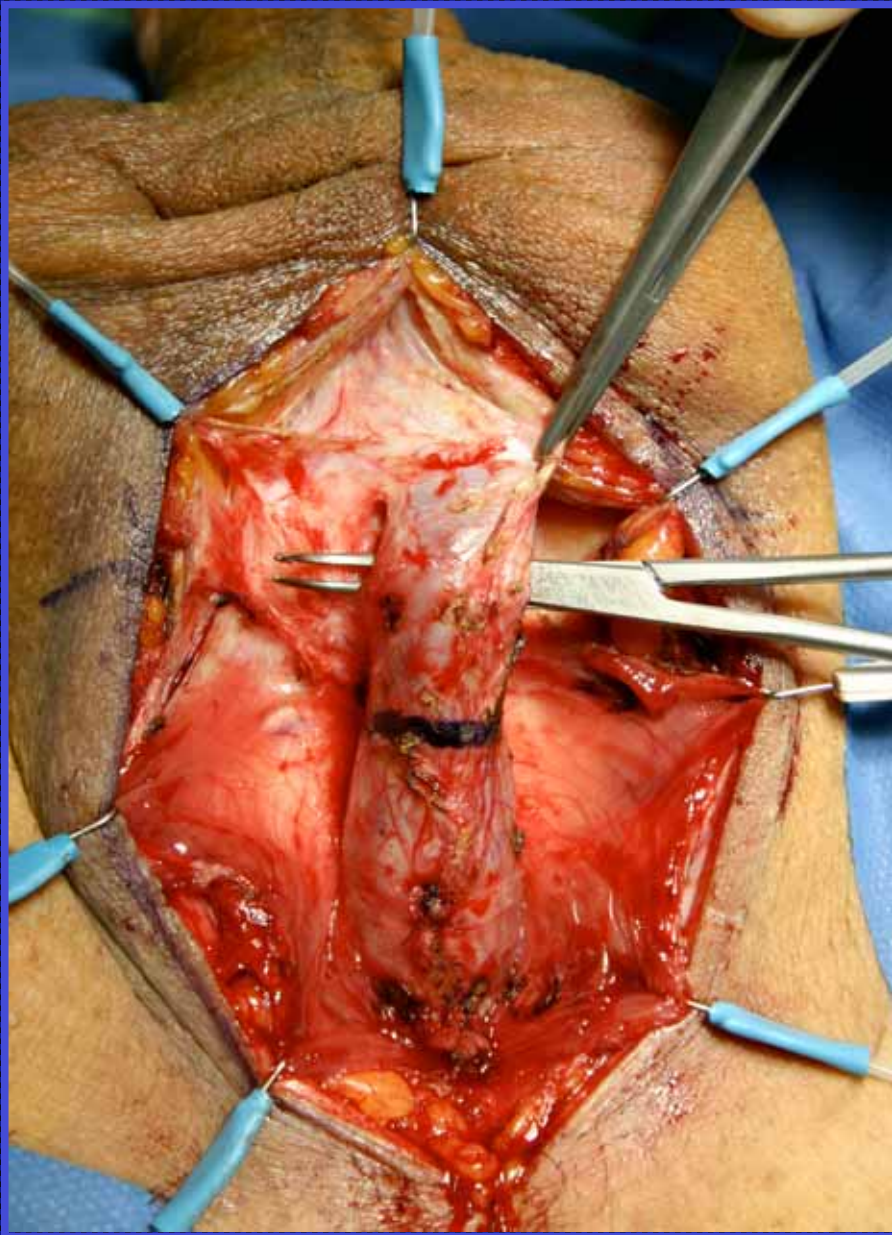
Augmented roof-strip anastomosis using buccal mucosal graft with fibrin glue

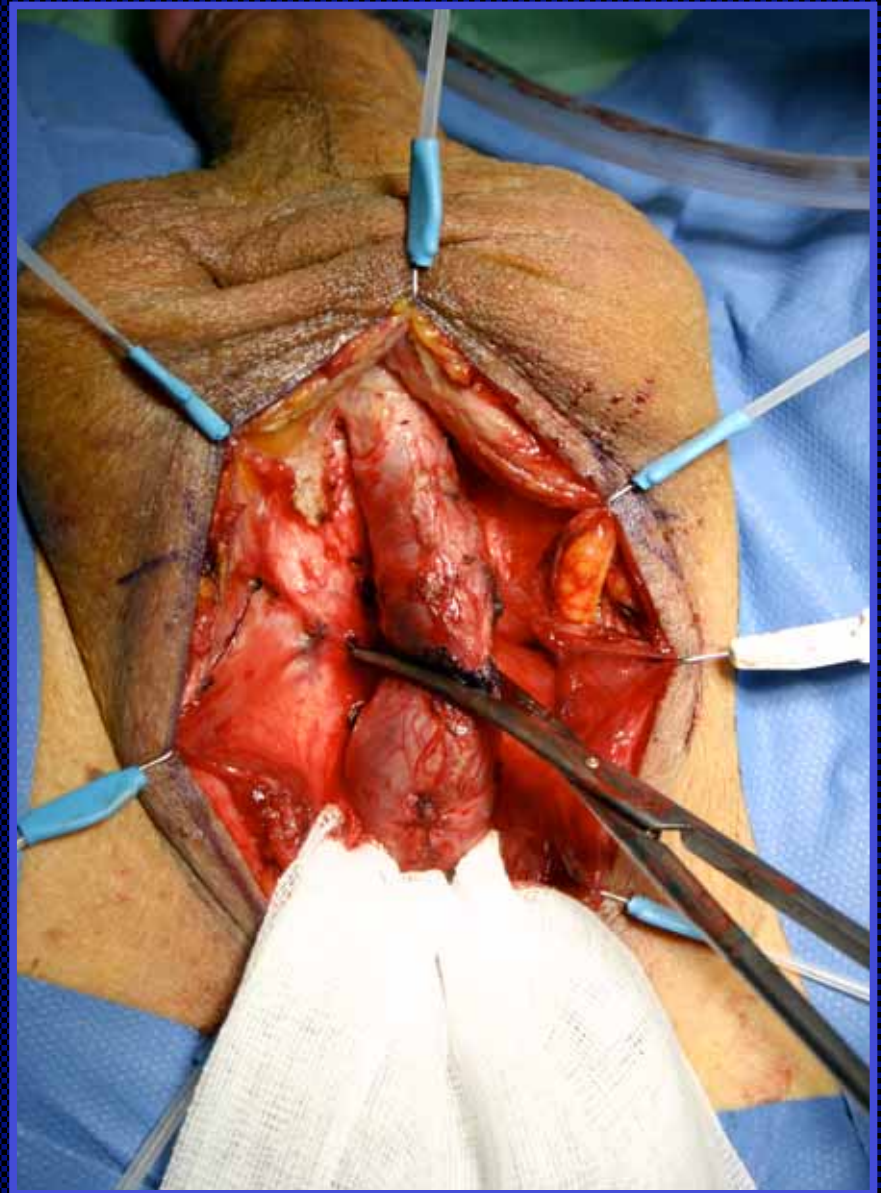
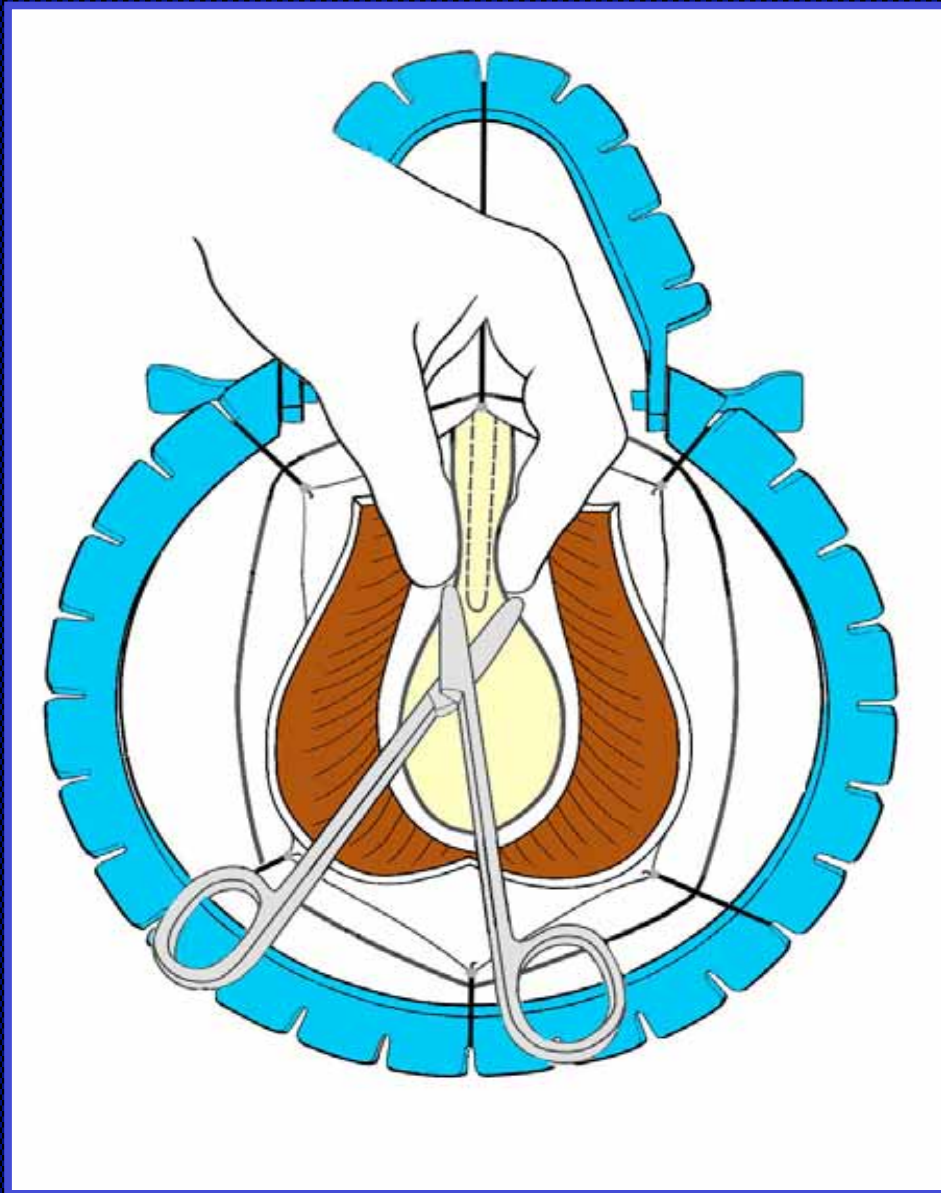


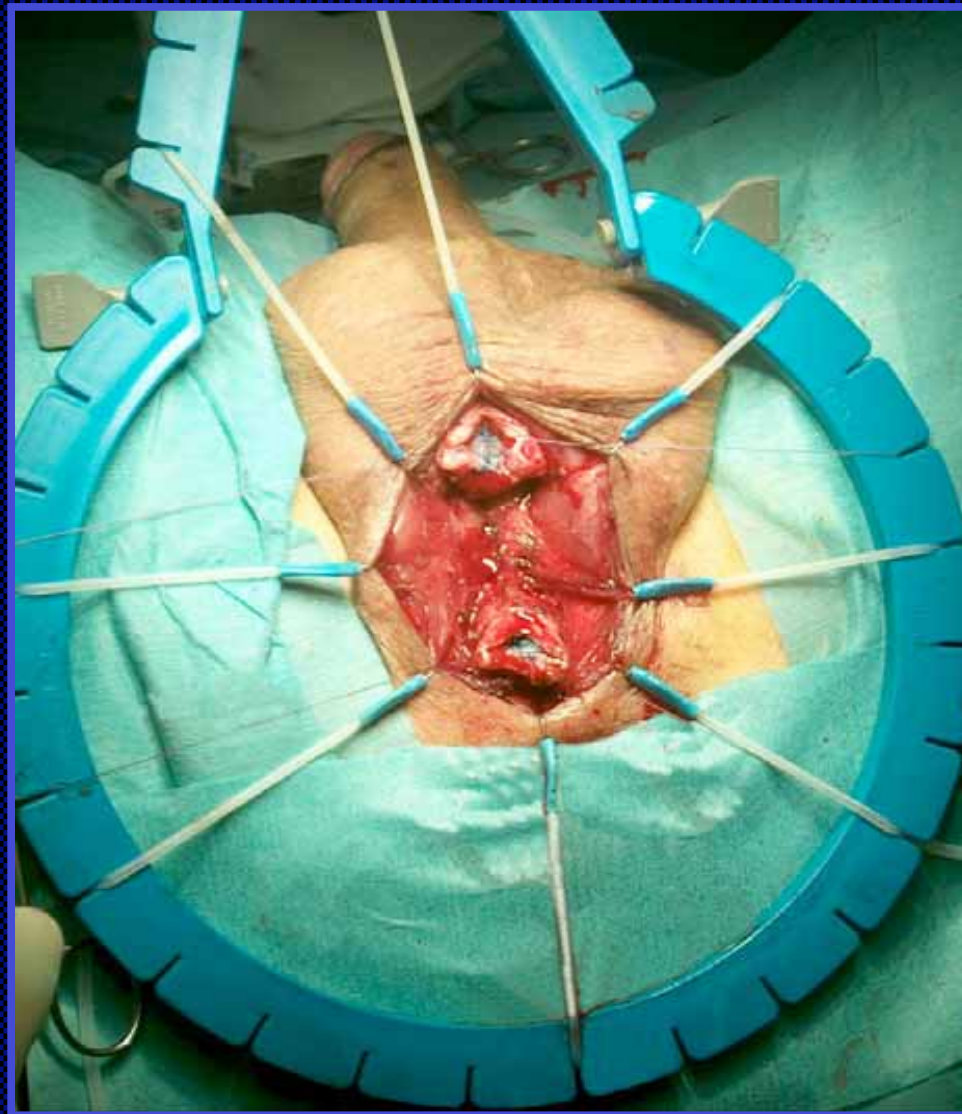
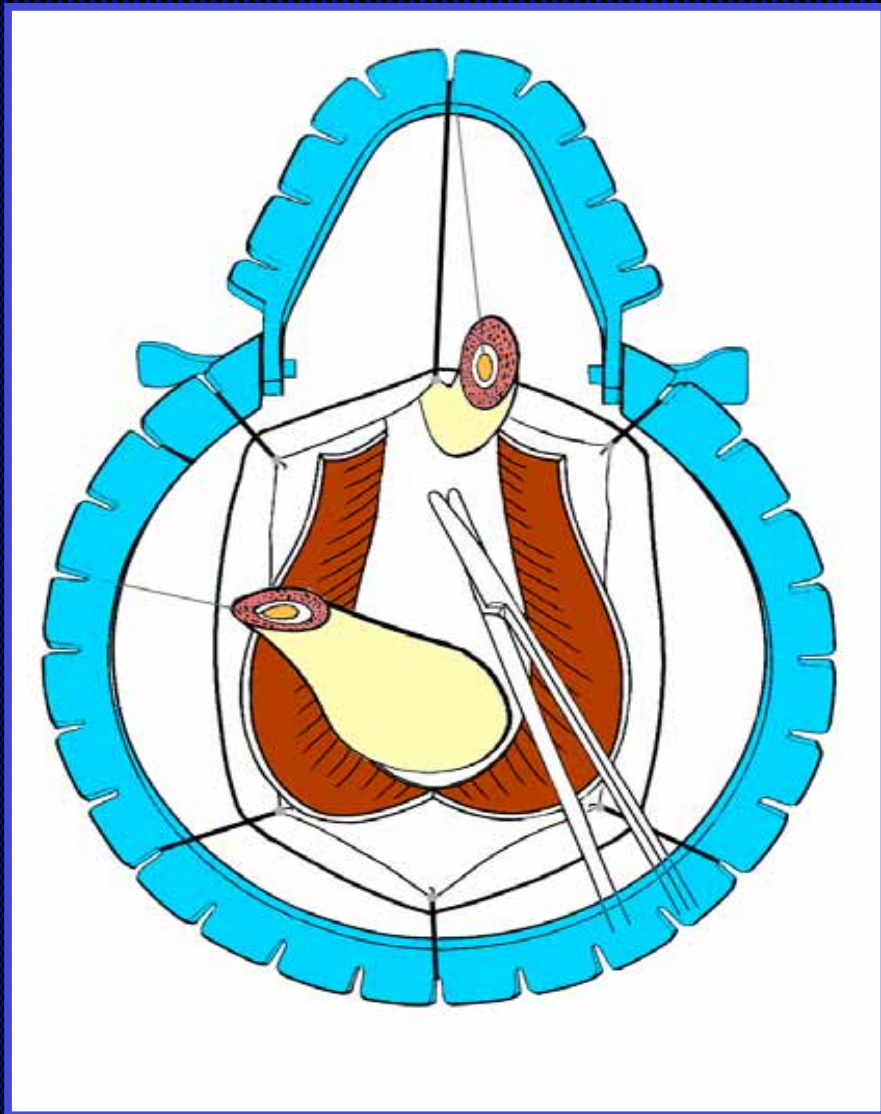


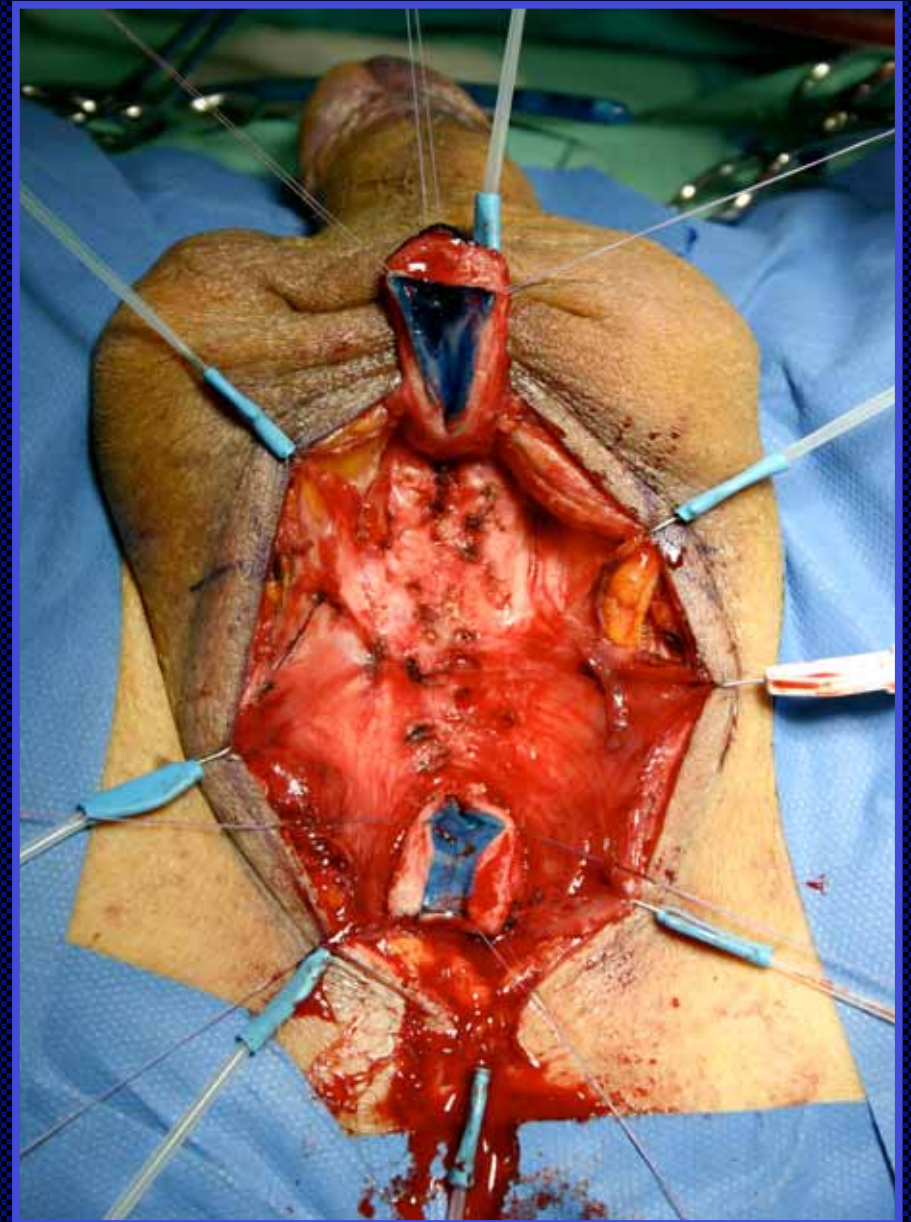
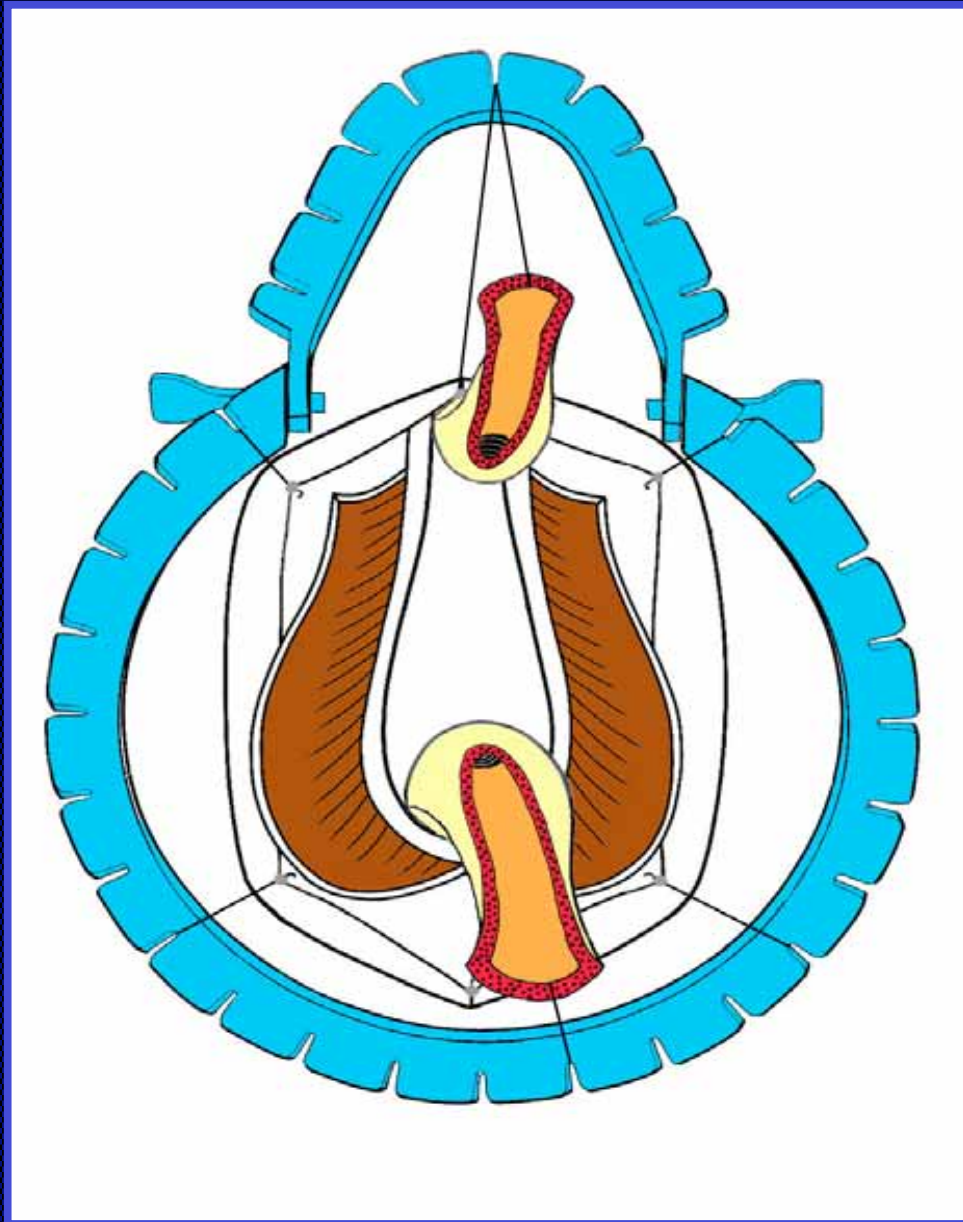


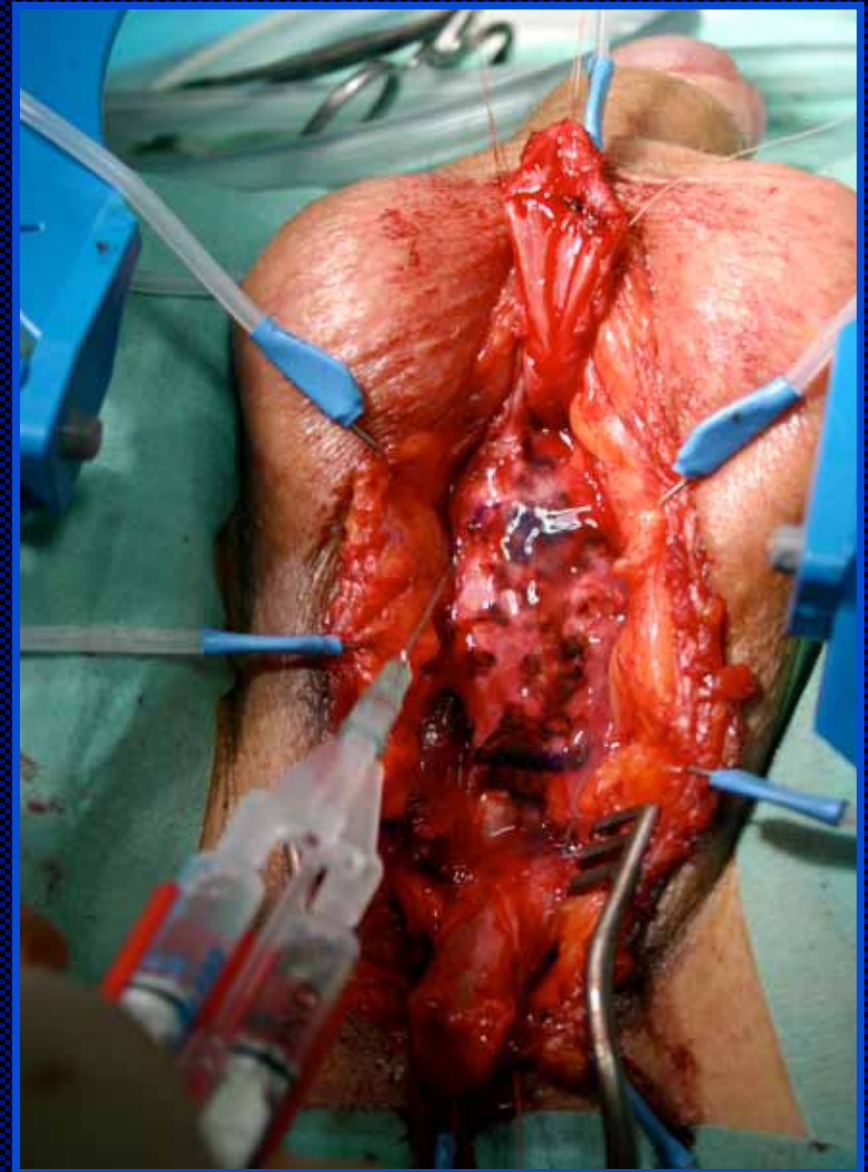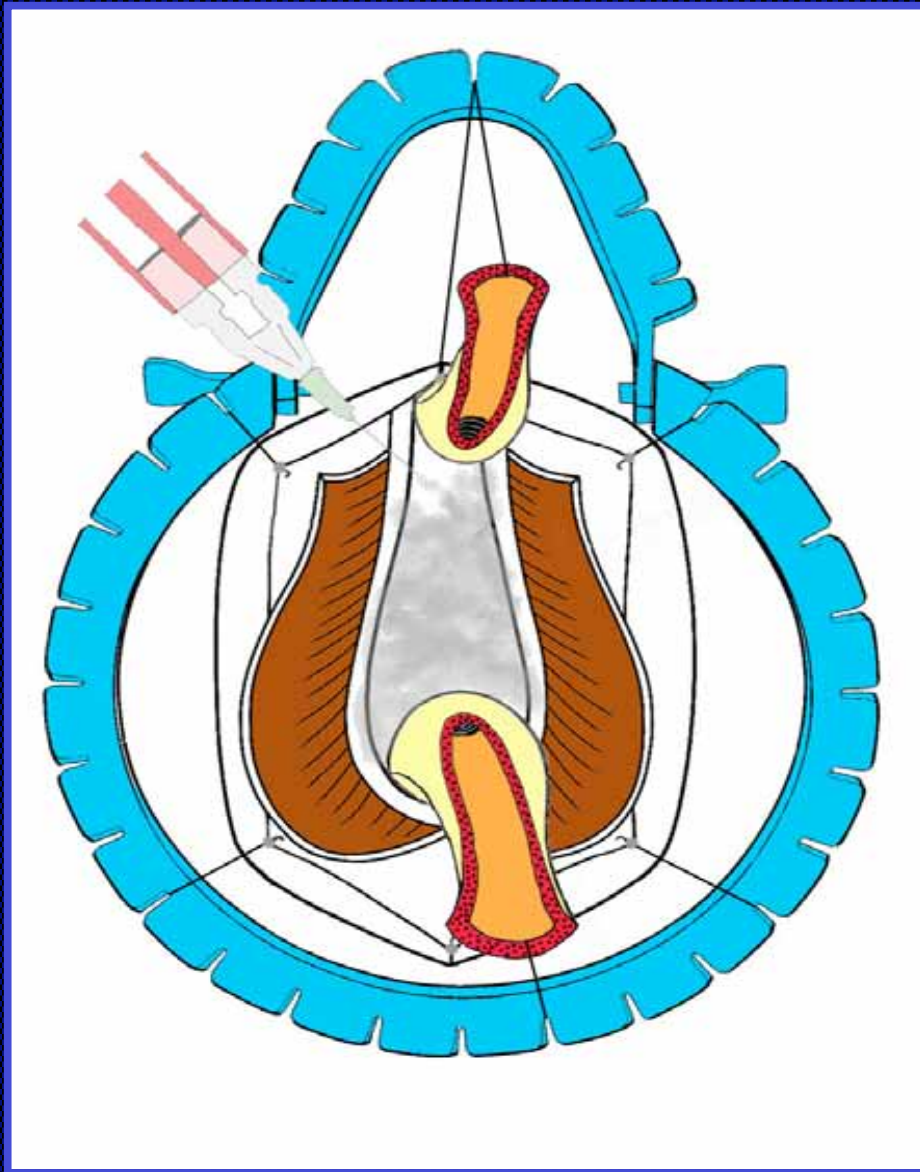
Center for Reconstructive Urethral Surgery

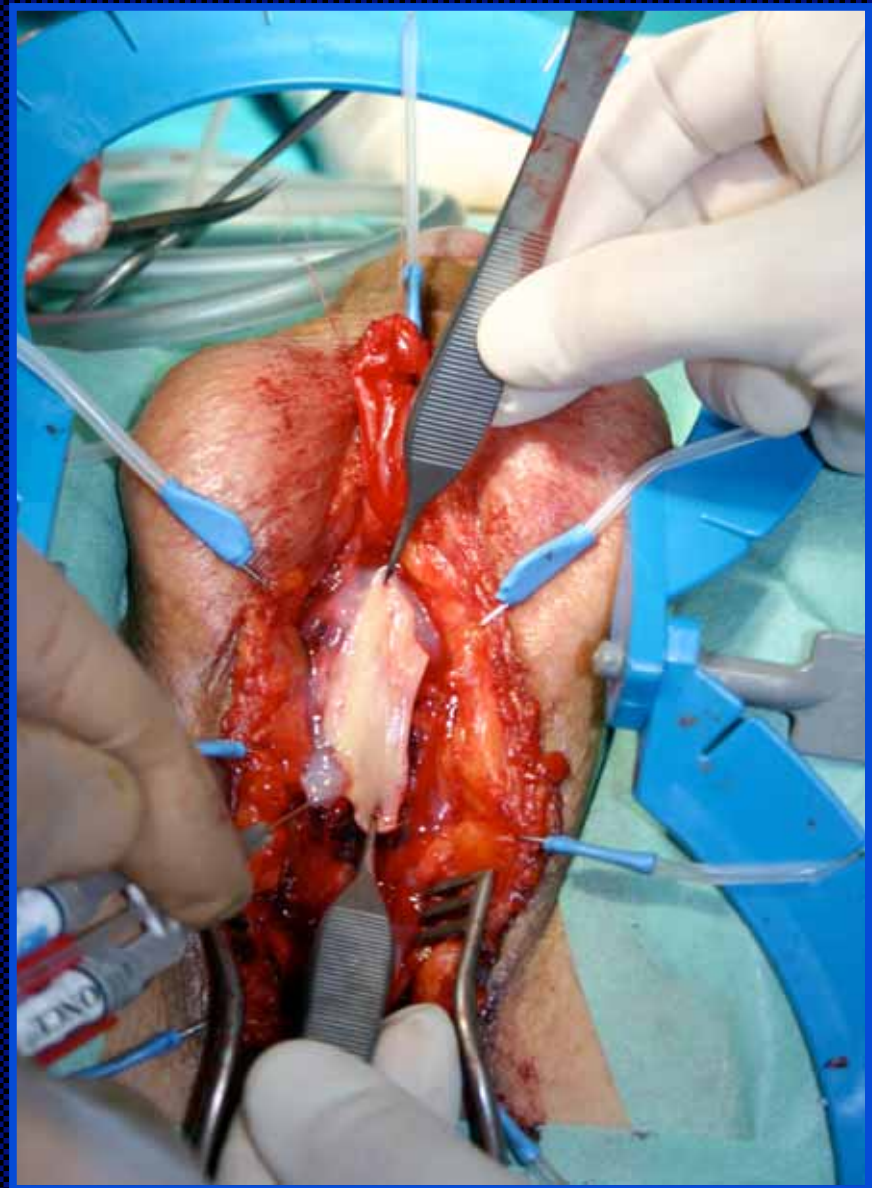
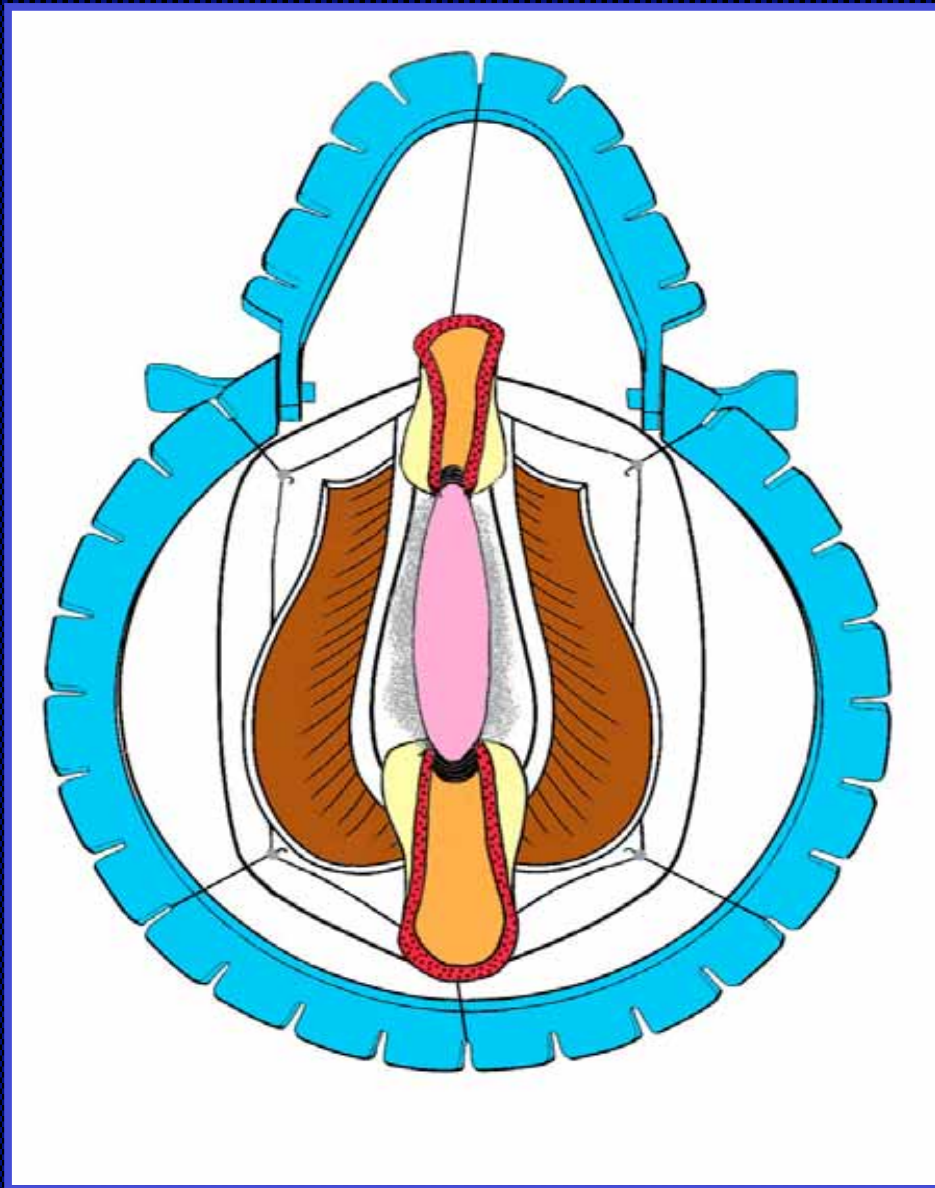


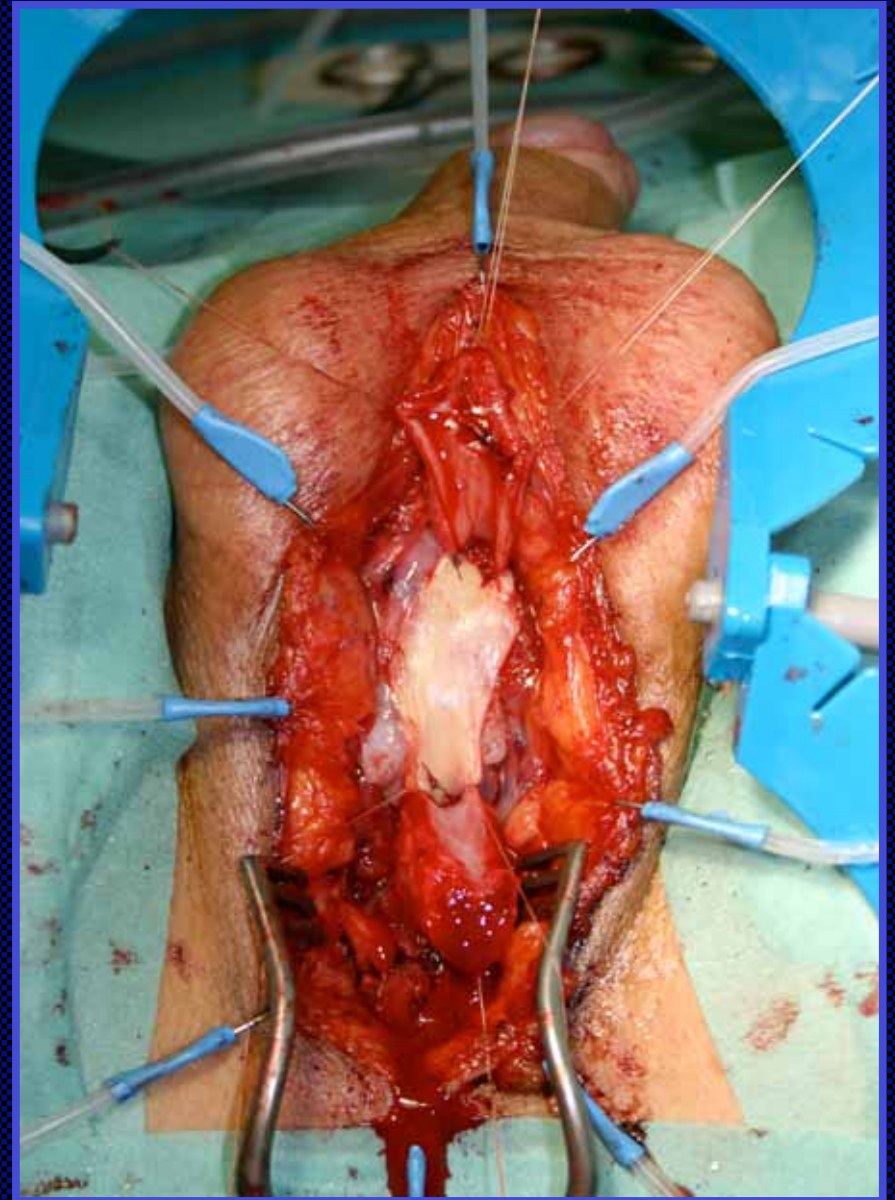
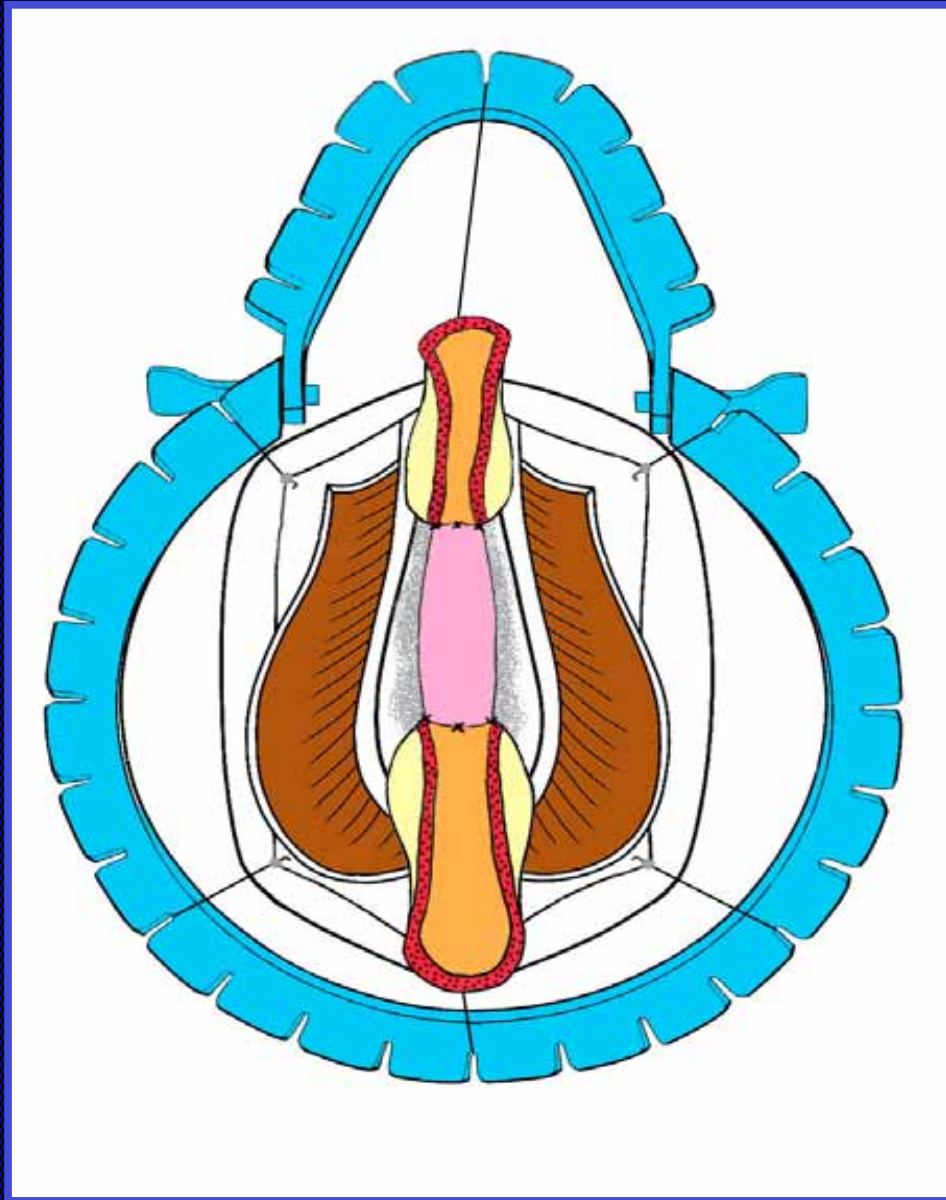


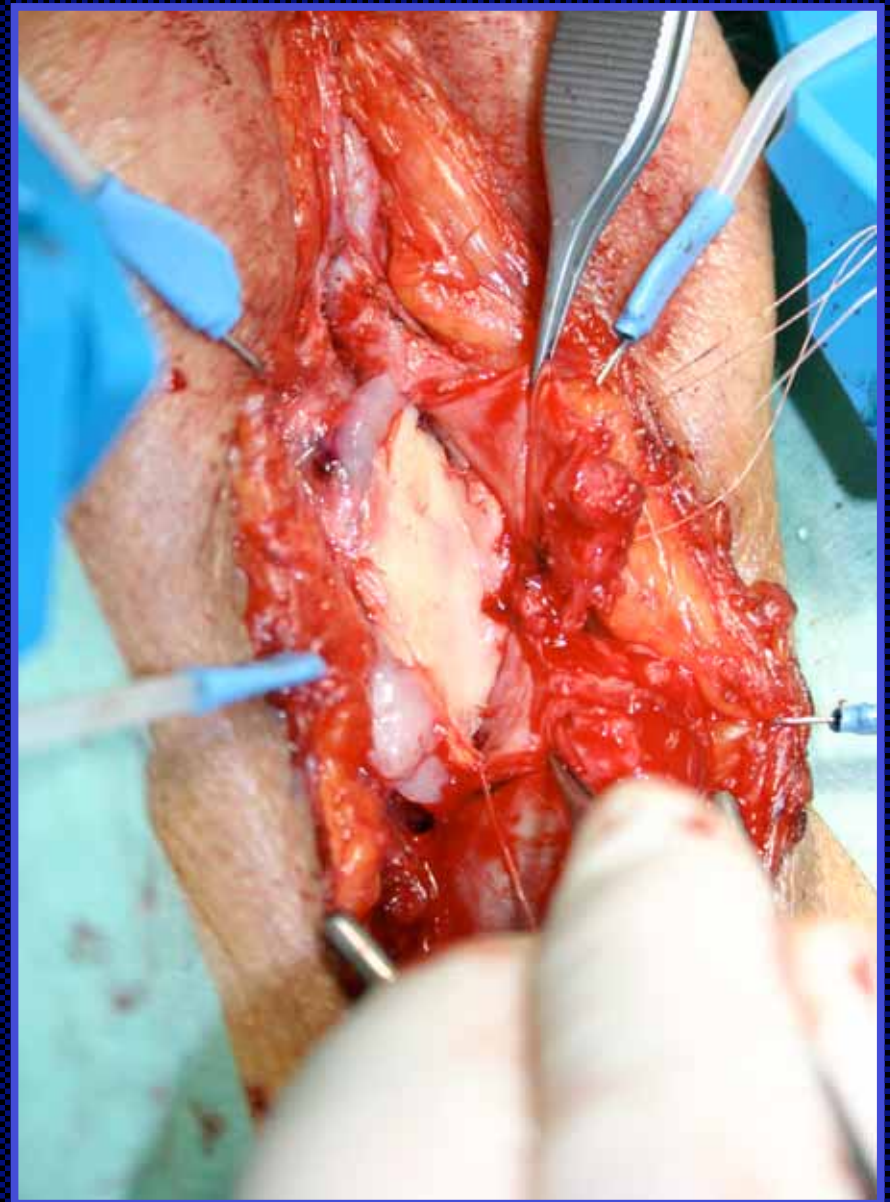
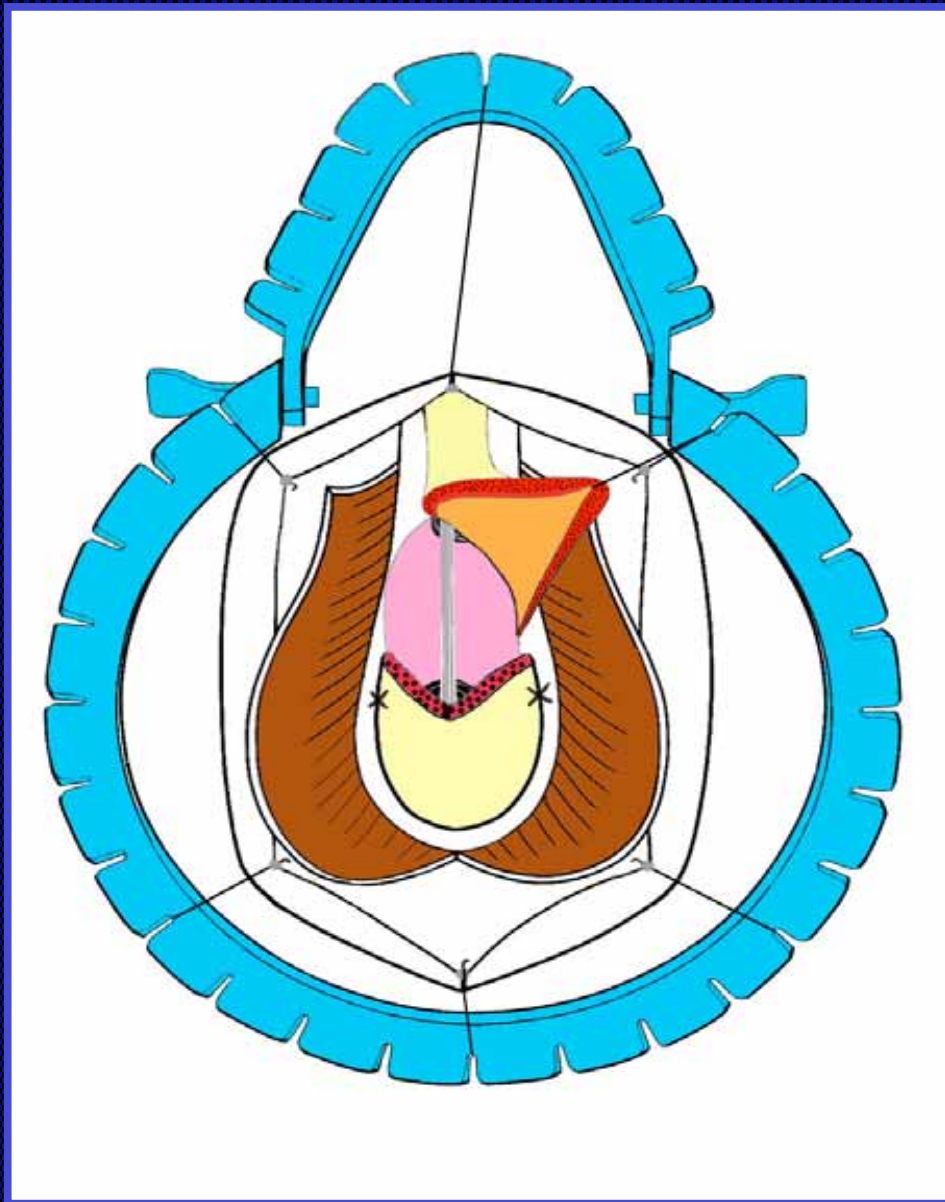


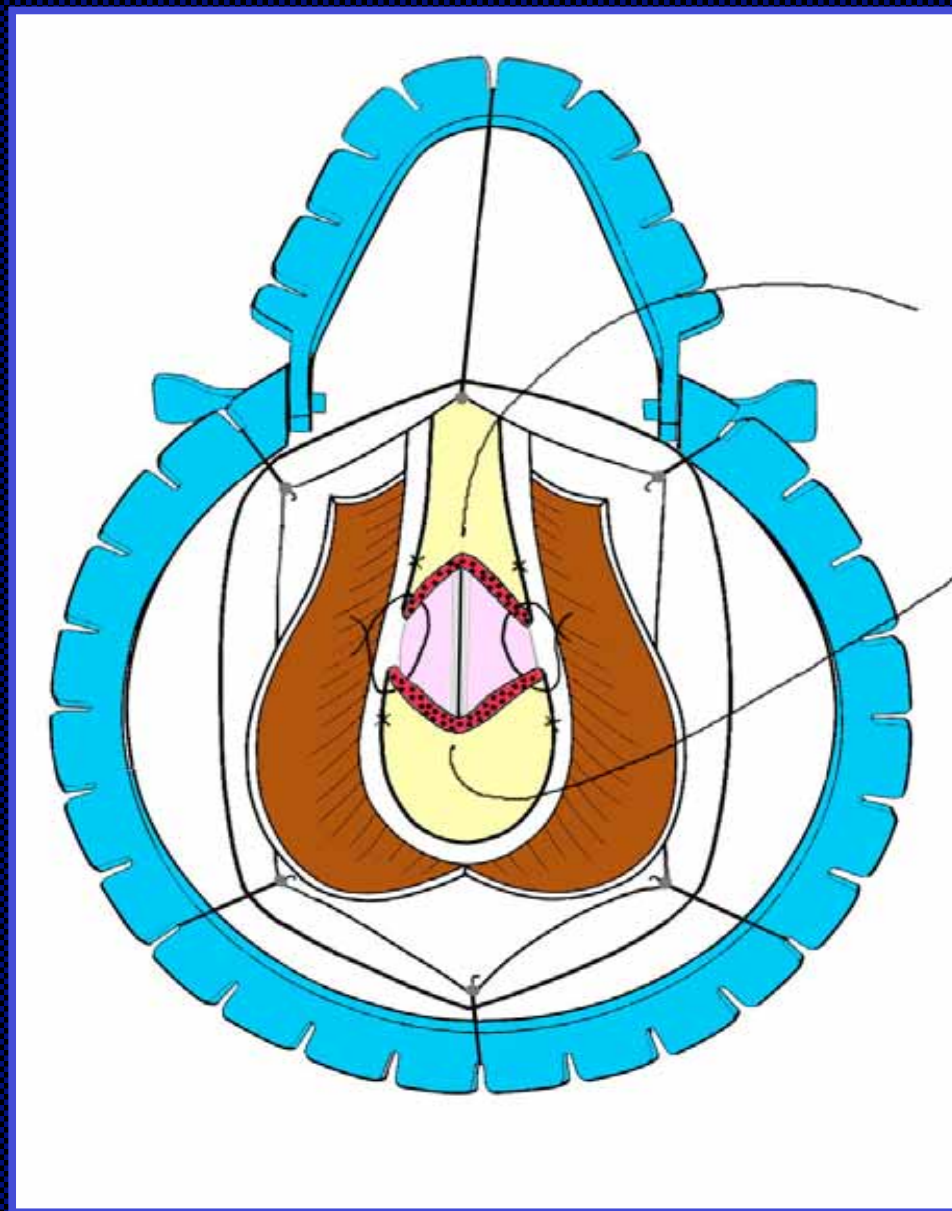


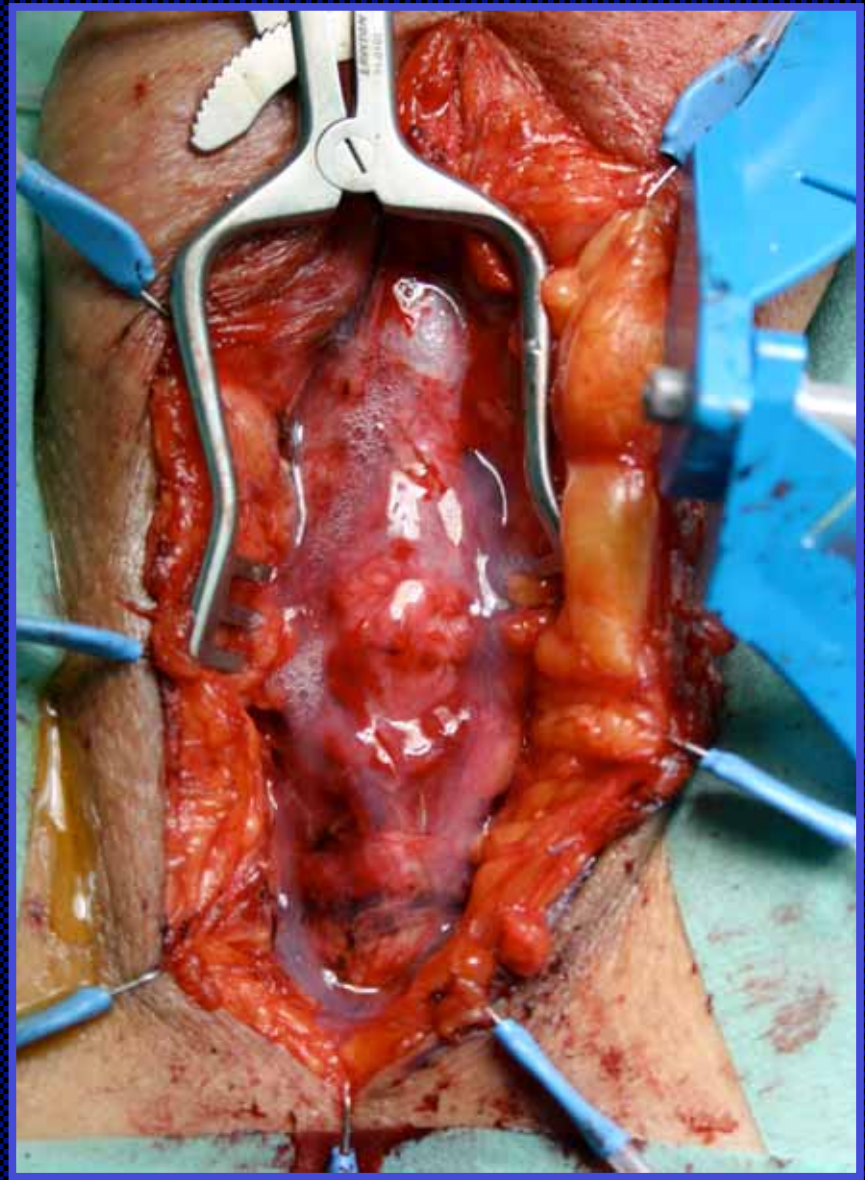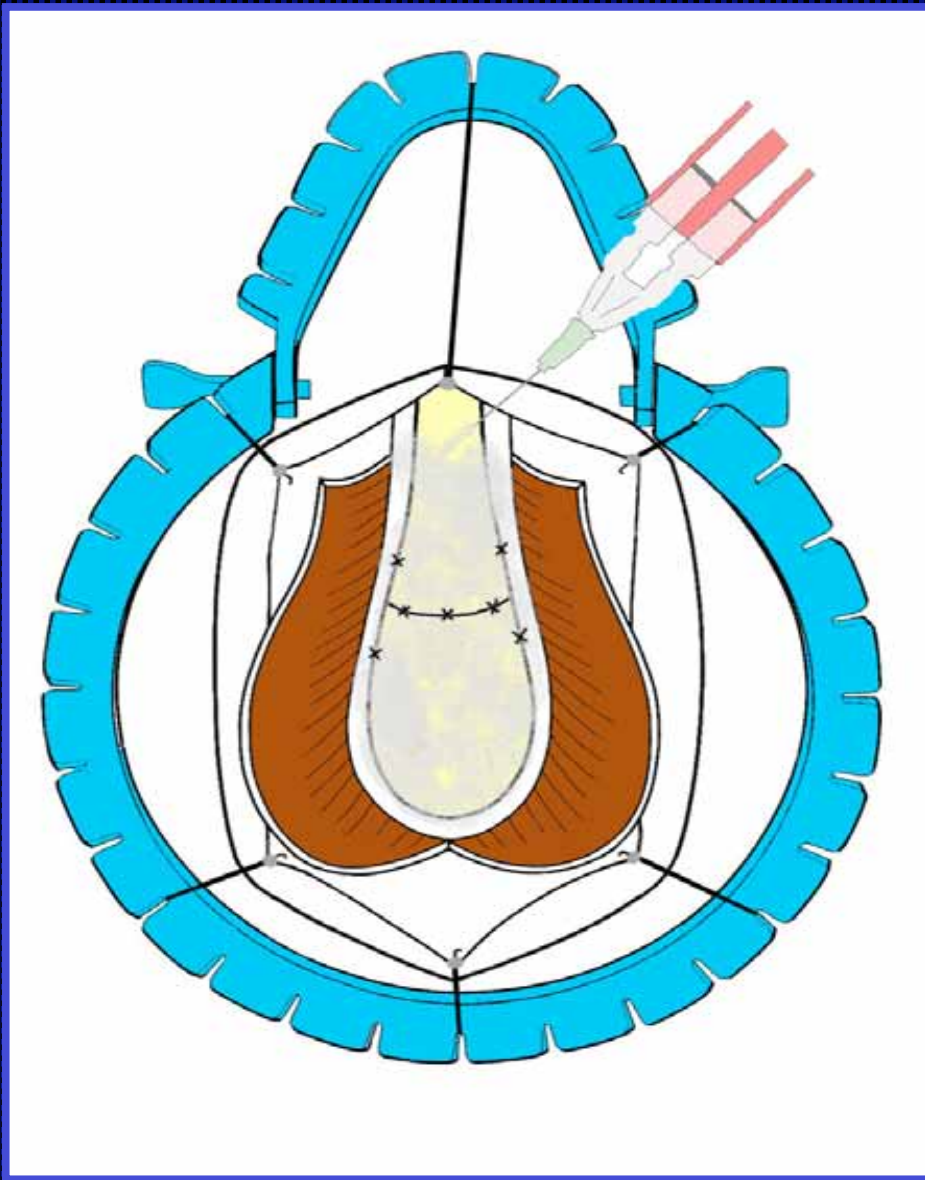




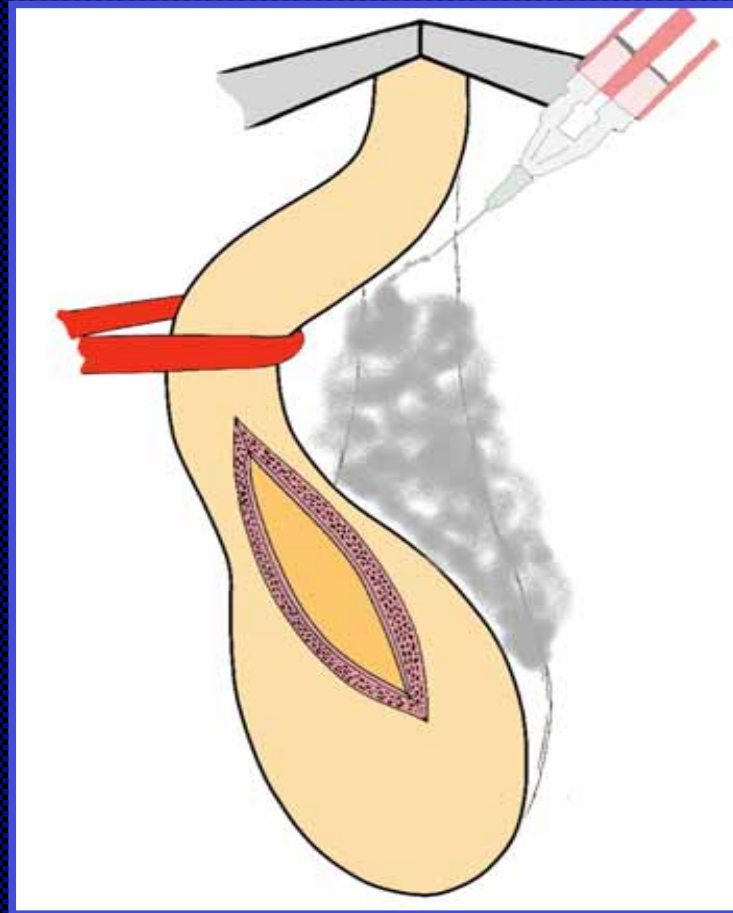


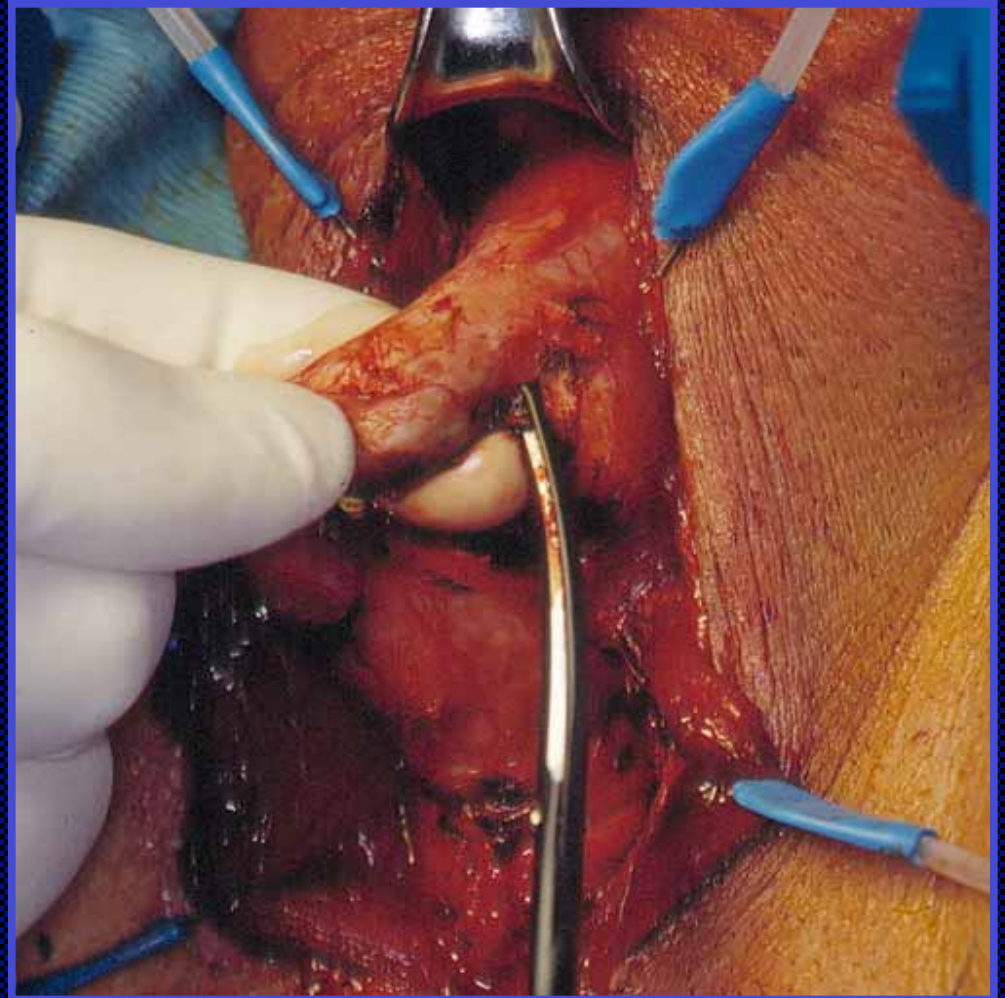
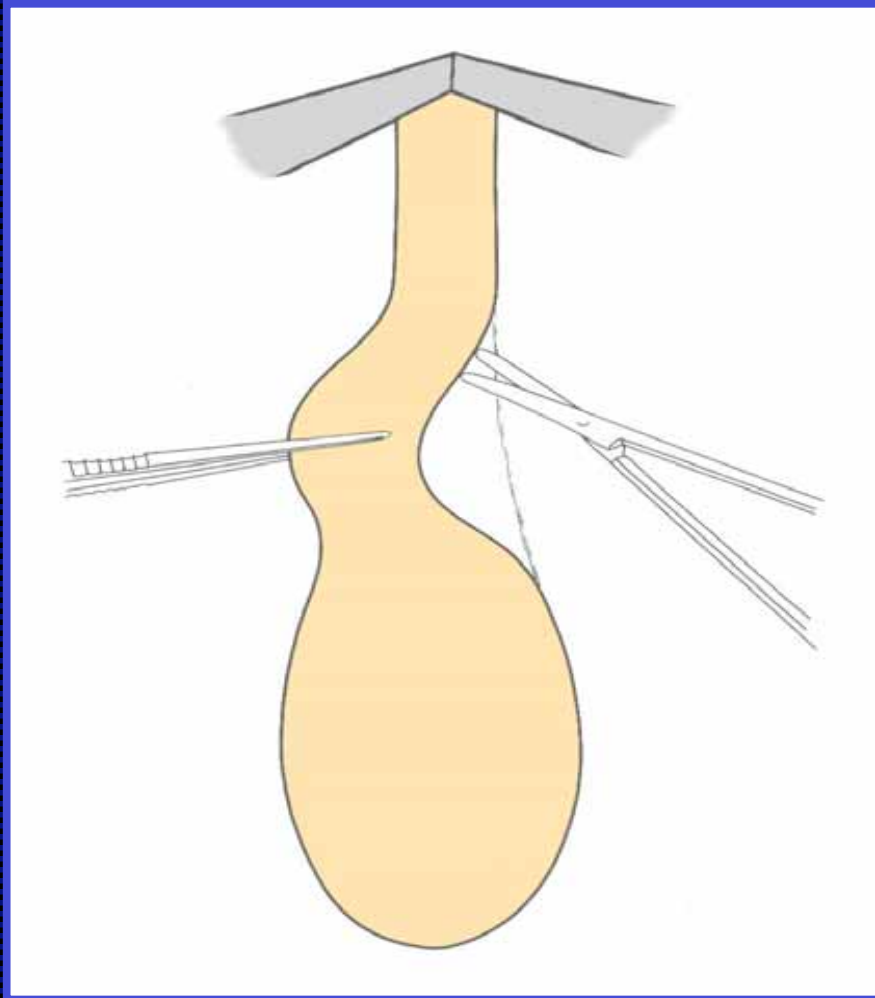


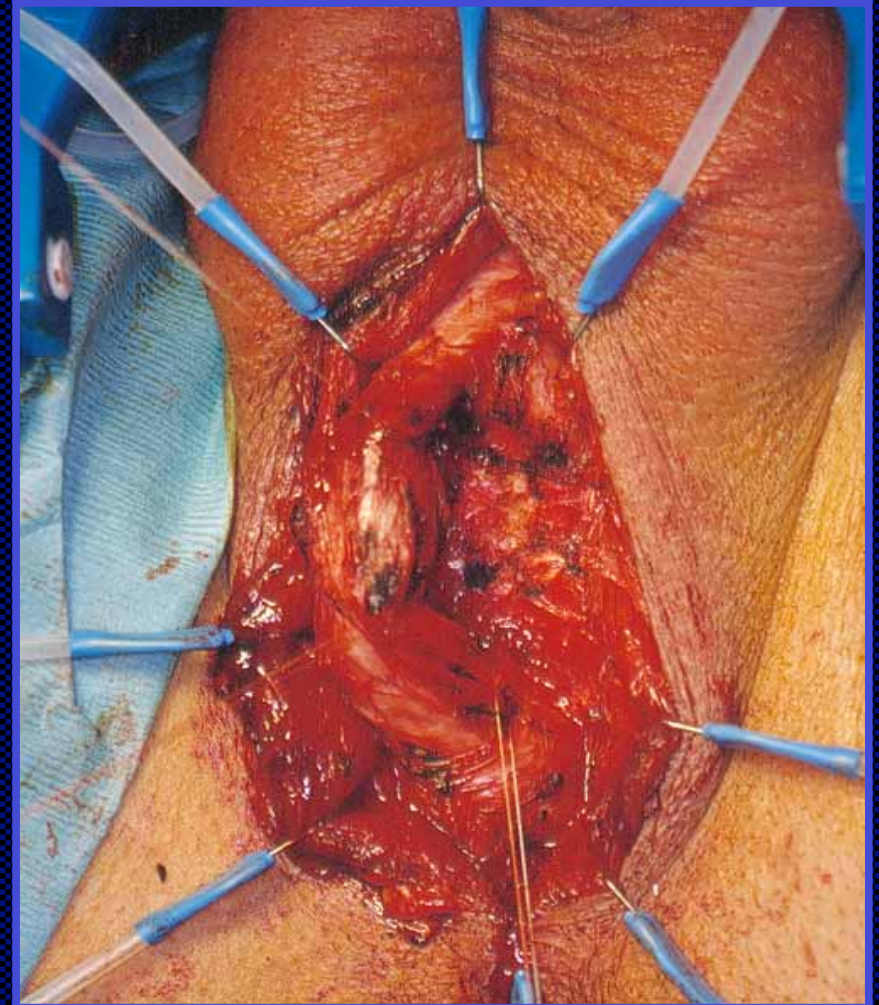
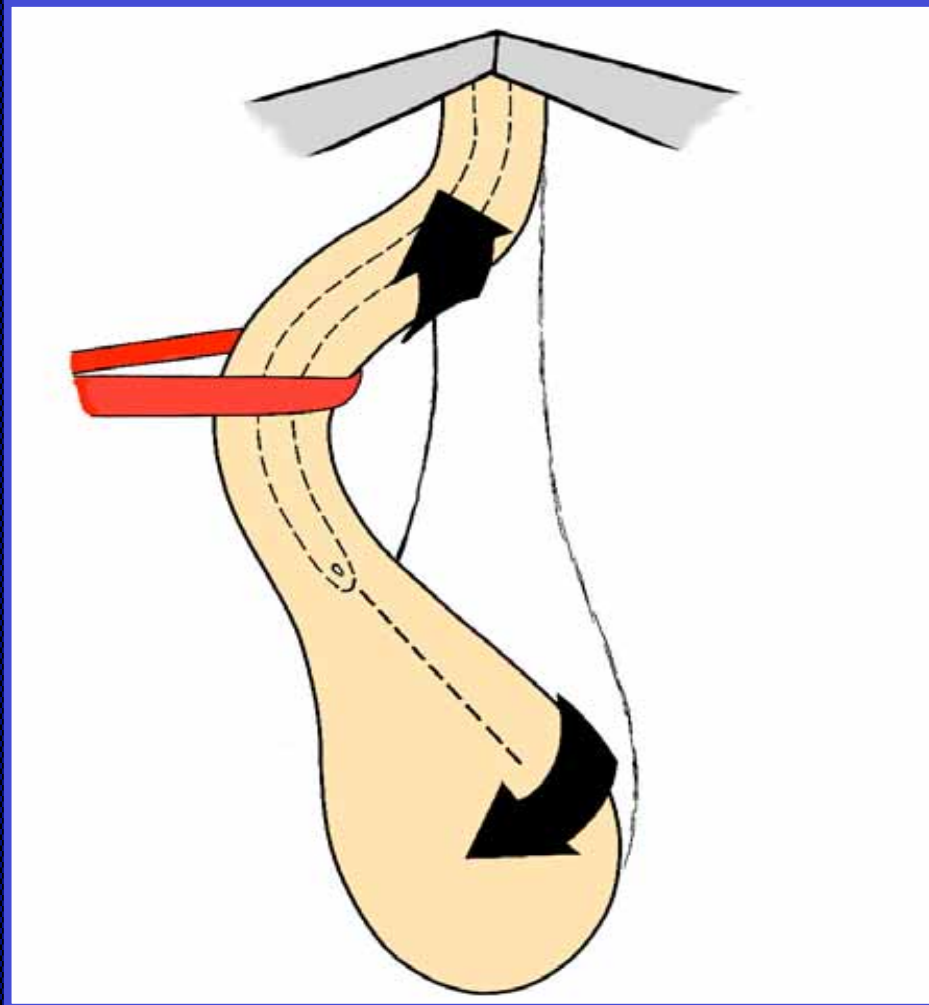


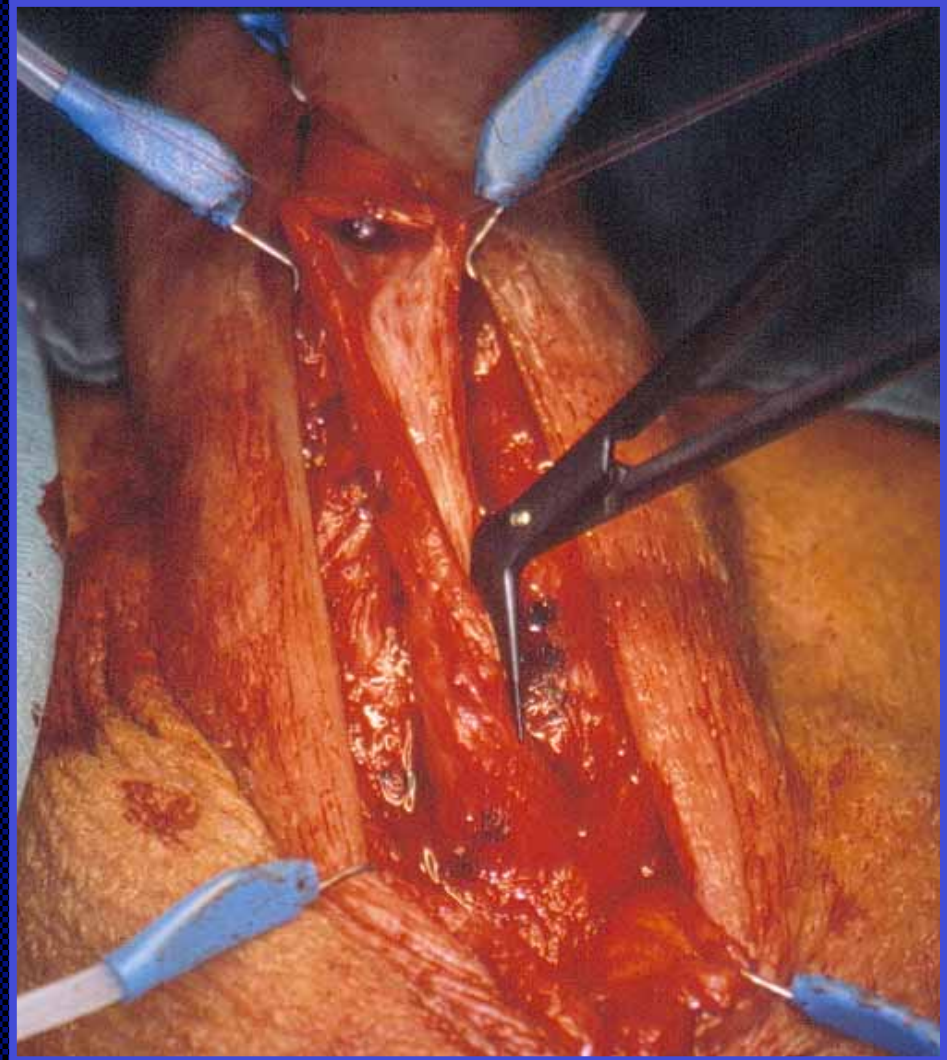
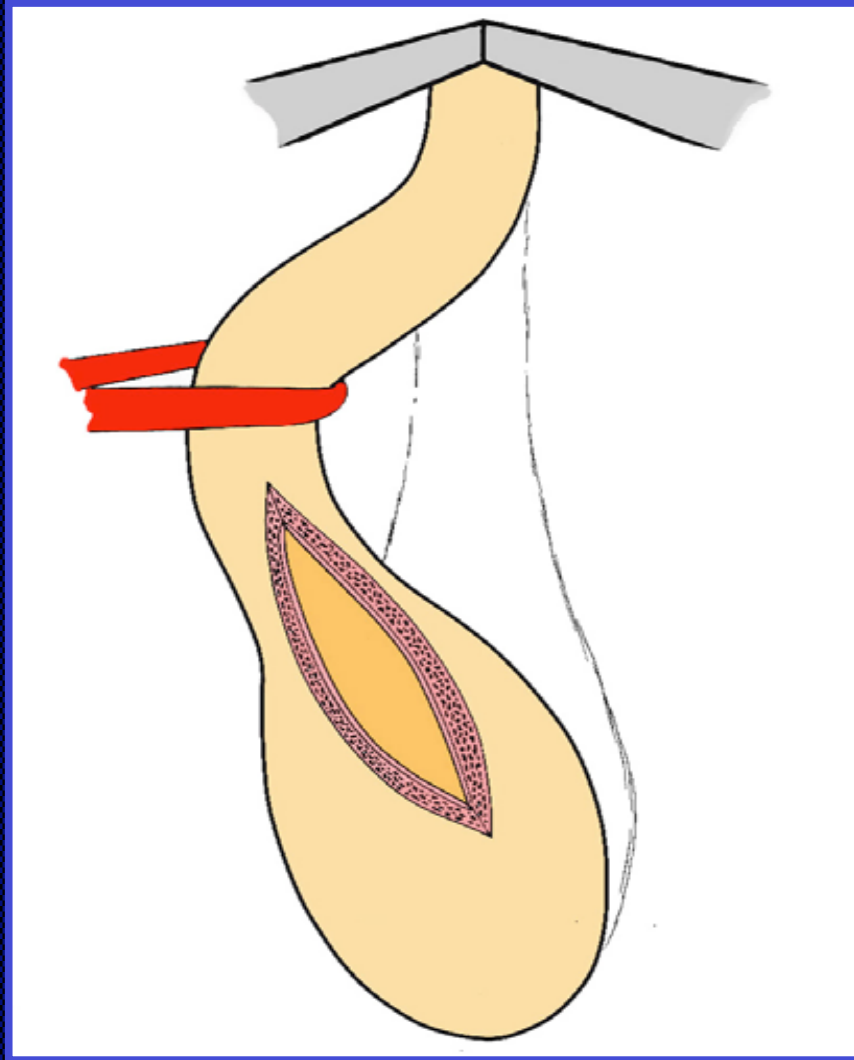


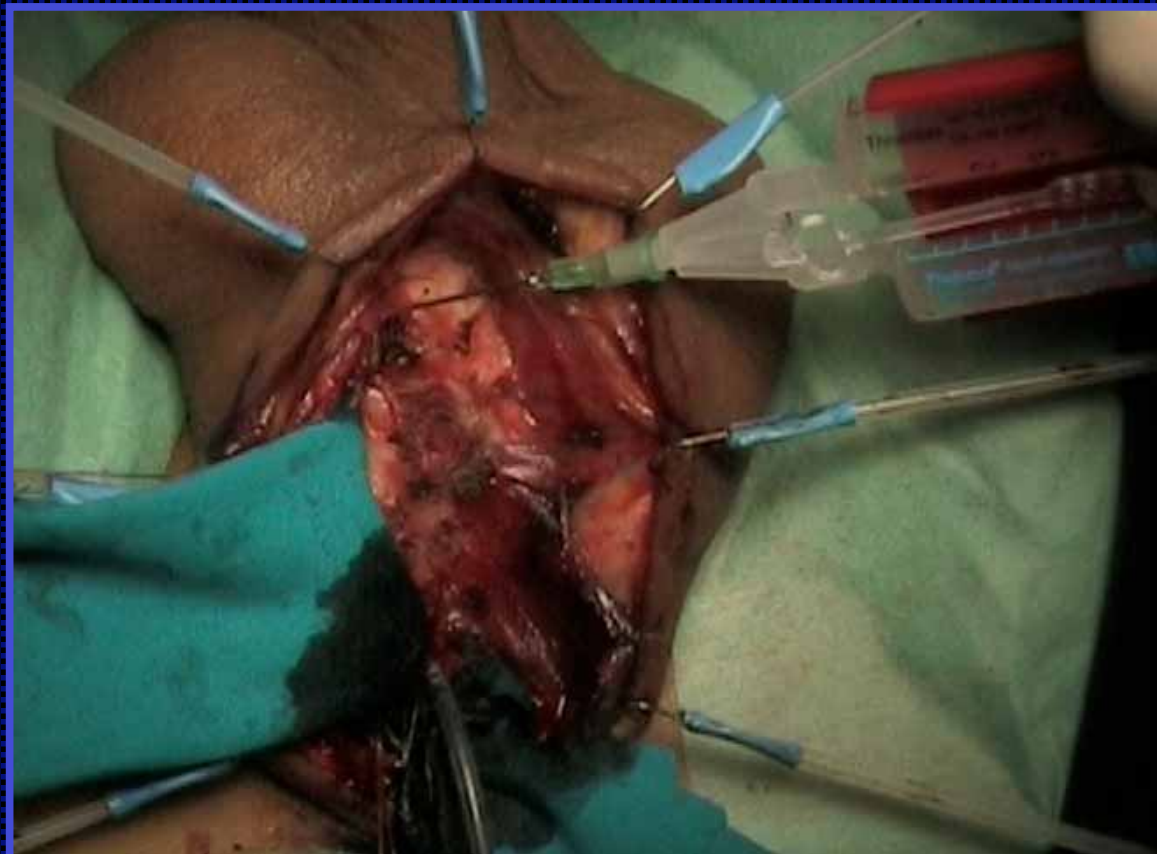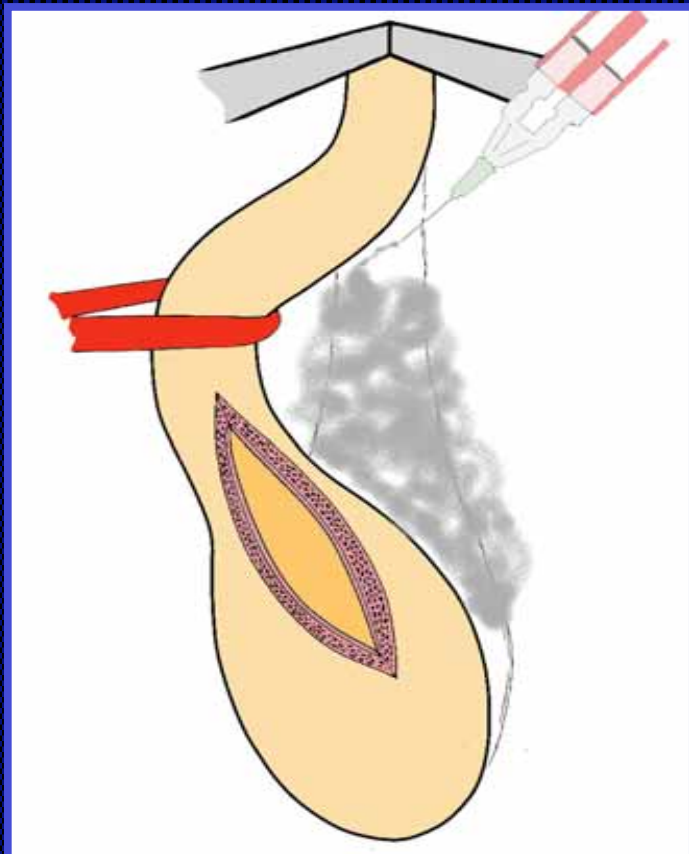
Dorsal onlay buccal mucosal graft urethroplasty with fibrin glue

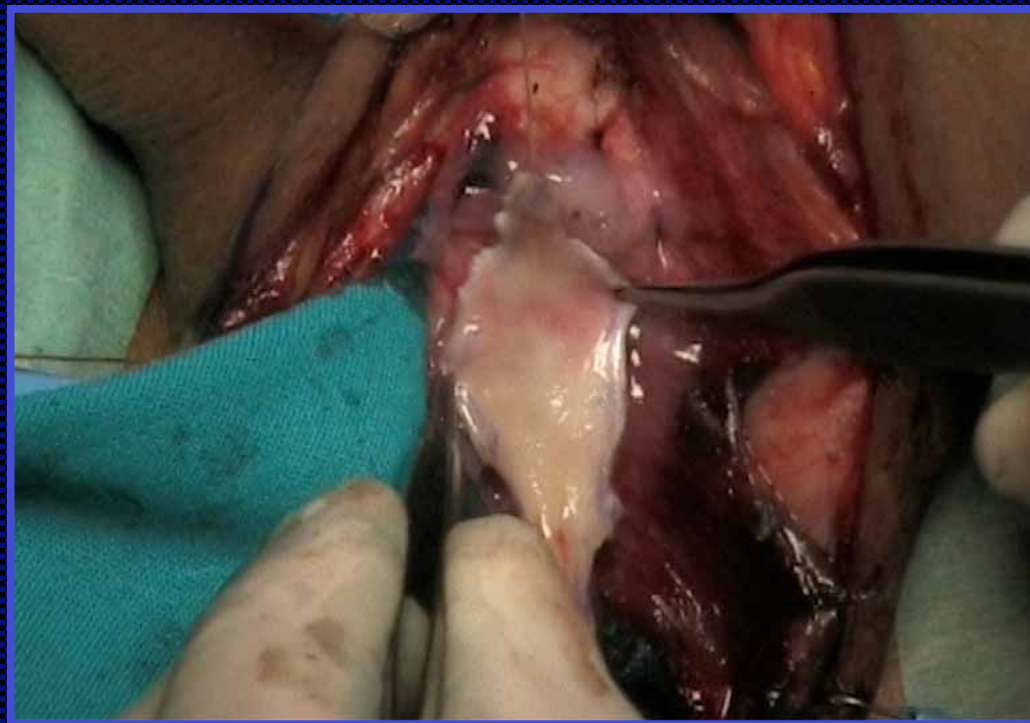
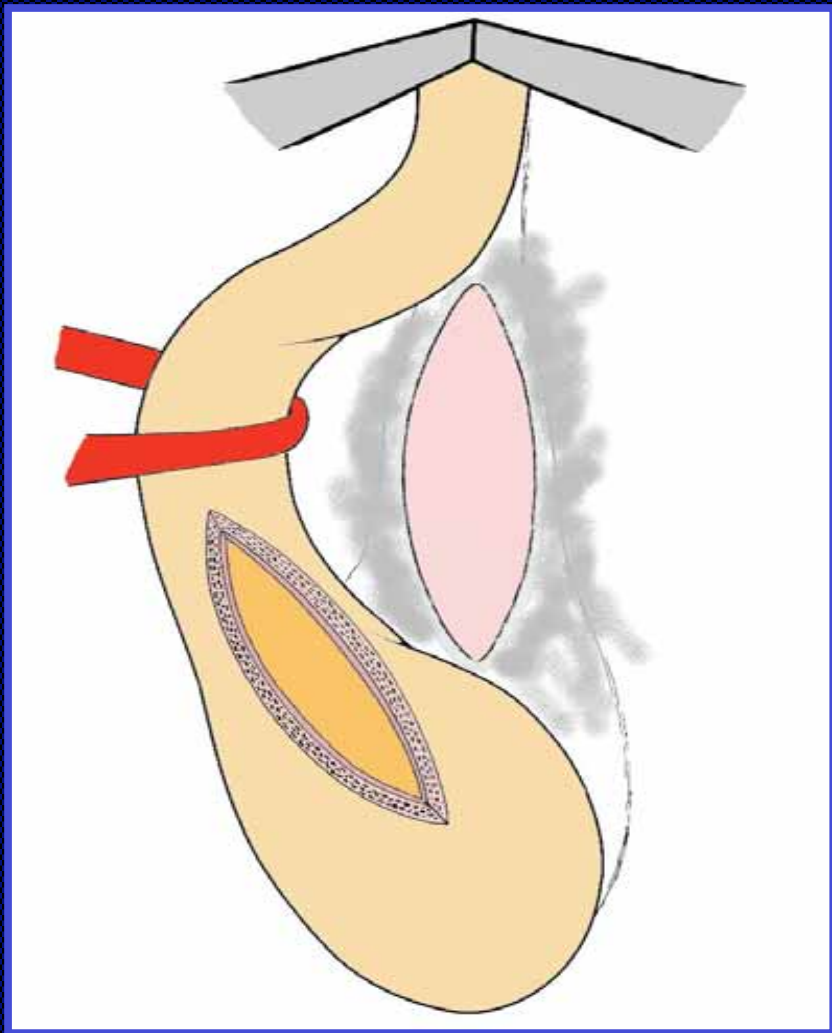


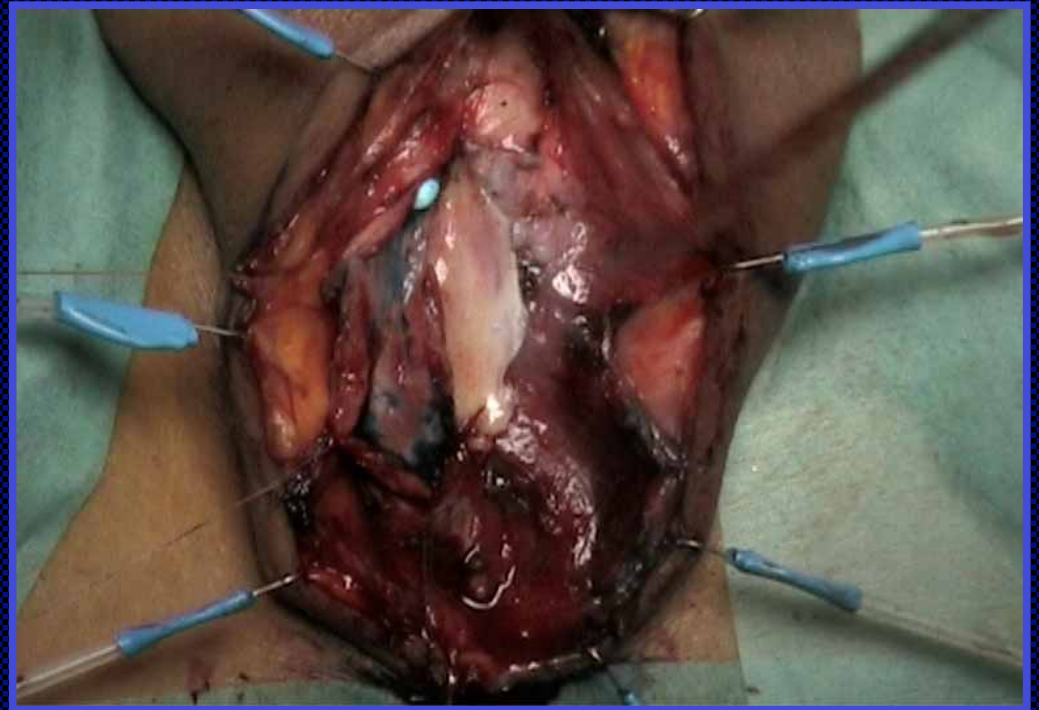
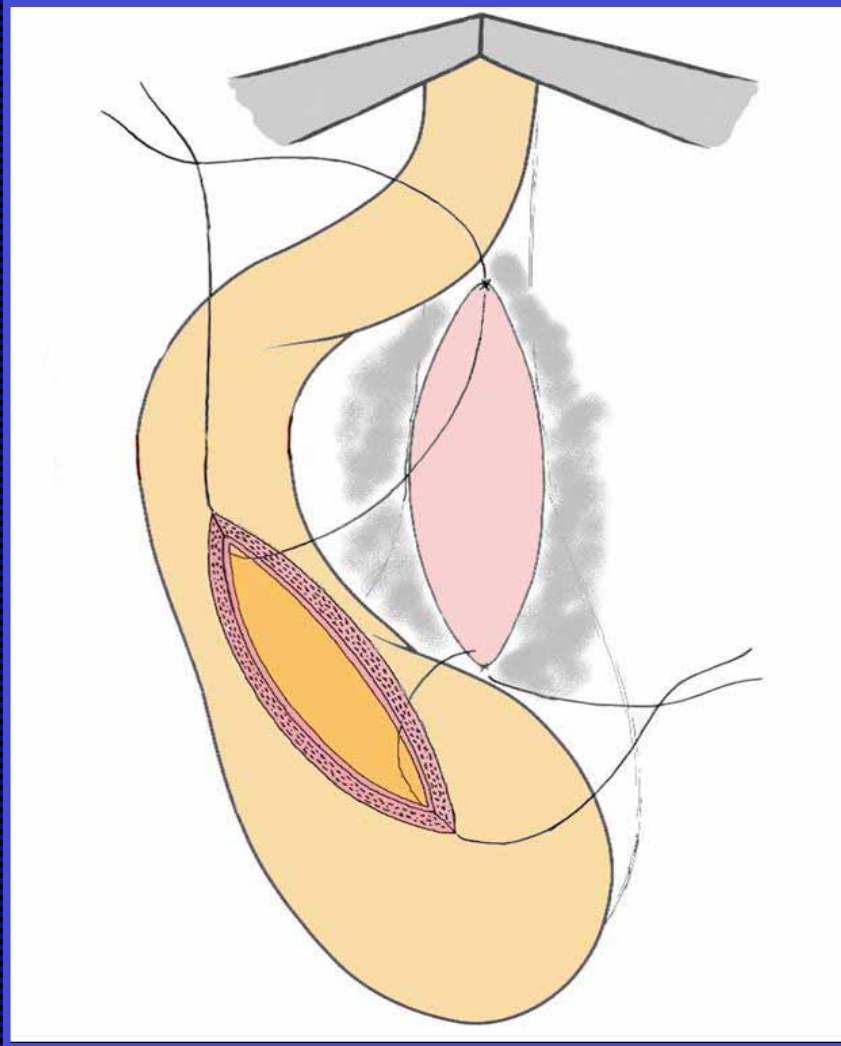


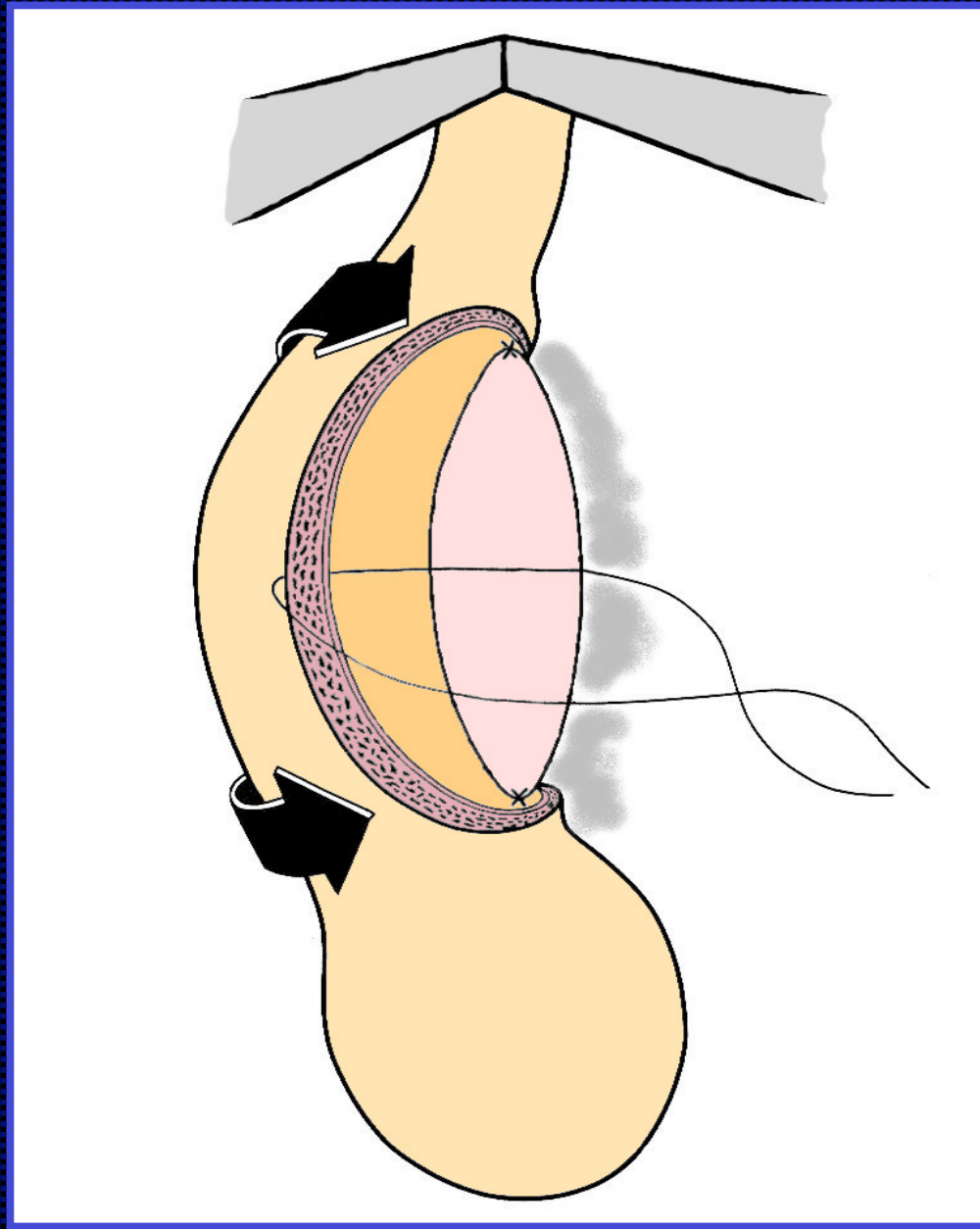


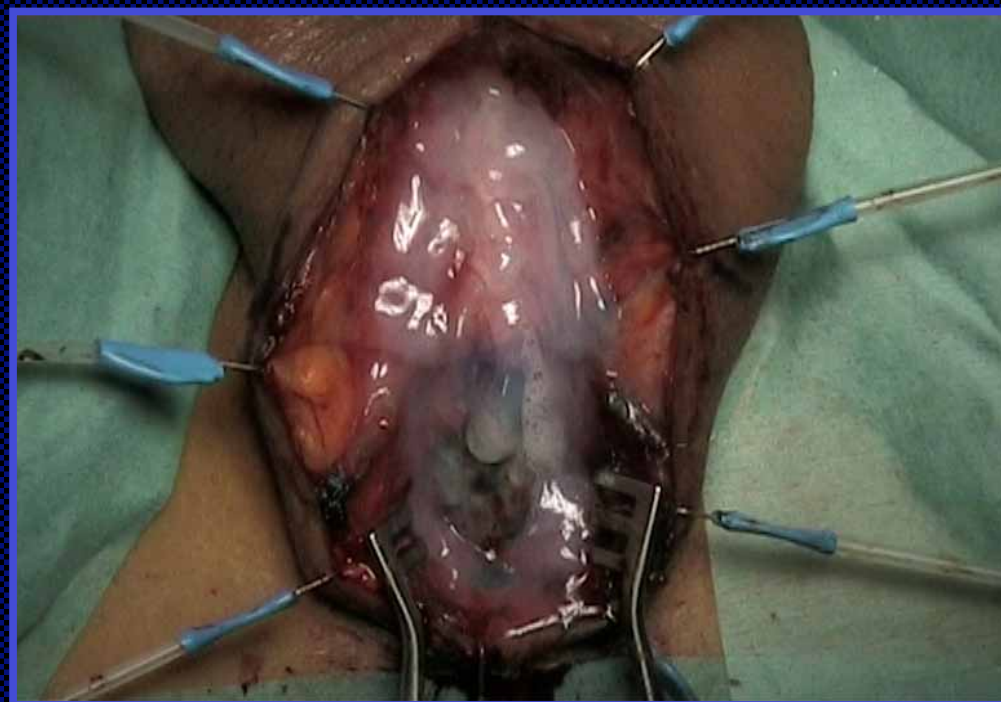
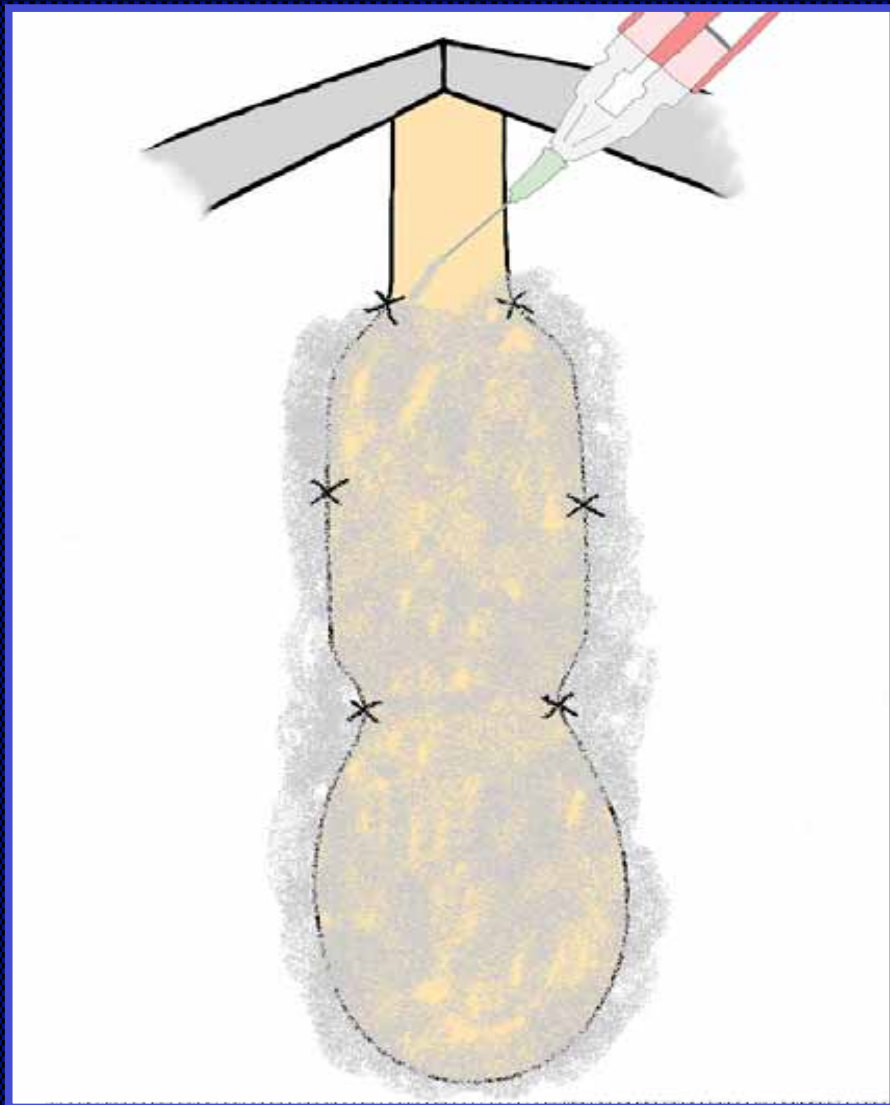




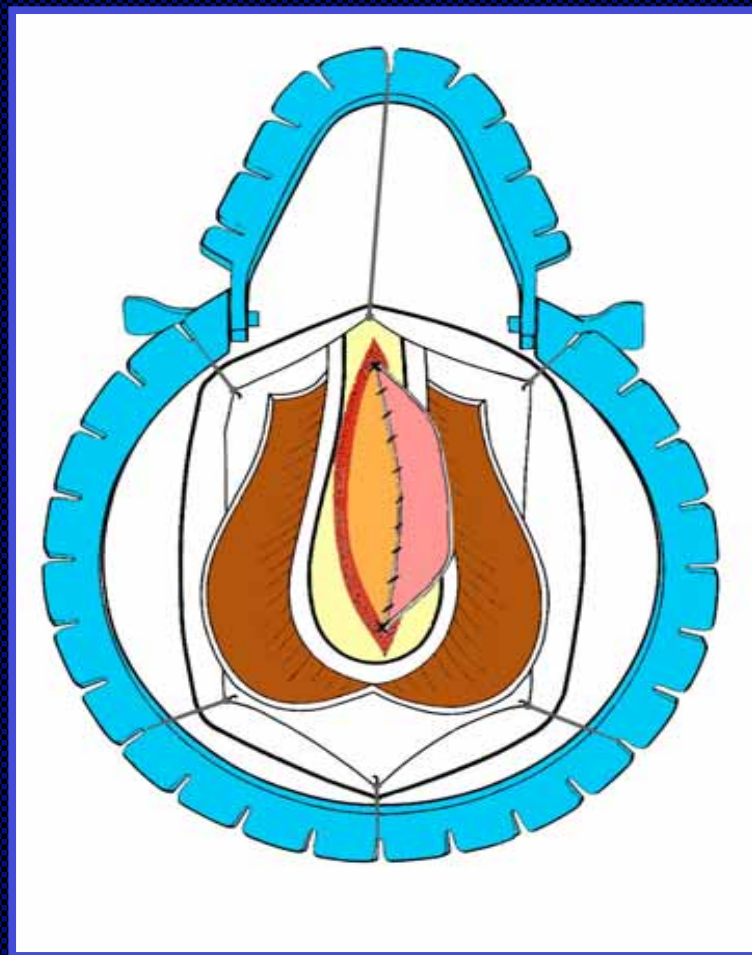


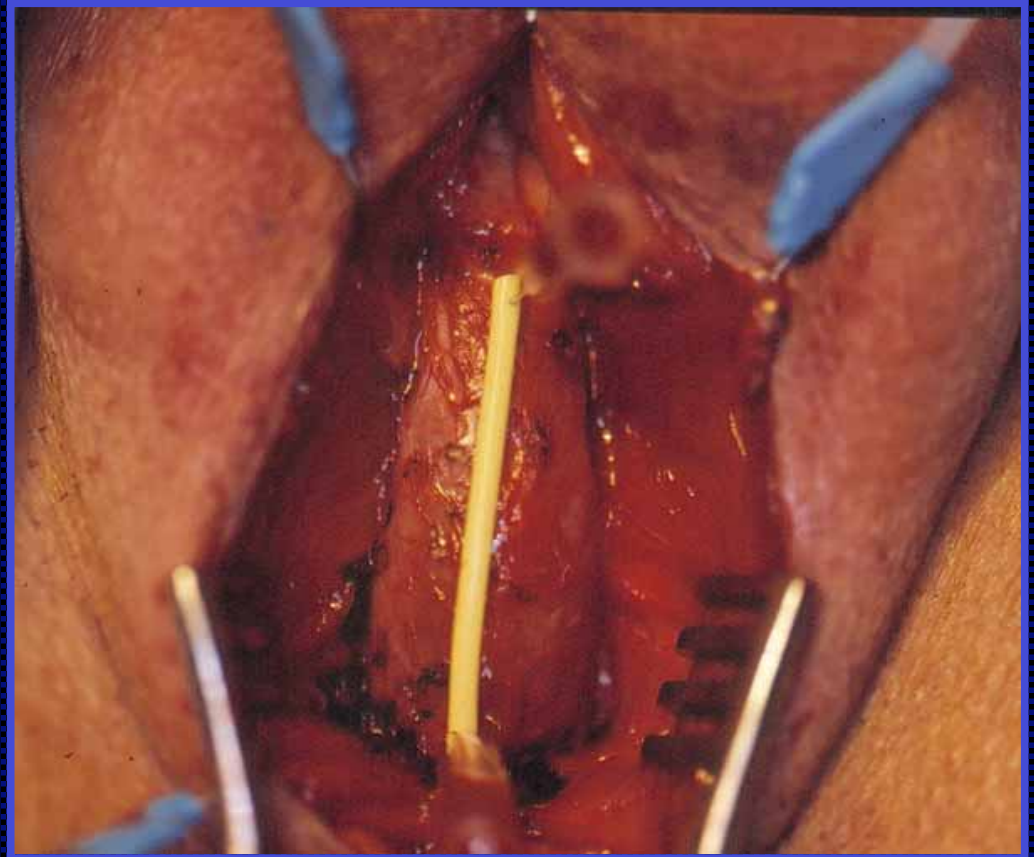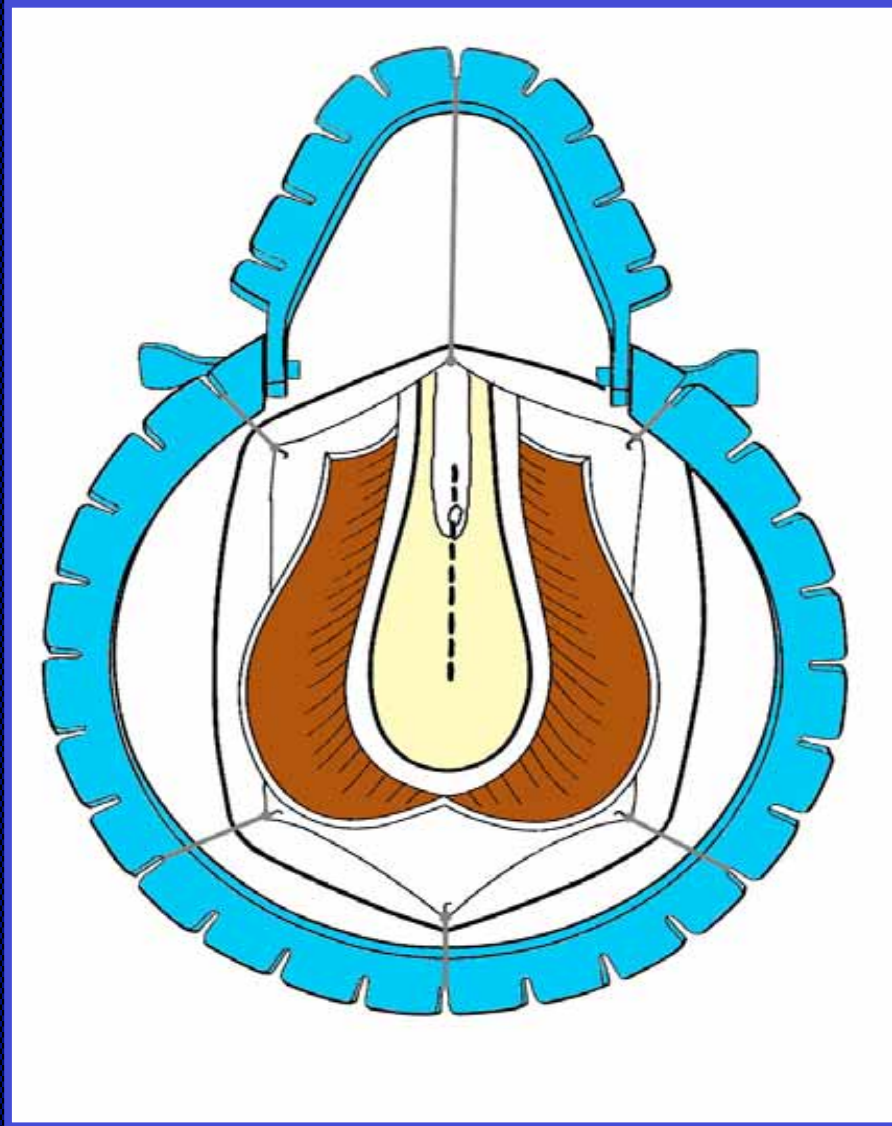


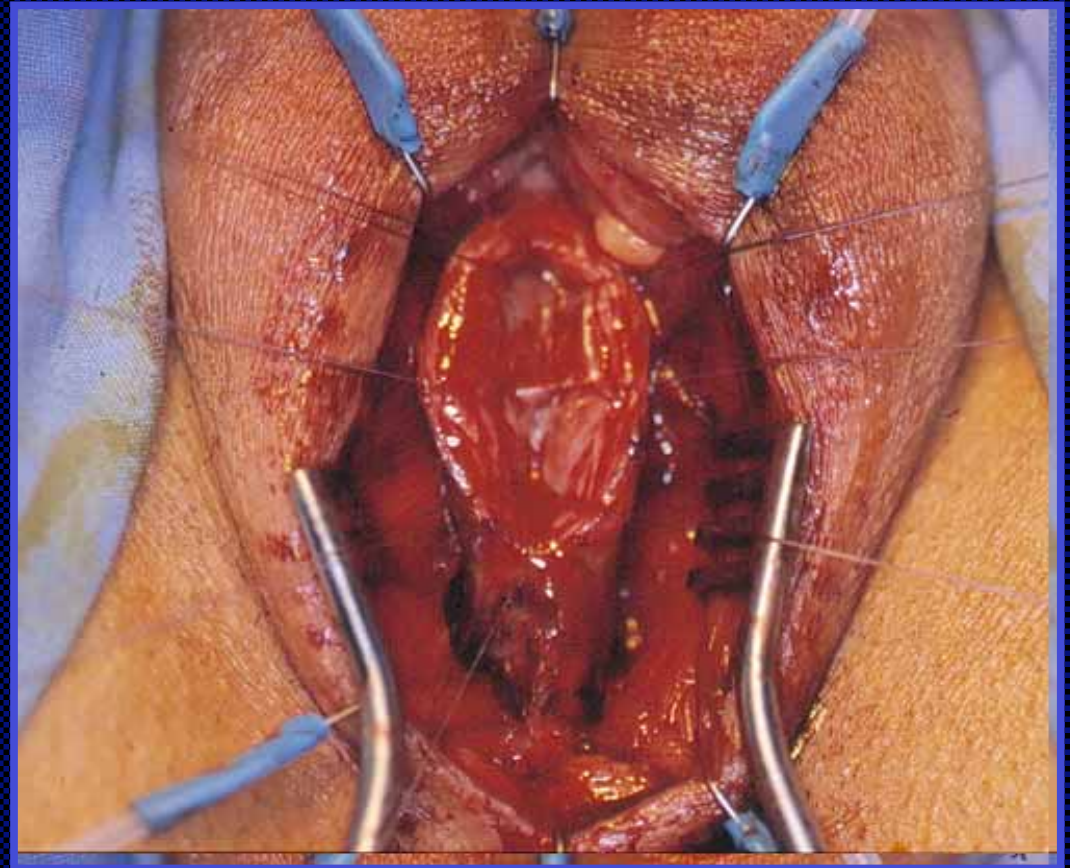
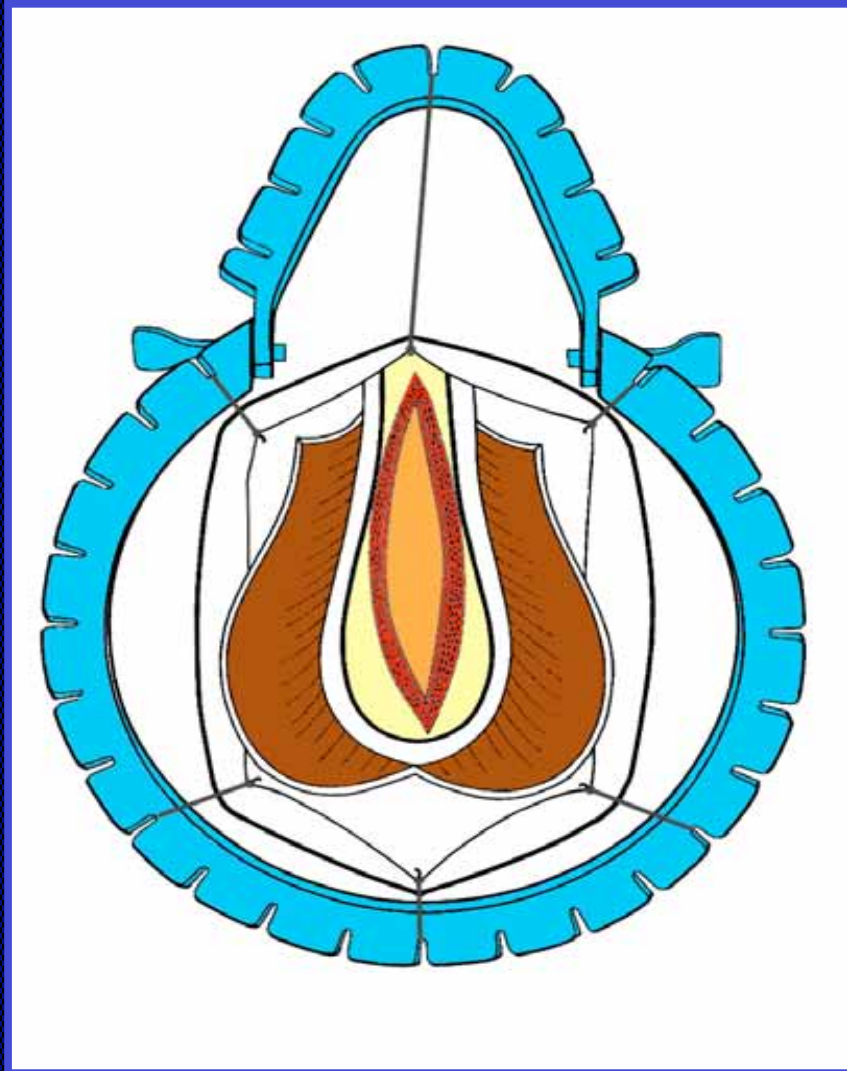


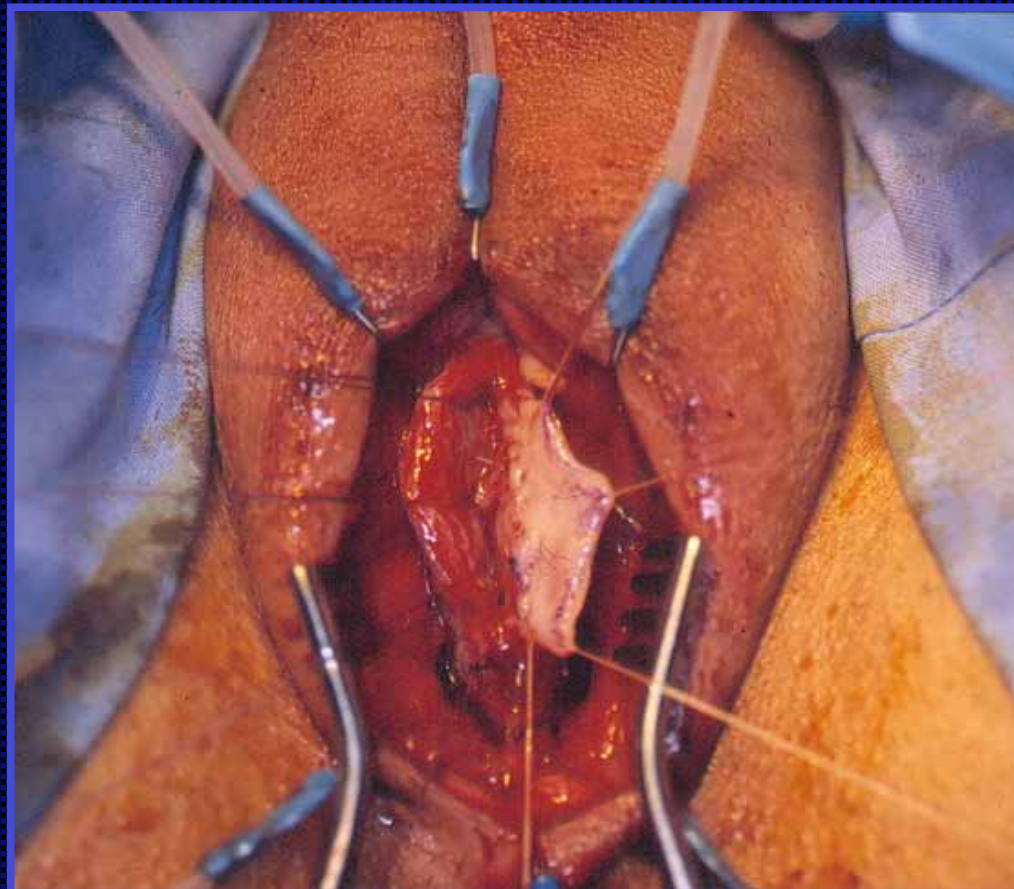
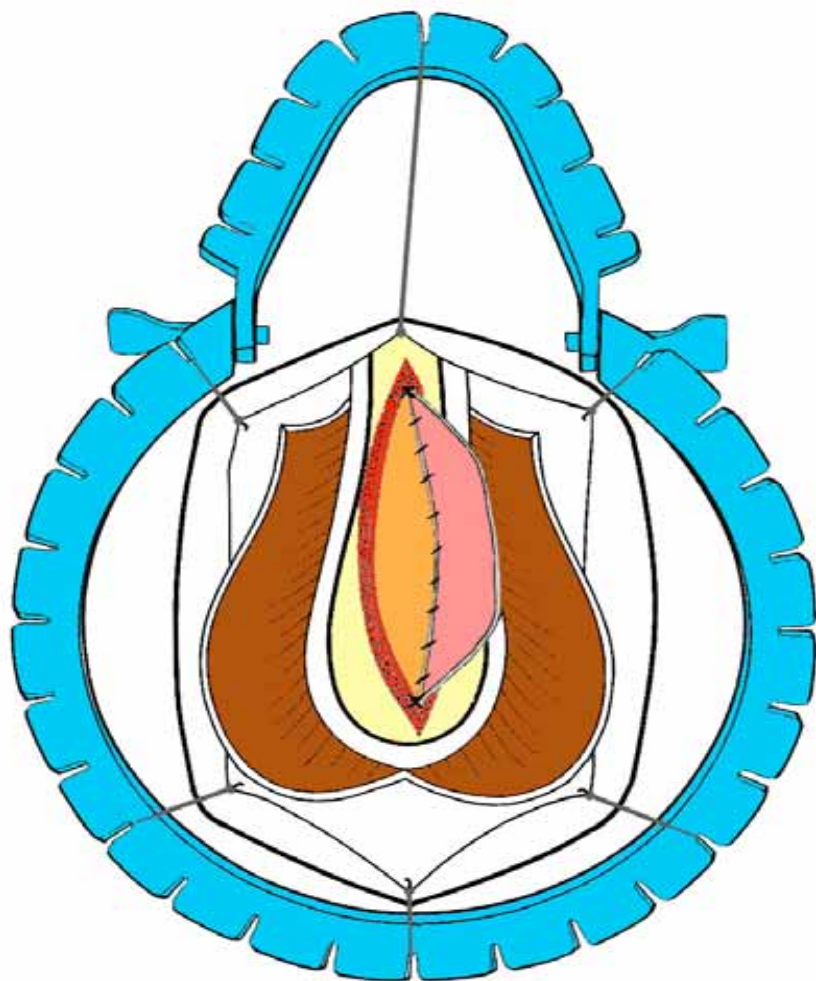


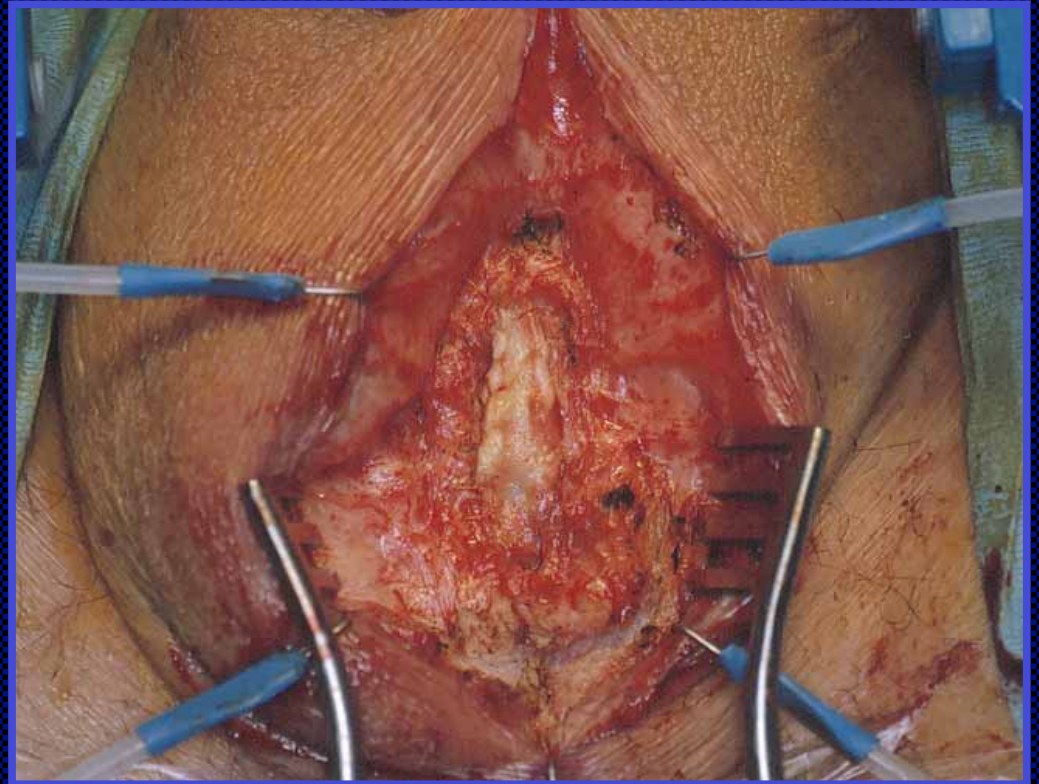
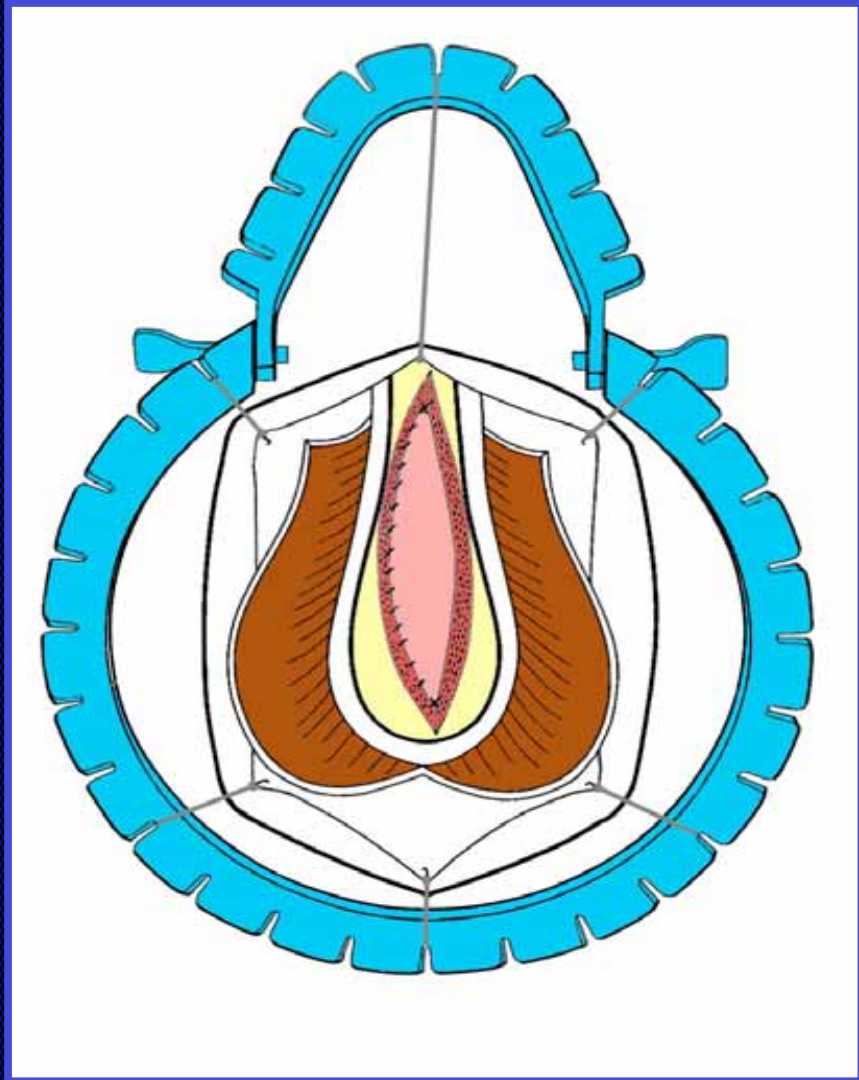
Ventral onlay buccal mucosal graft urethroplasty

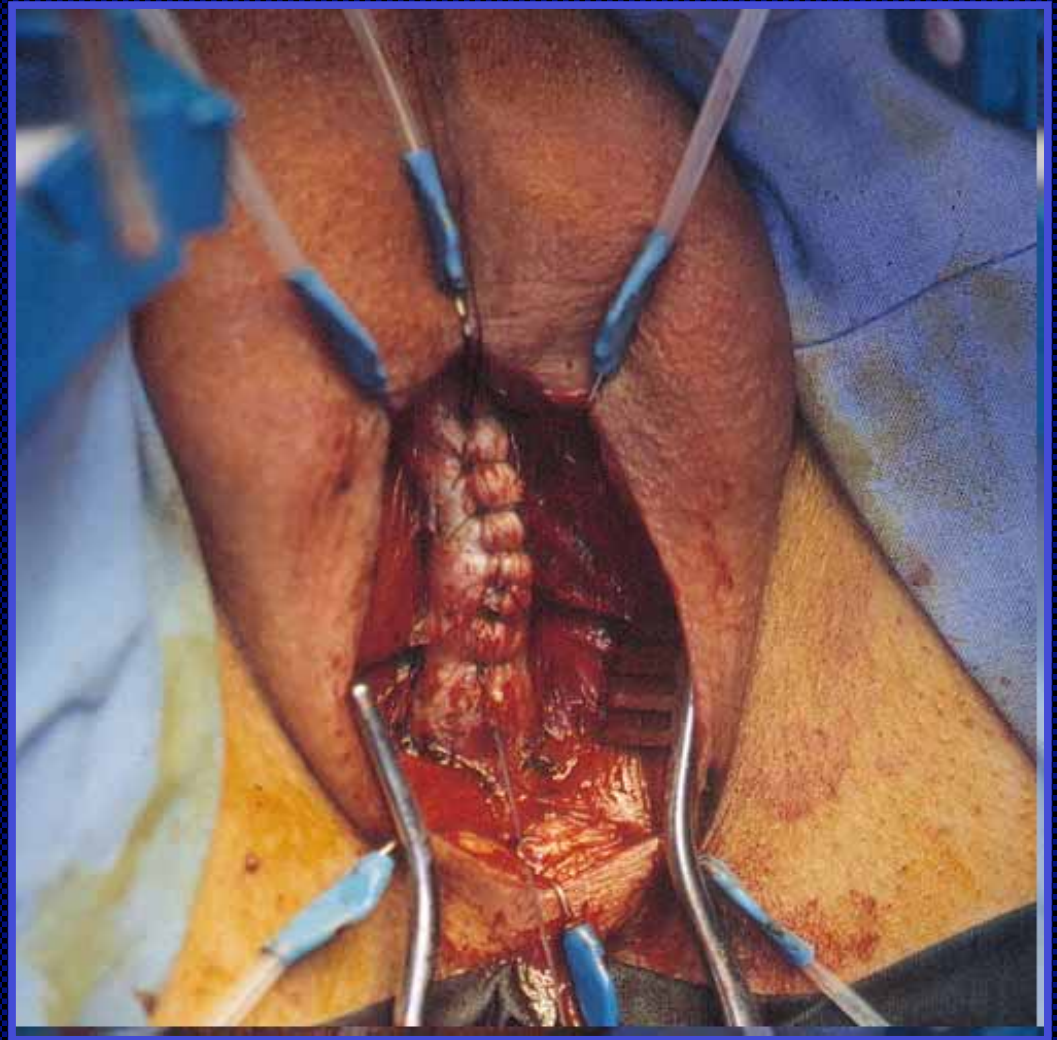
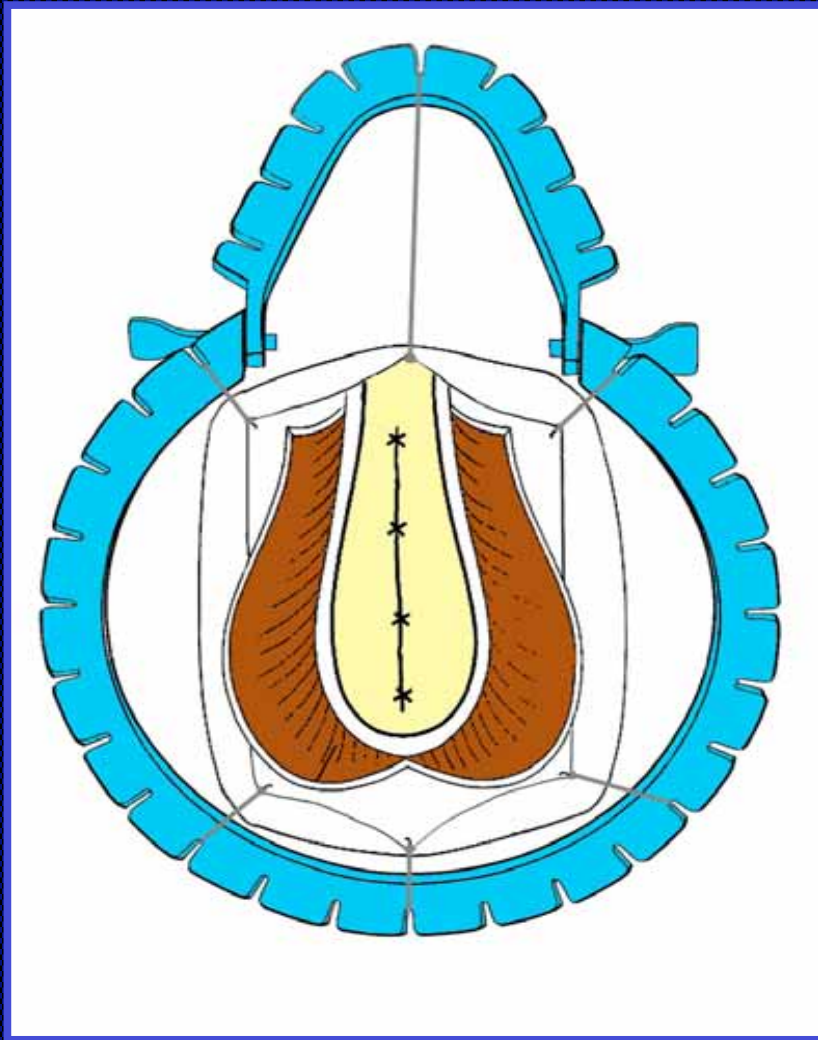












**I showed you the surgical techniques currently suggested for
the repair of penile and bulbar urethral strictures using
buccal mucosal grafts**

**What approach to take will be decided by you, your
experience, your surgical background and your patients'
expectations**

There is nothing more I can tell you !



Thank you



Madonna del Parto - Piero della Francesca

Monterchi - Arezzo



Center for Reconstructive Urethral Surgery

