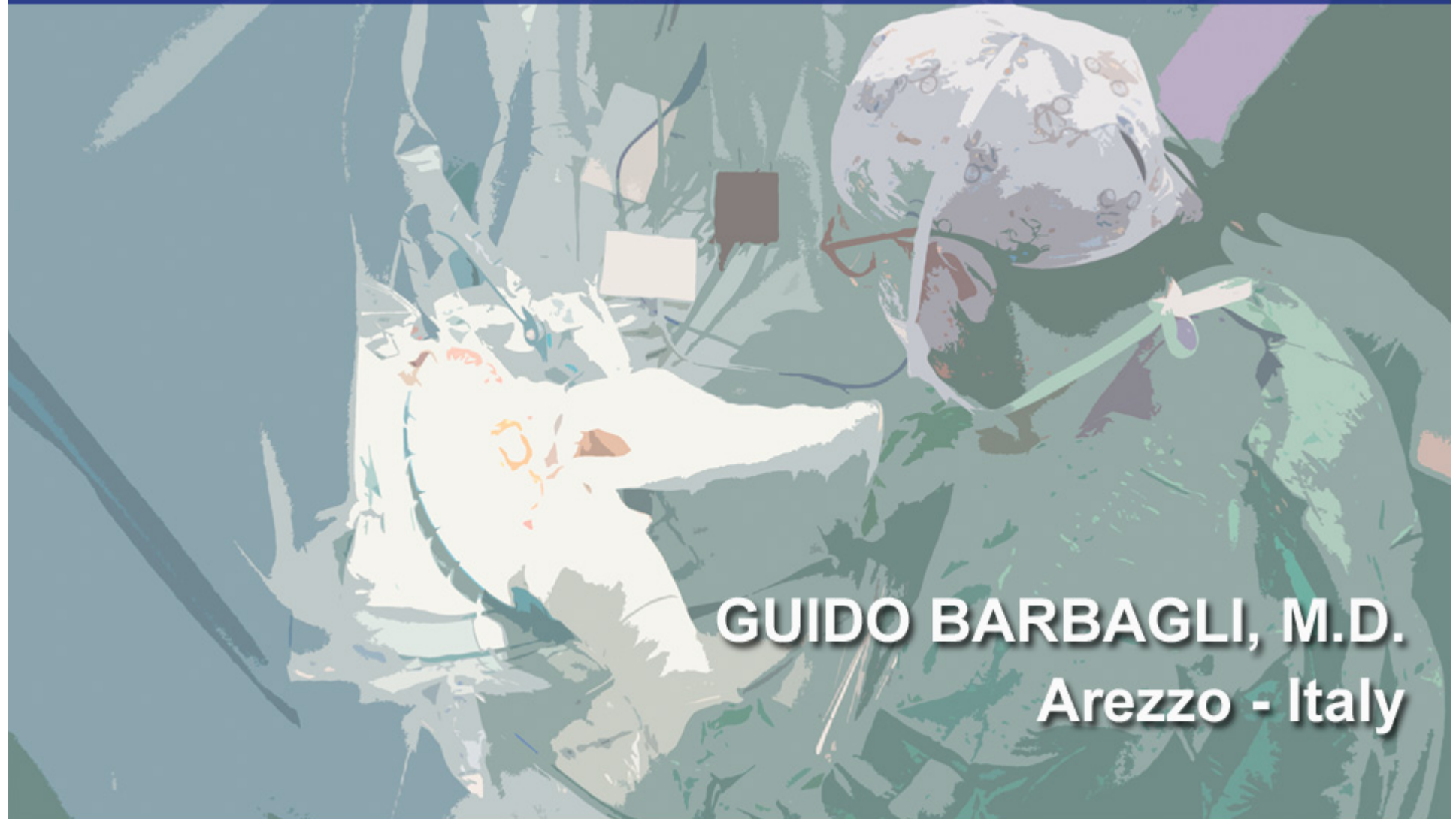

CENTER FOR RECONSTRUCTIVE URETHRAL SURGERY



GUIDO BARBAGLI, M.D.
Arezzo - Italy

e-mail: info@urethralcenter.it

Websites: www.uretra.it
www.urethralcenter.it



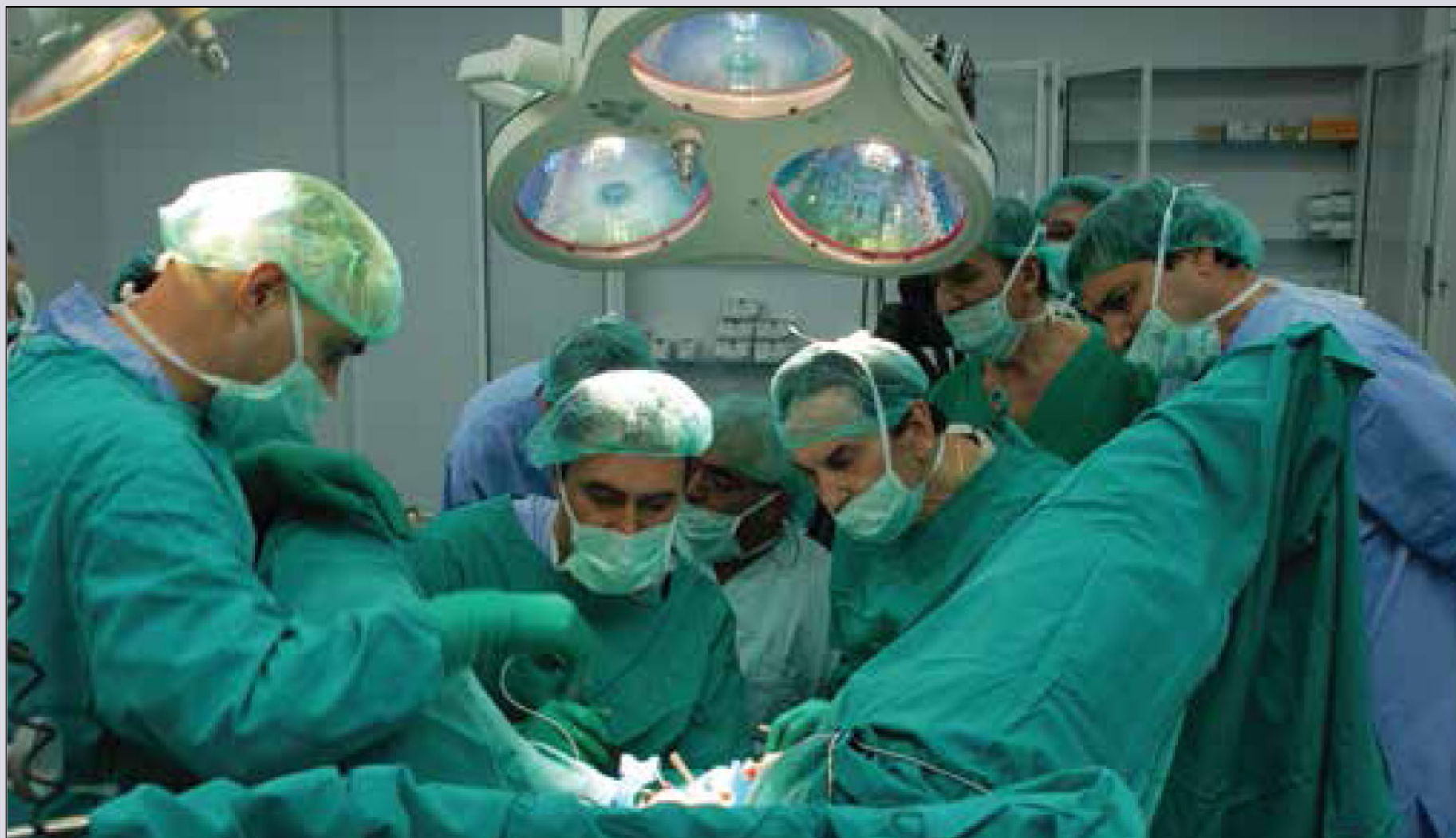5th Surgical Workshop of CUGRS SAVA PEROVIC

3-day Live-Surgery Workshop and Lectures
26 - 28 September 2013

Belgrade – Serbia

e-mail: info@urethralcenter.it

Websites: www.uretra.it
www.urethralcenter.it



e-mail: info@urethralcenter.it

Websites: www.uretra.it
www.urethralcenter.it

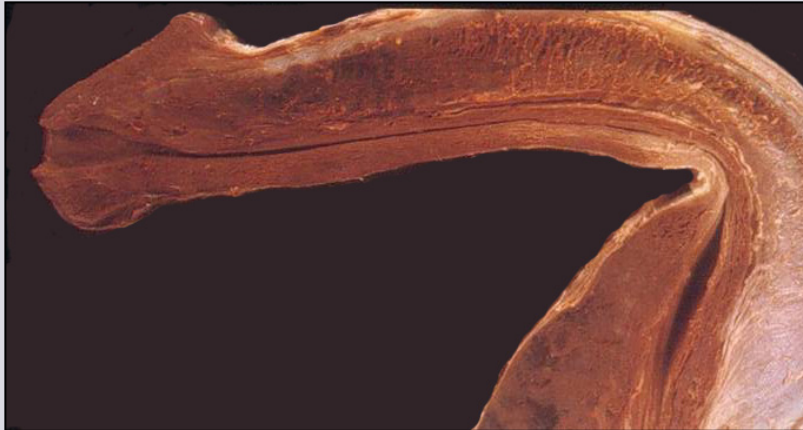
CENTER FOR RECONSTRUCTIVE UROLOGICAL SURGERY

New classification of urethral stricture diseases and a simplified algorithm for their treatment

e-mail: info@urethralcenter.it

Websites: www.uretra.it
www.urethralcenter.it

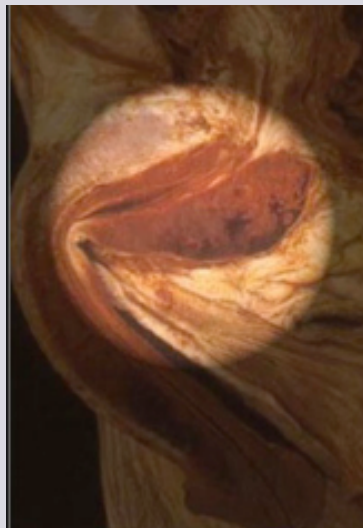
New classification of anterior urethral strictures



Penile

Simple

Complex

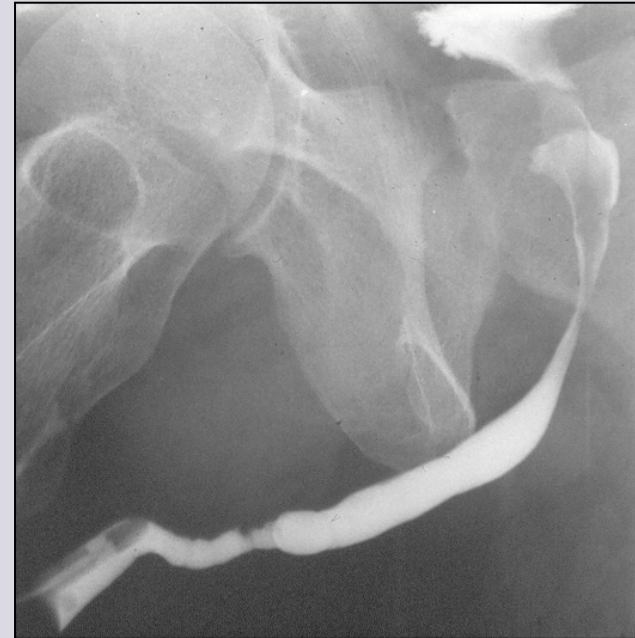
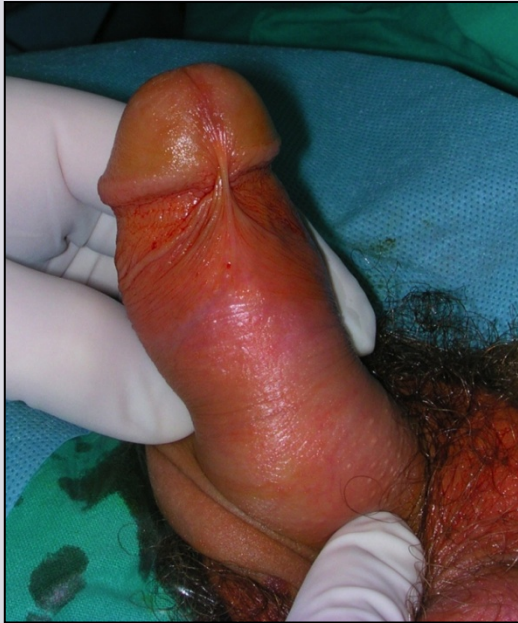
Bulbar

Traumatic

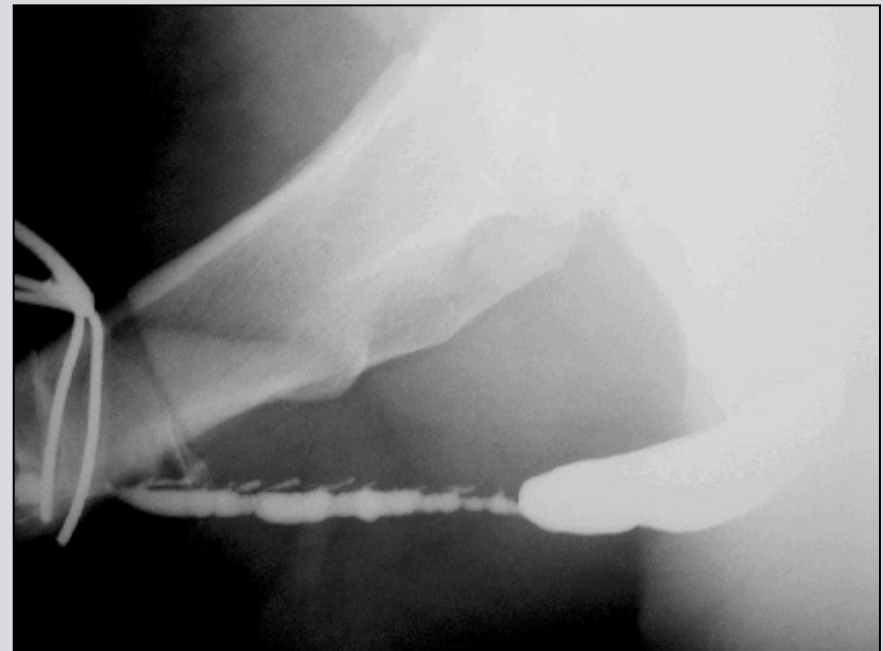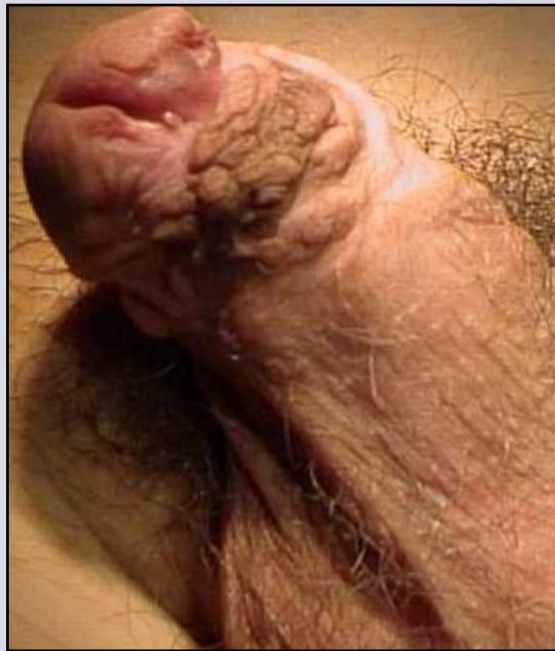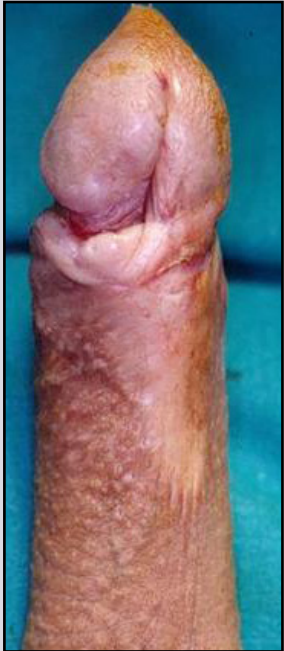Non-traumatic

Simple penile urethral stricture



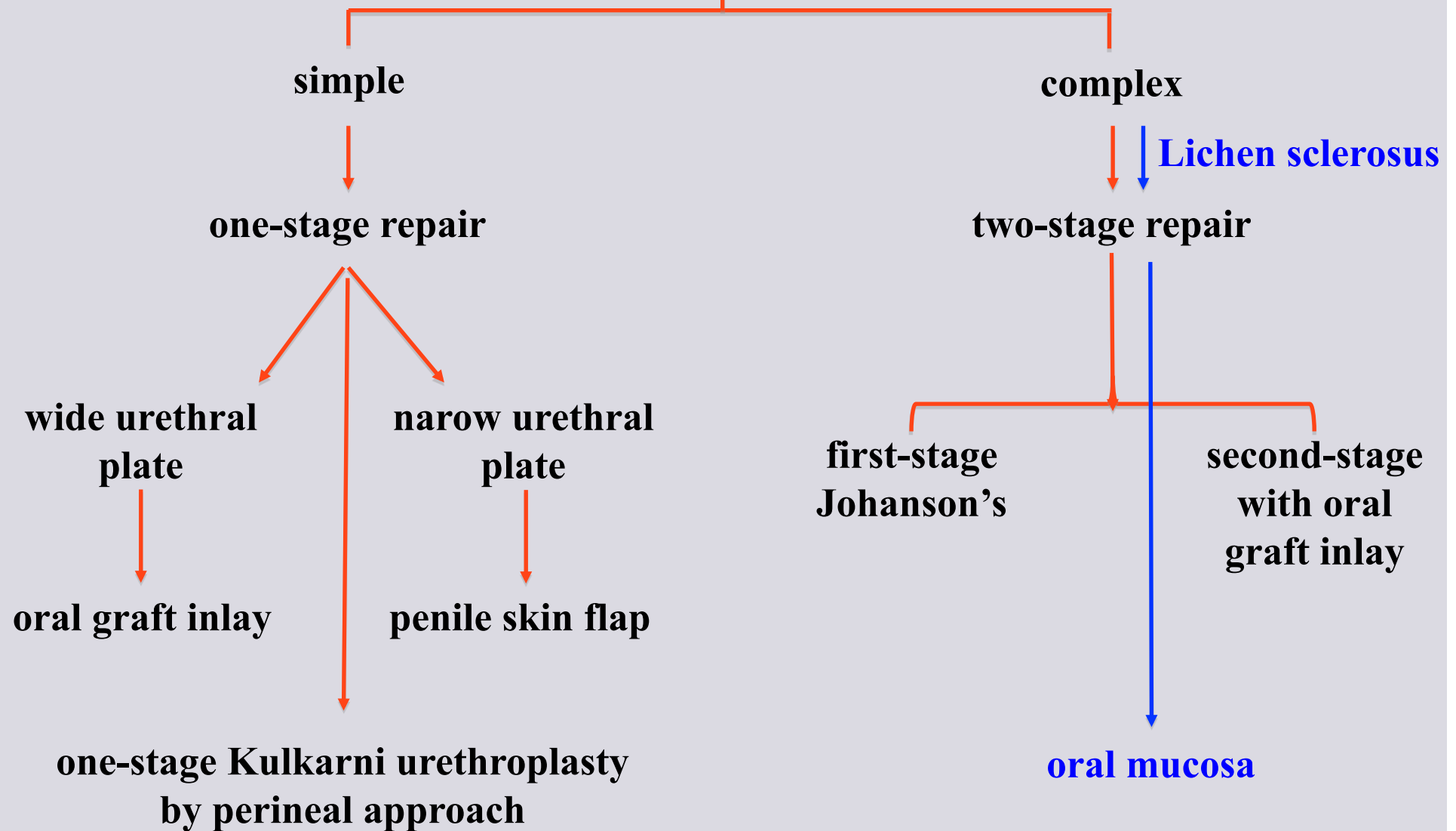
1. The penis and genitalia are normal
2. Practicable urethral plate
3. No Lichen sclerosus
4. No failed hypospadias repair
5. No prior failed urethroplasty

Complex penile urethral stricture



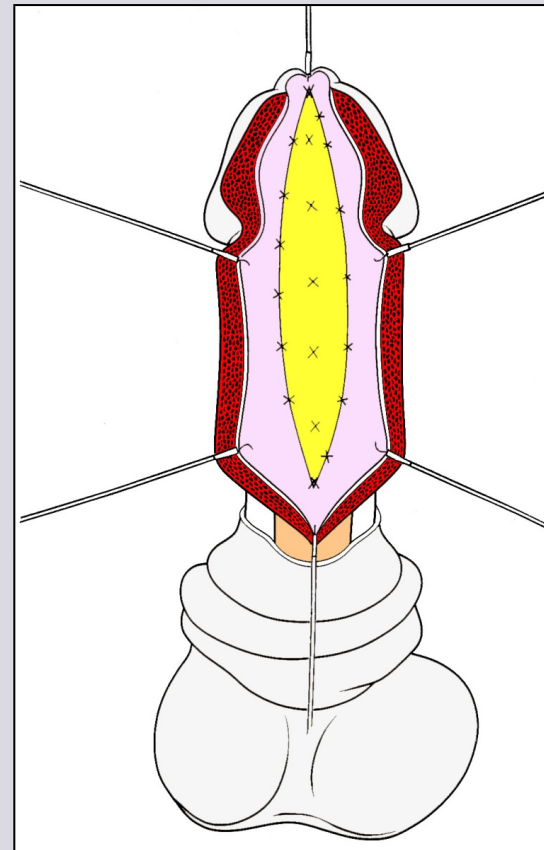
1. Genital Lichen sclerosus
2. Failed hypospadias repair
3. Prior failed urethroplasty
4. No practicable urethral plate

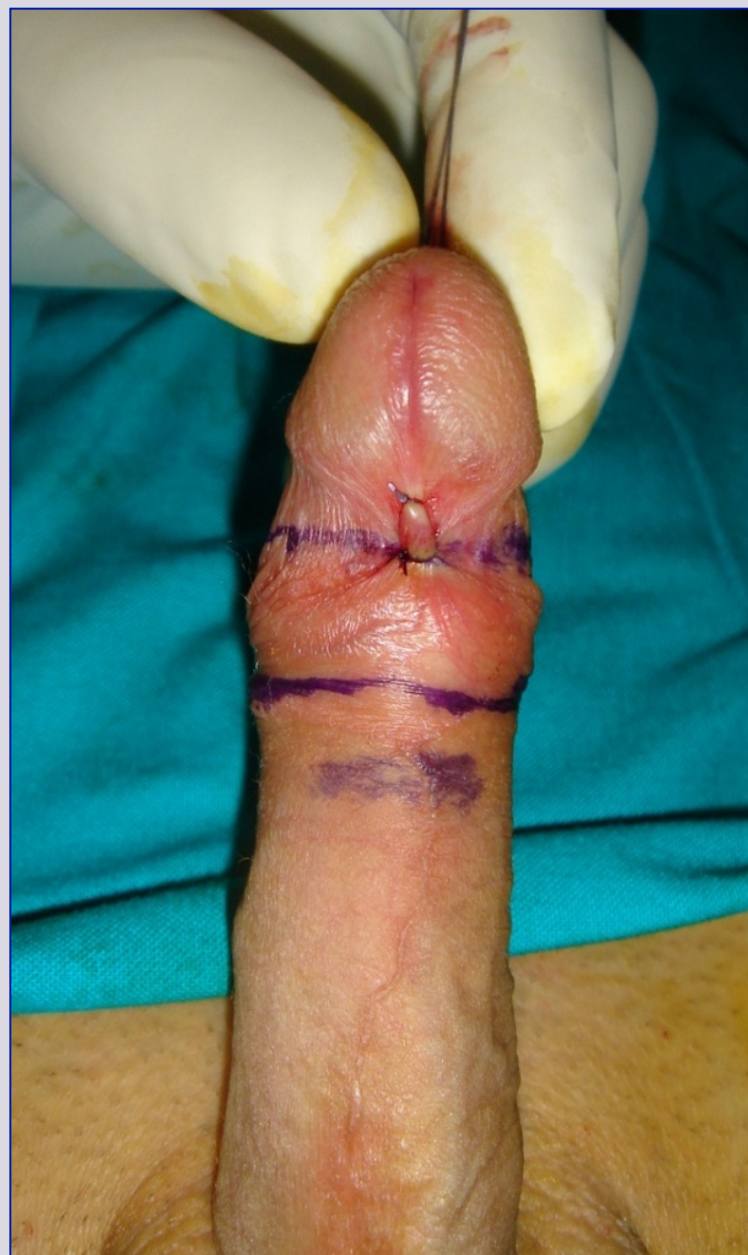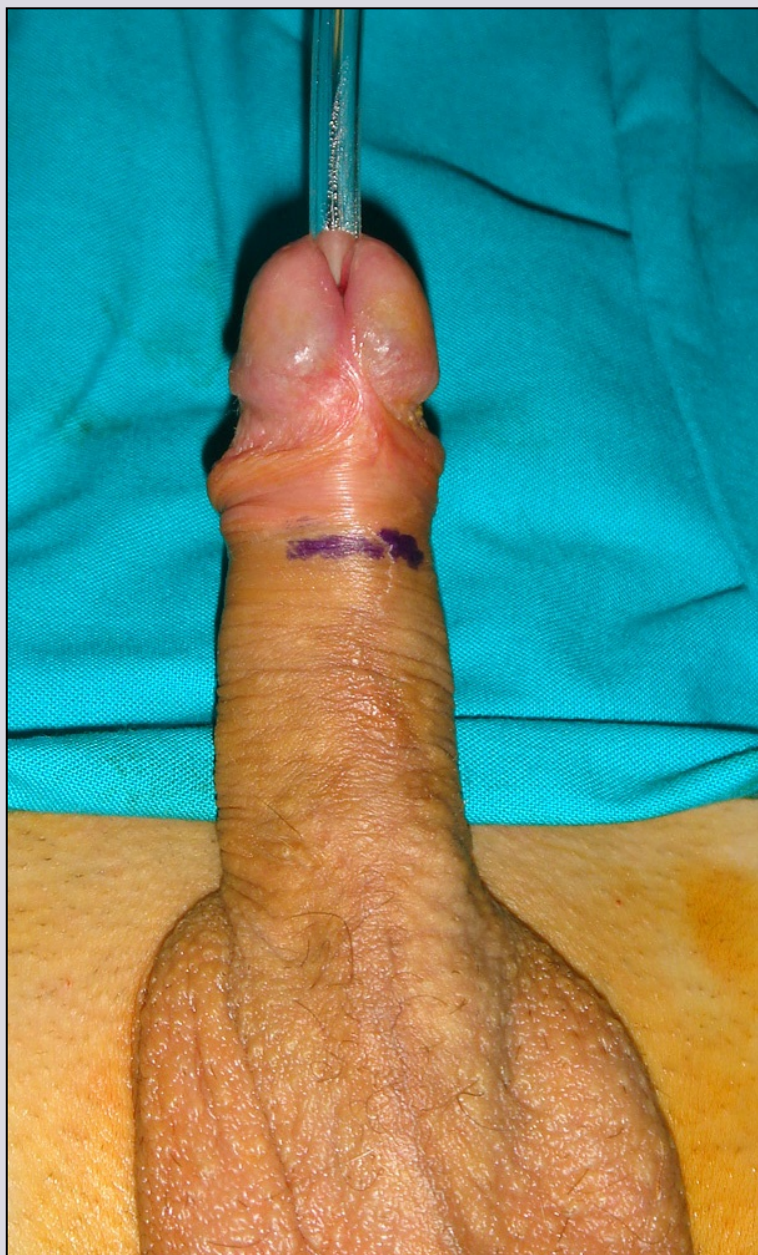Penile urethral stricture



One-stage penile graft urethroplasty (wide urethral plate)

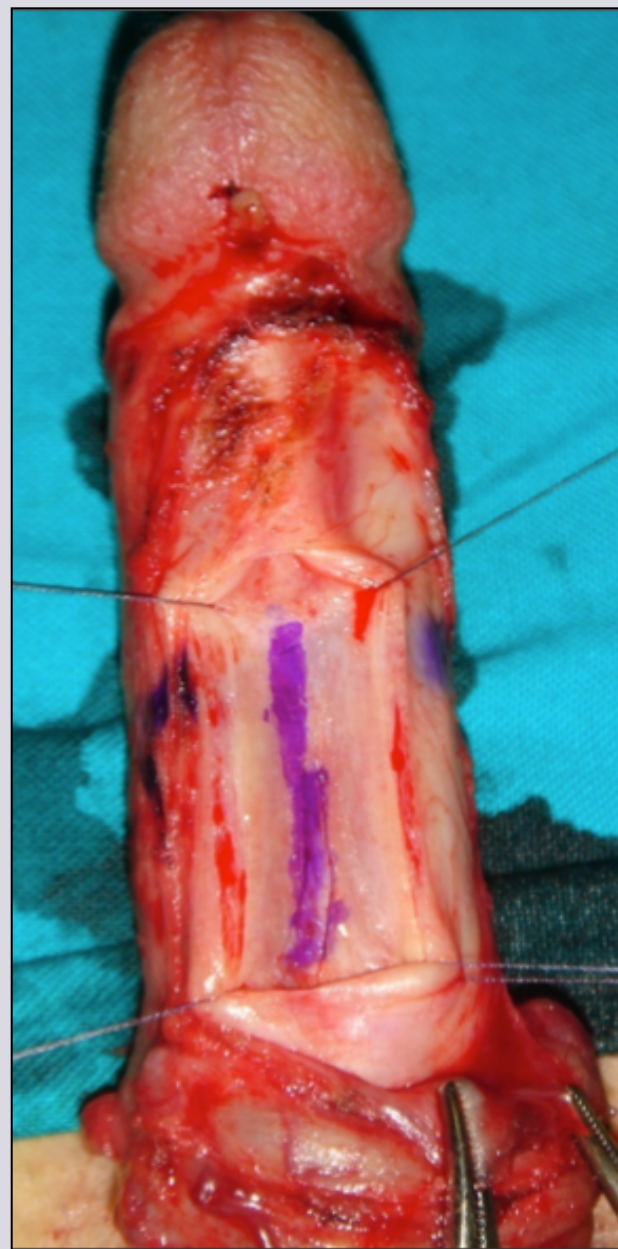
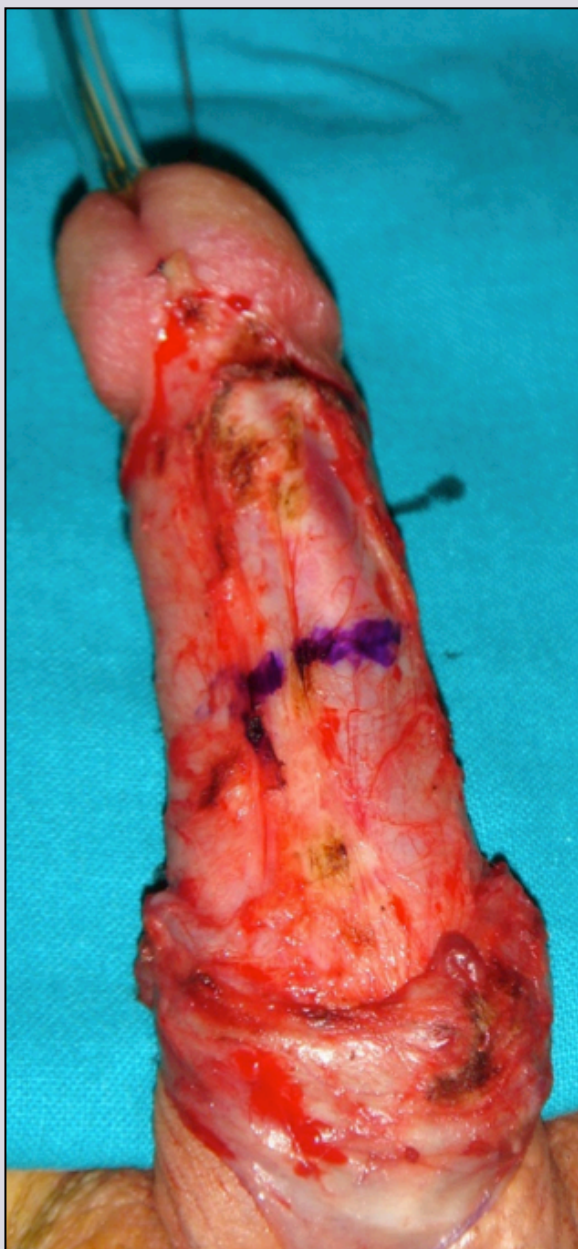Surgical technique





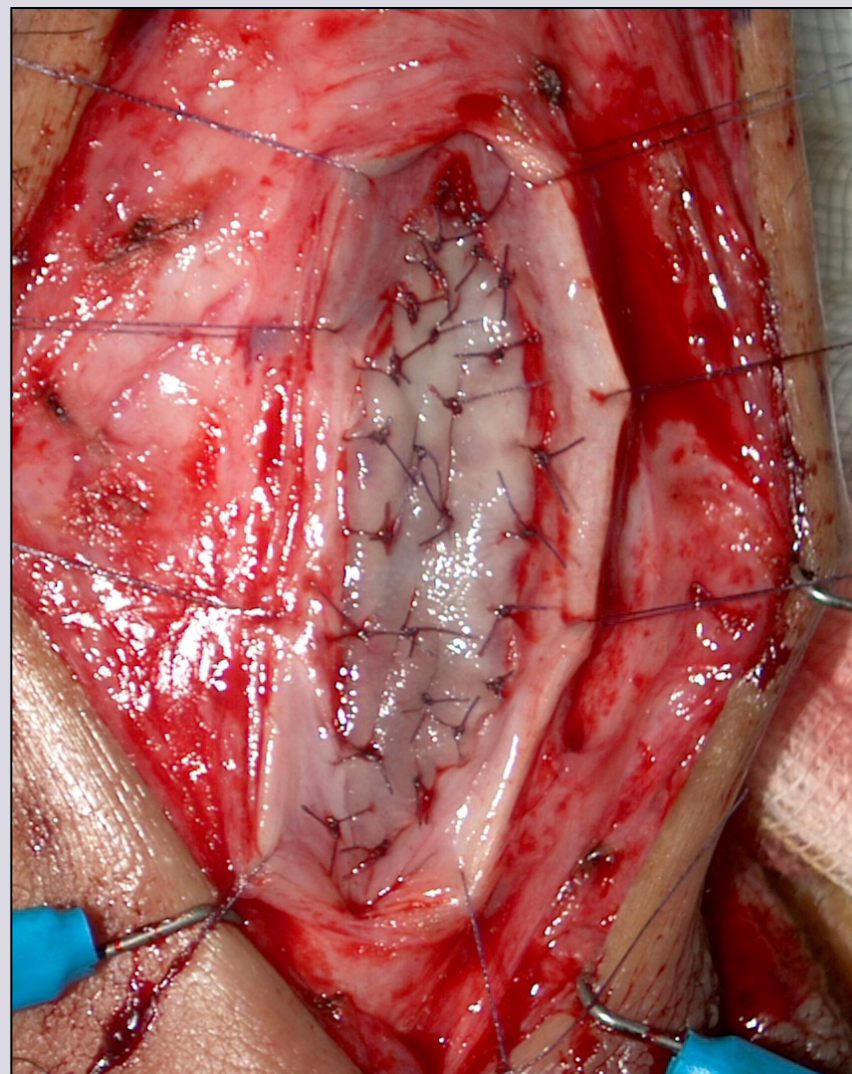
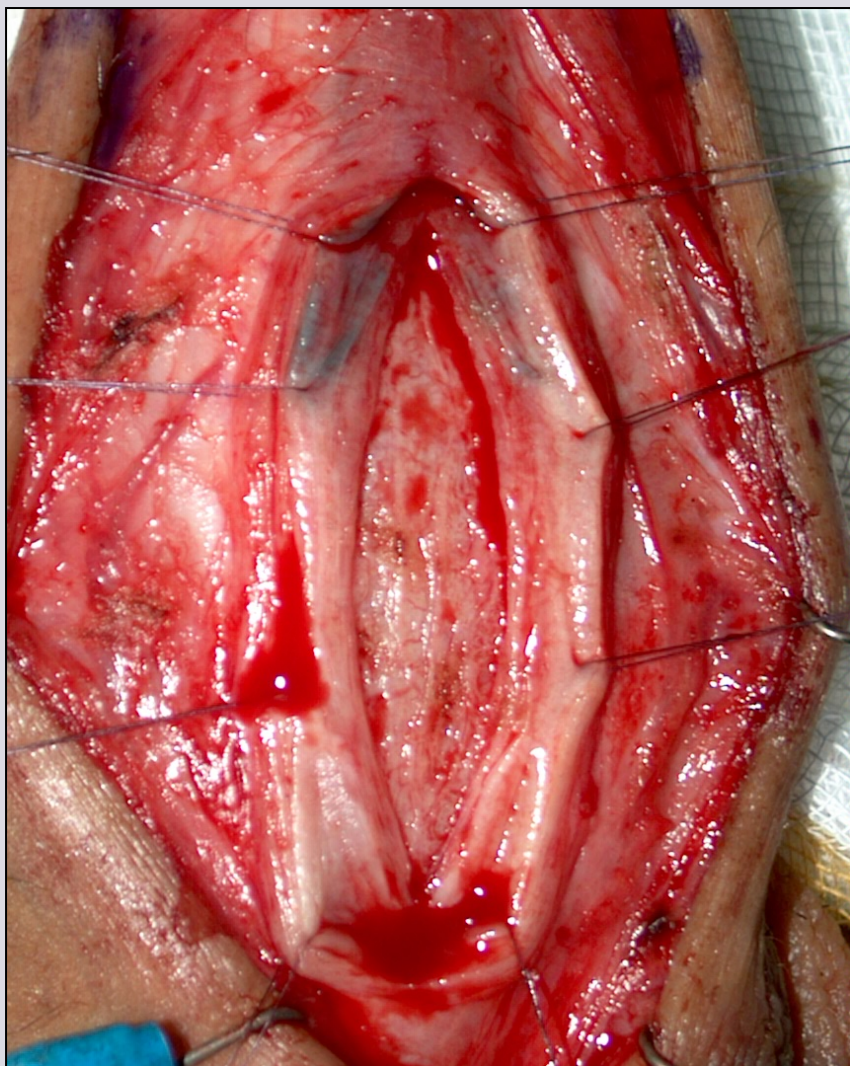
e-mail: info@urethralcenter.it

Websites: www.uretra.it
www.urethralcenter.it



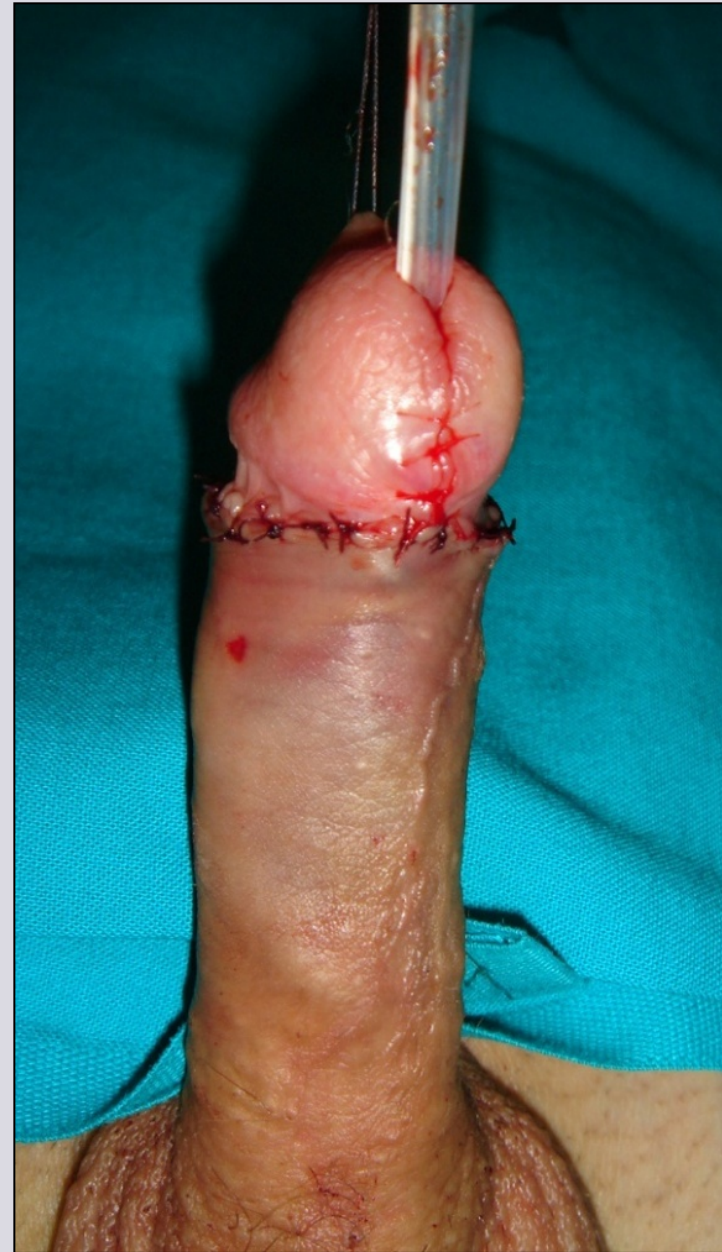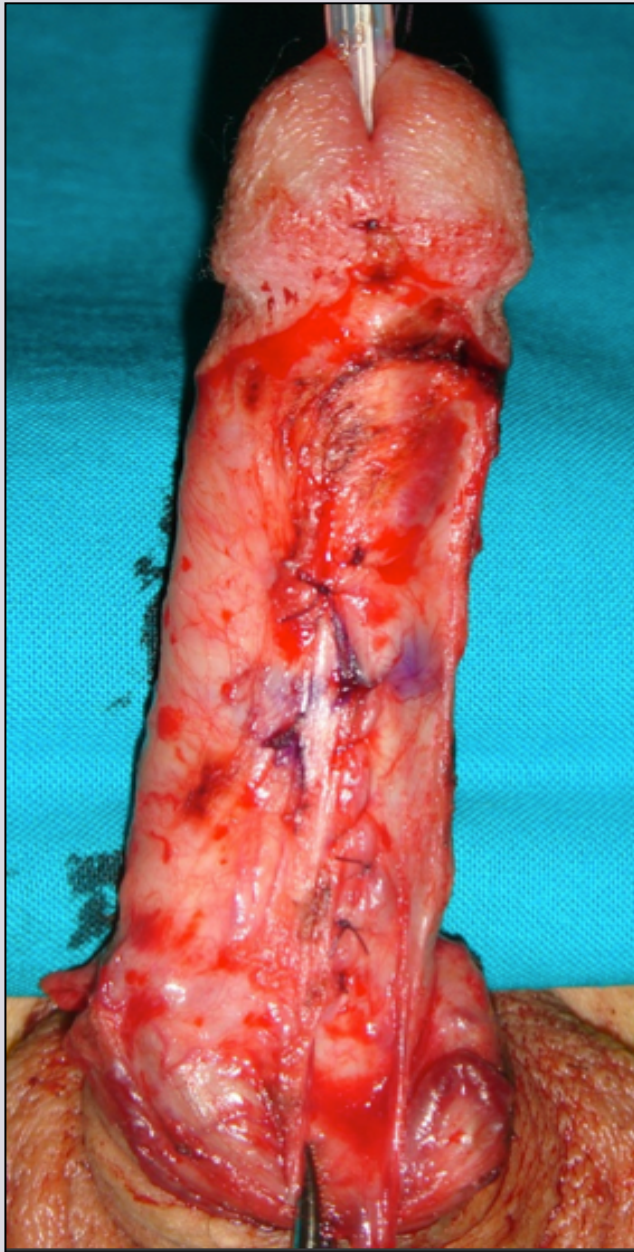e-mail: info@urethralcenter.it

Websites: www.uretra.it
www.urethralcenter.it



e-mail: info@urethralcenter.it

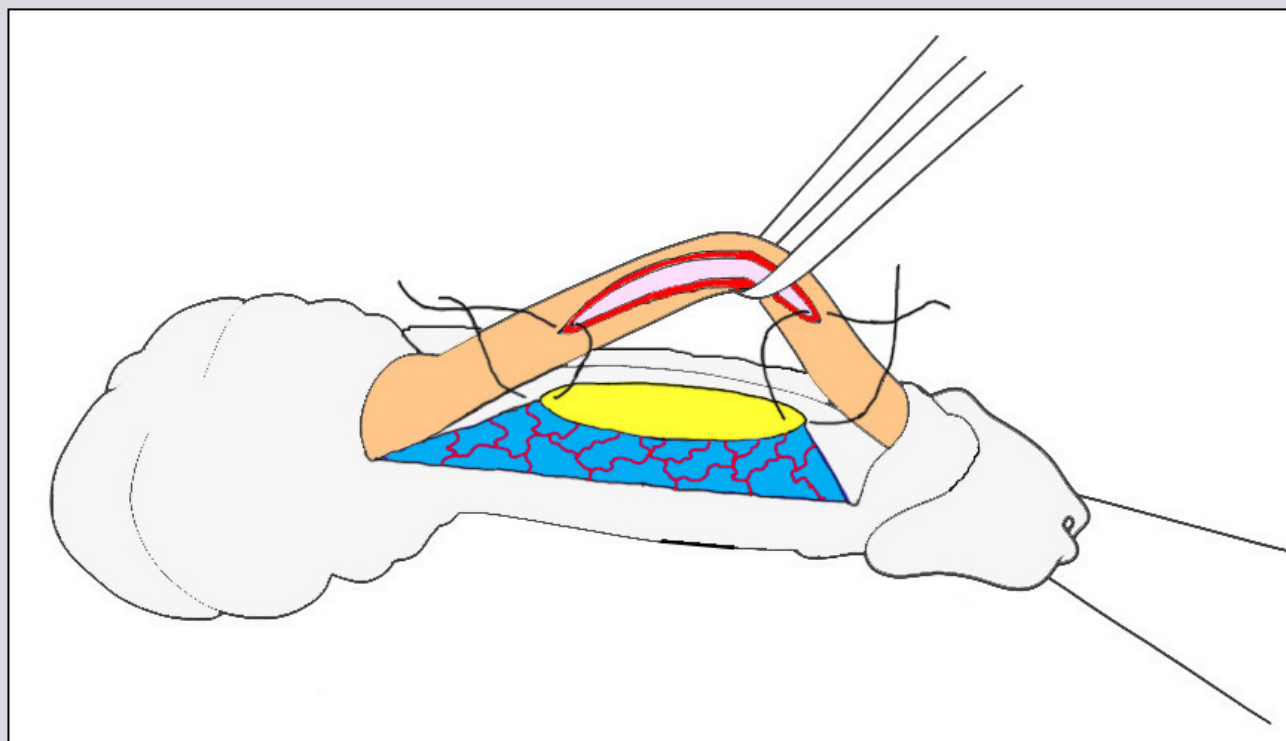
Websites: www.uretra.it
www.urethralcenter.it



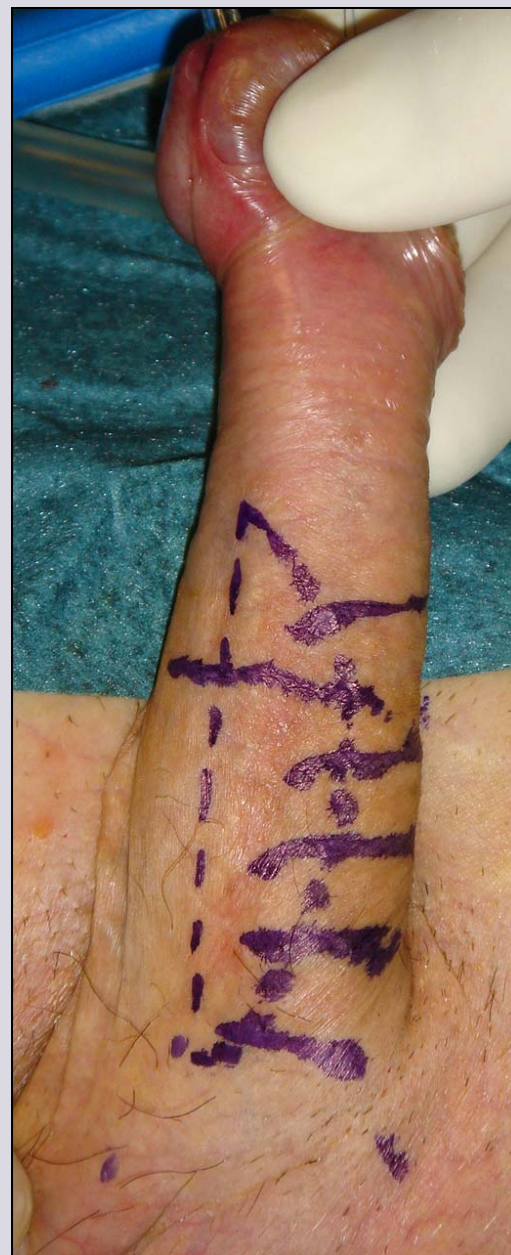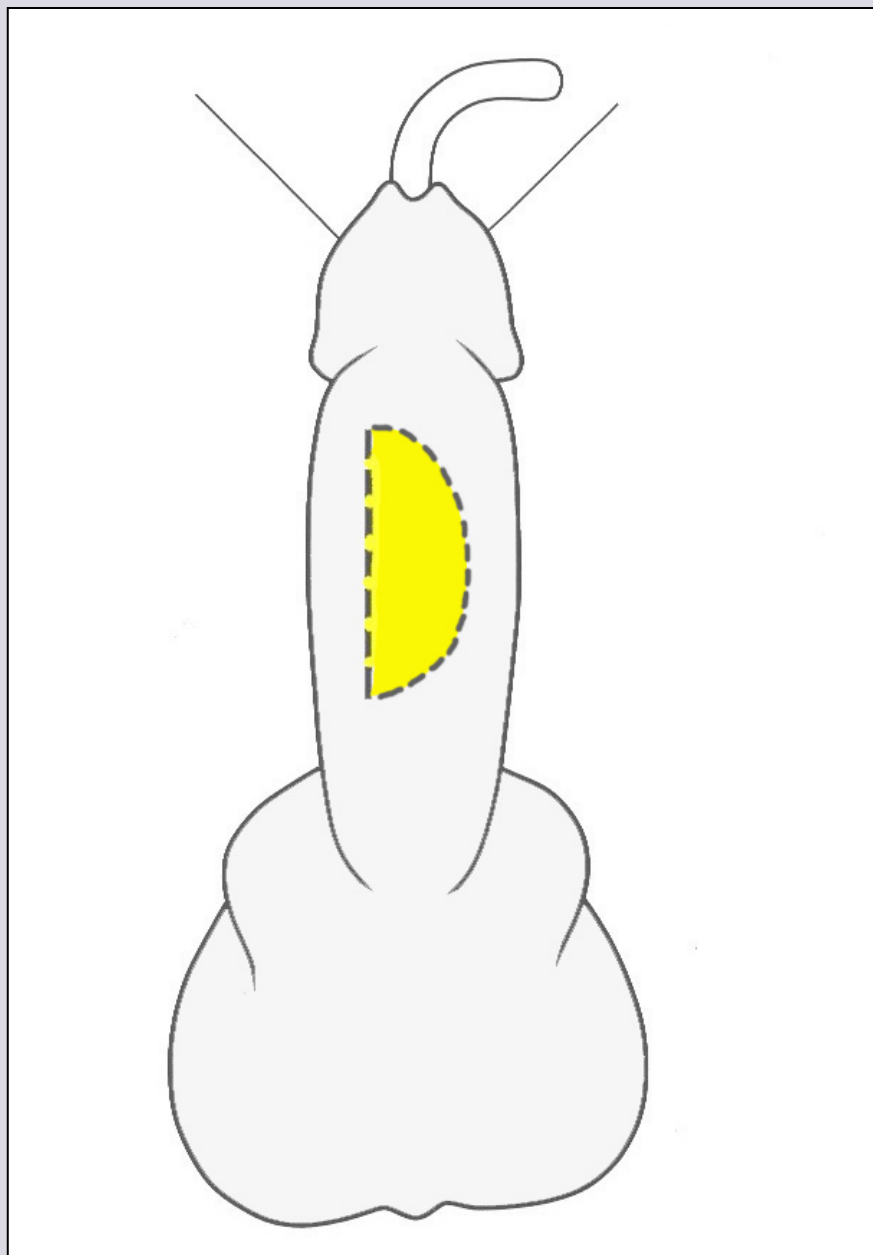
e-mail: info@urethralcenter.it

Websites: www.uretra.it
www.urethralcenter.it

One-stage penile flap urethroplasty (narrow urethral plate)

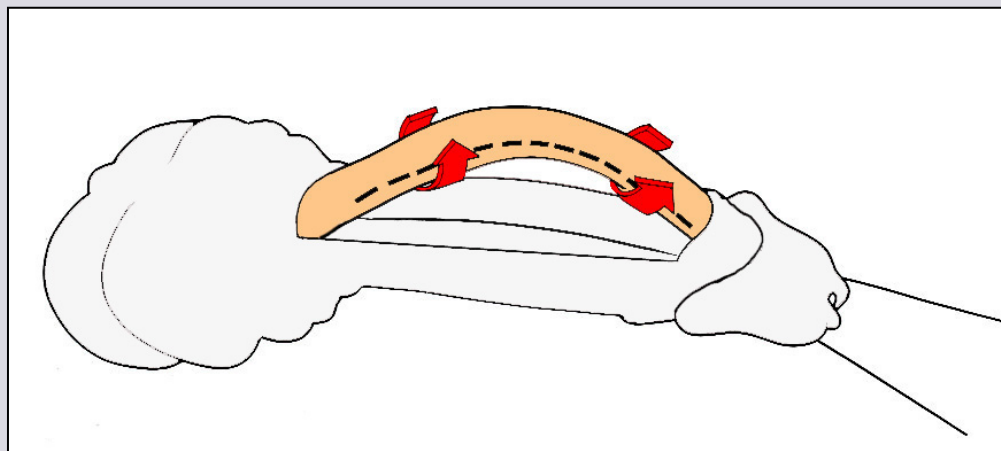
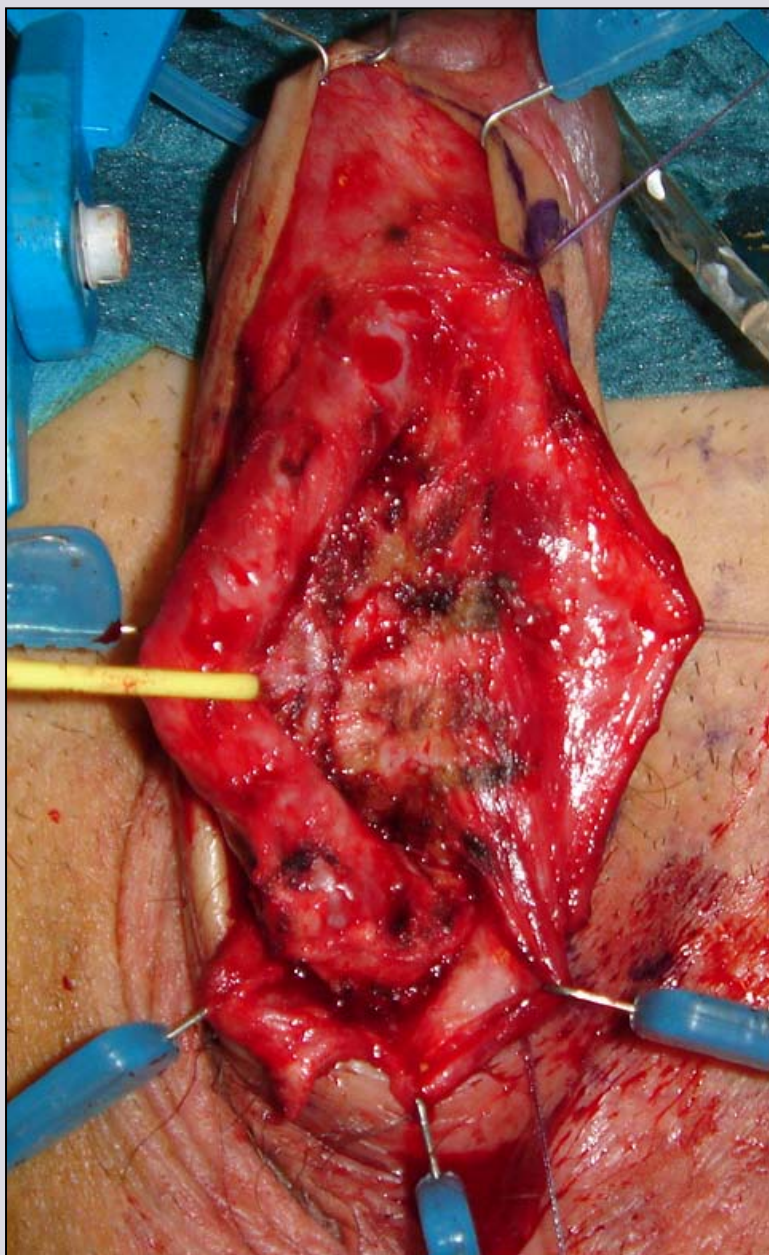


Surgical technique



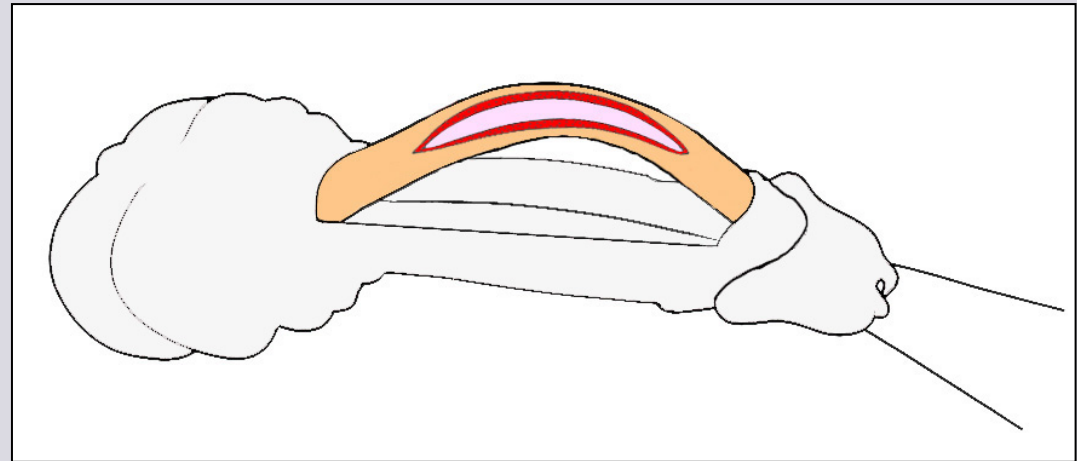
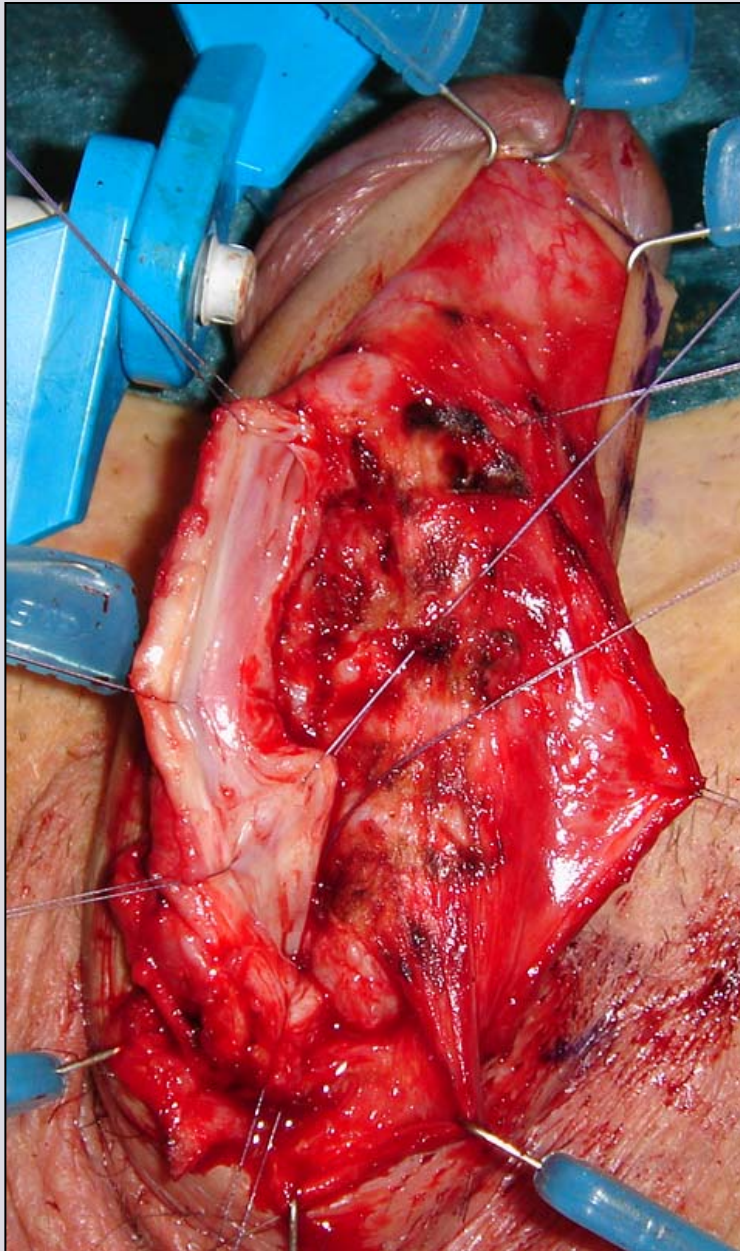
e-mail: info@urethralcenter.it

Websites: www.uretra.it
www.urethralcenter.it



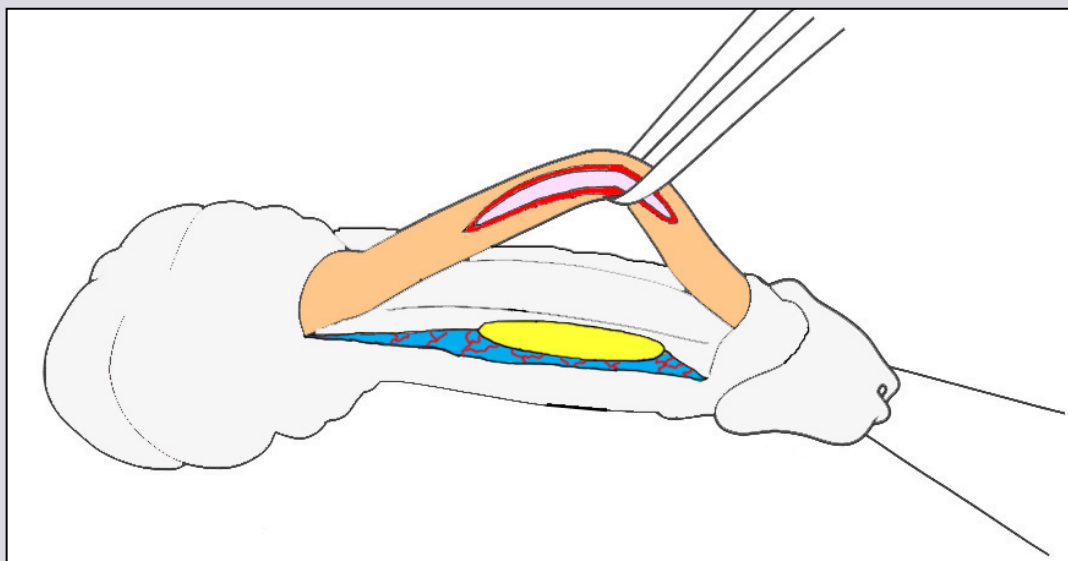
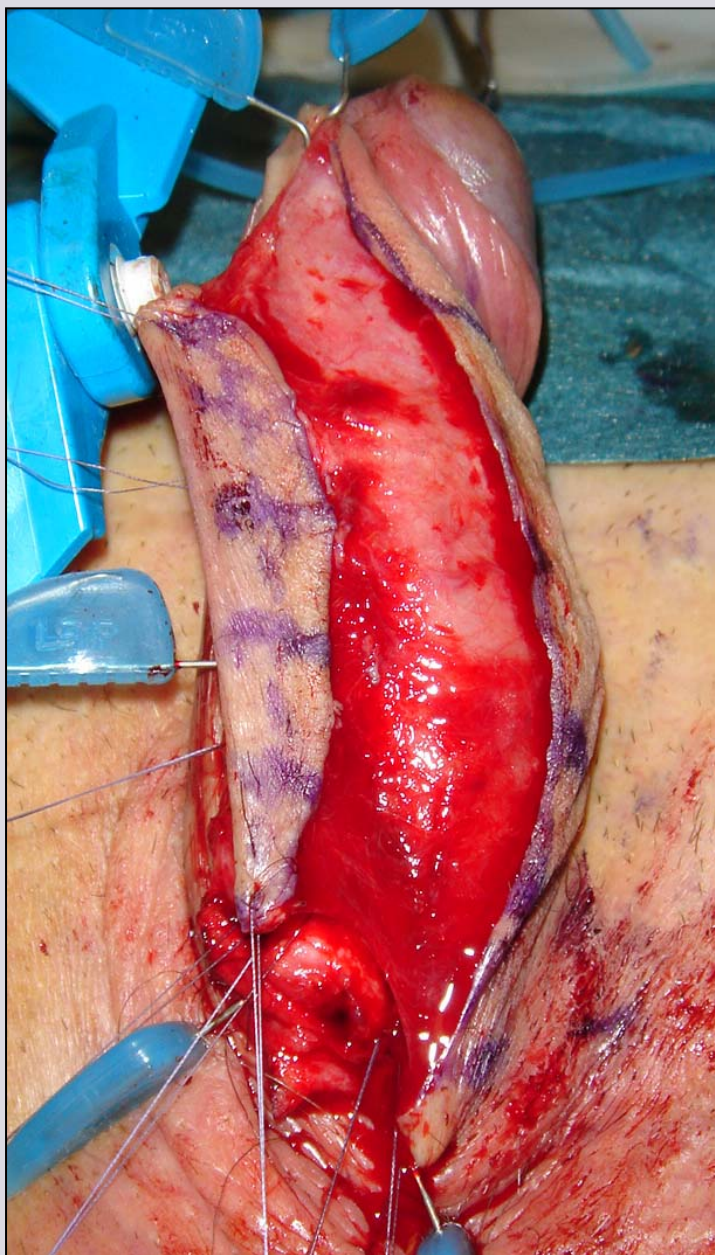
e-mail: info@urethralcenter.it

Websites: www.uretra.it
www.urethralcenter.it



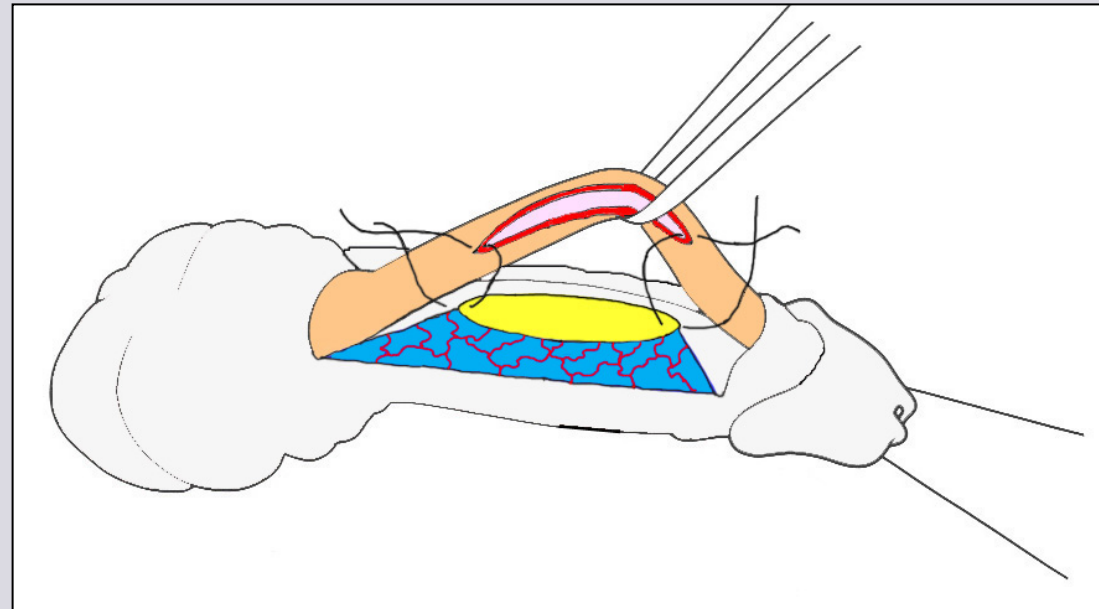
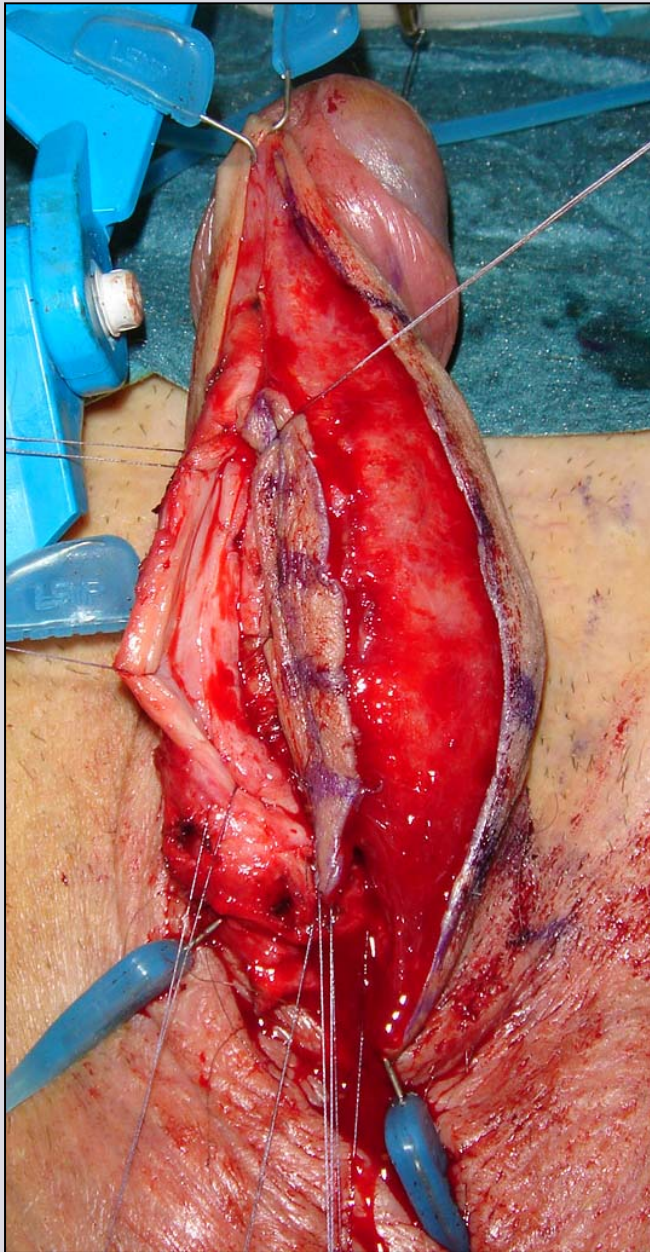
e-mail: info@urethralcenter.it

Websites: www.uretra.it
www.urethralcenter.it



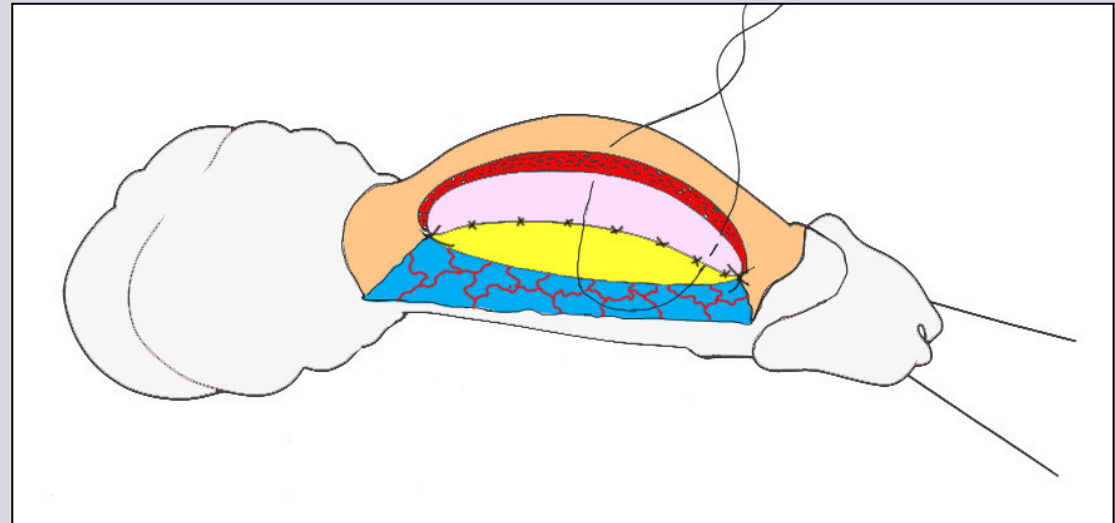
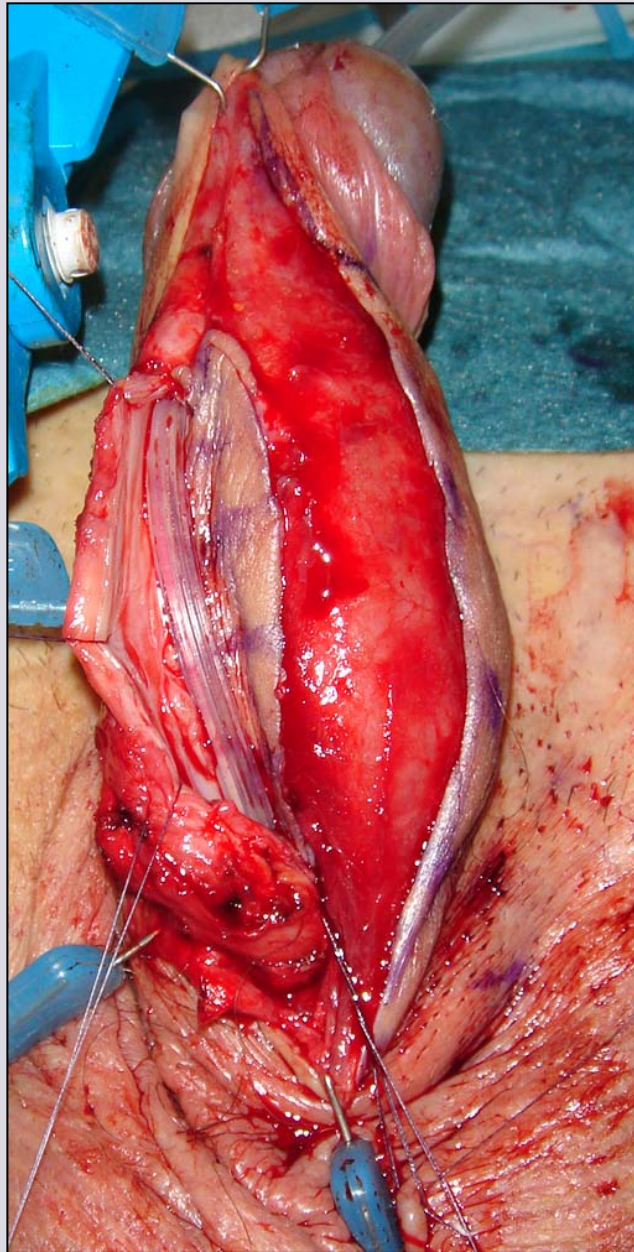
e-mail: info@urethralcenter.it

Websites: www.uretra.it
www.urethralcenter.it



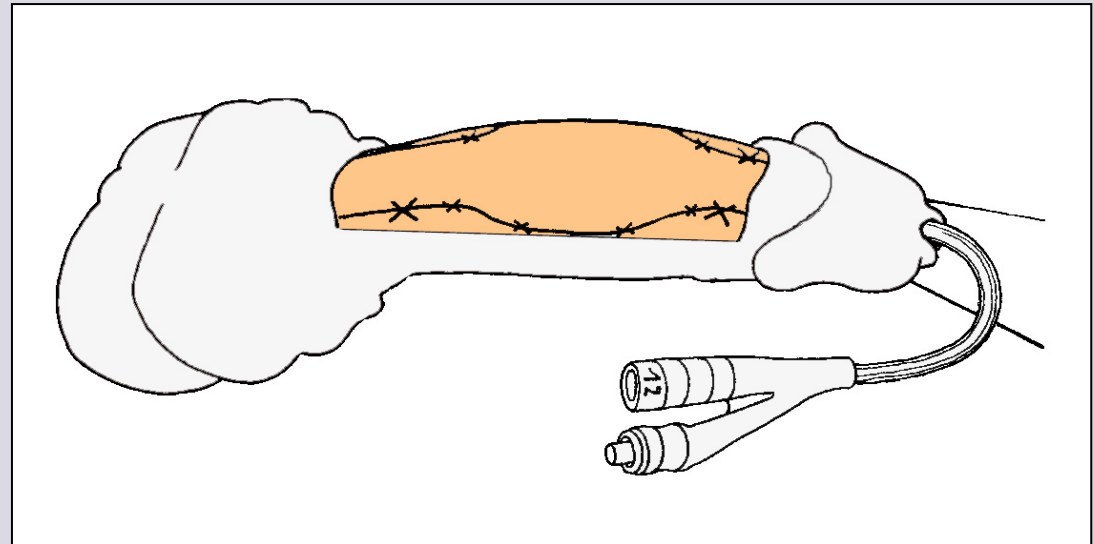
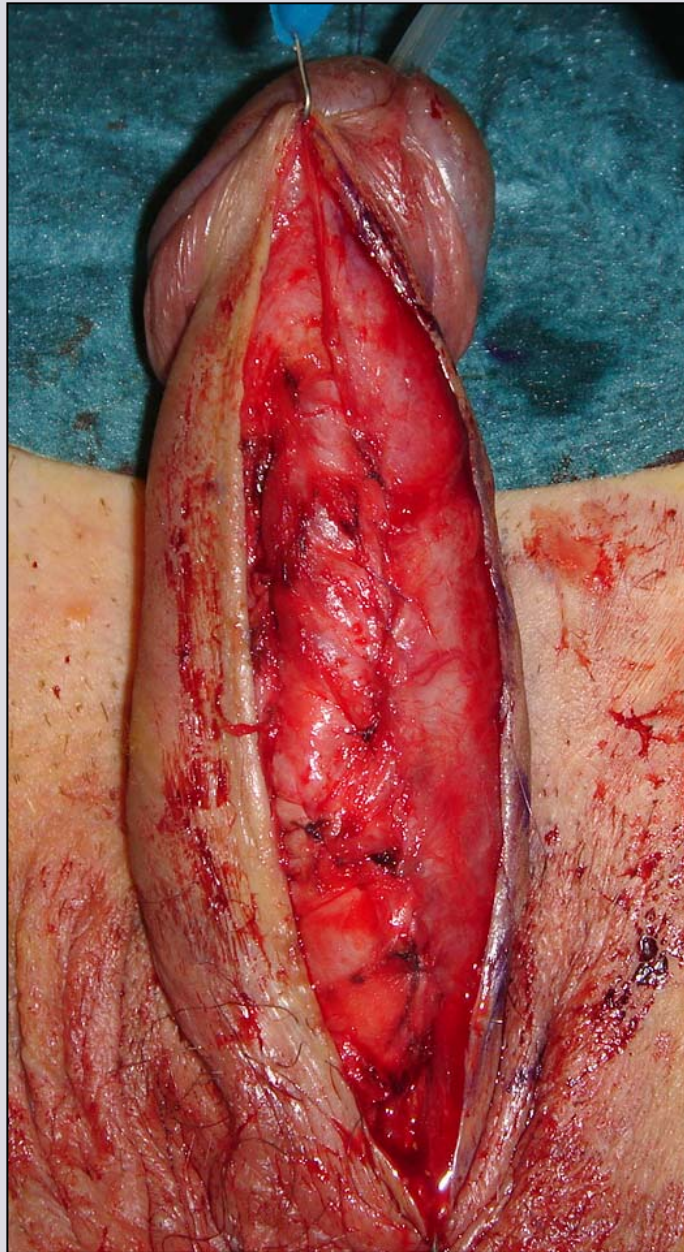
e-mail: info@urethralcenter.it

Websites: www.uretra.it
www.urethralcenter.it



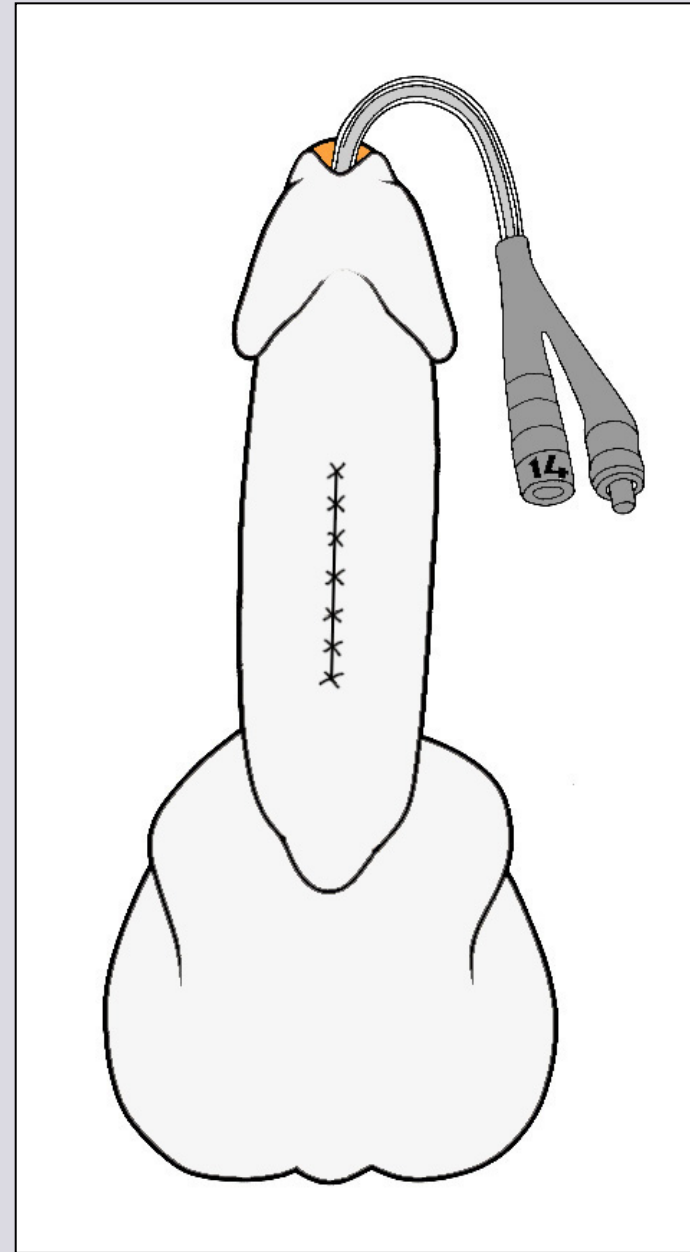
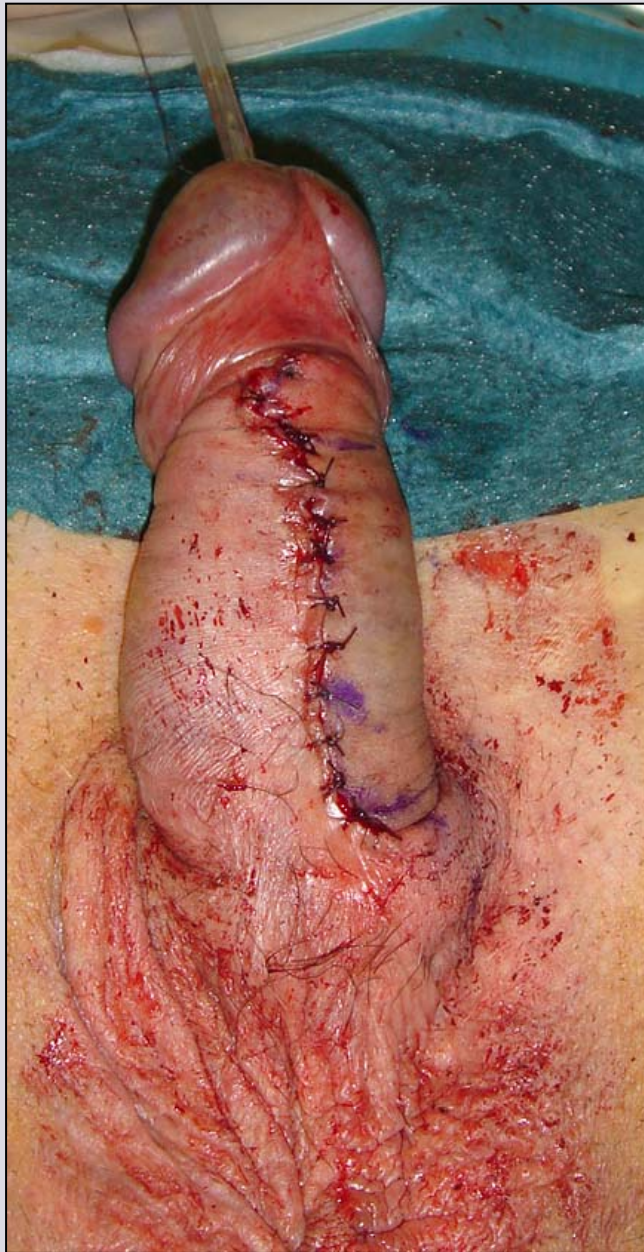e-mail: info@urethralcenter.it

Websites: www.uretra.it
www.urethralcenter.it



e-mail: info@urethralcenter.it

Websites: www.uretra.it
www.urethralcenter.it



e-mail: info@urethralcenter.it

Websites: www.uretra.it
www.urethralcenter.it

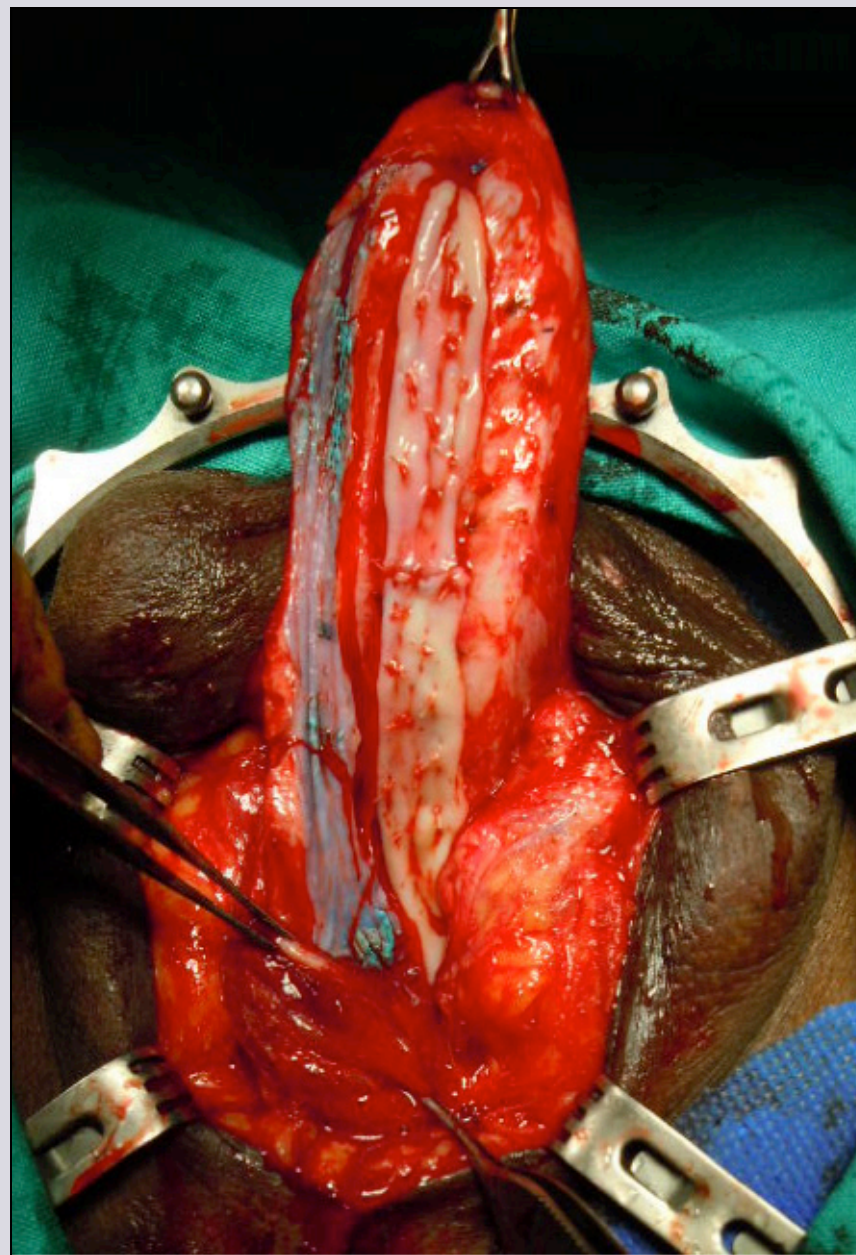
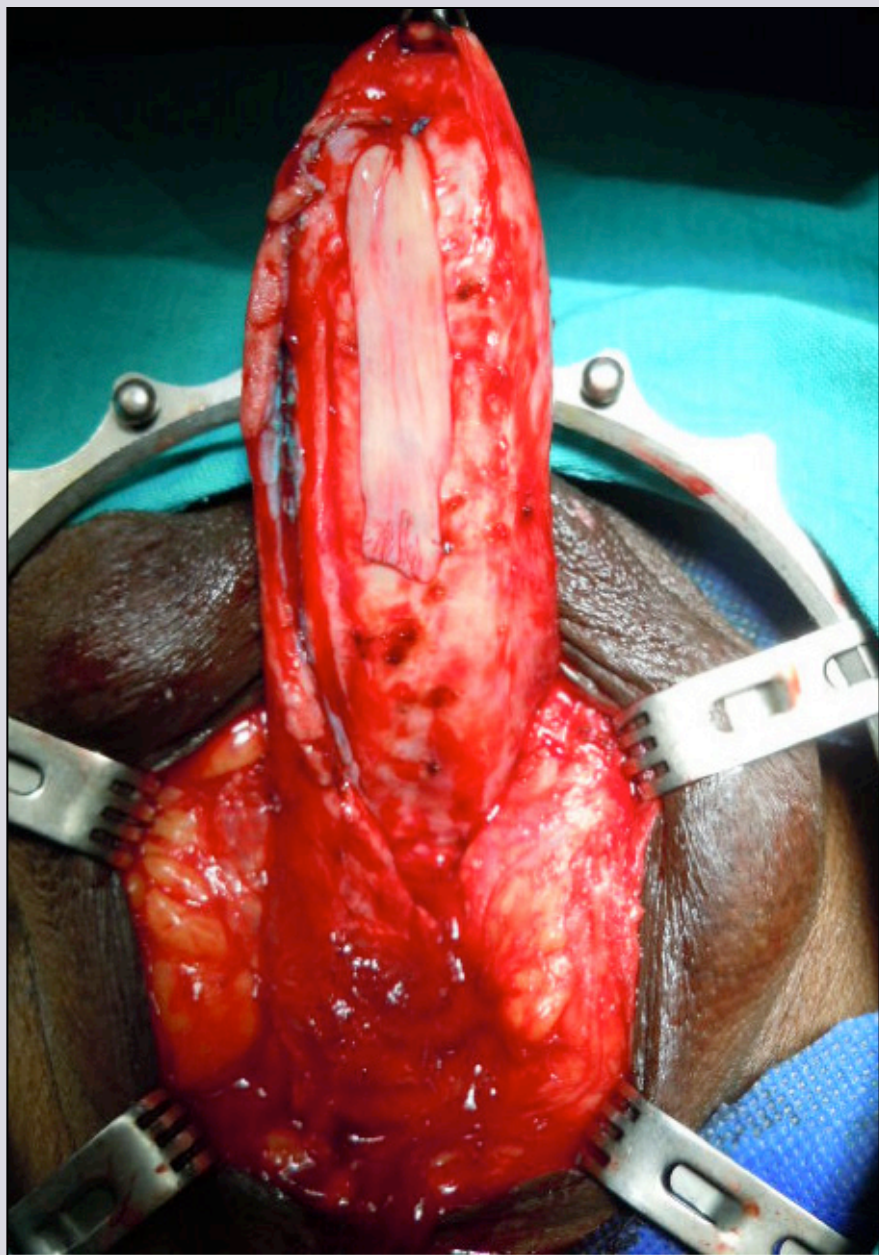
One-stage penile urethroplasty: graft or flap ?

- ❖ NO sure data available from literature
- ❖ NO comparative studies including evaluation of post-operative sexual and aesthetic dysfunctions and patient satisfaction
- ❖ Surgeon background and preference



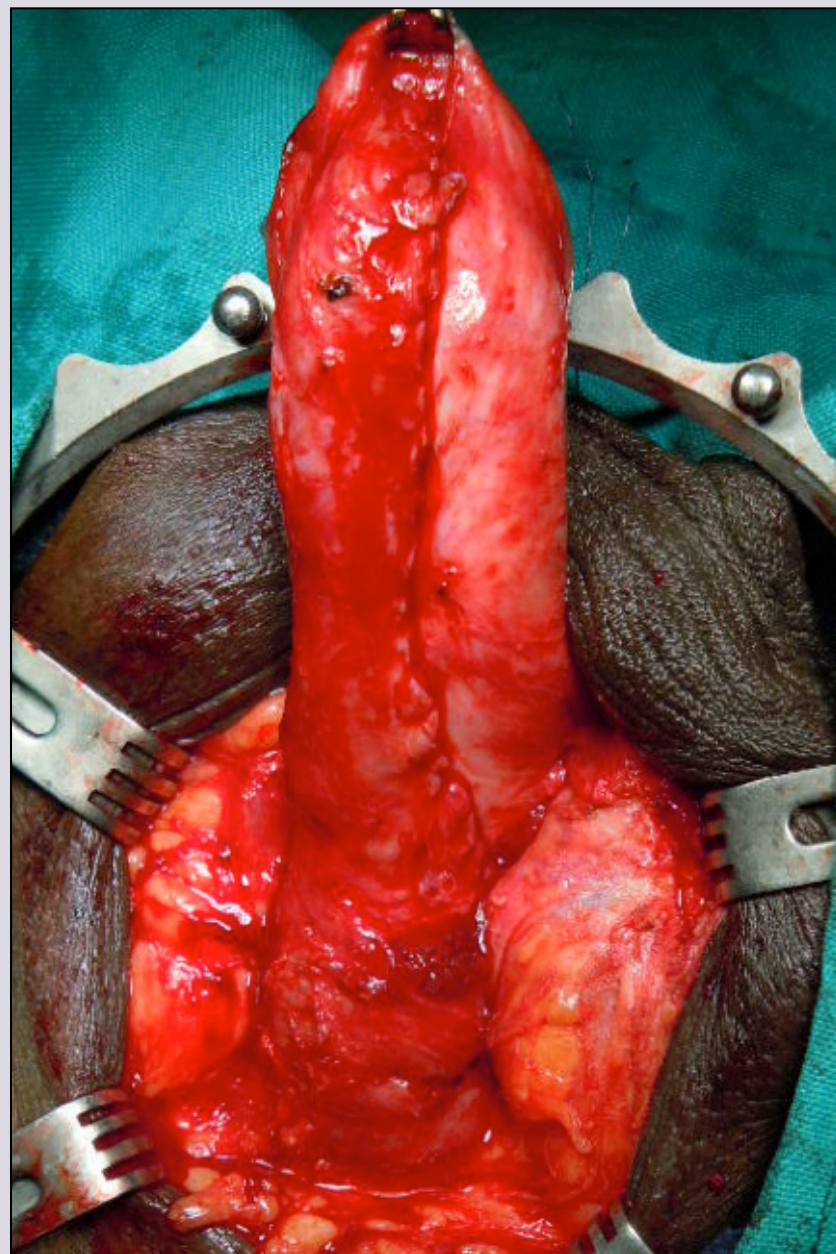
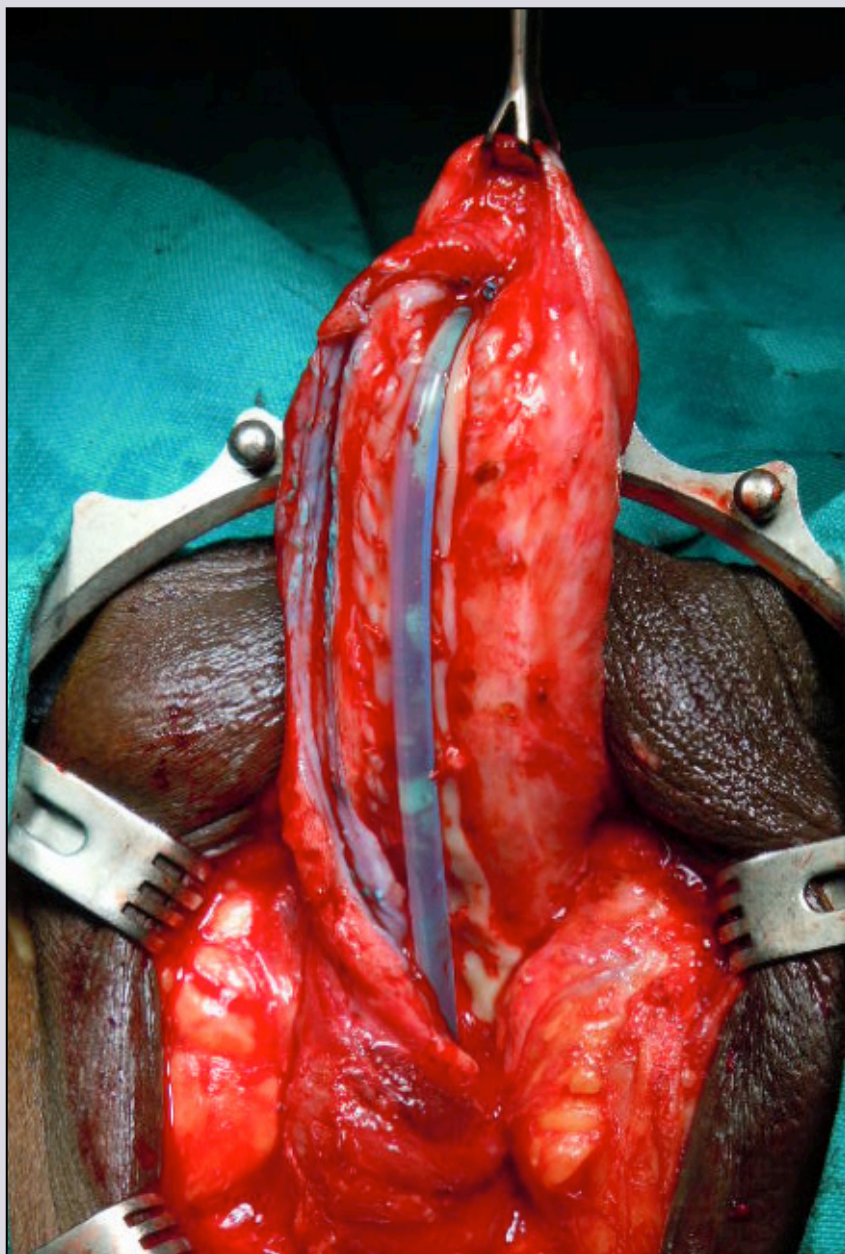
One-stage Kulkarni urethroplasty by perineal approach

Surgical technique



e-mail: info@urethralcenter.it

Websites: www.uretra.it
www.urethralcenter.it

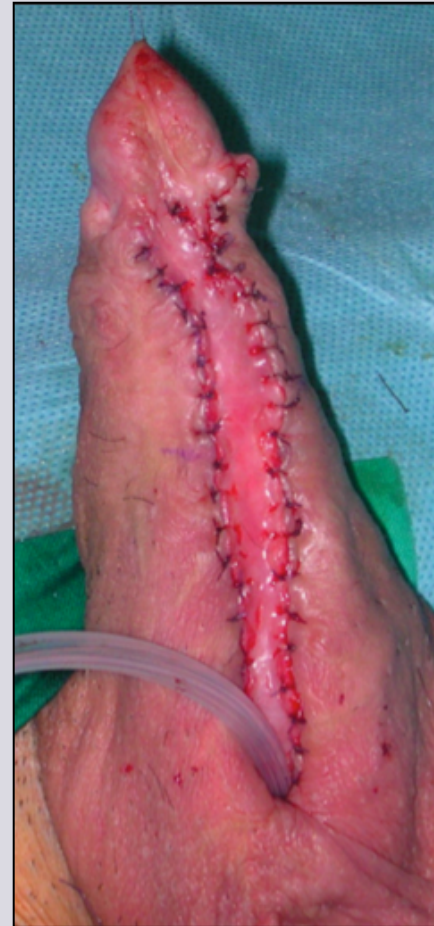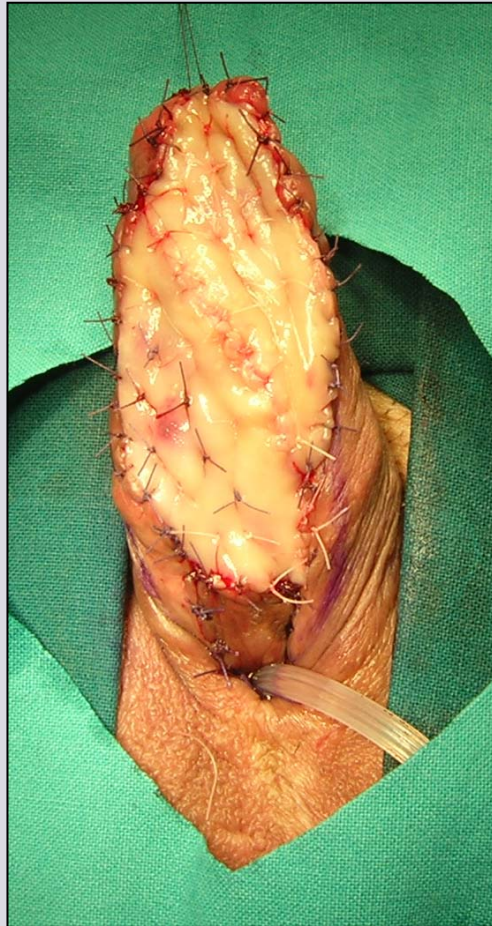


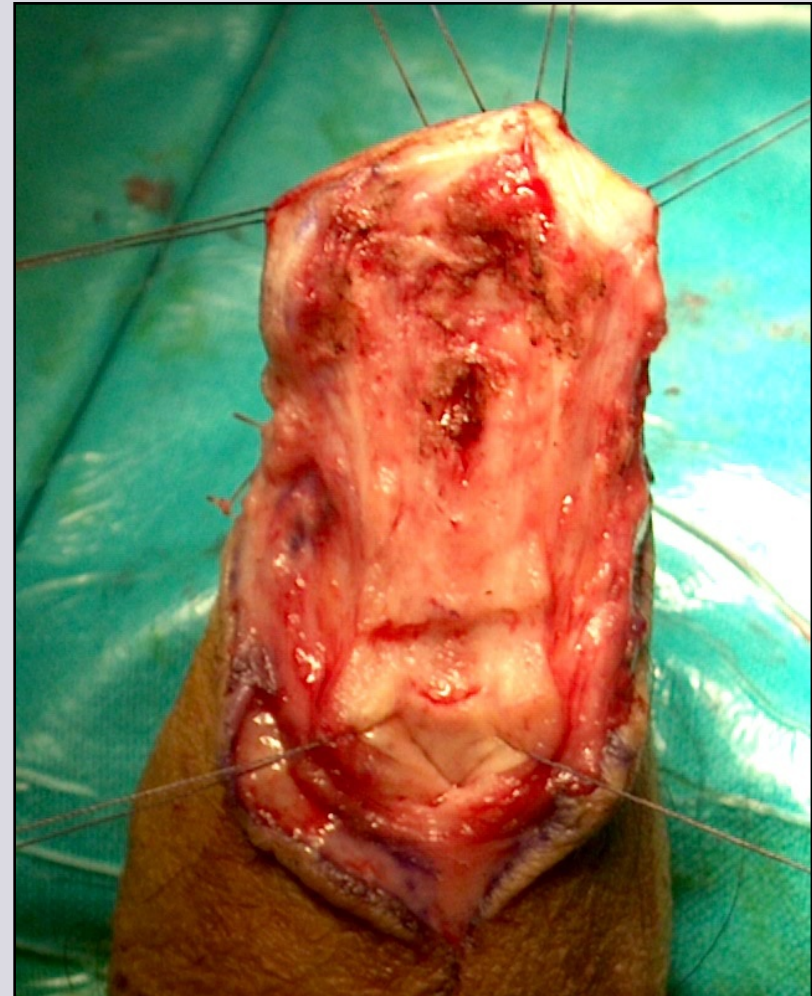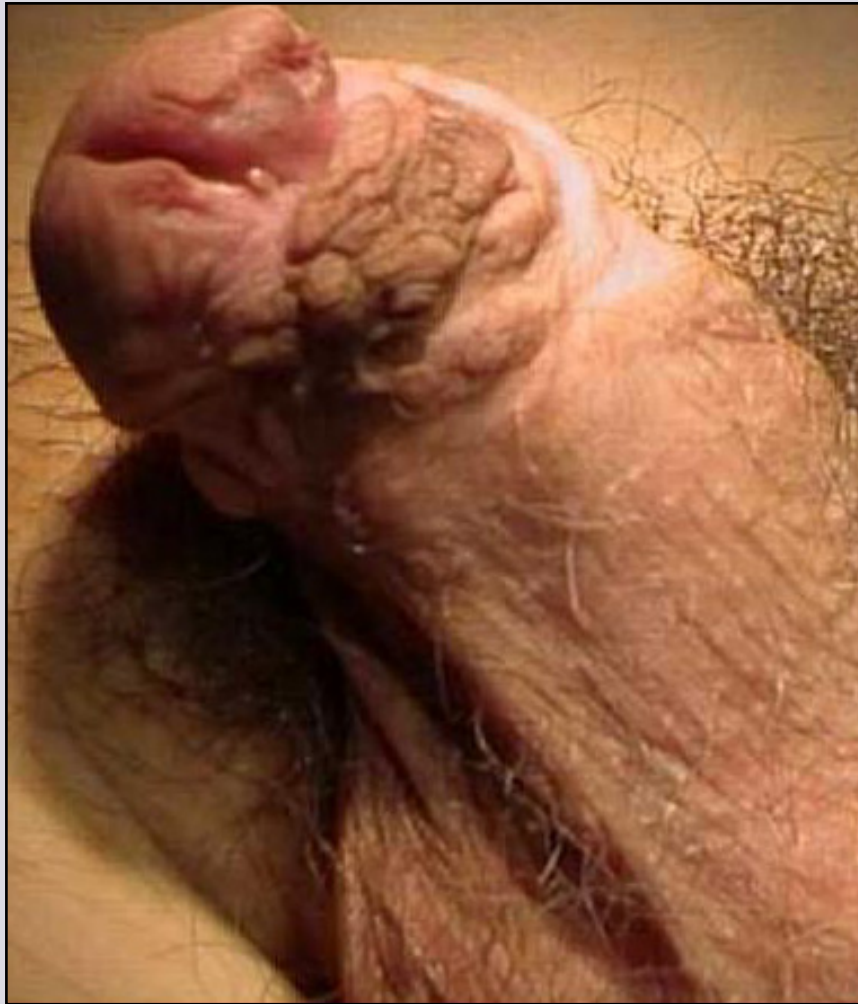e-mail: info@urethralcenter.it

Websites: www.uretra.it
www.urethralcenter.it

Surgical repair of complex penile urethral stricture

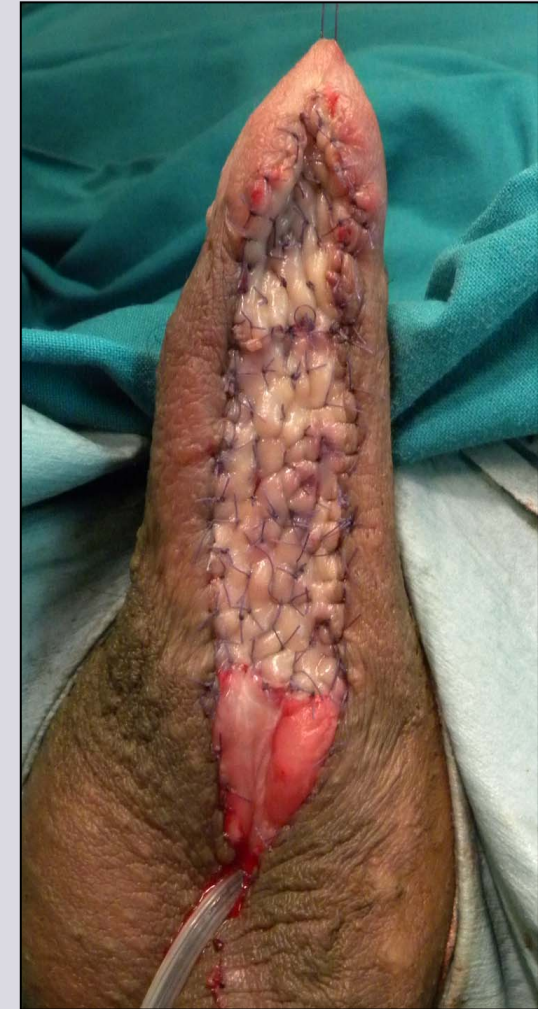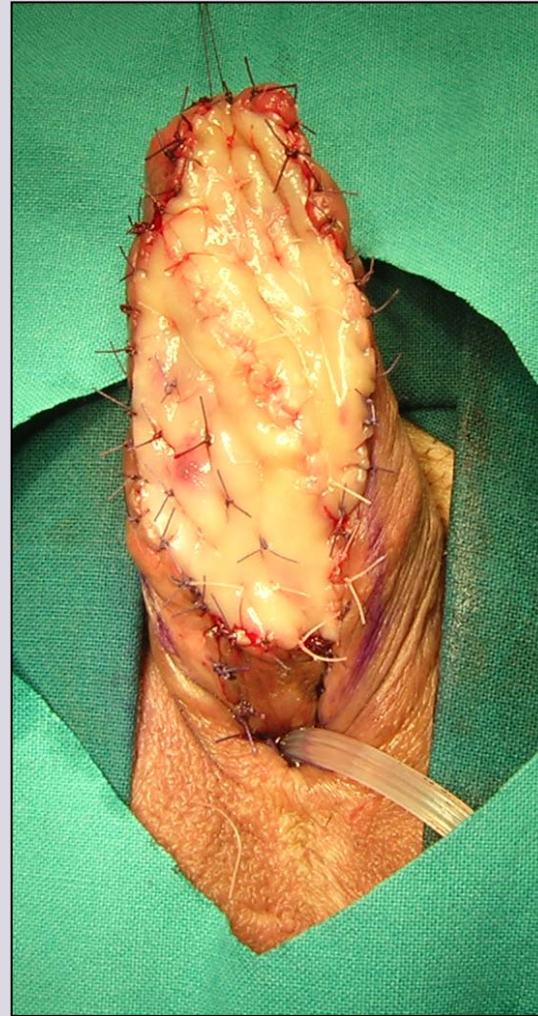
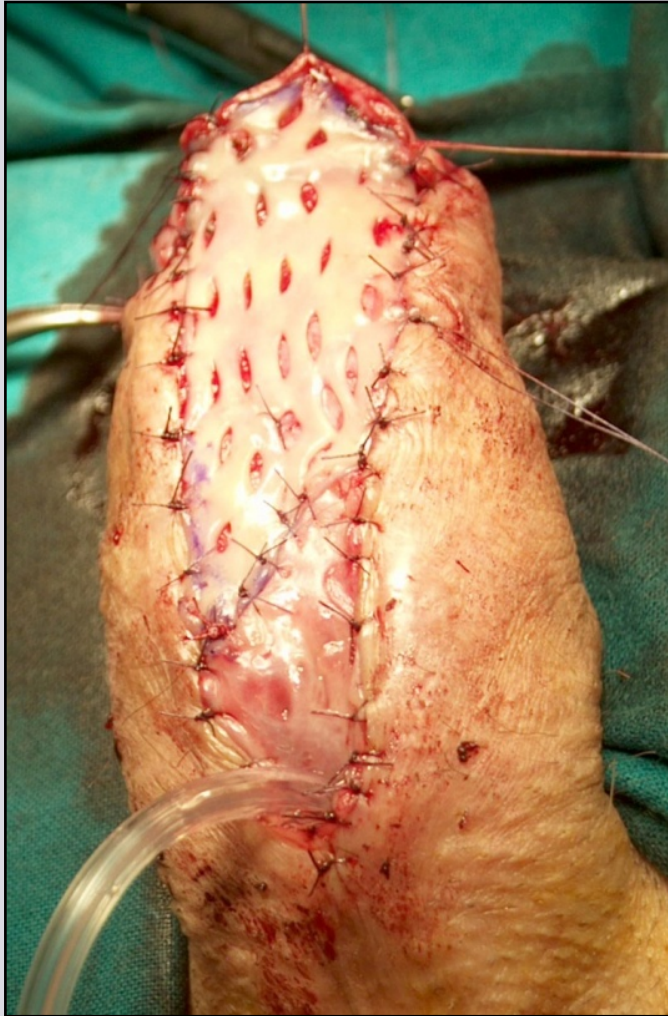Staged repair





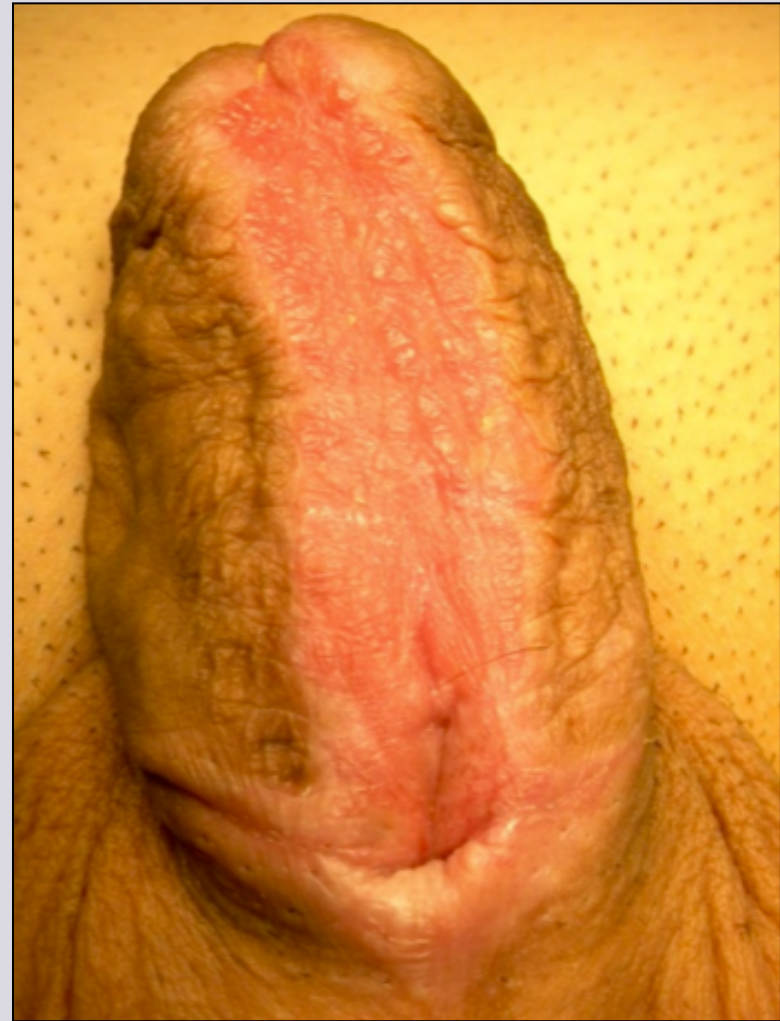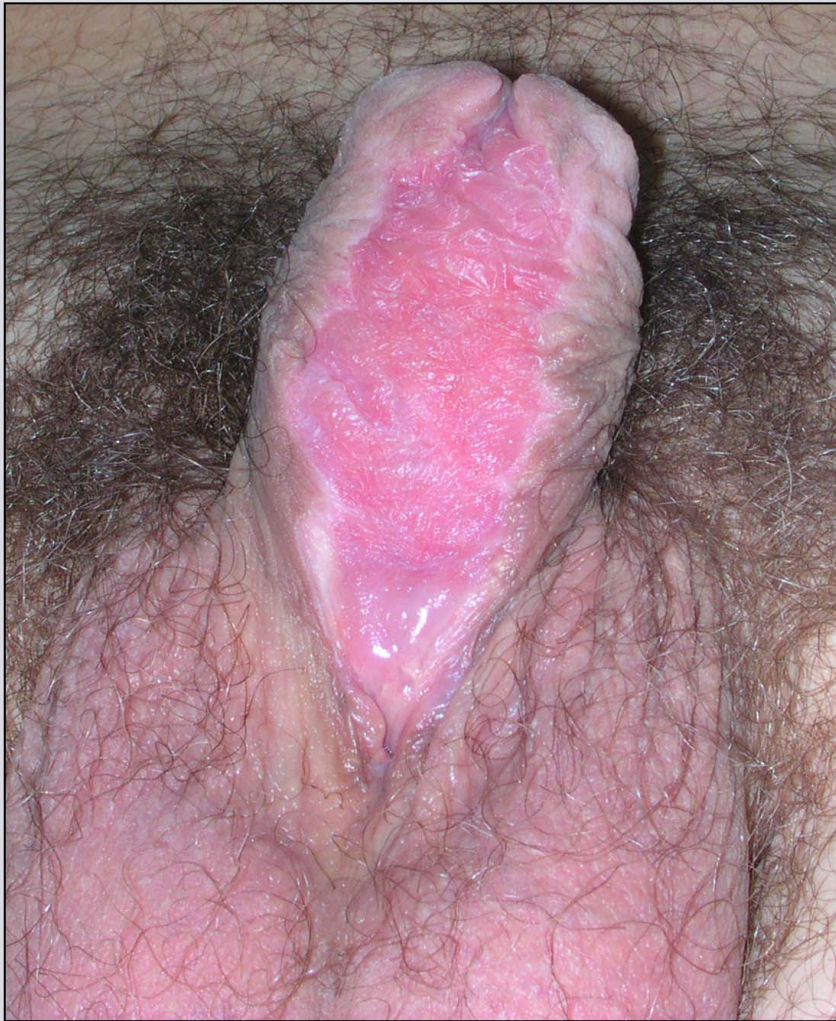e-mail: info@urethralcenter.it

Websites: www.uretra.it
www.urethralcenter.it



e-mail: info@urethralcenter.it

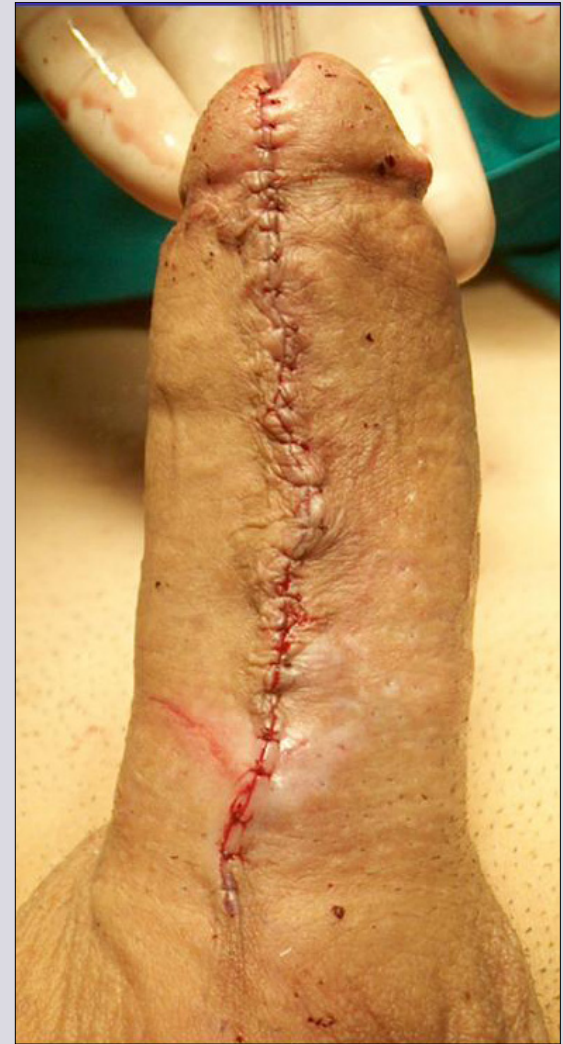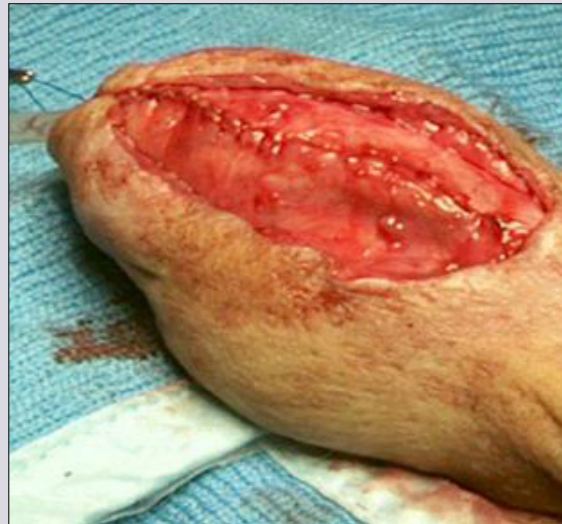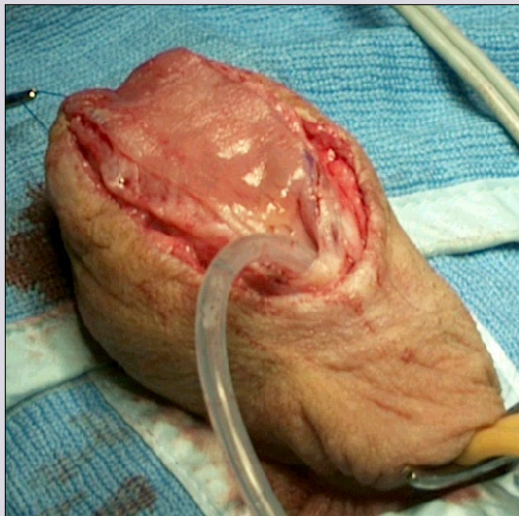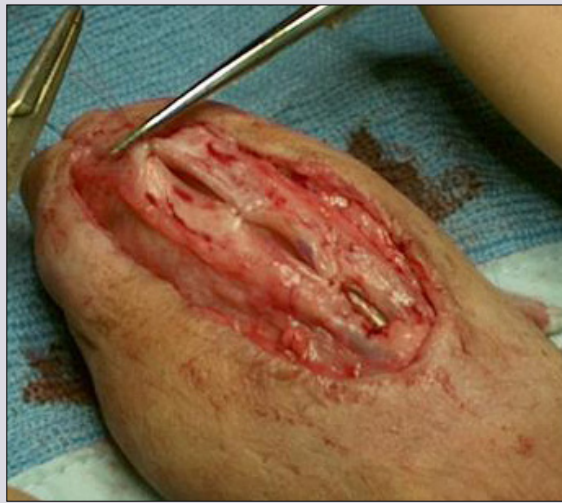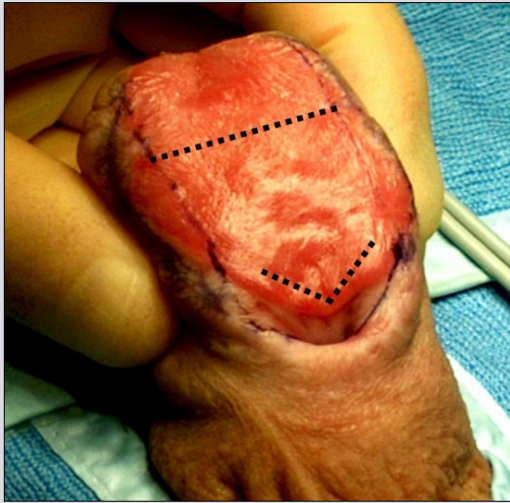Websites: www.uretra.it
www.urethralcenter.it



e-mail: info@urethralcenter.it

Websites: www.uretra.it
www.urethralcenter.it

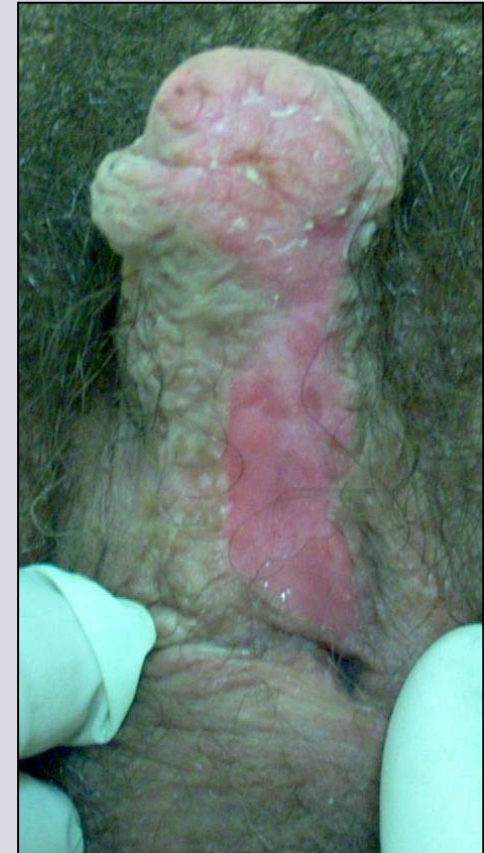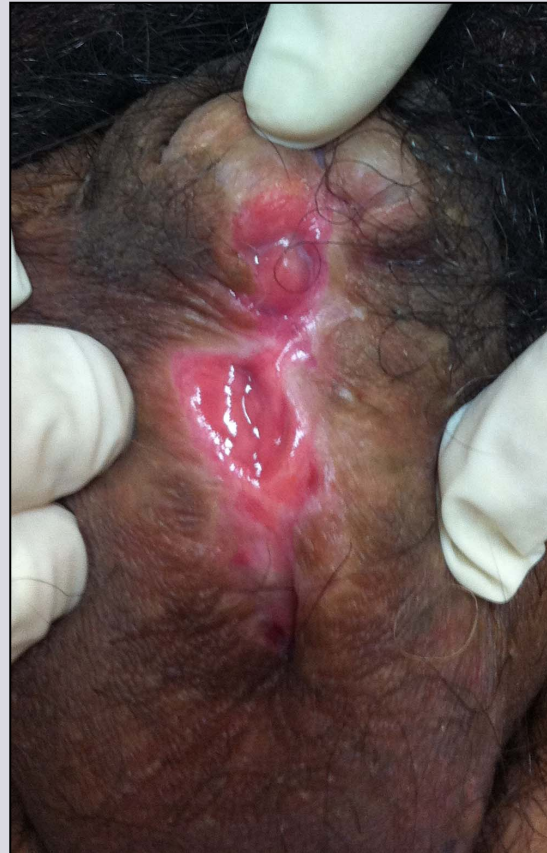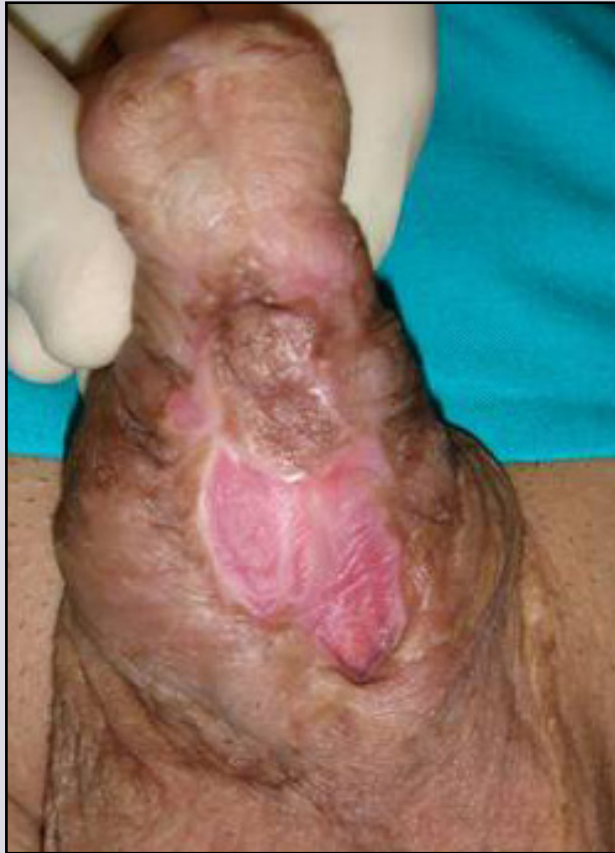Second stage



e-mail: info@urethralcenter.it

Websites: www.uretra.it
www.urethralcenter.it

**39% of patients require new surgical revision
of the grafted area**

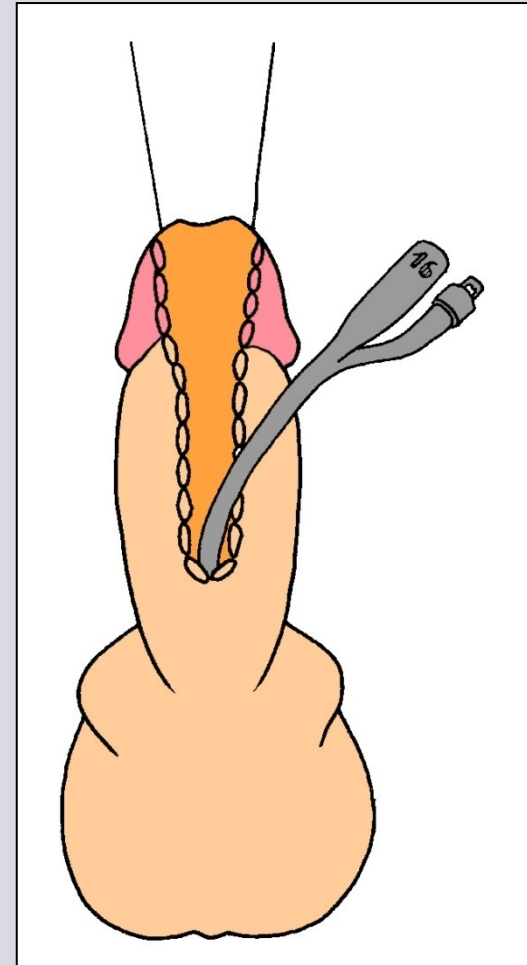
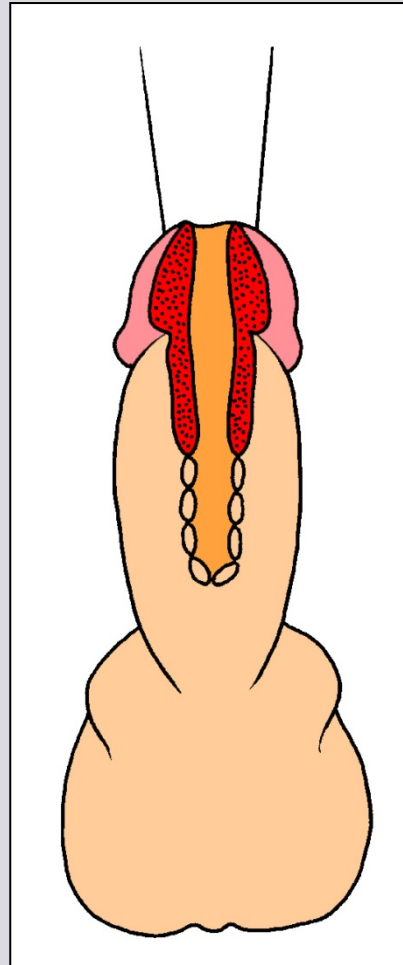
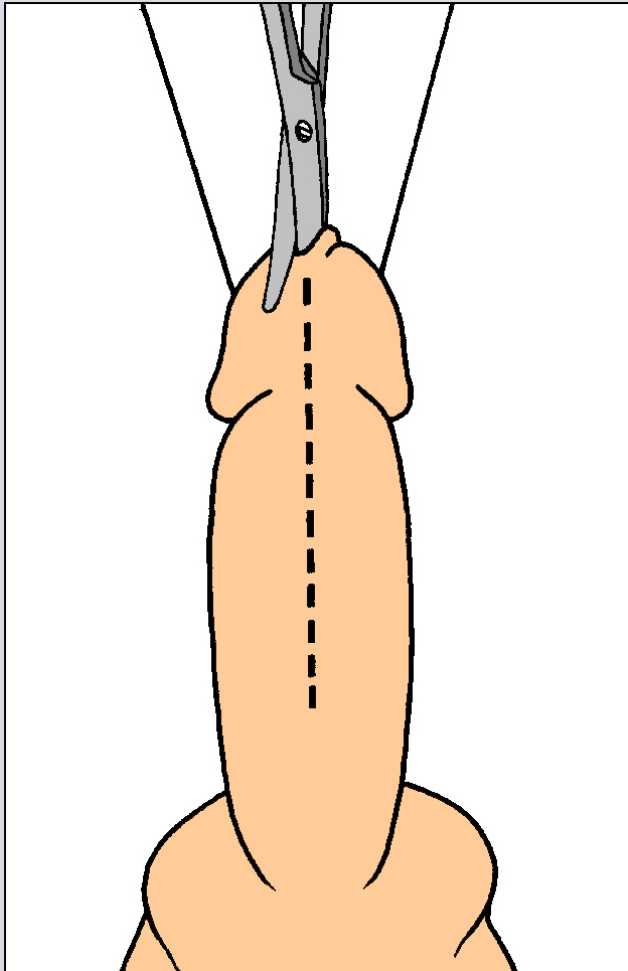


Eur Urol 2006; 49: 887-895

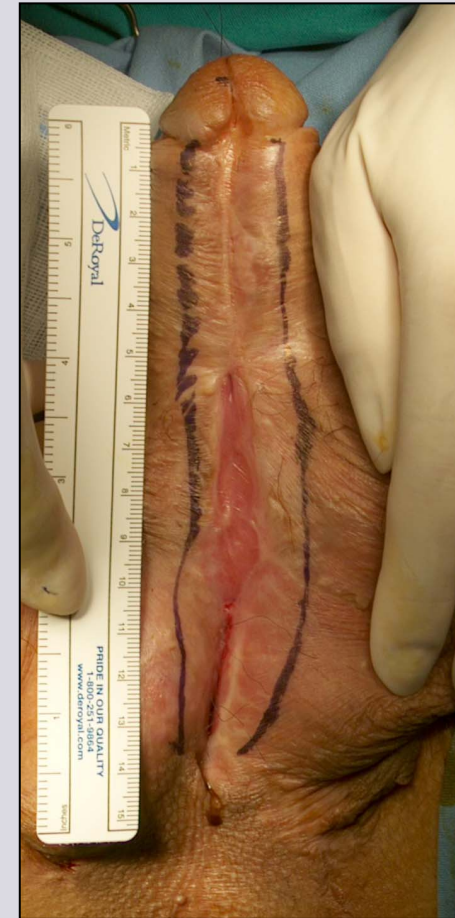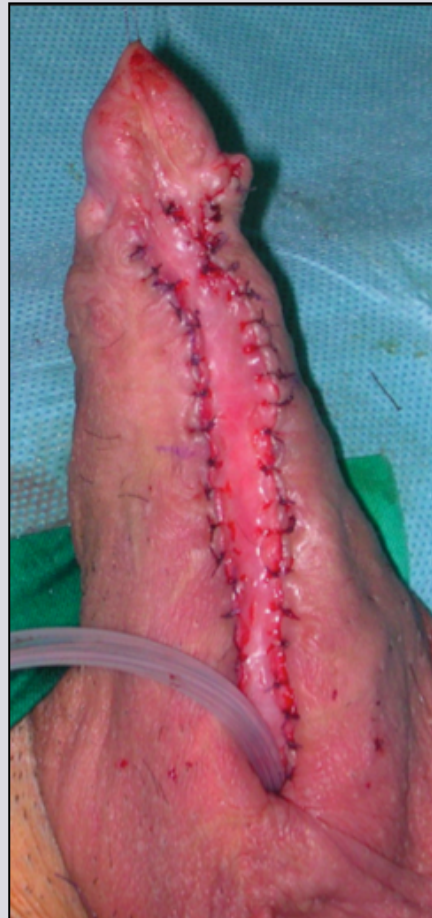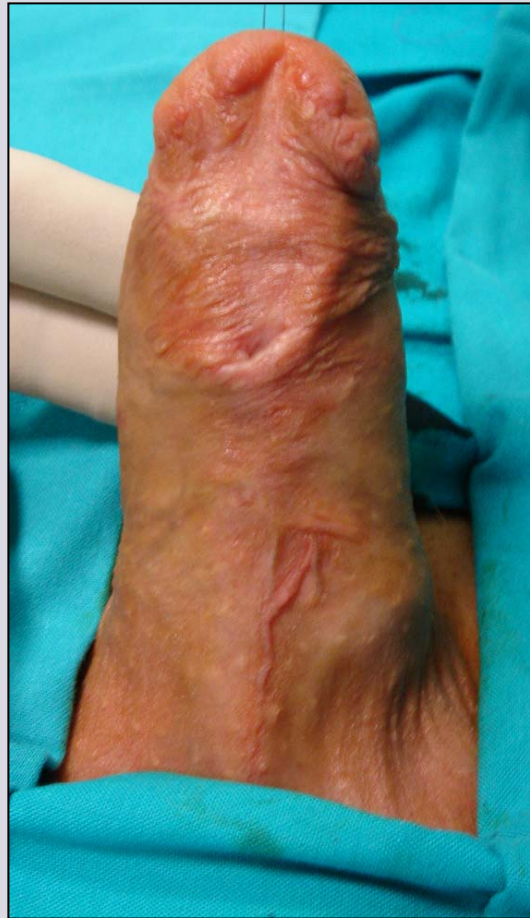e-mail: info@urethralcenter.it

Websites: www.uretra.it
www.urethralcenter.it

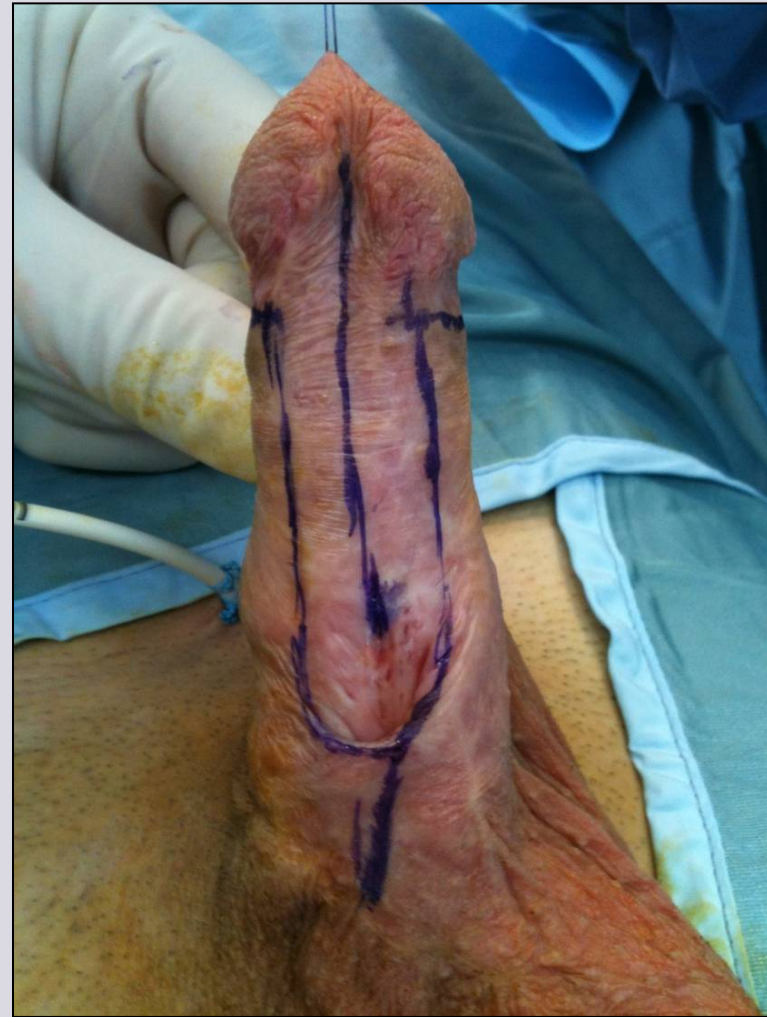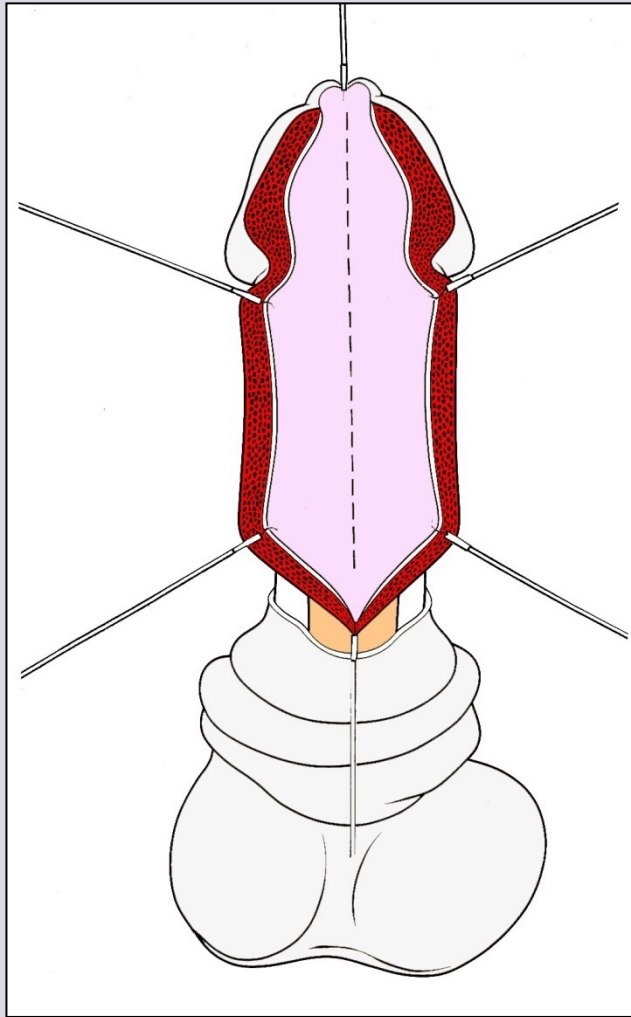
First stage – Johanson's urethroplasty



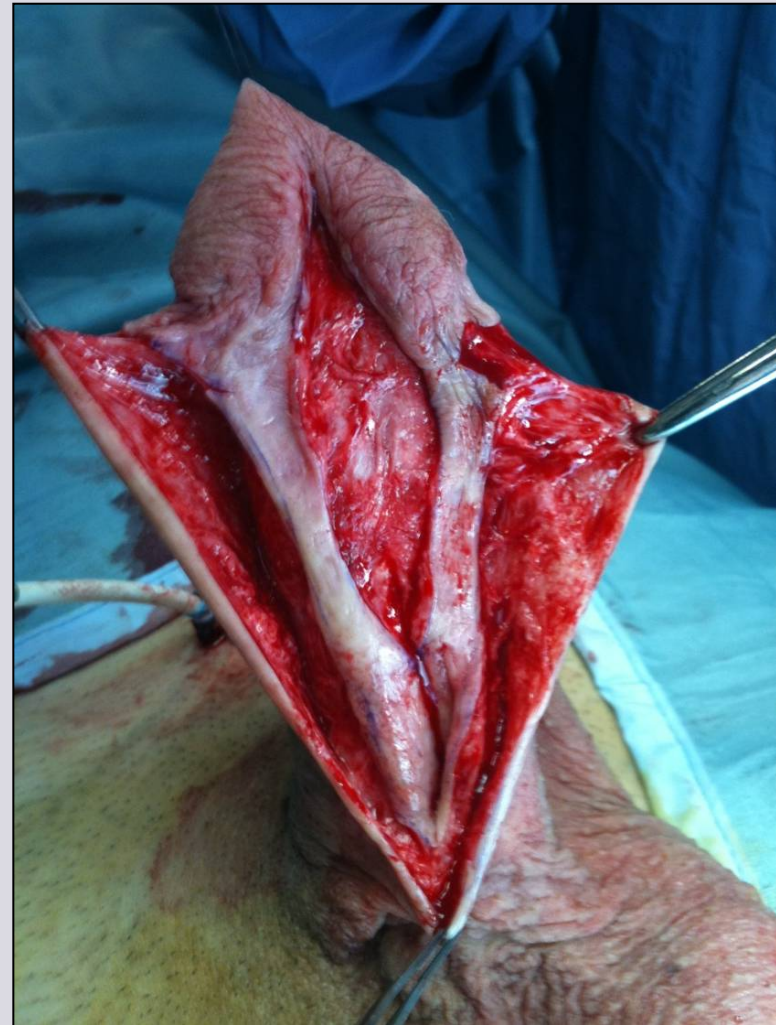
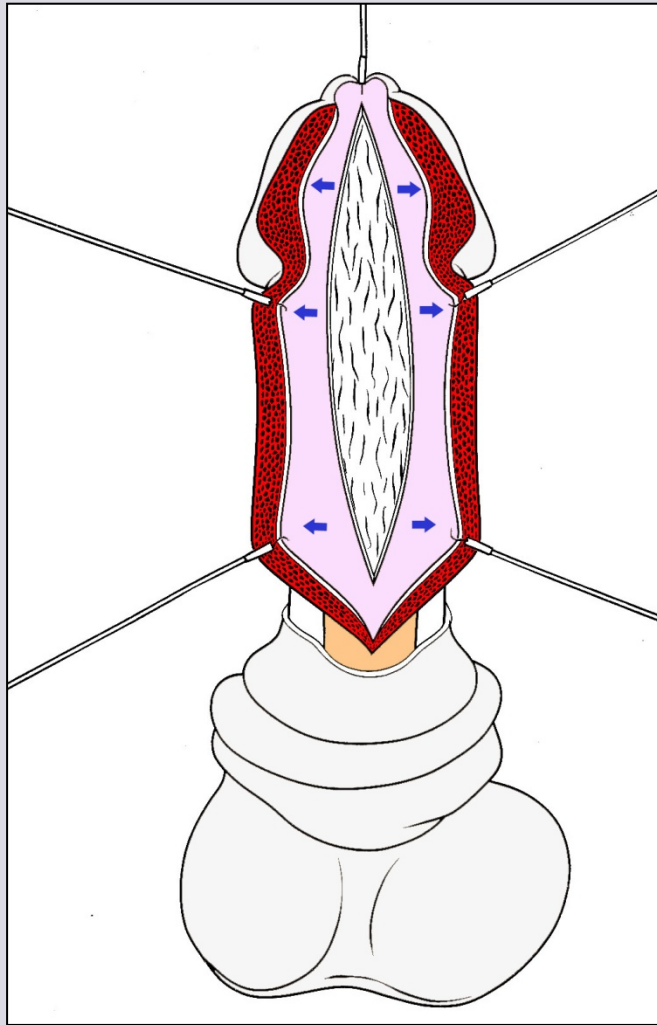
First stage – Johanson's urethroplasty



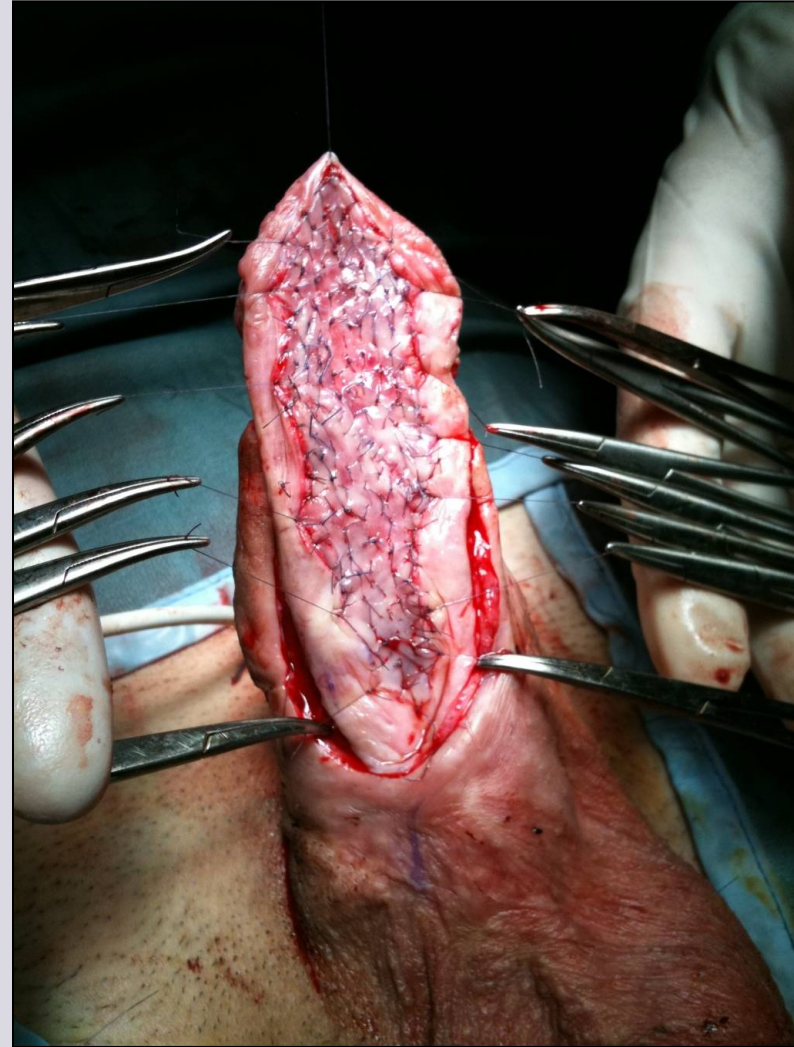
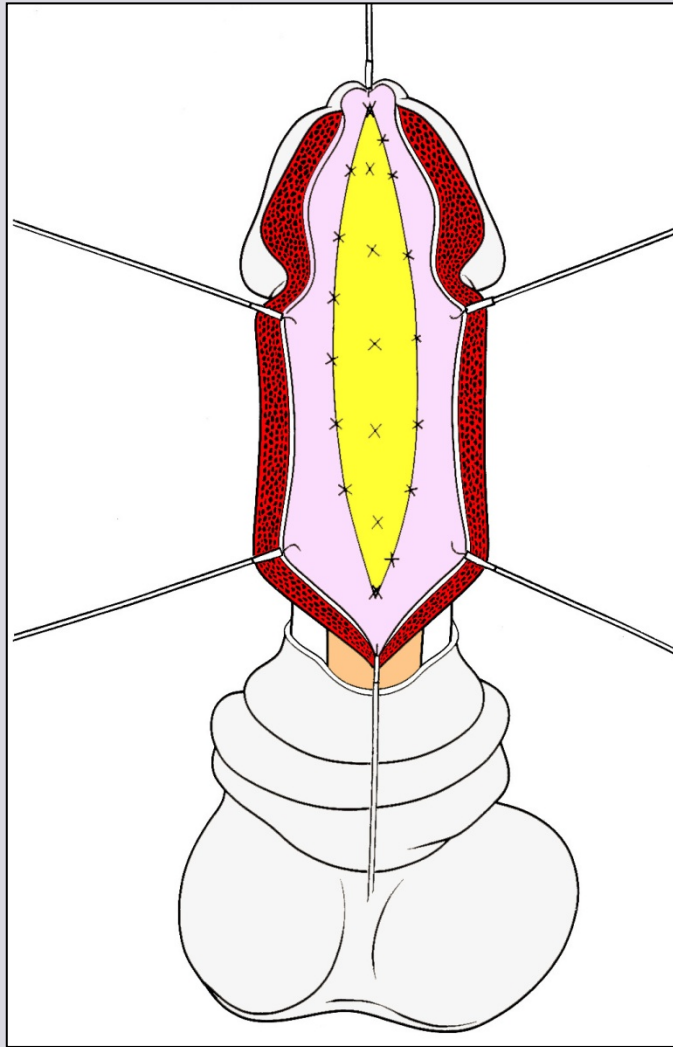
Second stage – Oral graft inlay urethroplasty



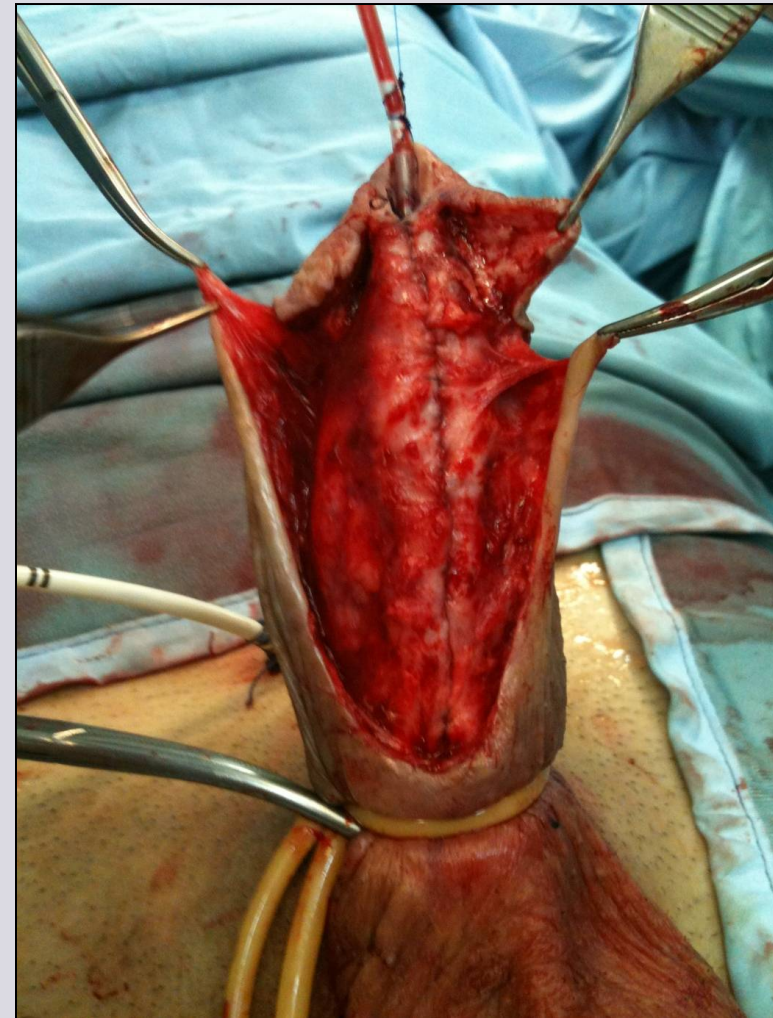
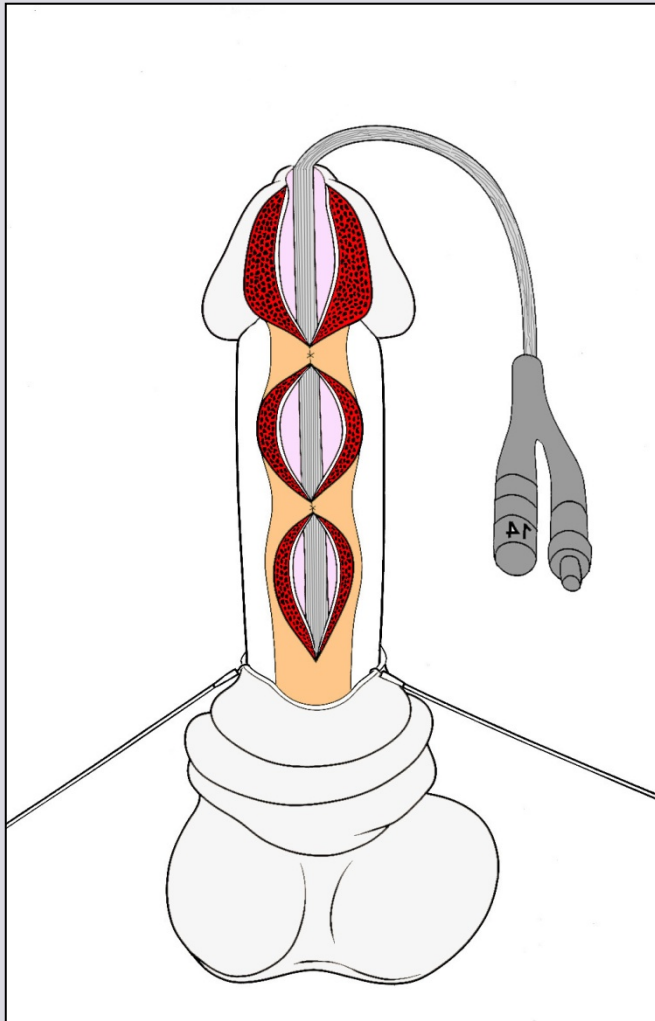
Second stage – Oral graft inlay urethroplasty



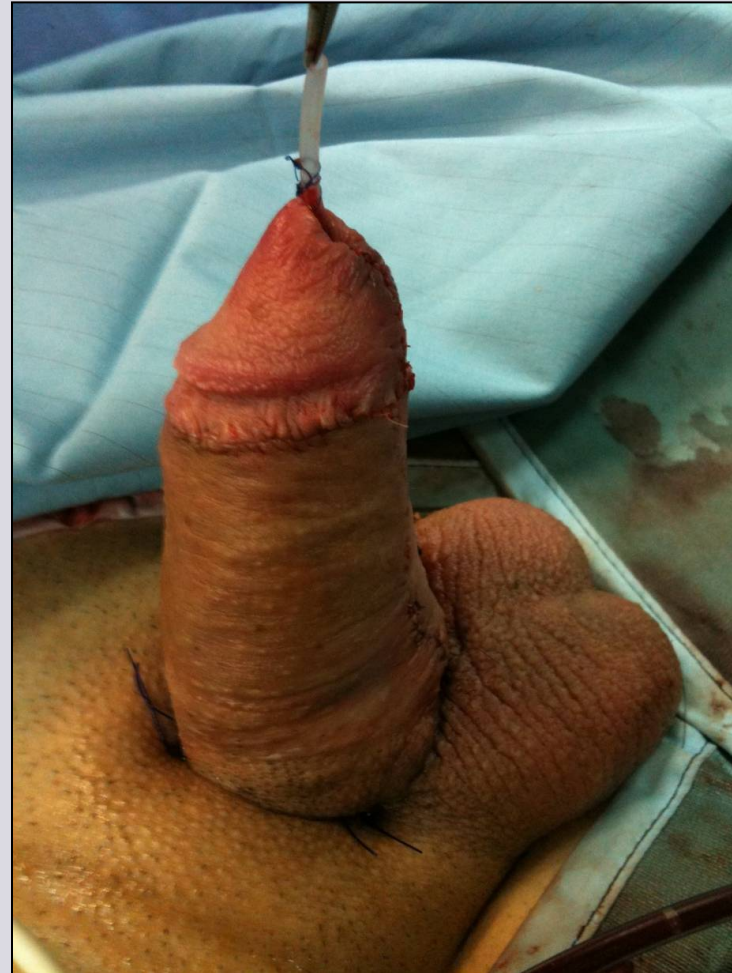
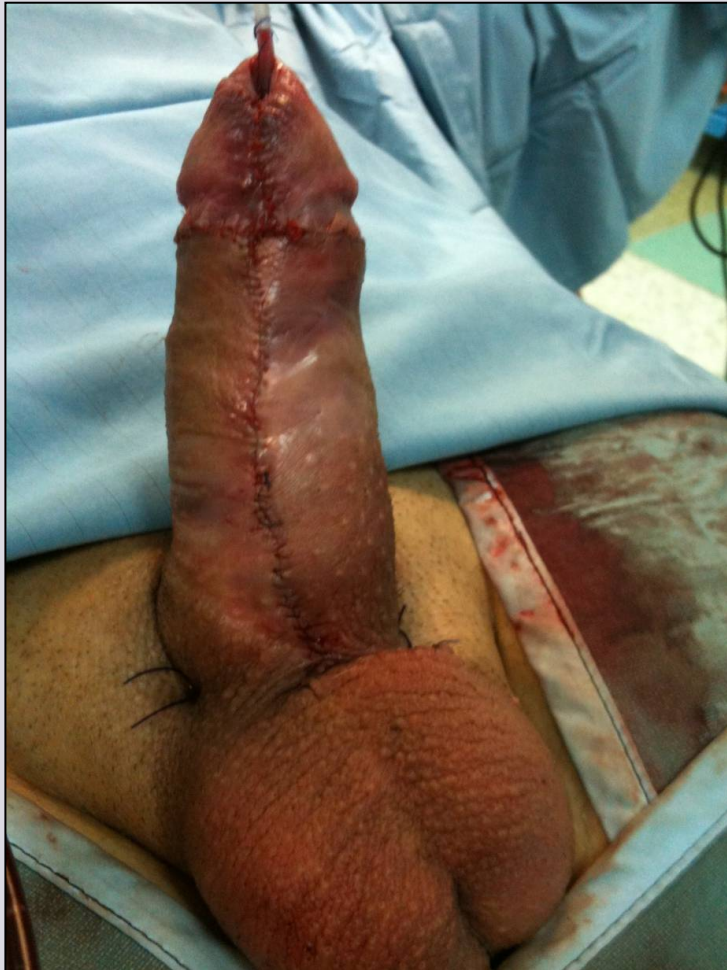Second stage – Oral graft inlay urethroplasty

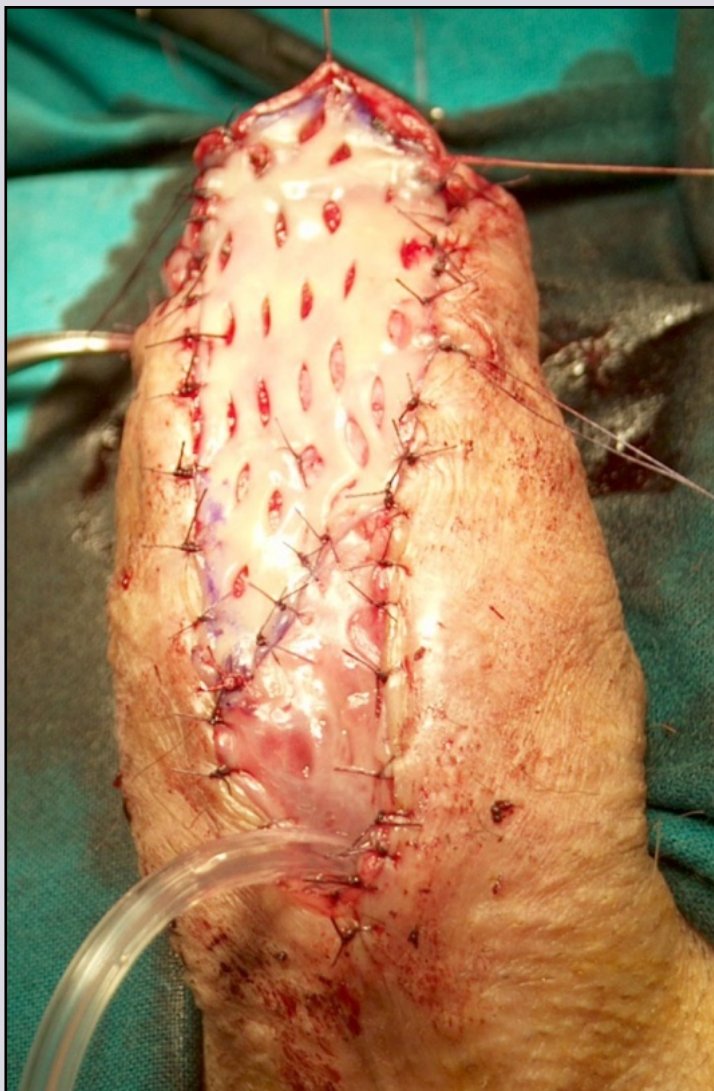

Second stage – Oral graft inlay urethroplasty



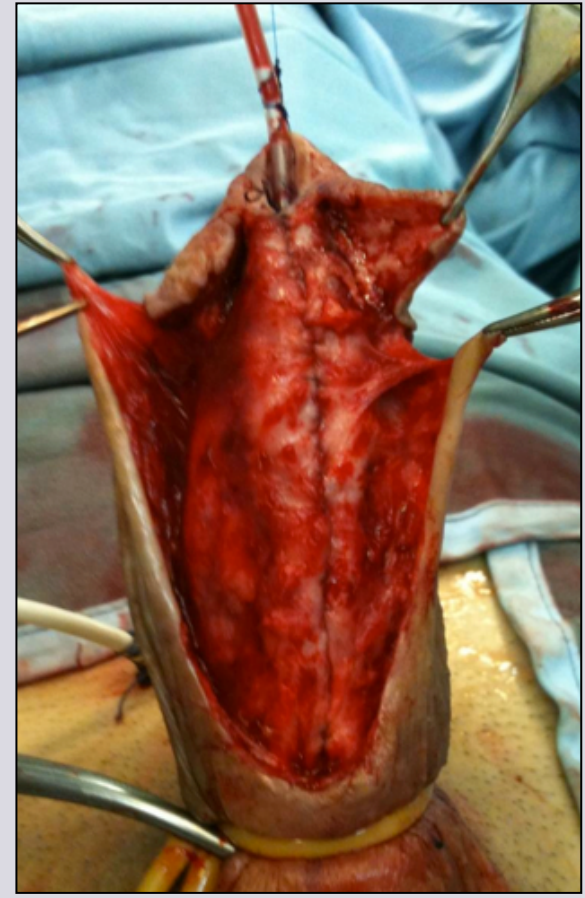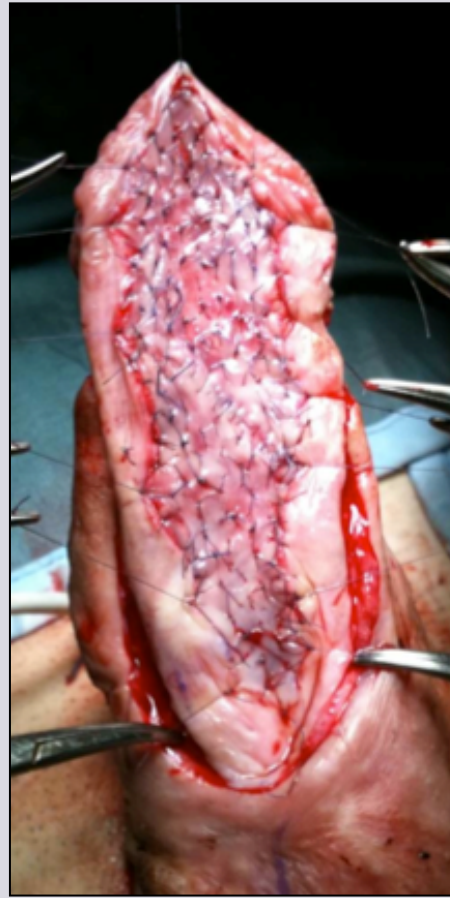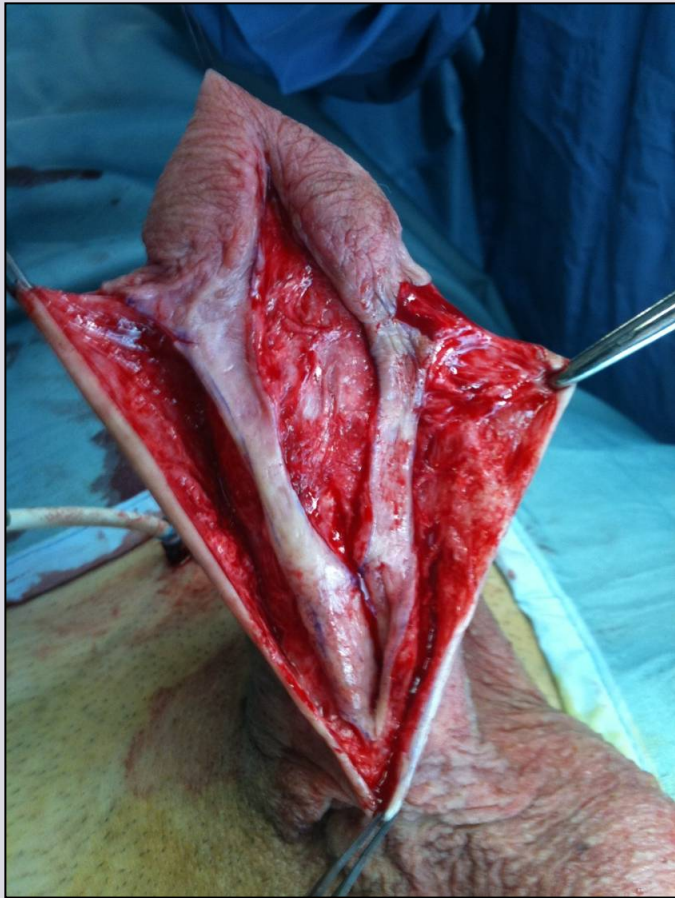
Second stage – Oral graft inlay urethroplasty





e-mail: info@urethralcenter.it

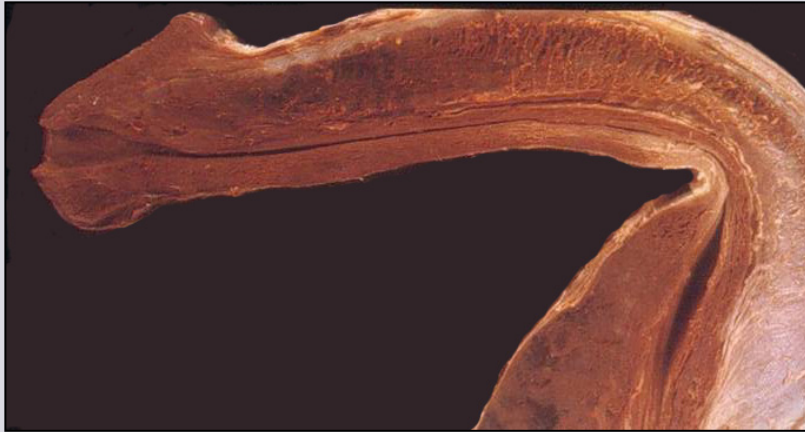
Websites: www.uretra.it
www.urethralcenter.it



e-mail: info@urethralcenter.it

Websites: www.uretra.it
www.urethralcenter.it

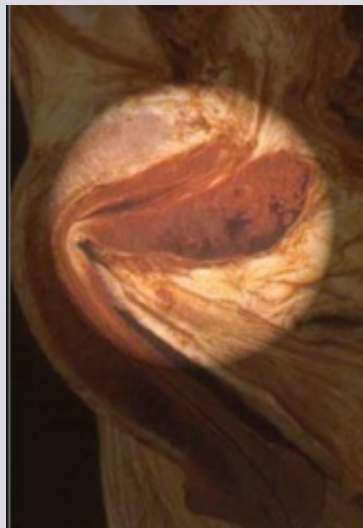
New classification of anterior urethral strictures



Penile

Simple

Complex

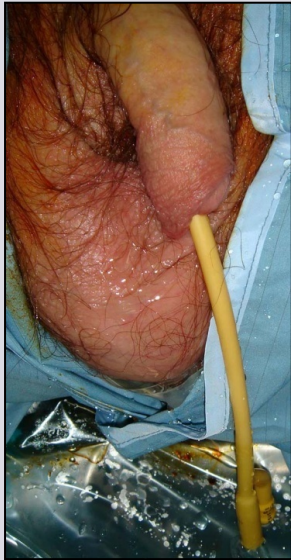

Bulbar

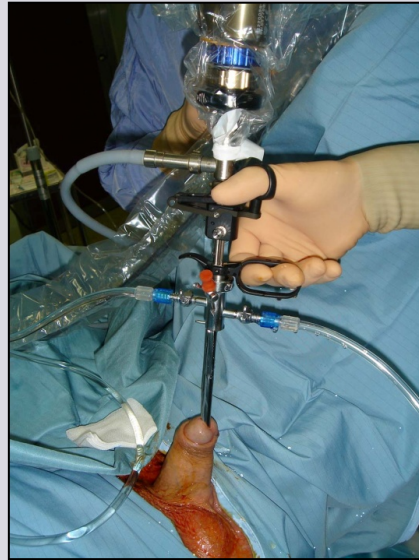Traumatic

Non-traumatic

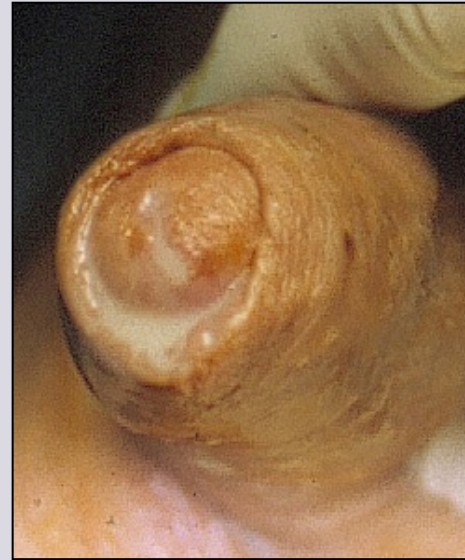Etiology of bulbar urethral stricture



Catheter



Instrumentation



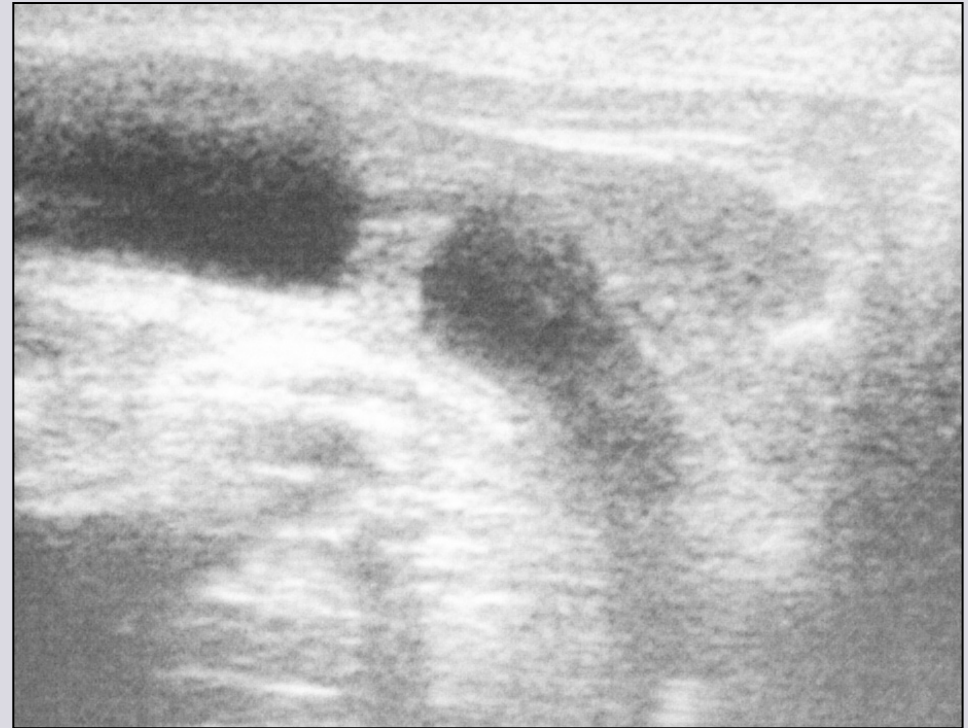
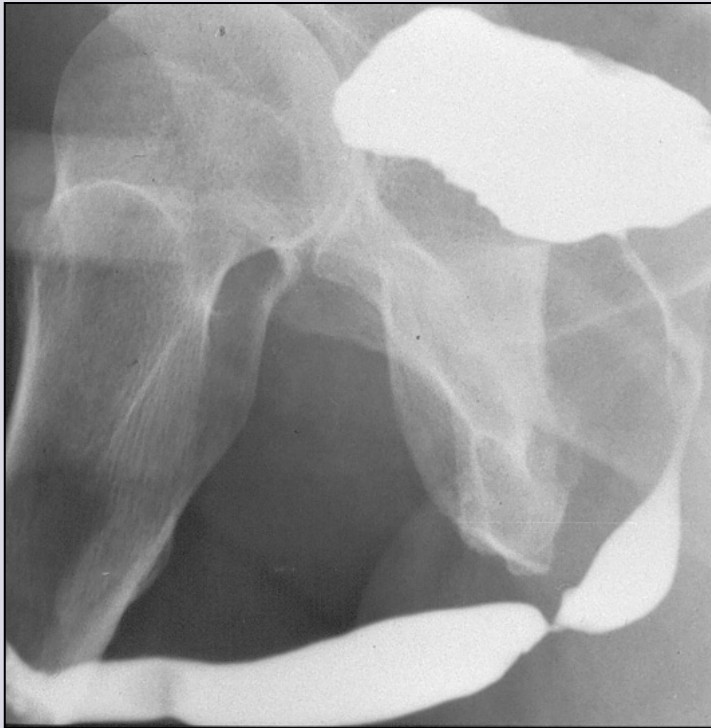
Infection

Idiopathic
Radiotherapy
Other



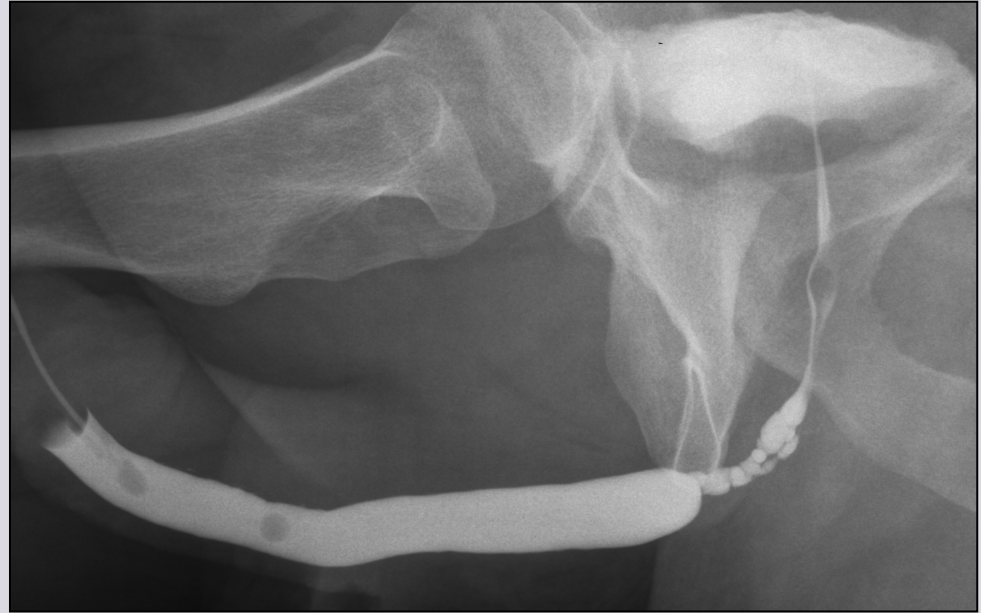
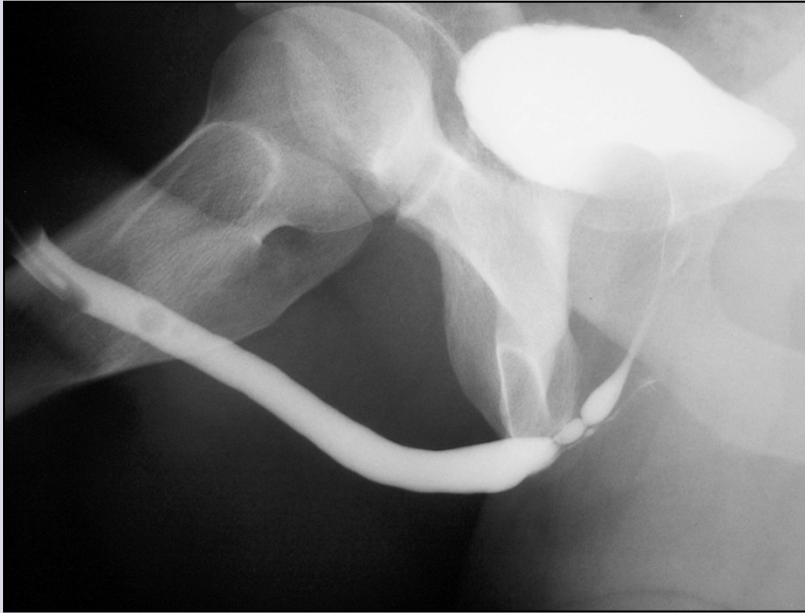
Trauma

Traumatic bulbar urethral stricture



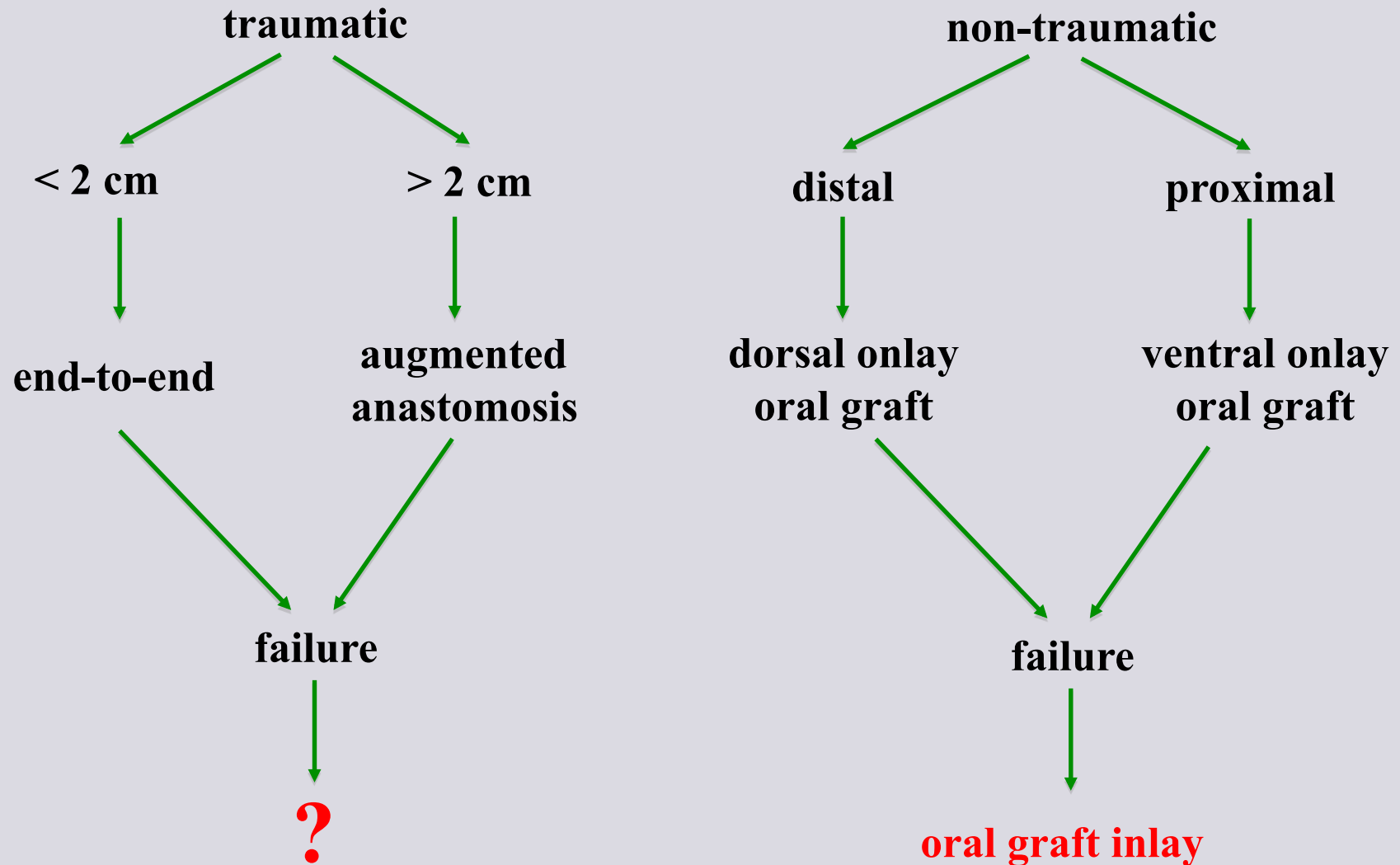
1. Obliterative stricture
2. No practicable urethral plate
3. Scar tissue
4. Short or long fibrous gap

Non-traumatic bulbar urethral stricture



1. Etiology: idiopathic – catheter - instrumentation –infection – other
2. Practicable urethral plate (3 Fr. Sensor guidewire)
3. No fibrous gap

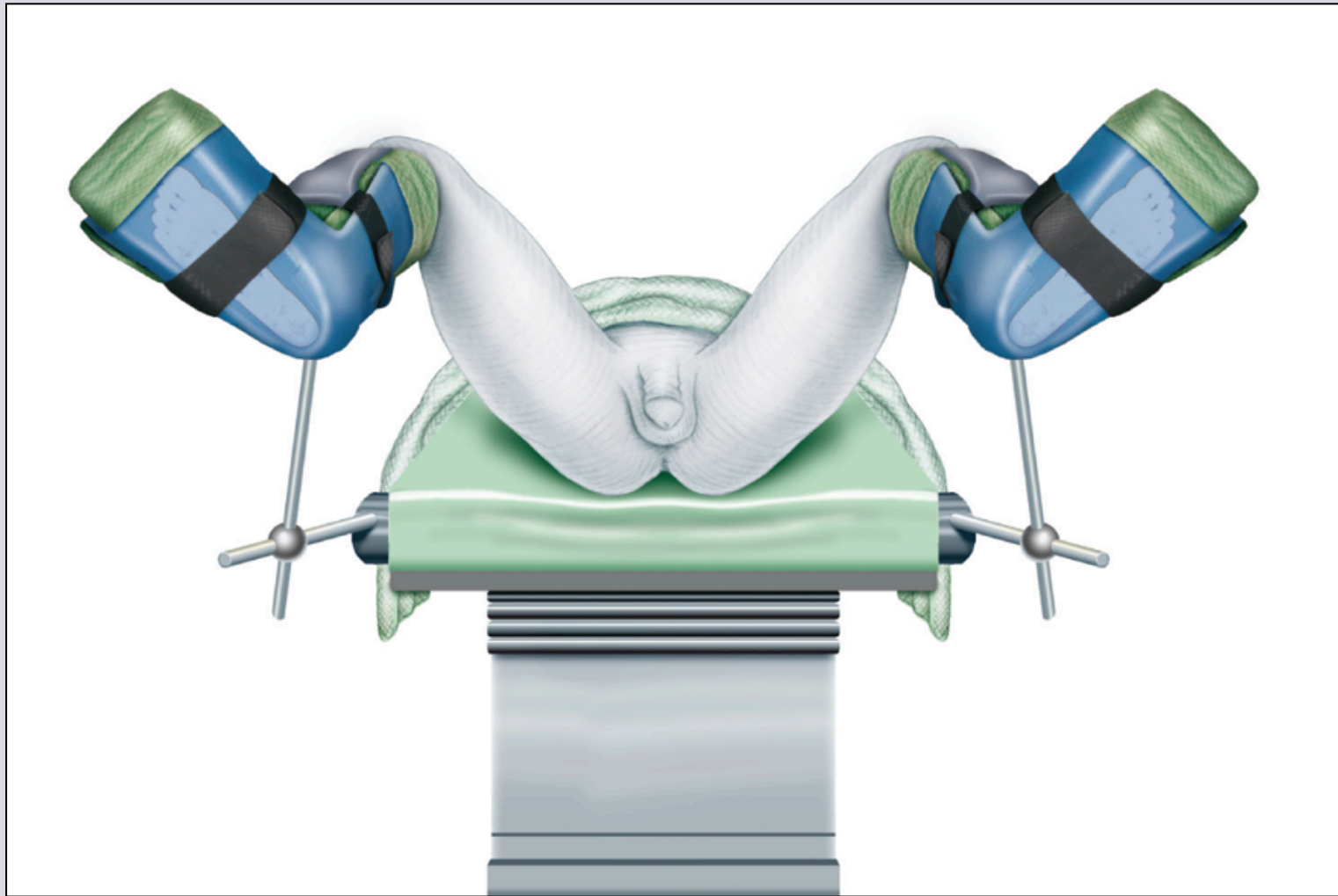
Bulbar urethral stricture



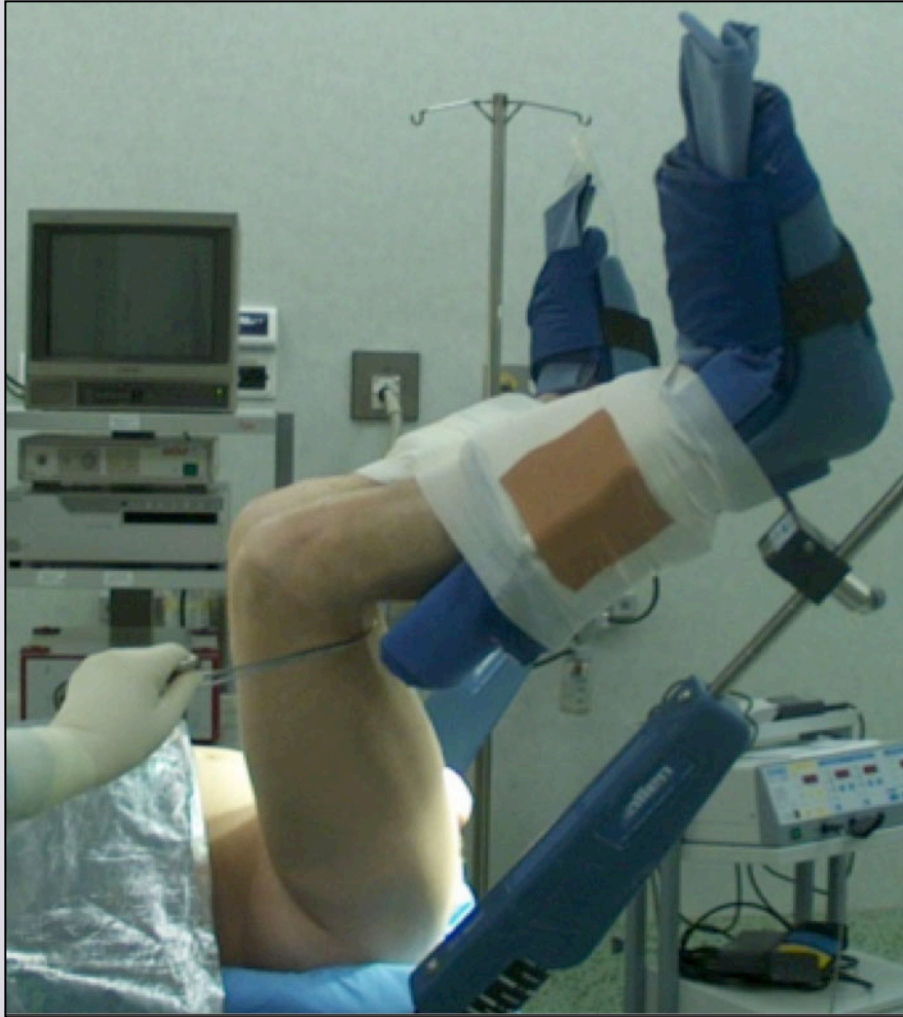Reconstruction of the bulbar urethra in traumatic stricture

e-mail: info@urethralcenter.it

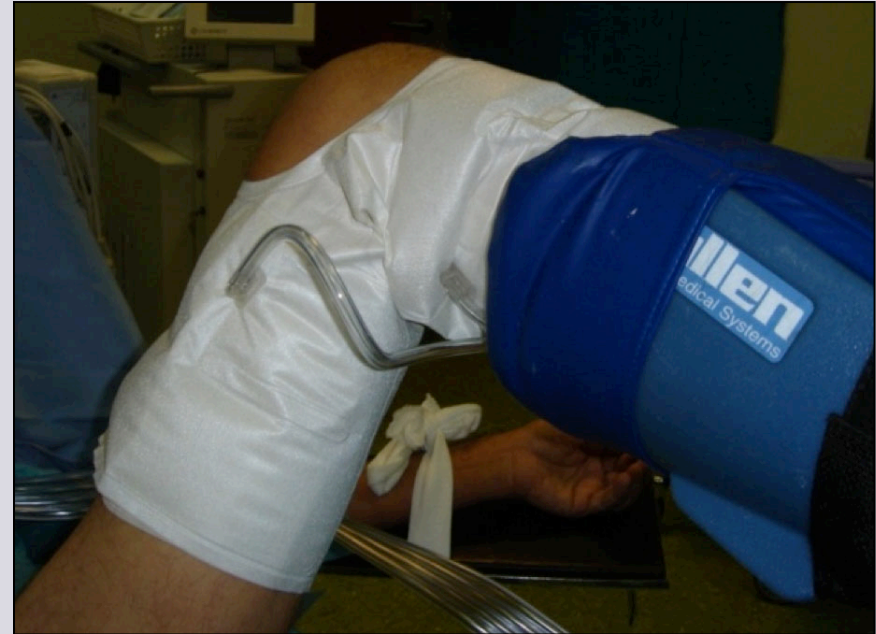Websites: www.uretra.it
www.urethralcenter.it



Simple lithotomy position

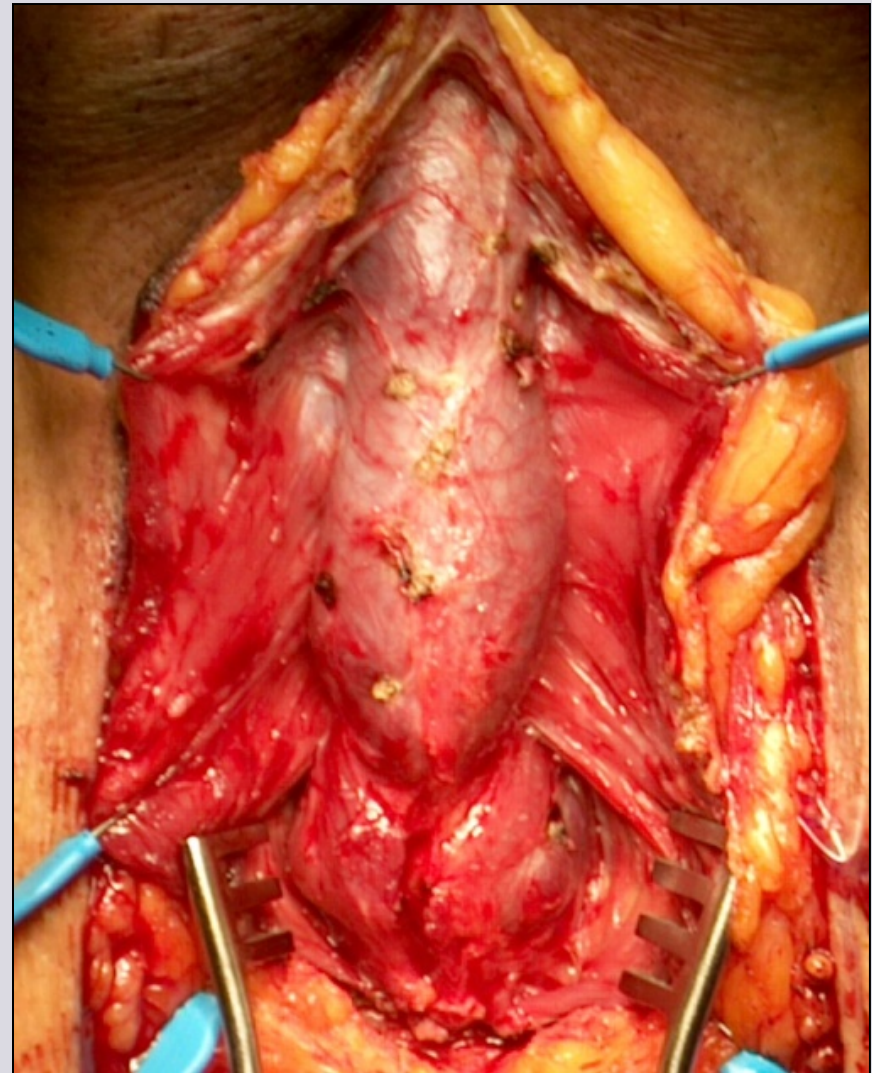
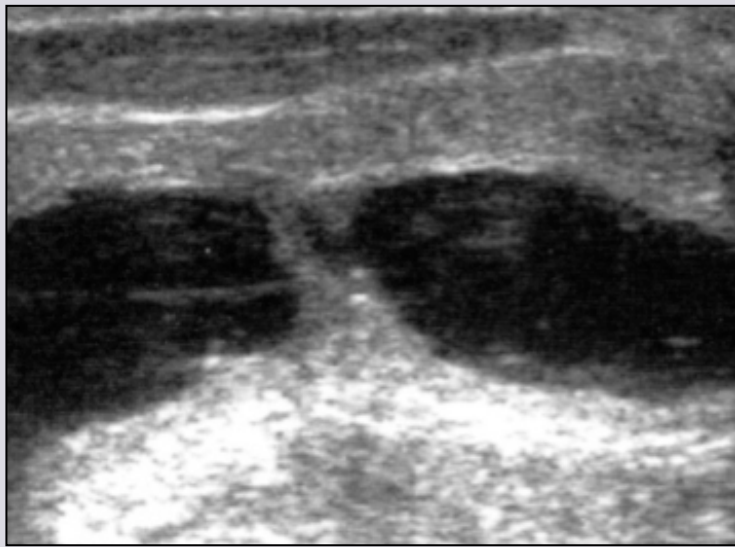
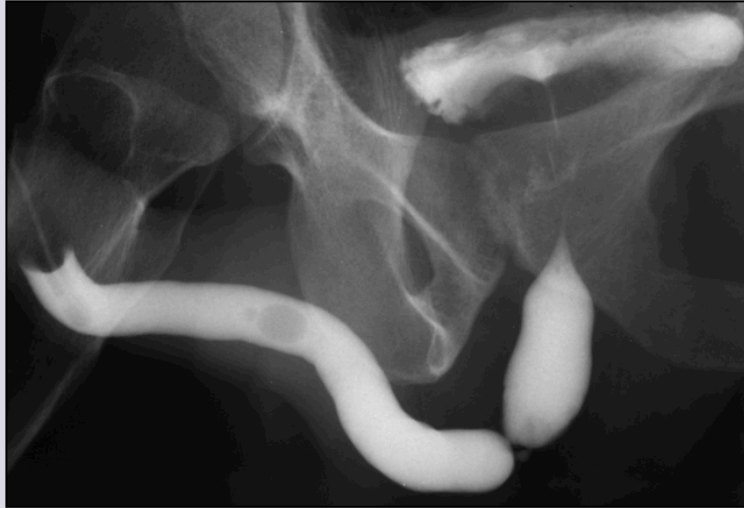

Allen stirrups



**Sequential inflatable
compression sleeves**

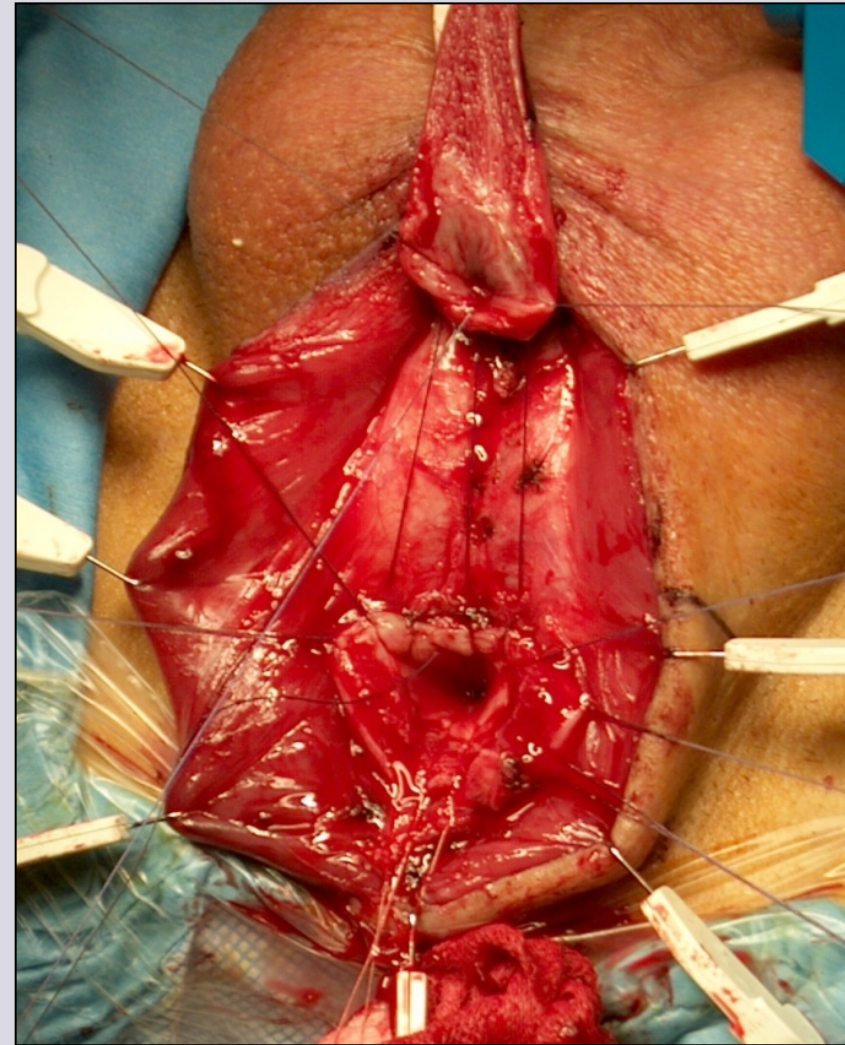
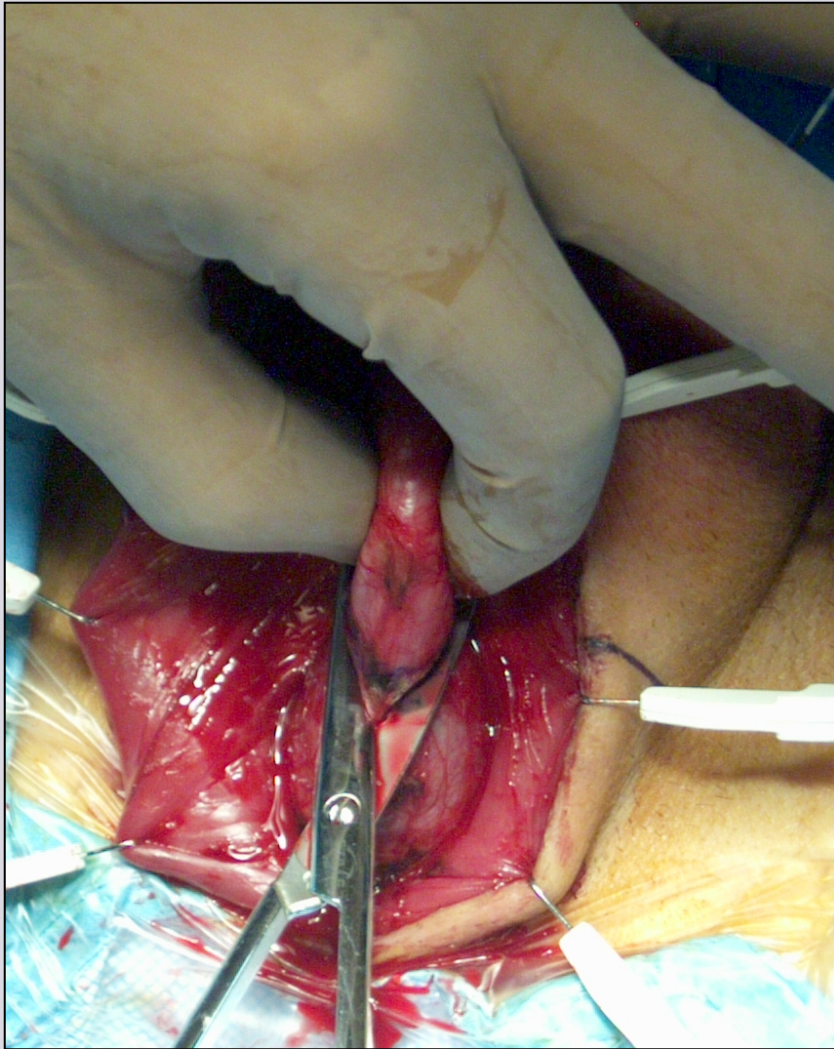
1 - 2 cm traumatic bulbar urethral stricture

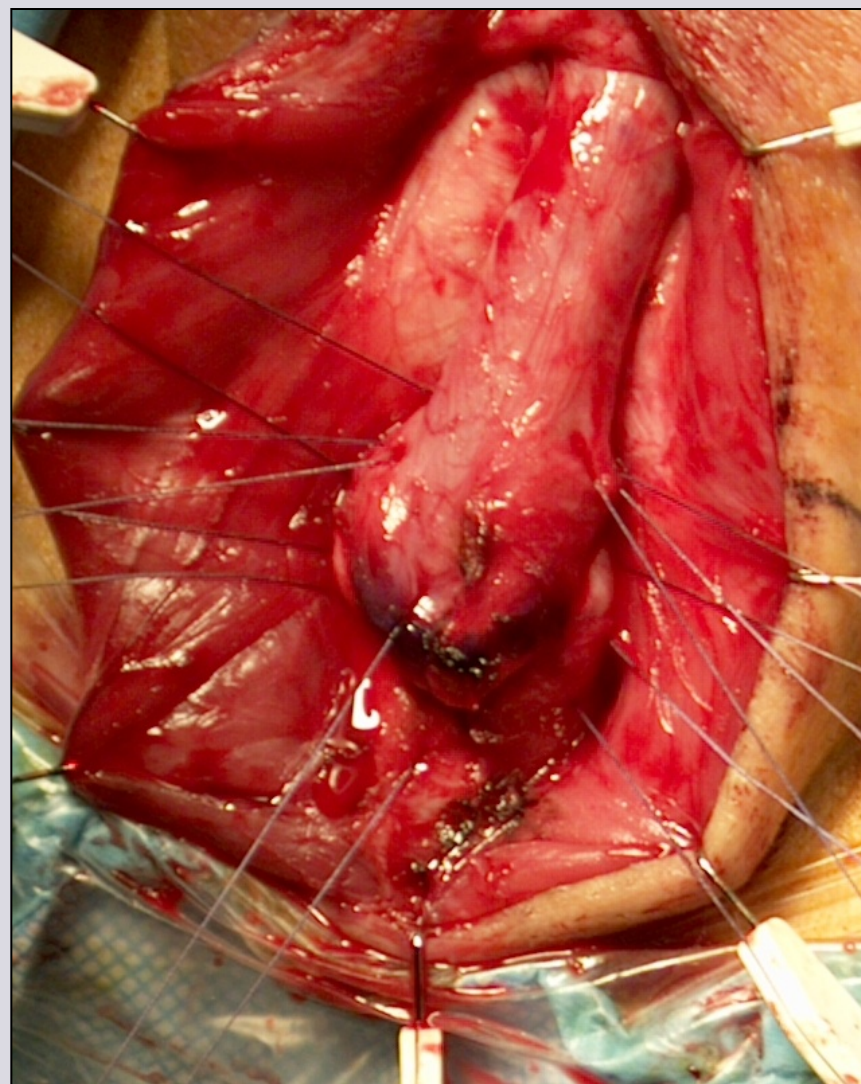
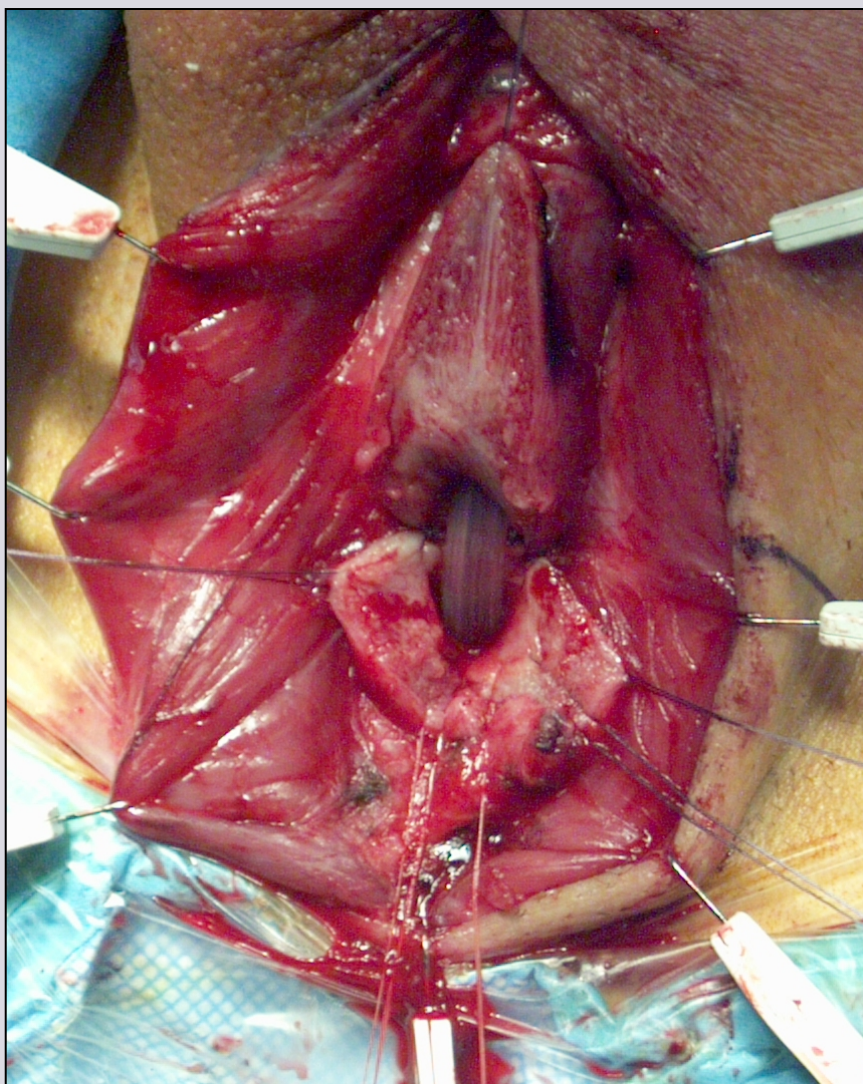


e-mail: info@urethralcenter.it

Websites: www.uretra.it
www.urethralcenter.it

End-to-end anastomosis

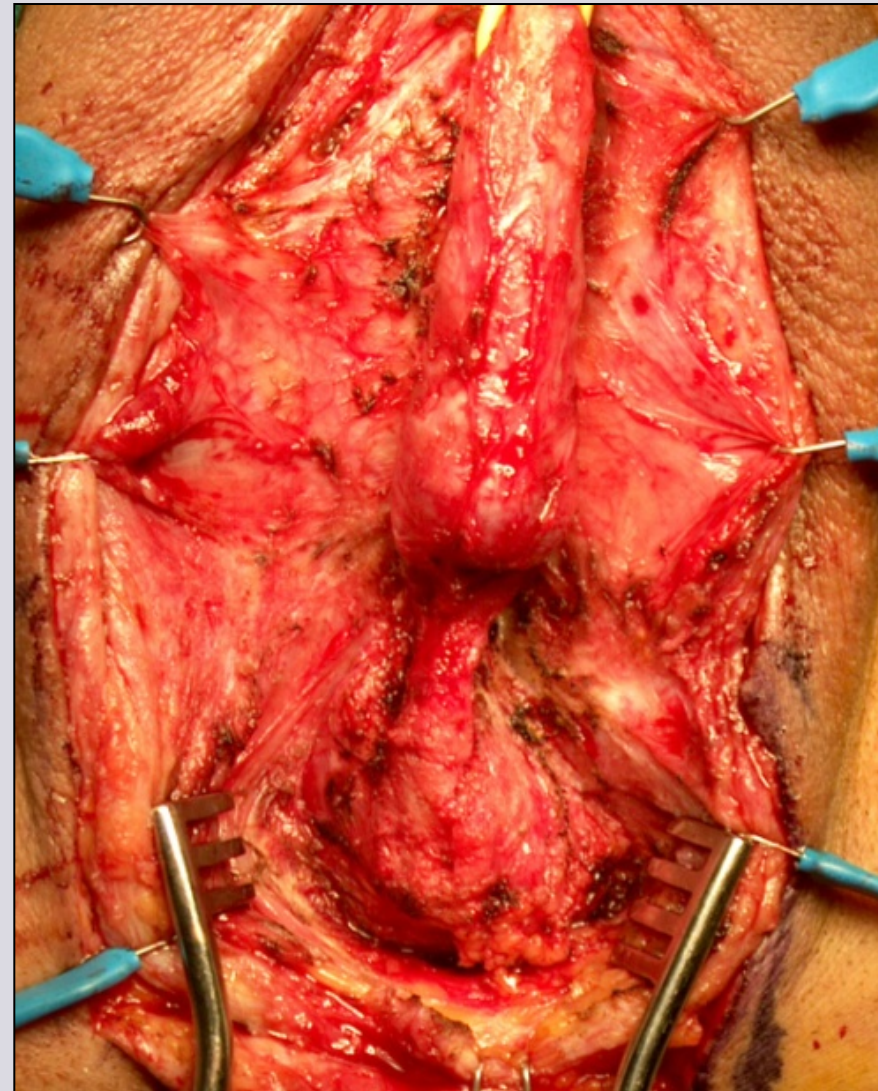
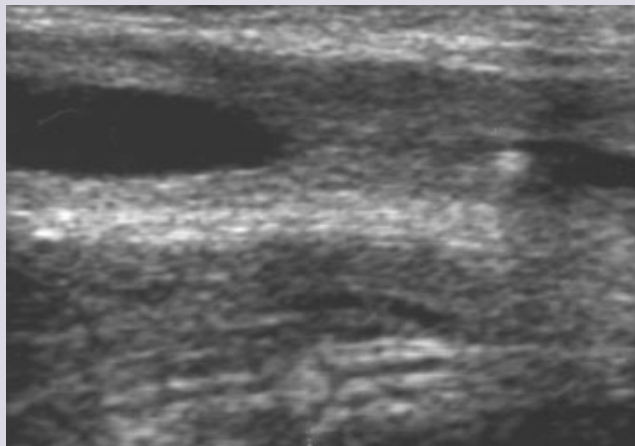
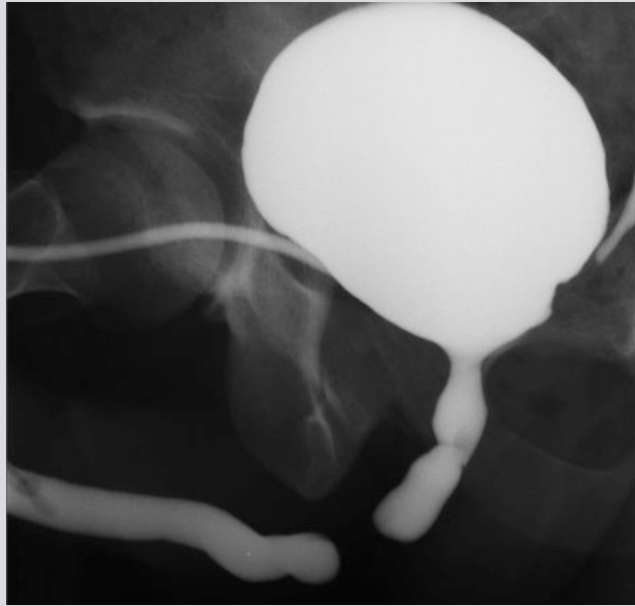




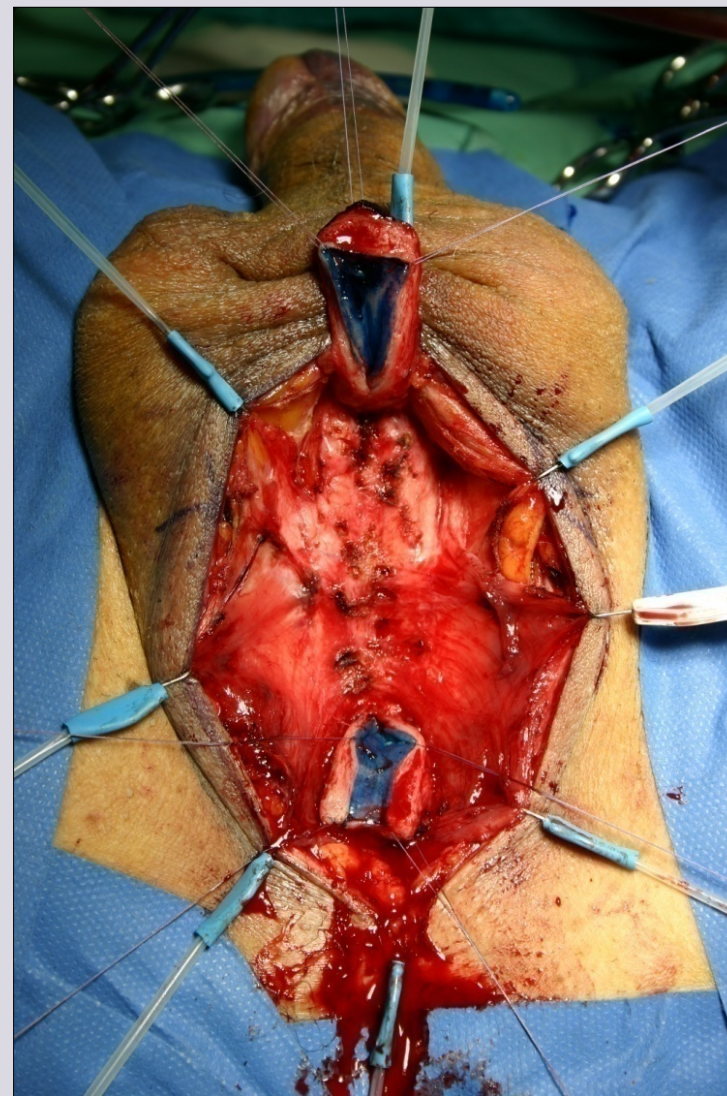
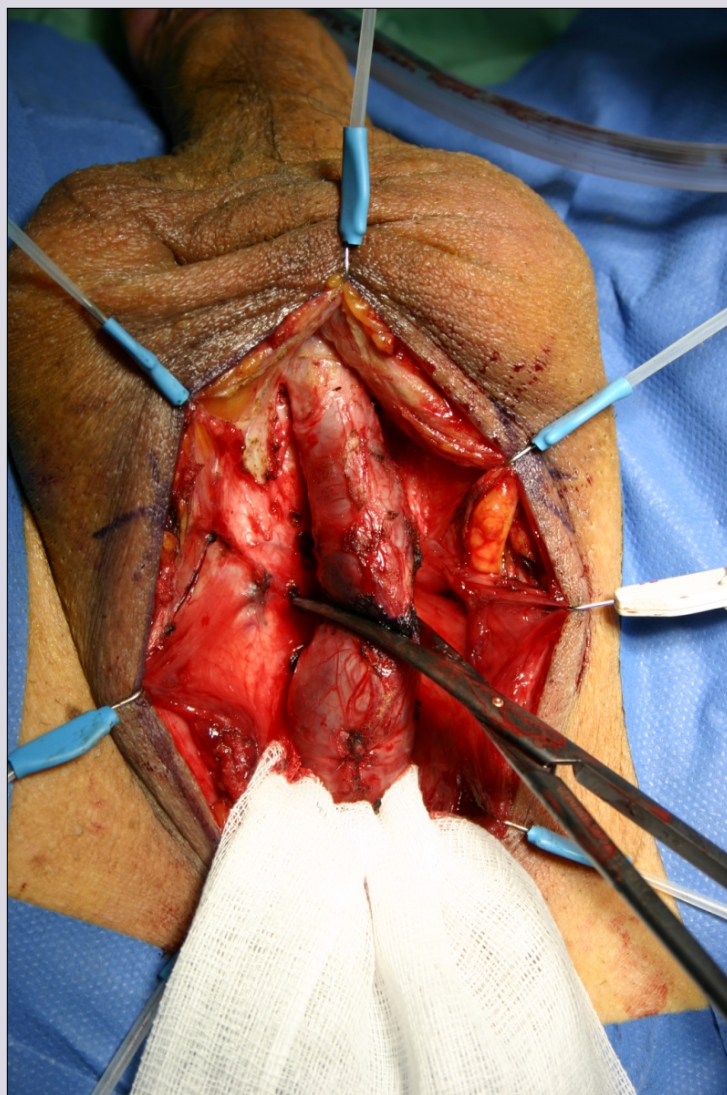
e-mail: info@urethralcenter.it

Websites: www.uretra.it
www.urethralcenter.it

2 - 4 cm traumatic bulbar urethral stricture

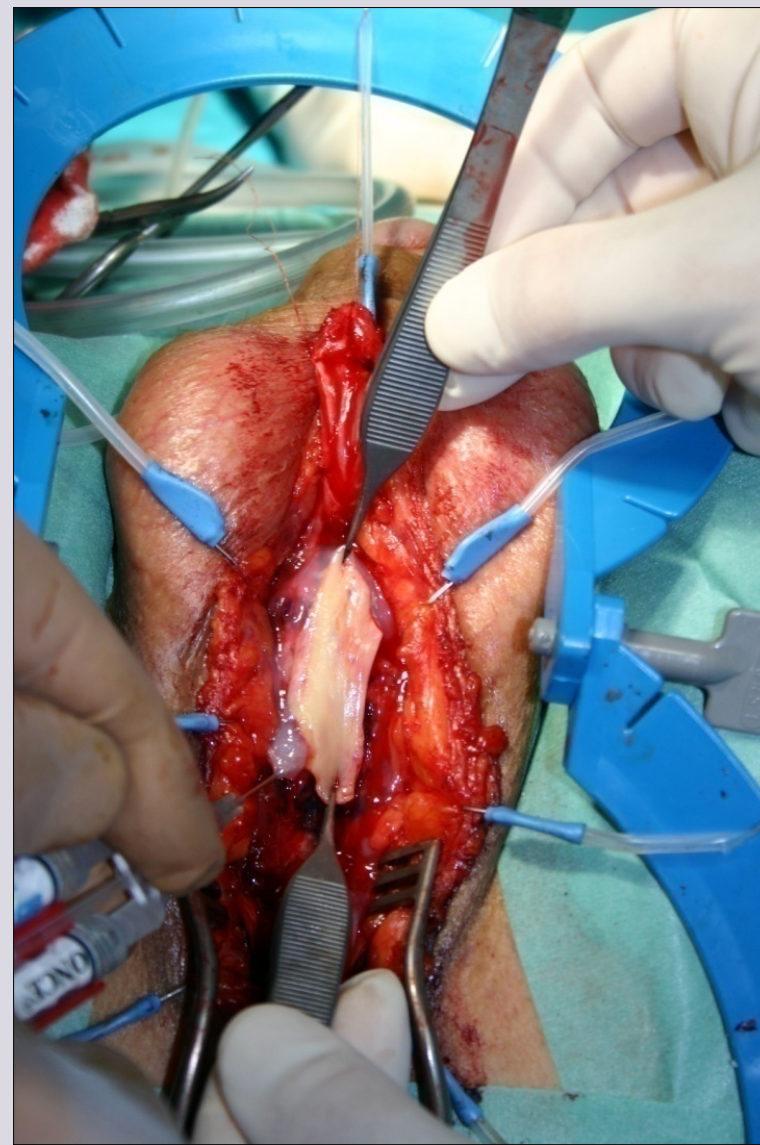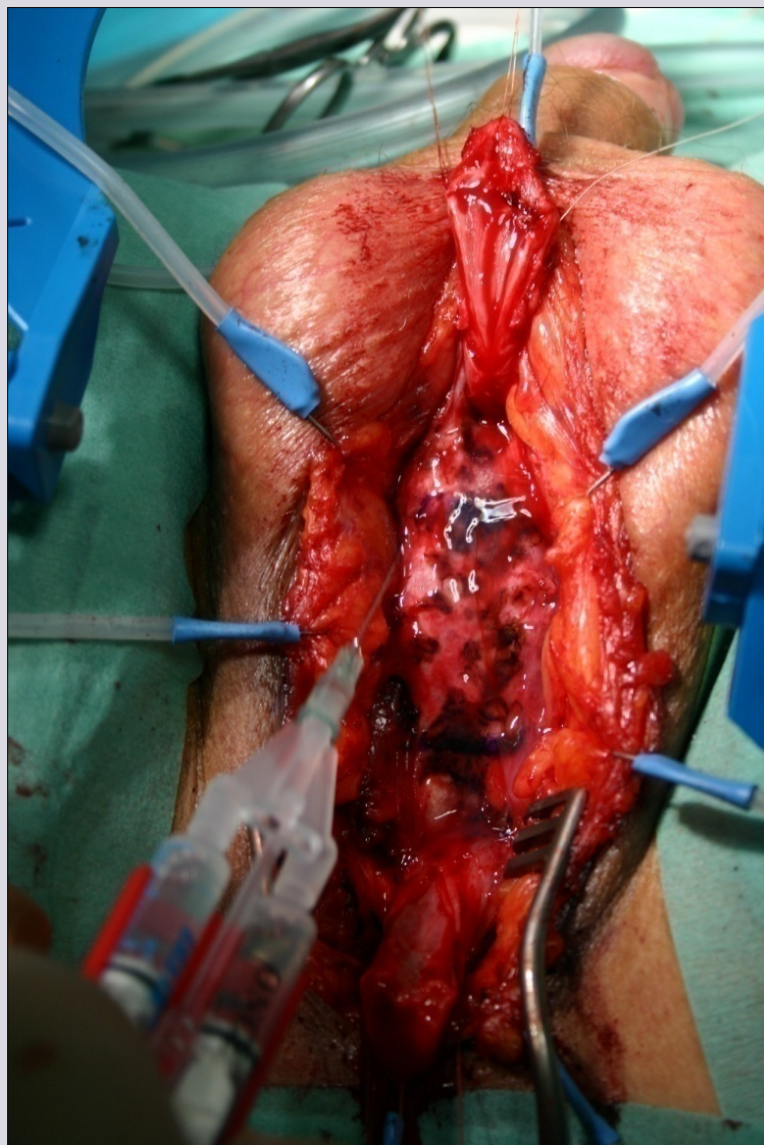


Augmented anastomotic repair



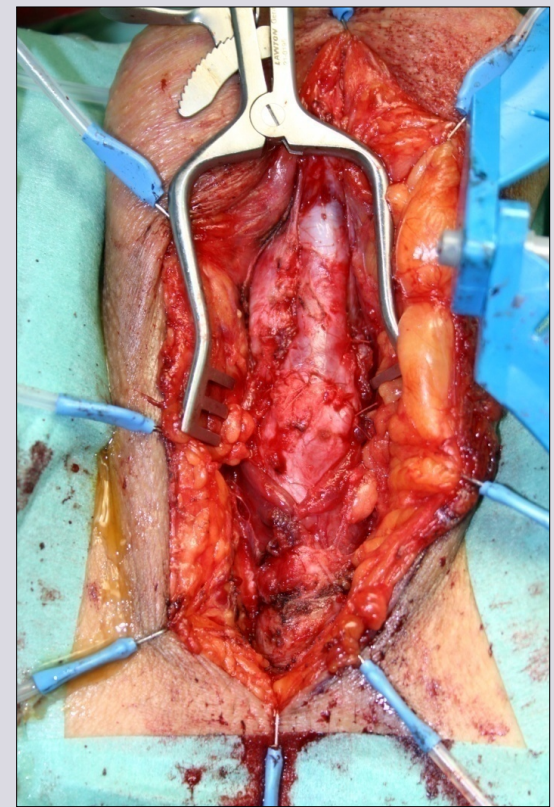
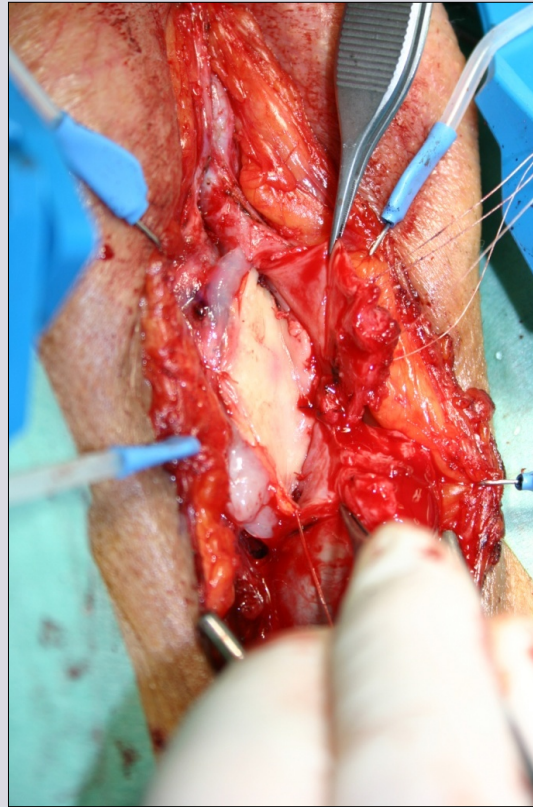
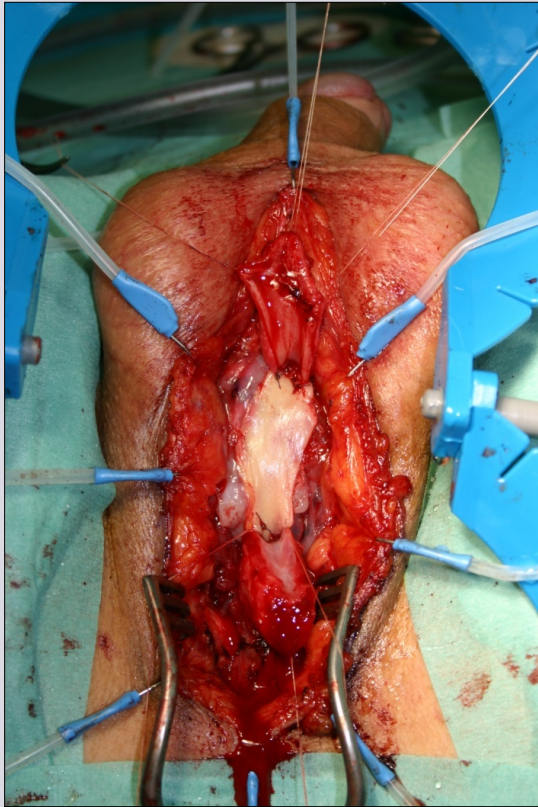
e-mail: info@urethralcenter.it

Websites: www.uretra.it
www.urethralcenter.it



e-mail: info@urethralcenter.it

Websites: www.uretra.it
www.urethralcenter.it

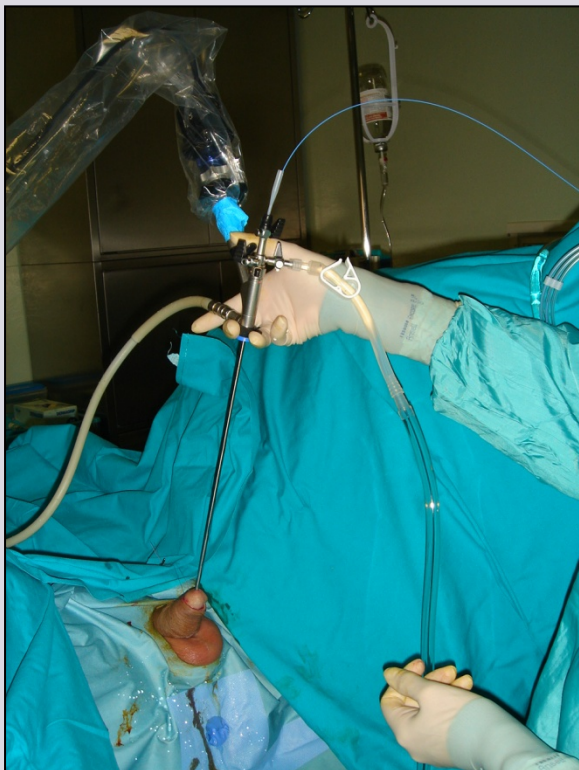


e-mail: info@urethralcenter.it

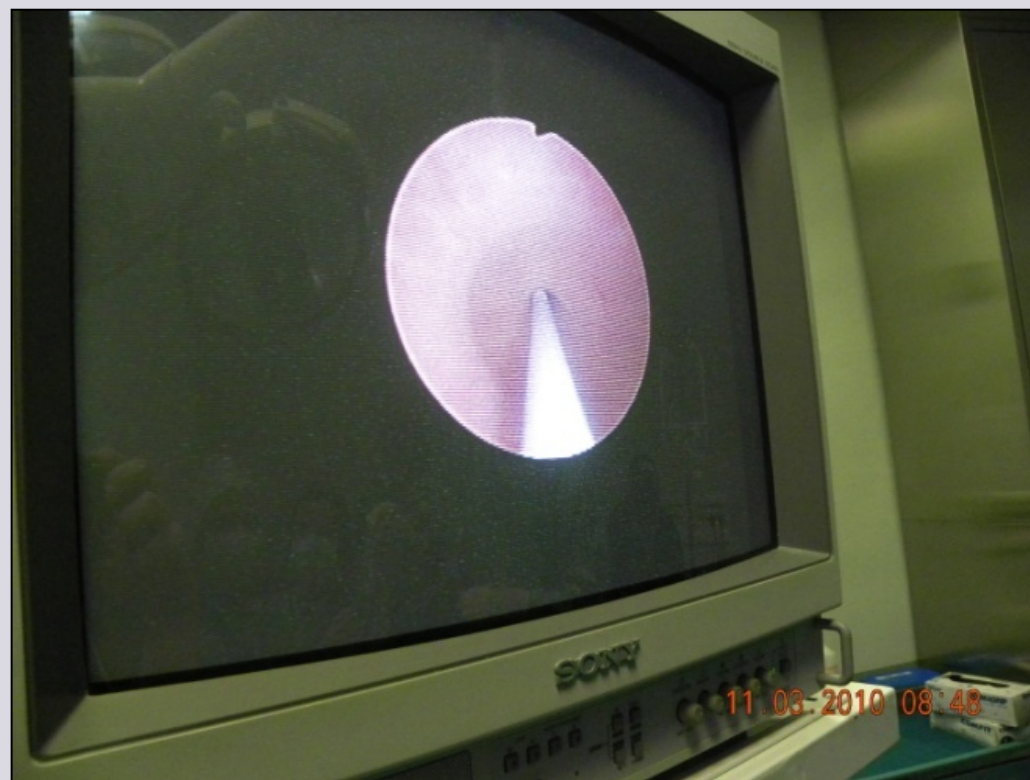Websites: www.uretra.it
www.urethralcenter.it

Reconstruction of the bulbar urethra in non-traumatic stricture

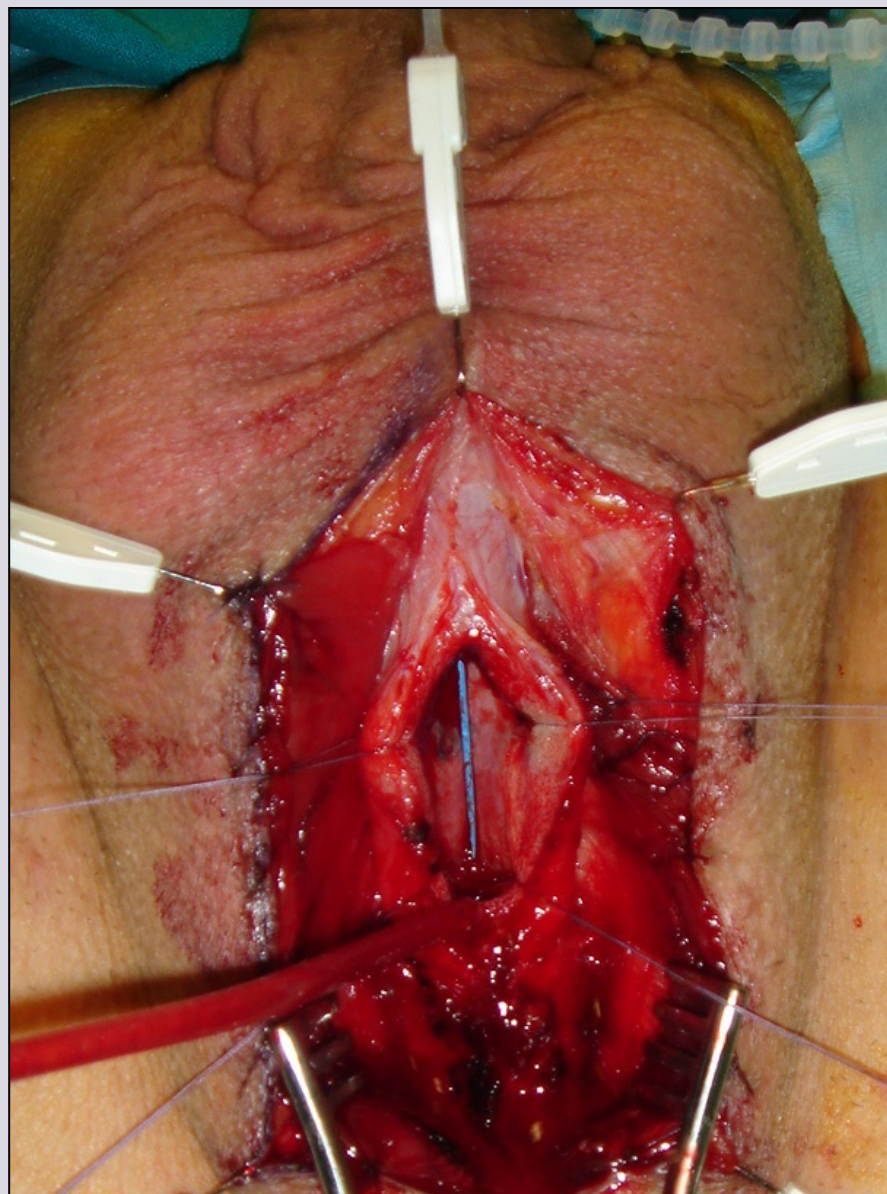Non-traumatic bulbar urethral stricture



**Pre-operative
urethroscopy**



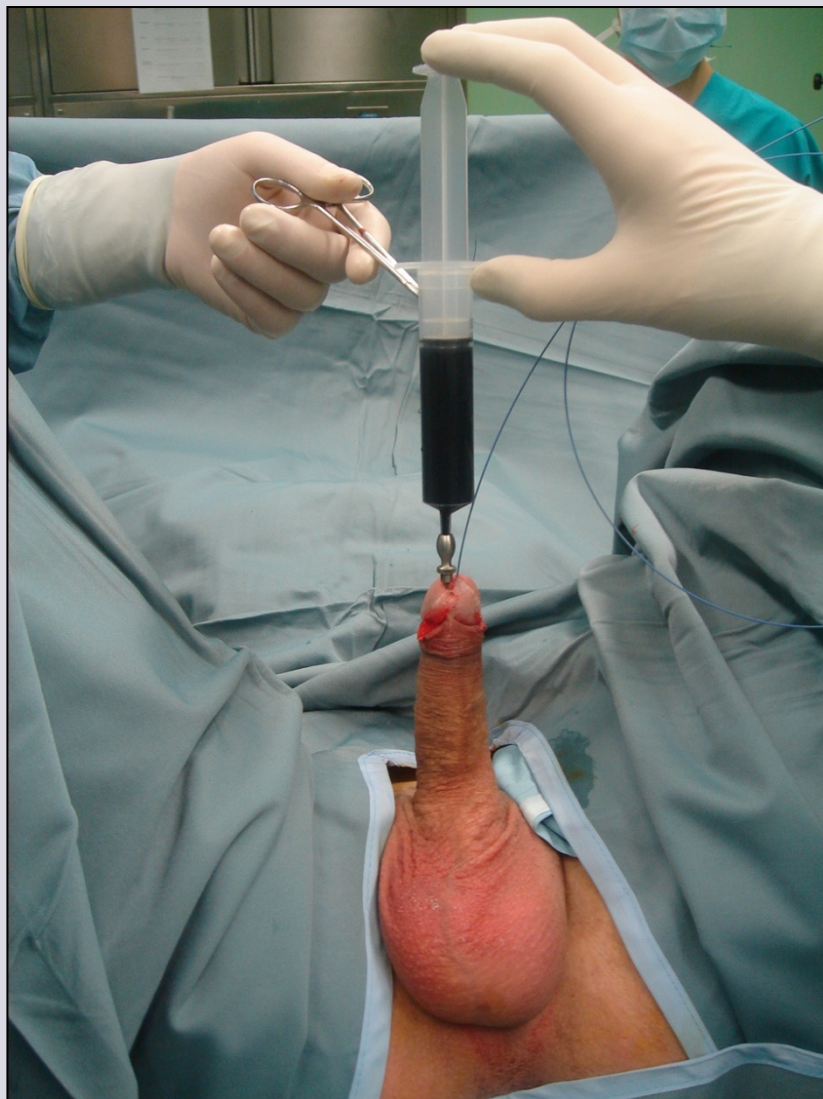
Insert Sensor 3 Fr. guidewire



e-mail: info@urethralcenter.it

Websites: www.uretra.it
www.urethralcenter.it

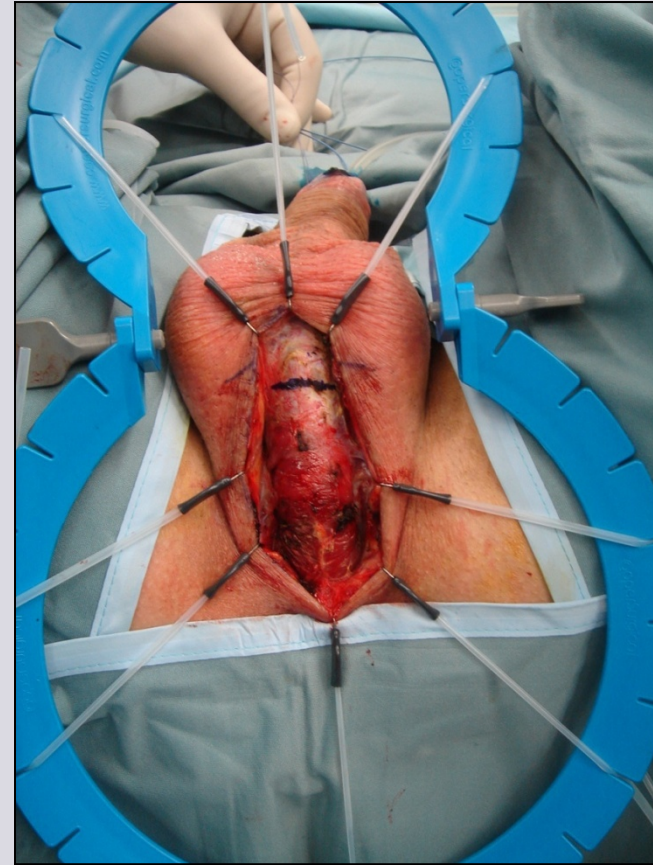
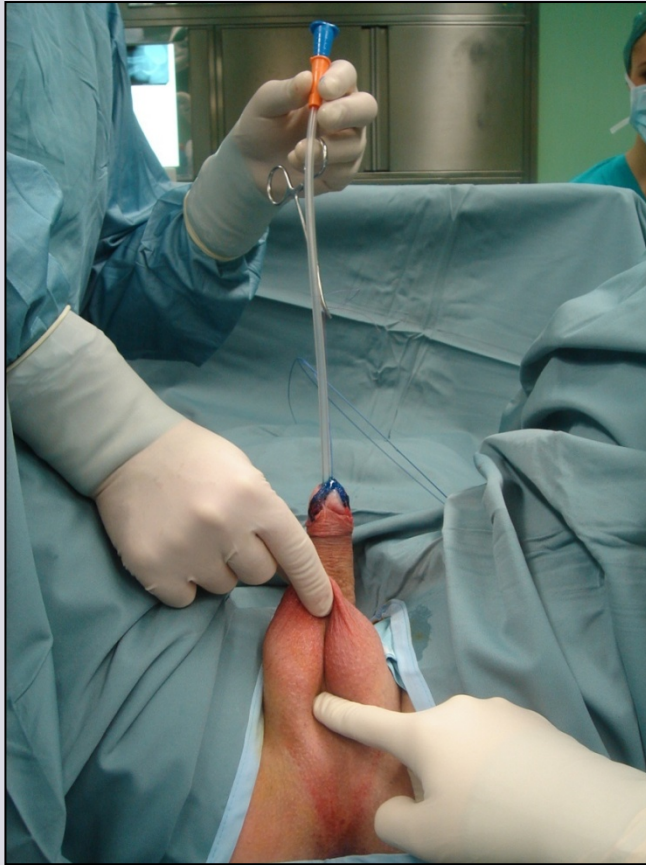Non-traumatic bulbar urethral stricture



**Inject methylene blue
inside the urethra**

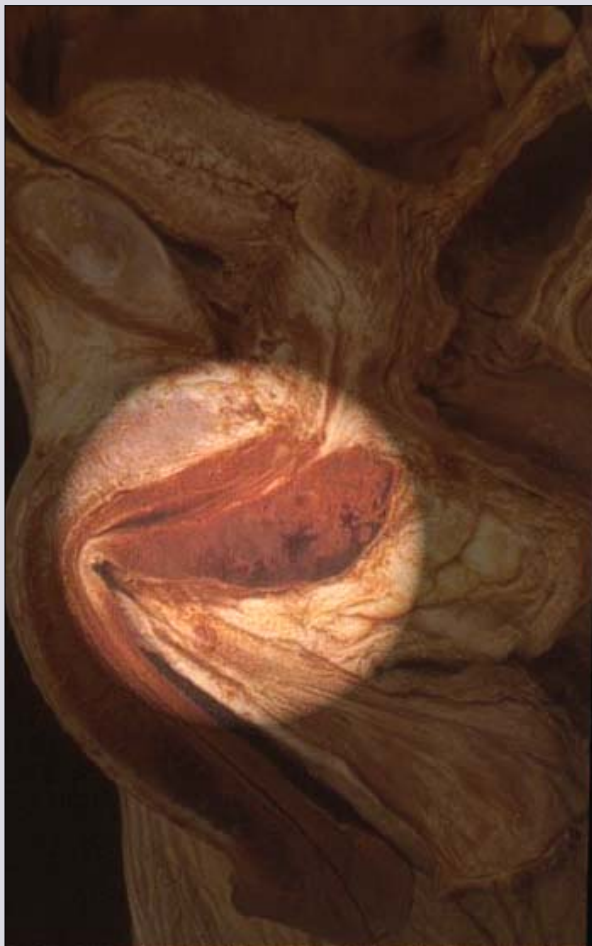(G. Webster)

Non-traumatic bulbar urethral stricture



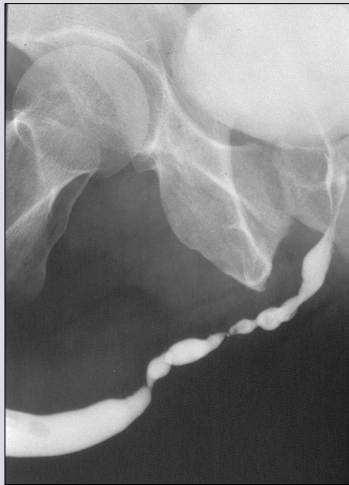Calibrate the distal urethra and identify the distal stop

Non-traumatic bulbar urethral stricture



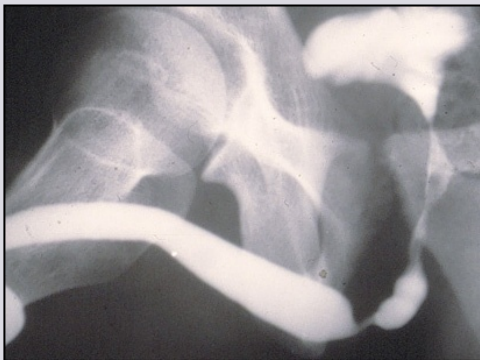Ventral or dorsal graft?

Ventral or dorsal graft?



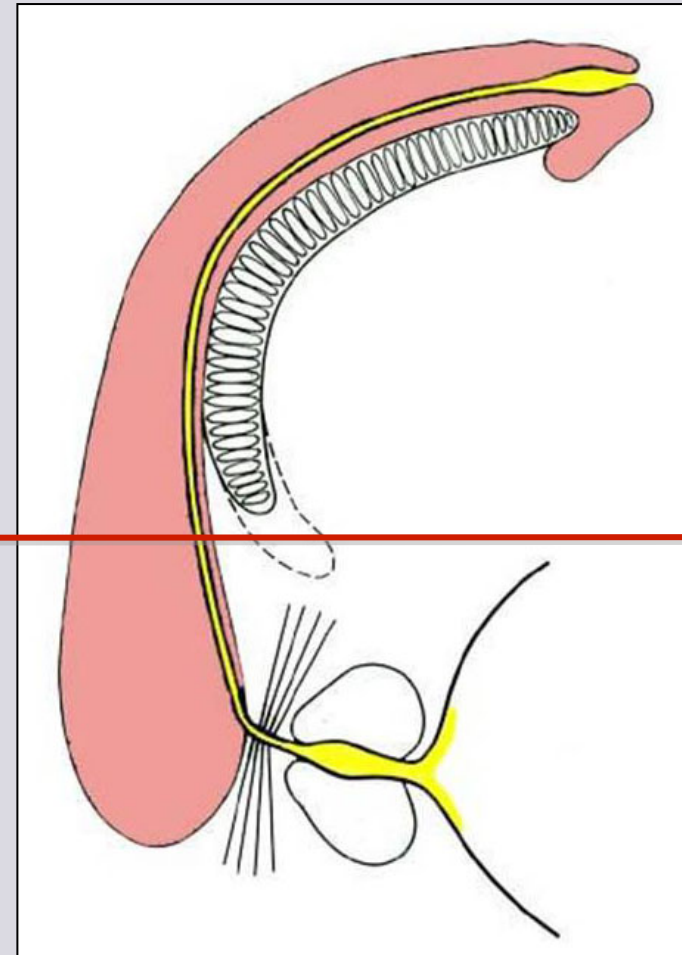
Distal

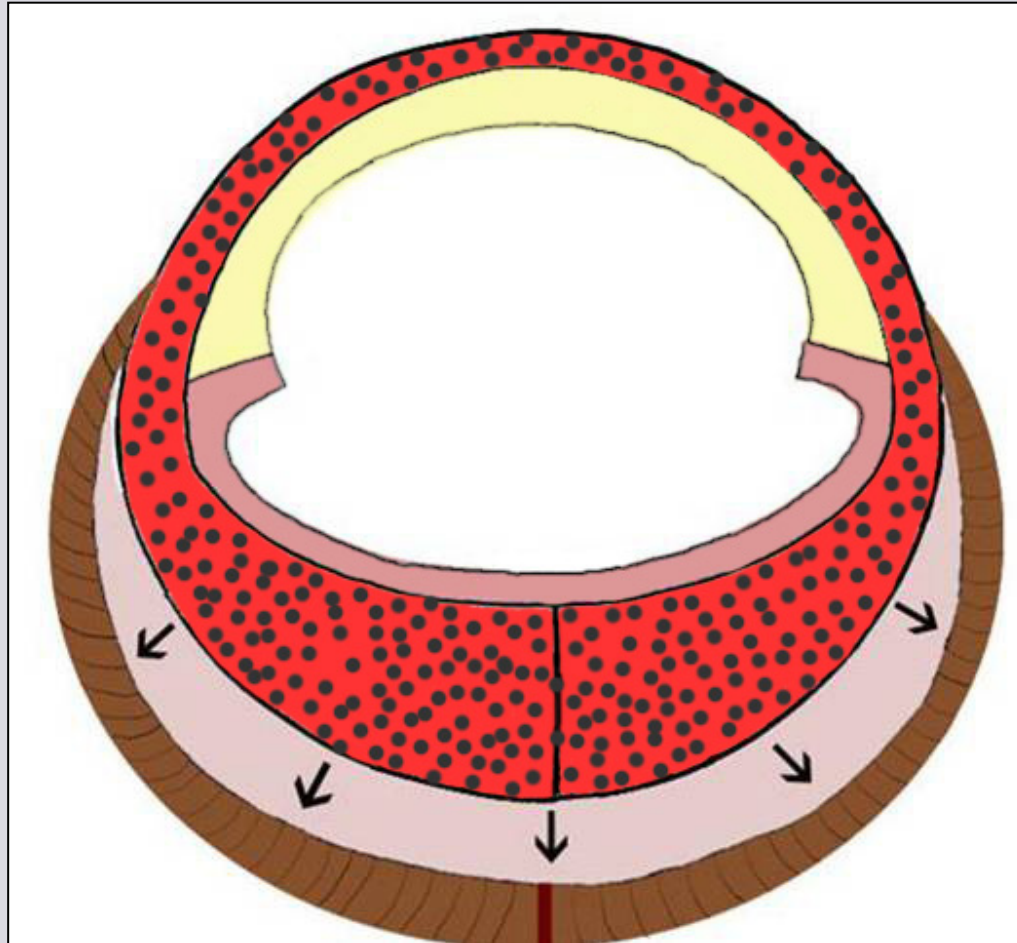
Dorsal onlay



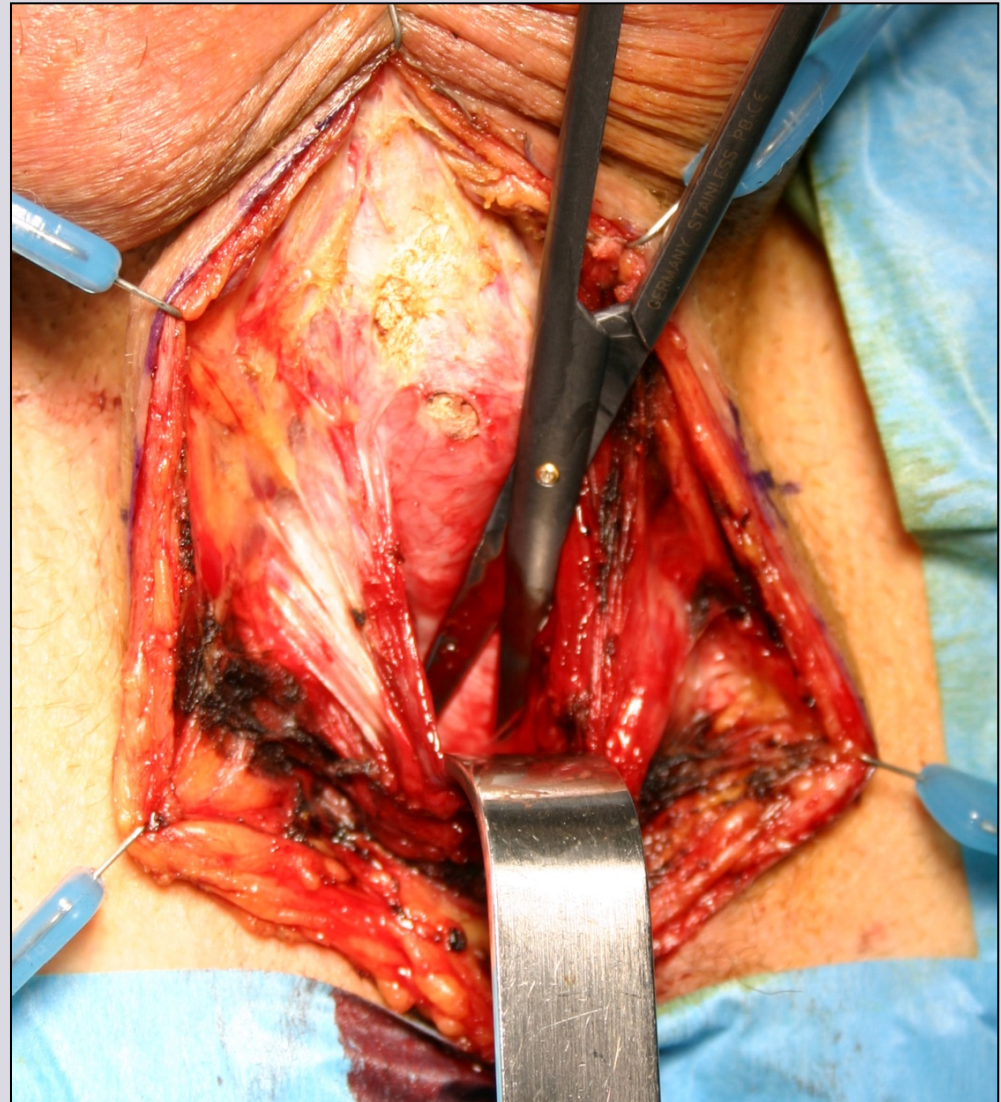
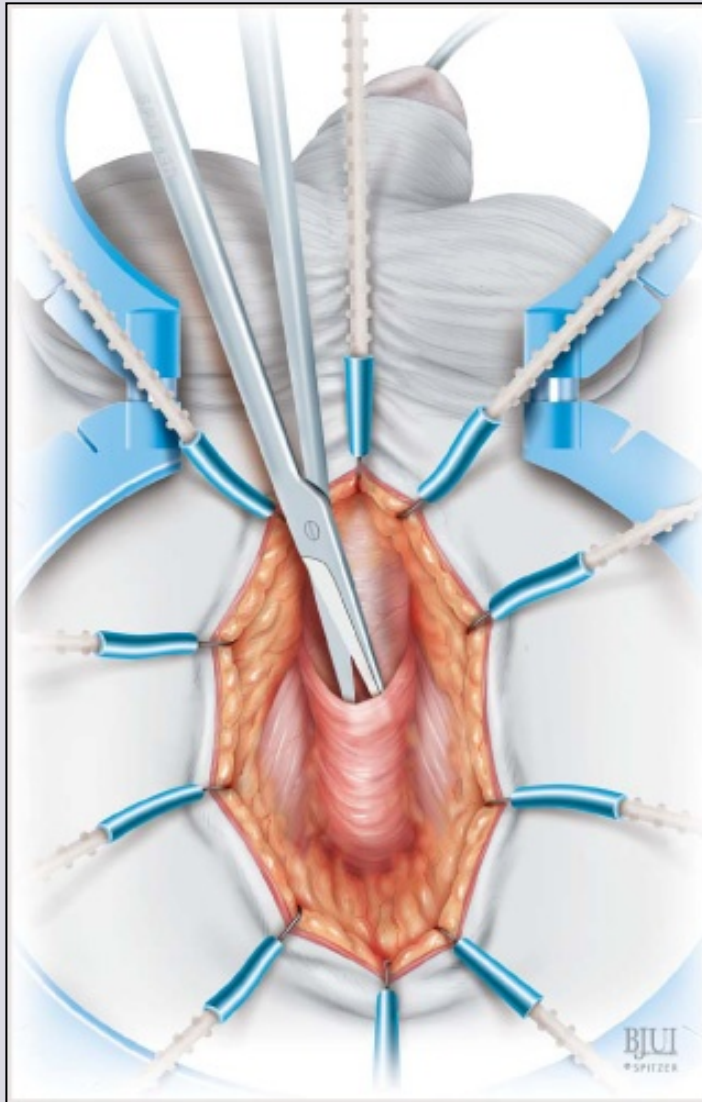
Proximal

Ventral onlay



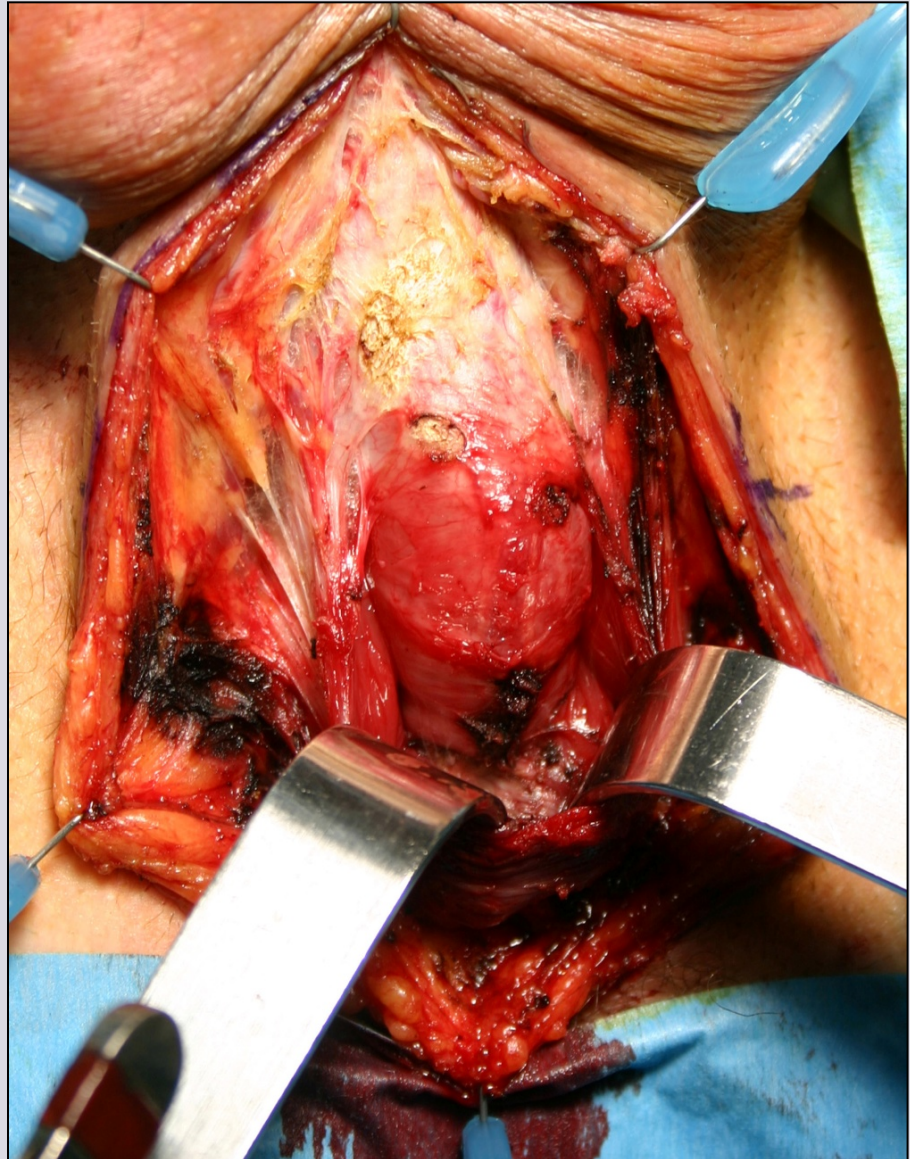
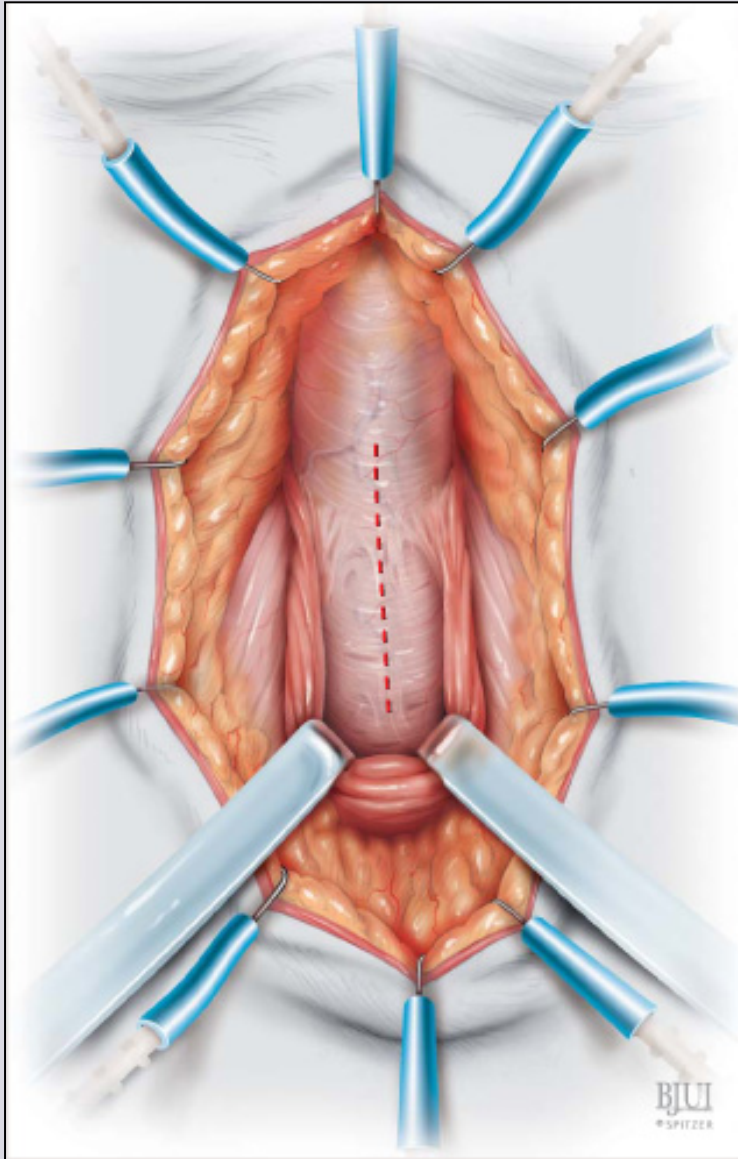


Muscle and nerve-sparing **ventral onlay graft bulbar urethroplasty**



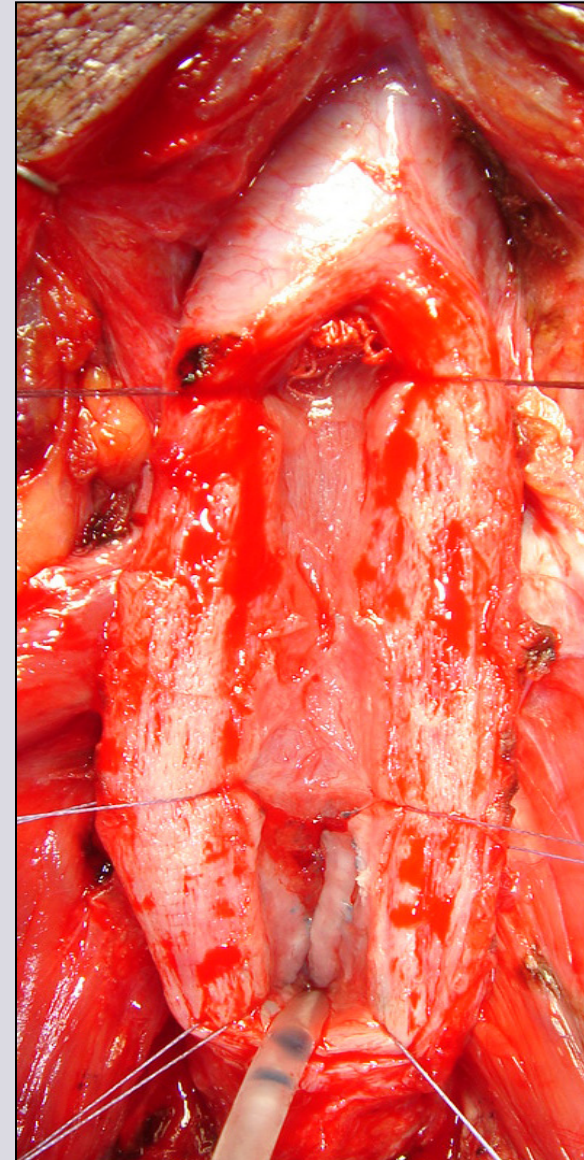
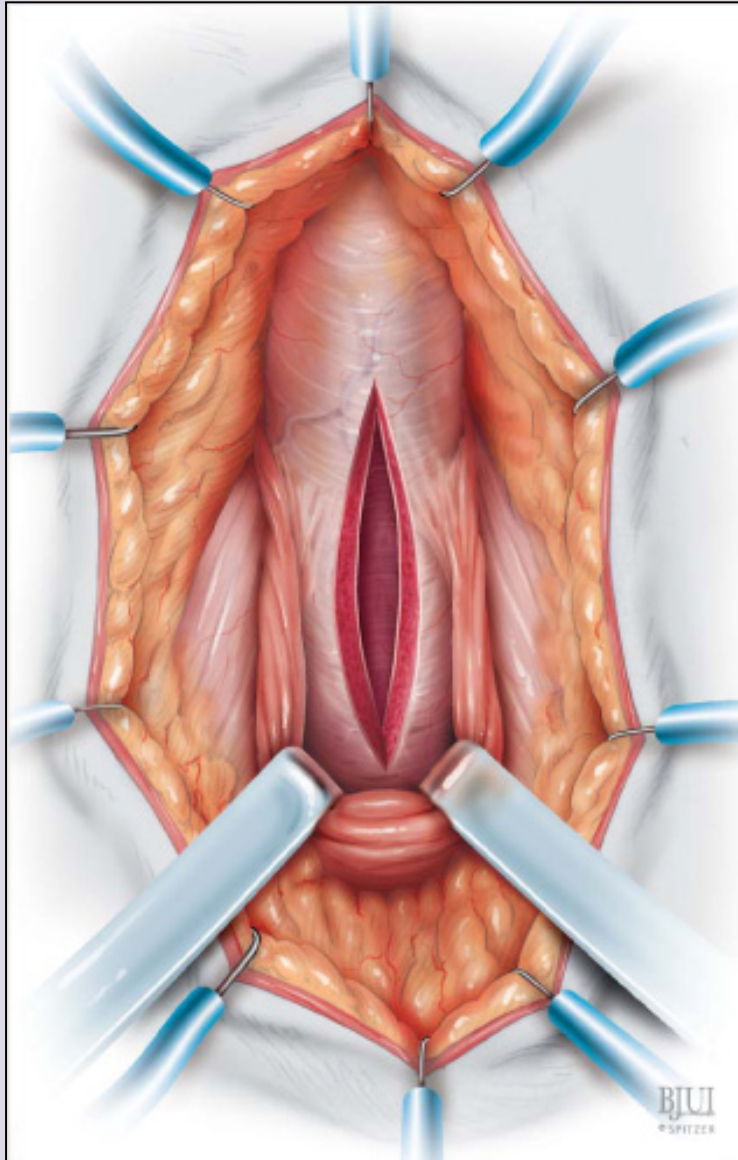
e-mail: info@urethralcenter.it

Websites: www.uretra.it
www.urethralcenter.it



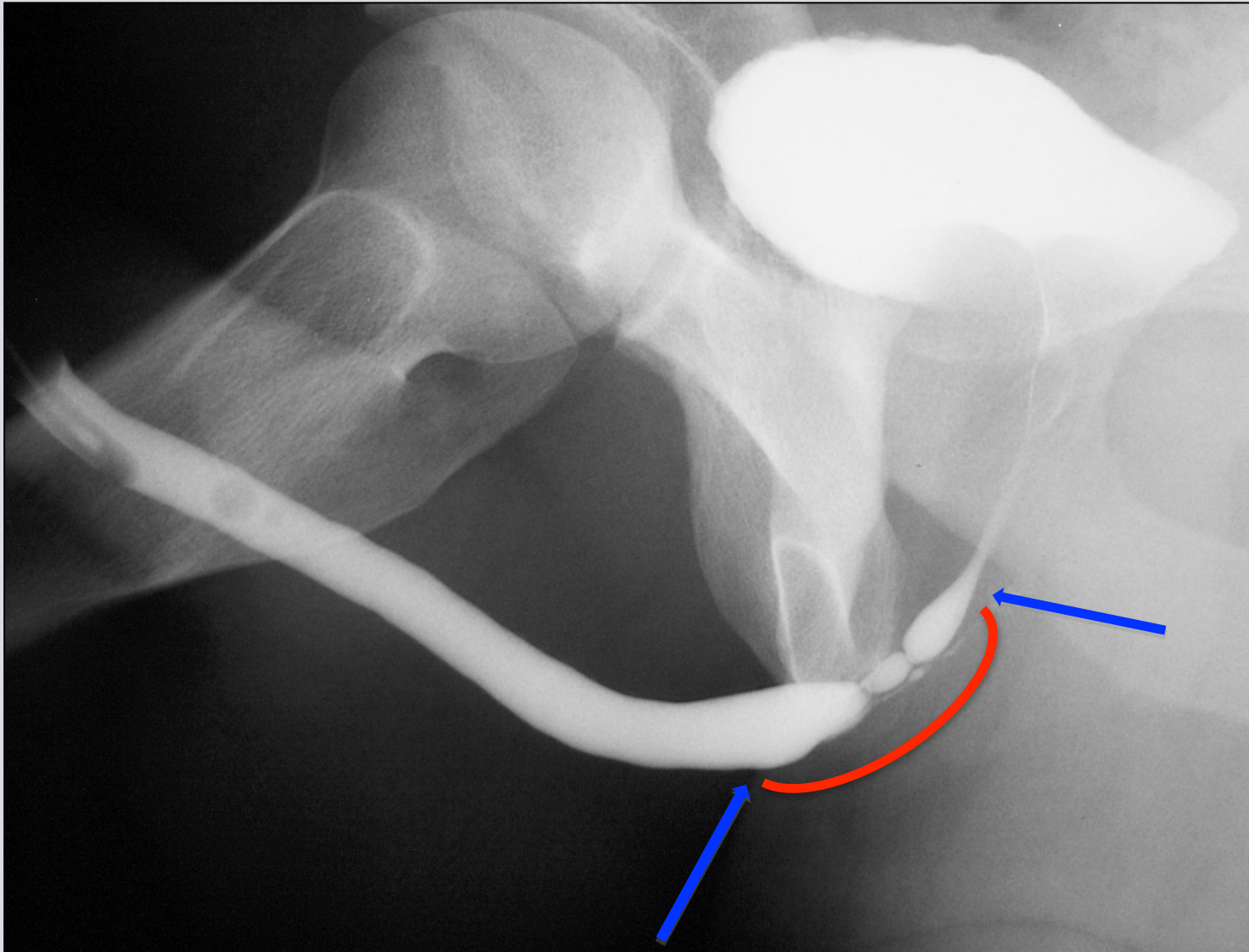
e-mail: info@urethralcenter.it

Websites: www.uretra.it
www.urethralcenter.it



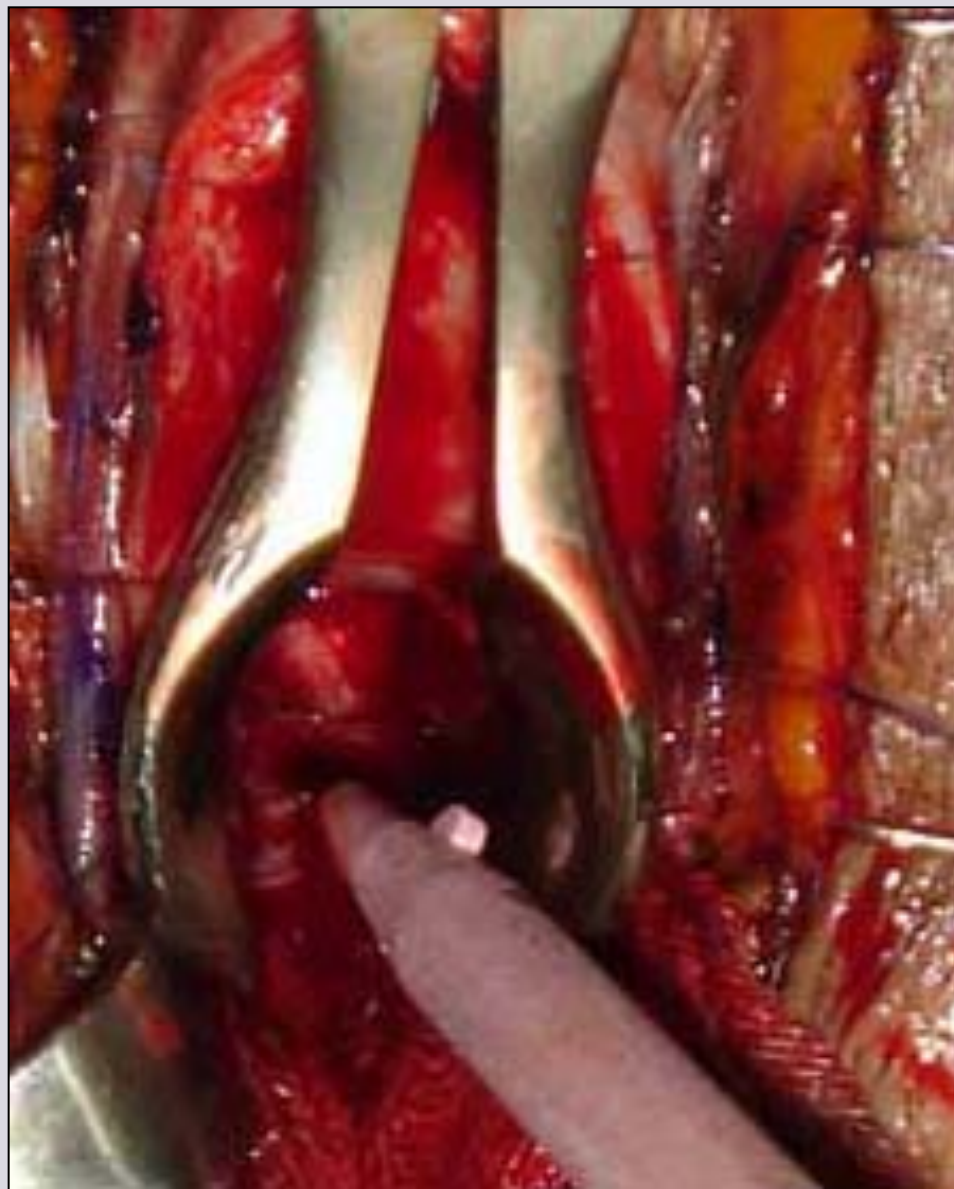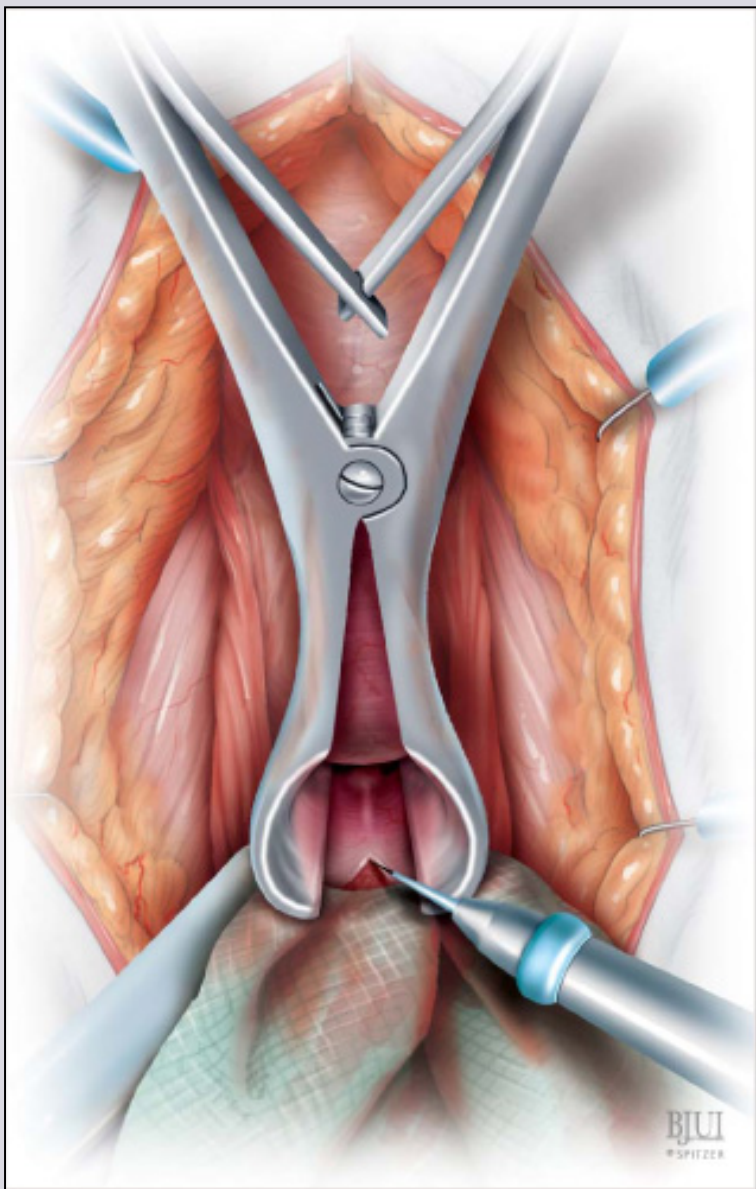
e-mail: info@urethralcenter.it

Websites: www.uretra.it
www.urethralcenter.it



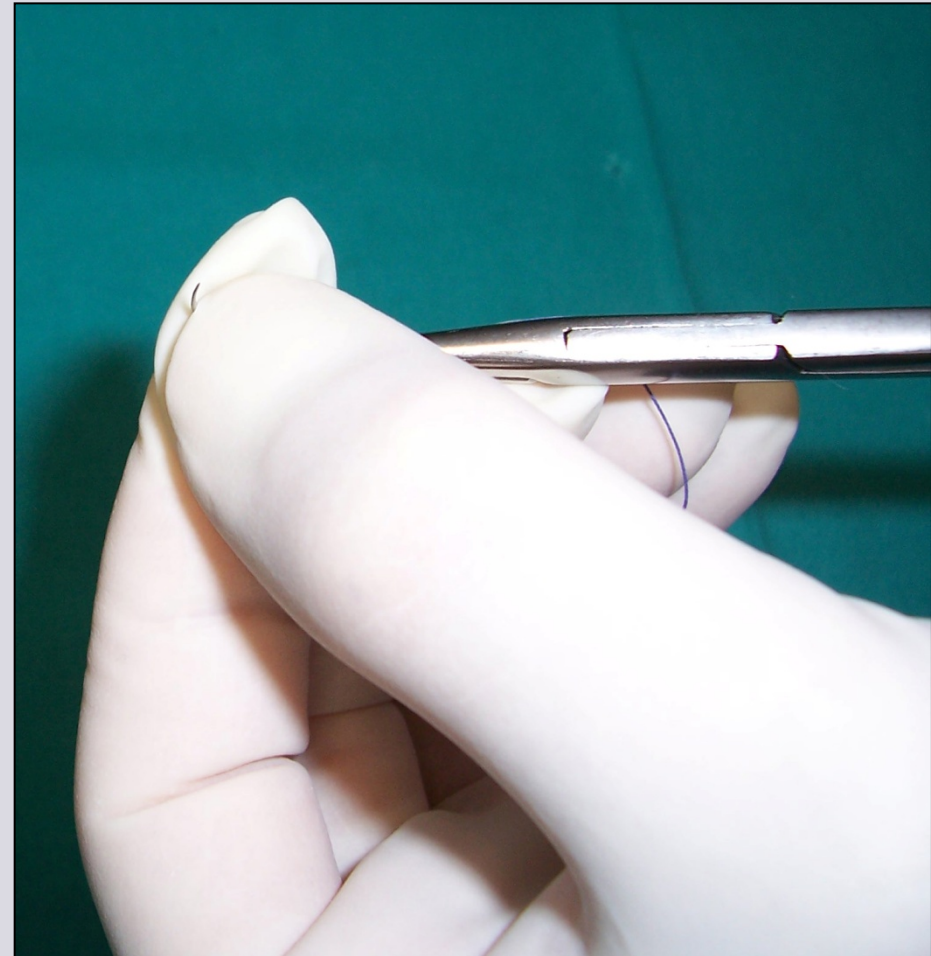
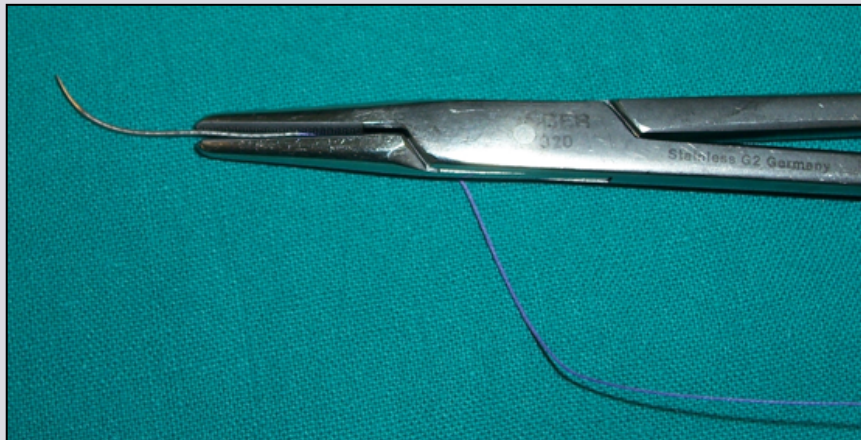
e-mail: info@urethralcenter.it

Websites: www.uretra.it
www.urethralcenter.it



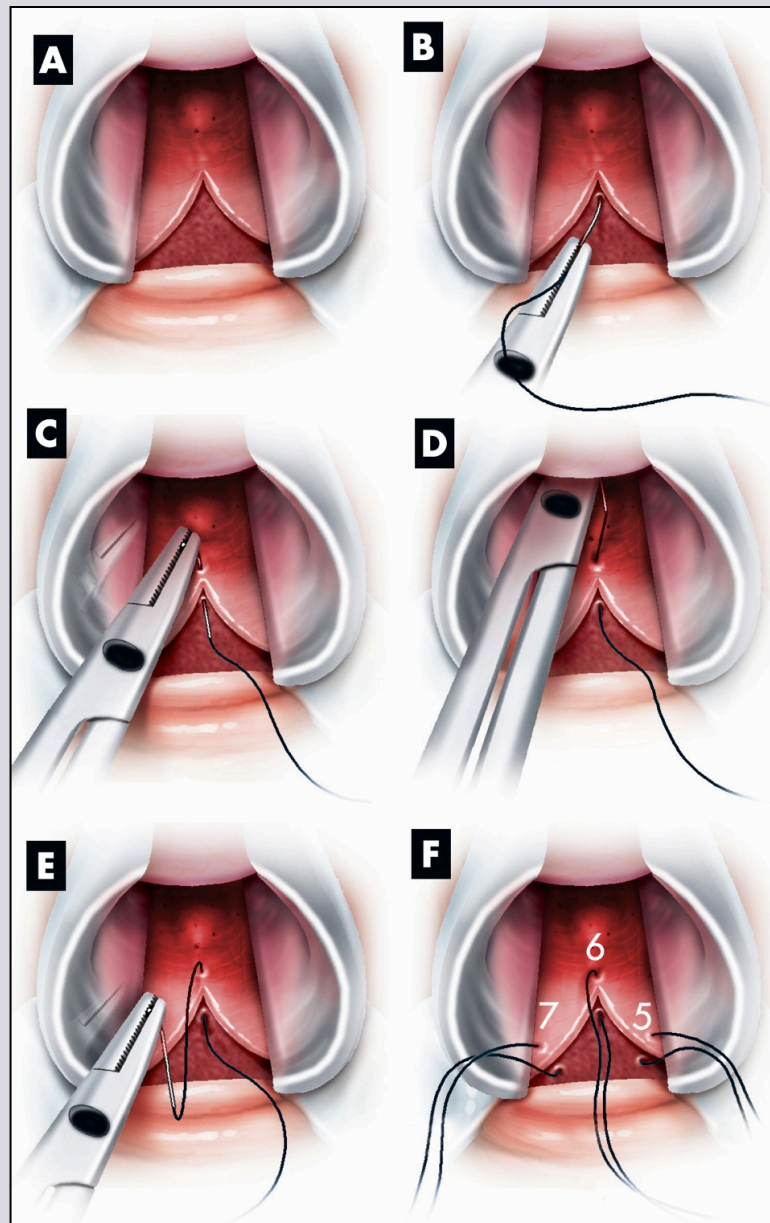
e-mail: info@urethralcenter.it

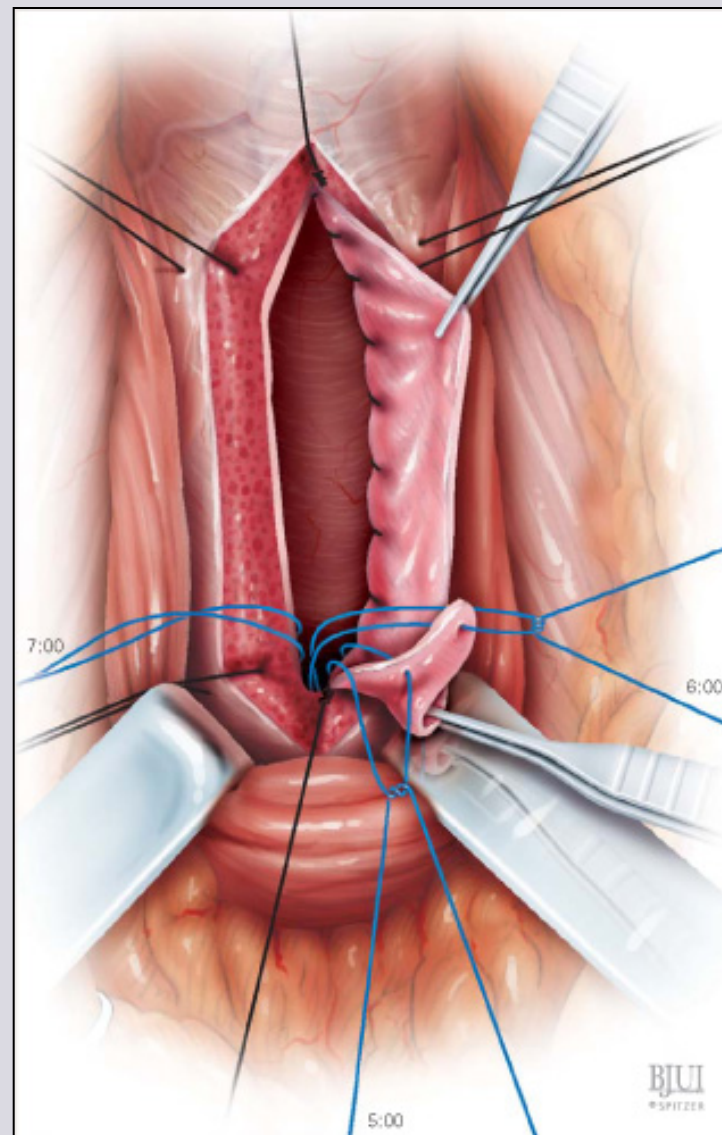
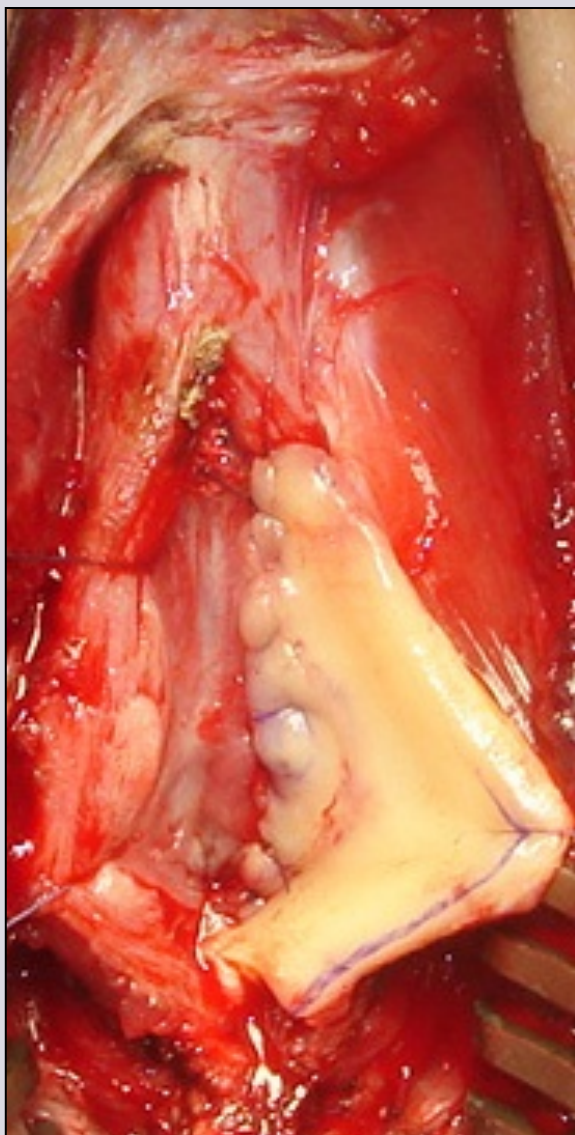
Websites: www.uretra.it
www.urethralcenter.it



e-mail: info@urethralcenter.it

Websites: www.uretra.it
www.urethralcenter.it

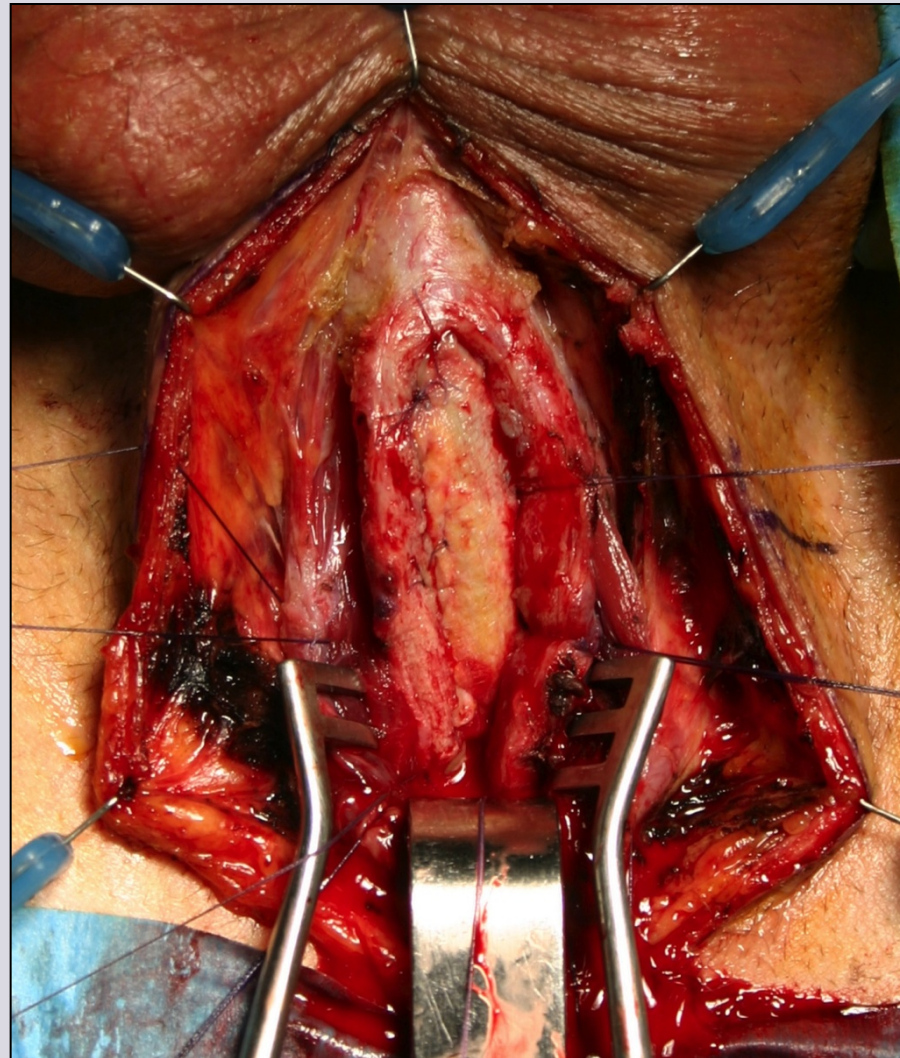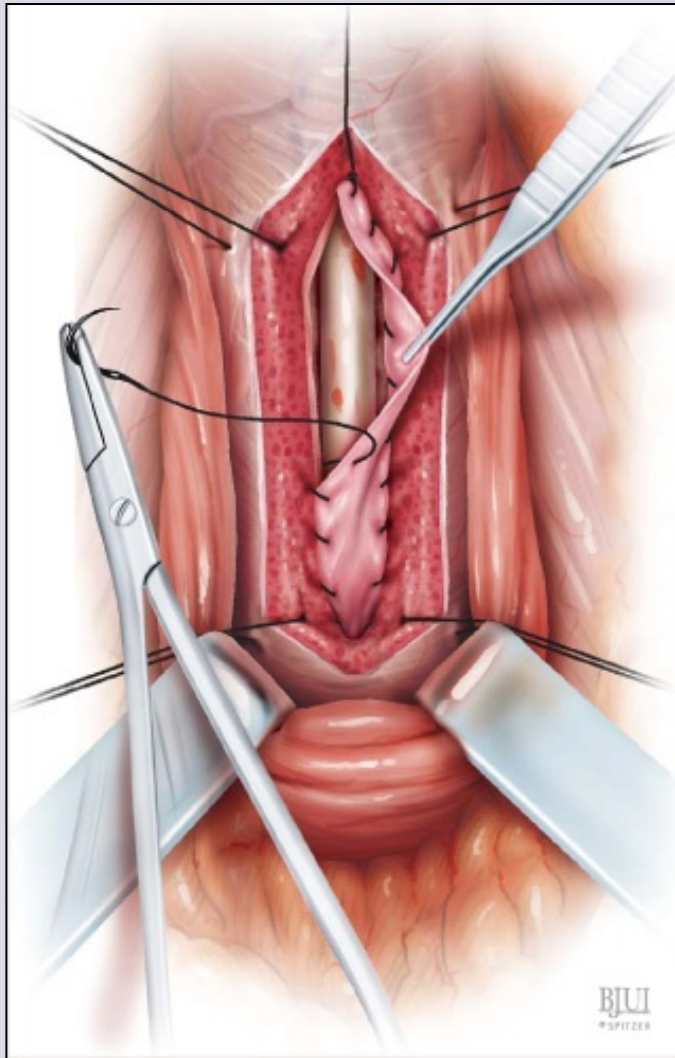




e-mail: info@urethralcenter.it

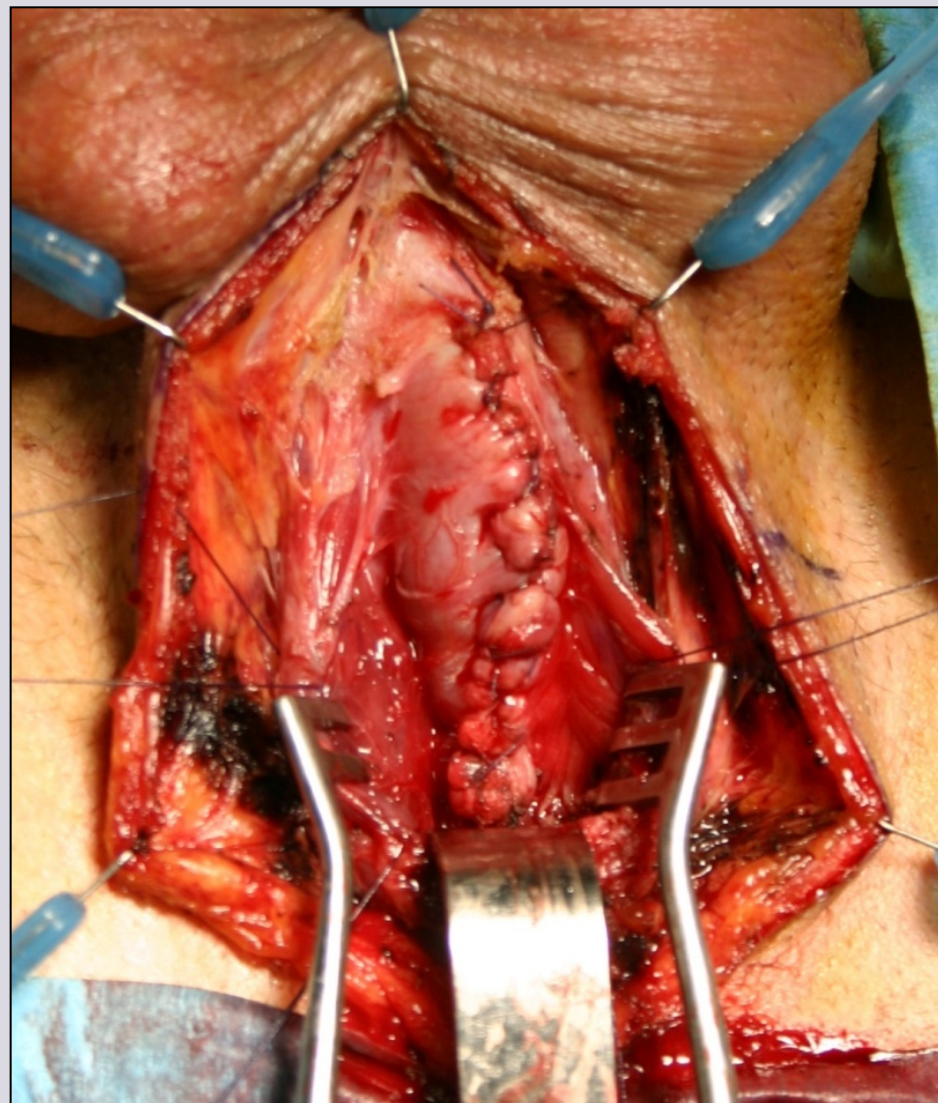
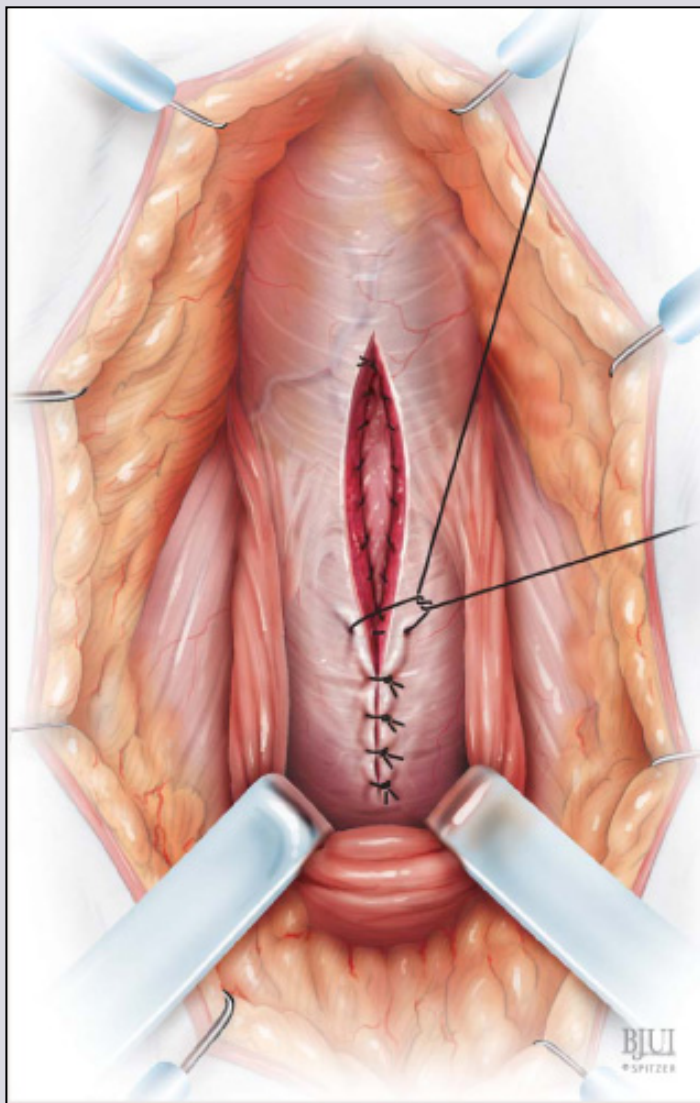
Websites: www.uretra.it
www.urethralcenter.it

CENTER FOR RECONSTRUCTIVE URETHRAL SURGERY



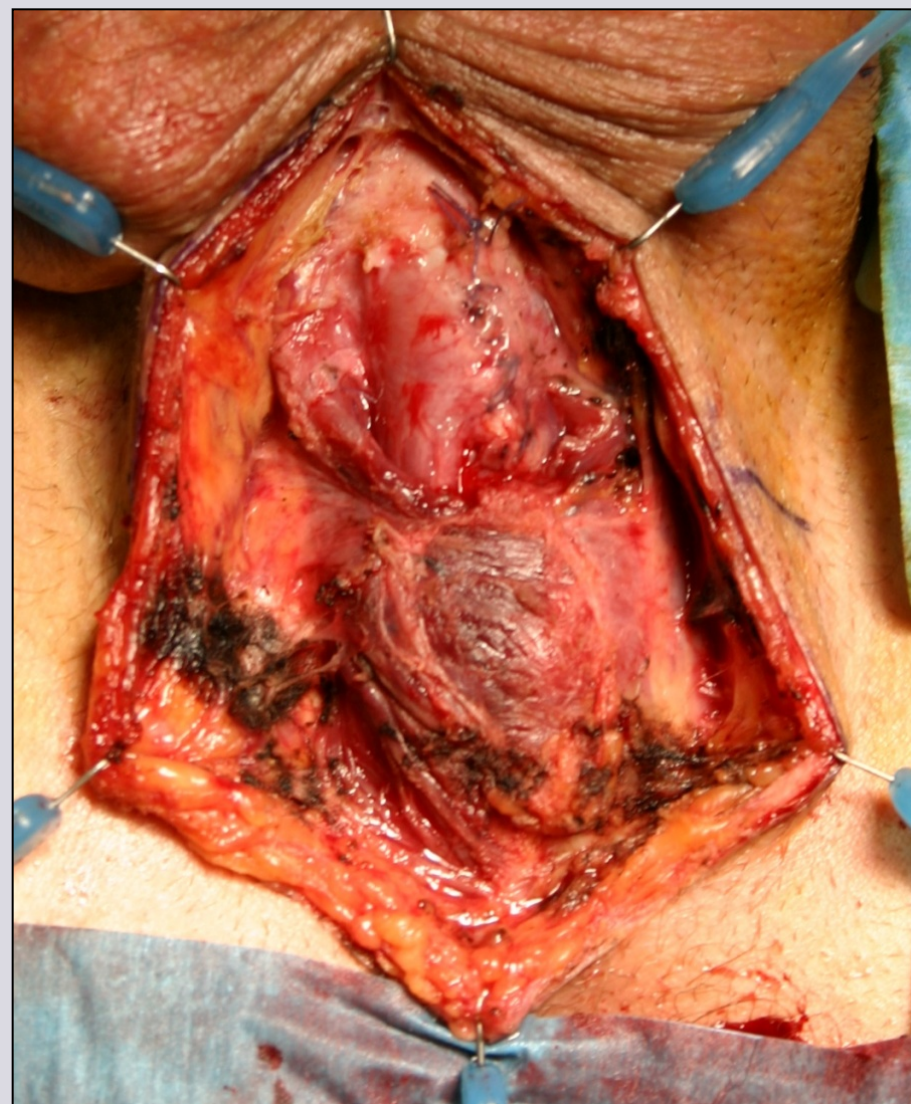
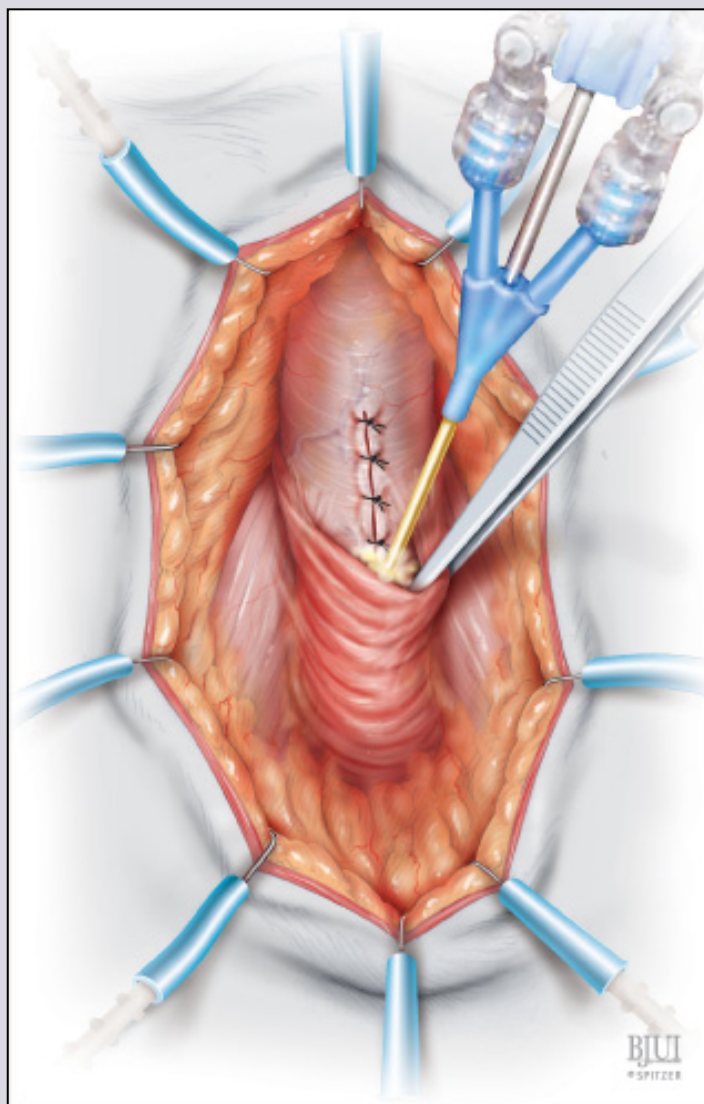
e-mail: info@urethralcenter.it

Websites: www.uretra.it
www.urethralcenter.it



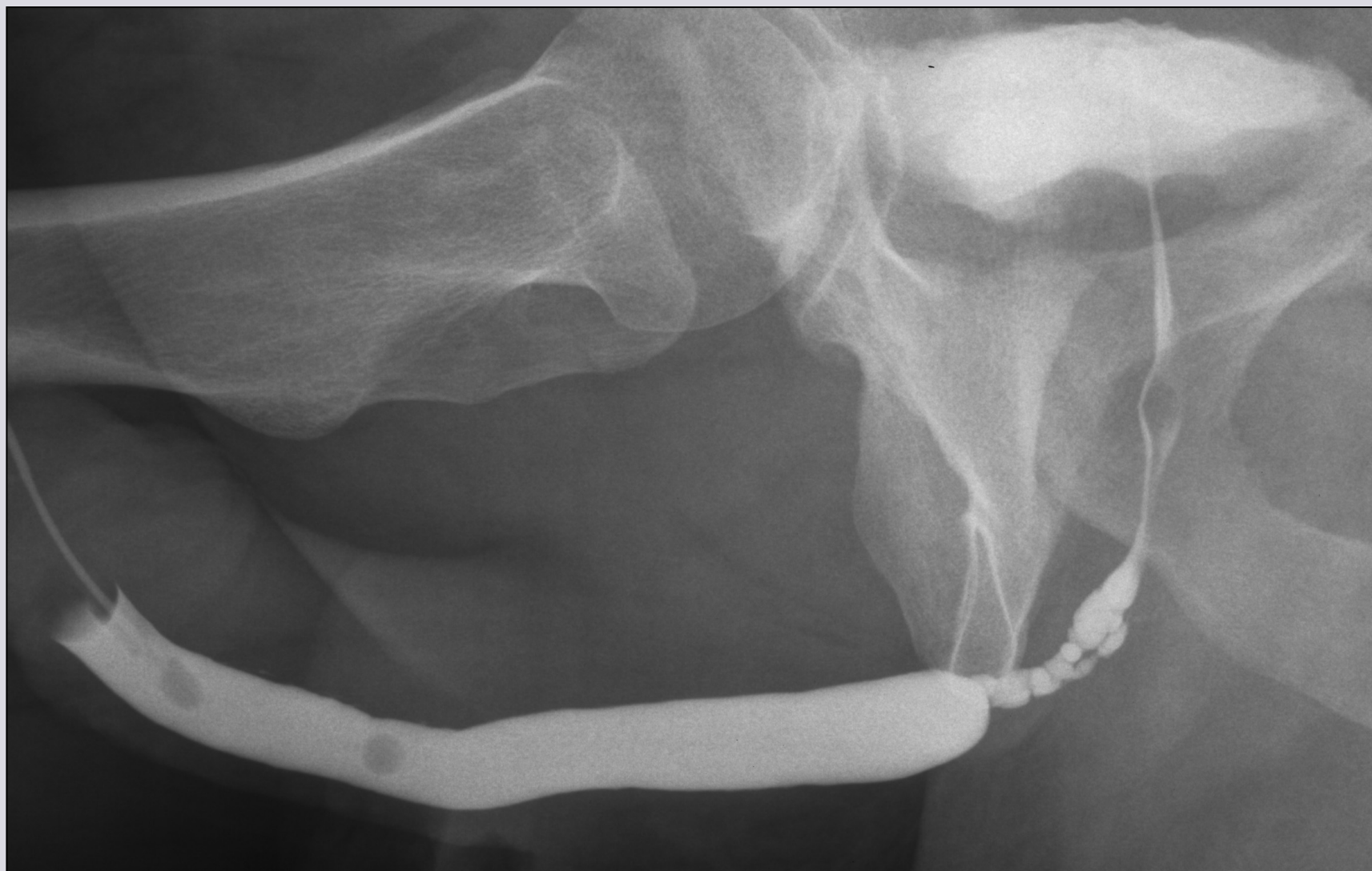e-mail: info@urethralcenter.it

Websites: www.uretra.it
www.urethralcenter.it



e-mail: info@urethralcenter.it

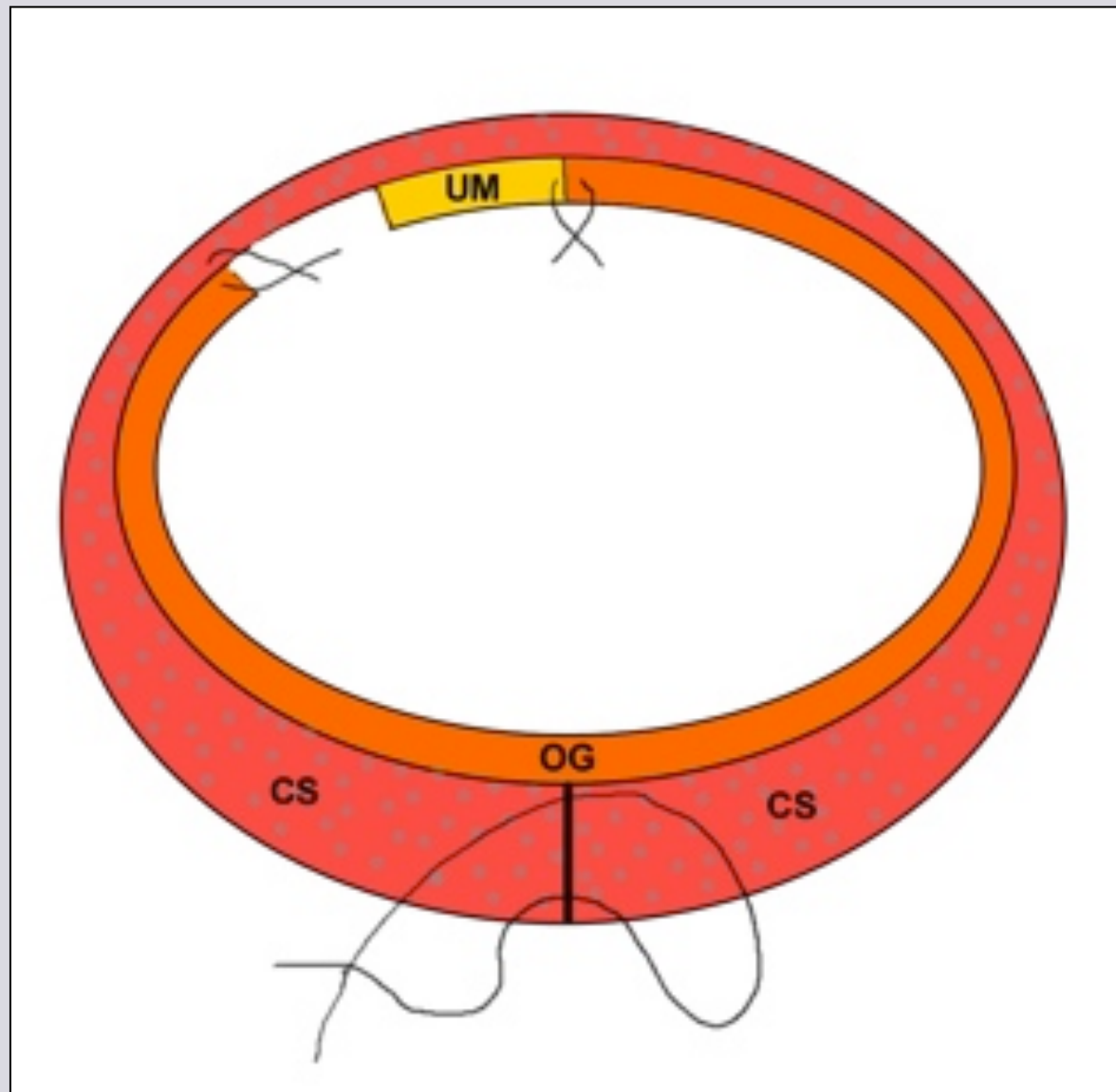
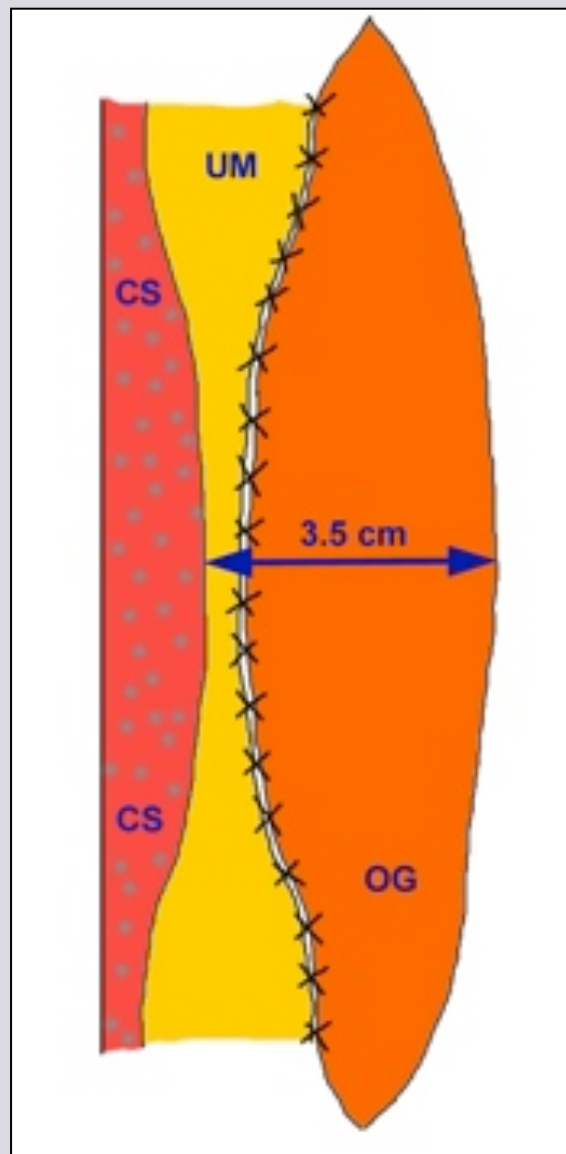
Websites: www.uretra.it
www.urethralcenter.it

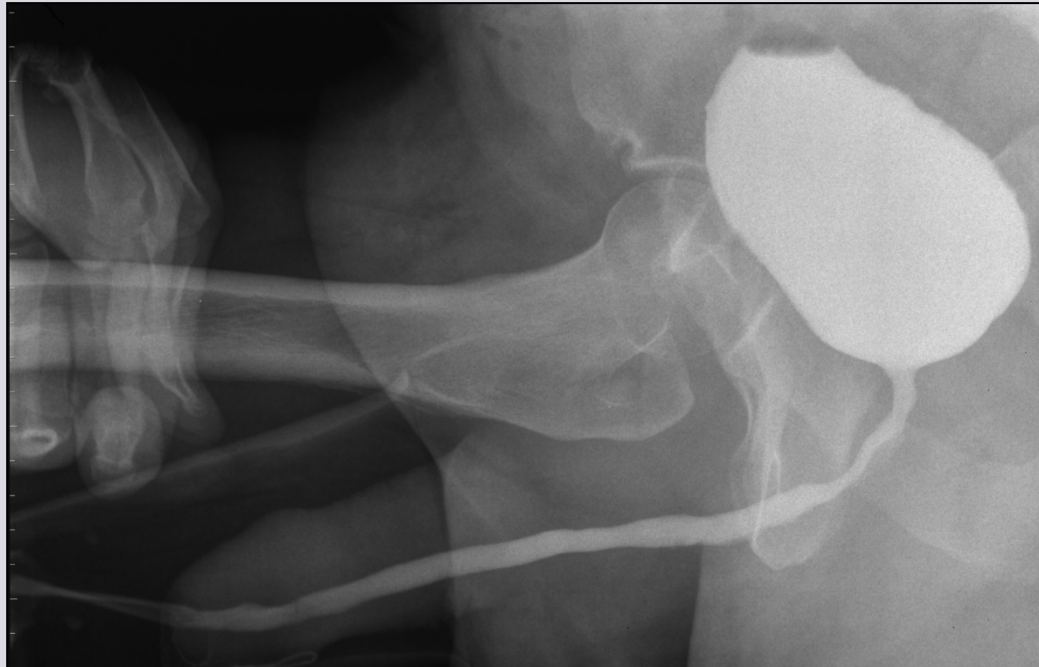
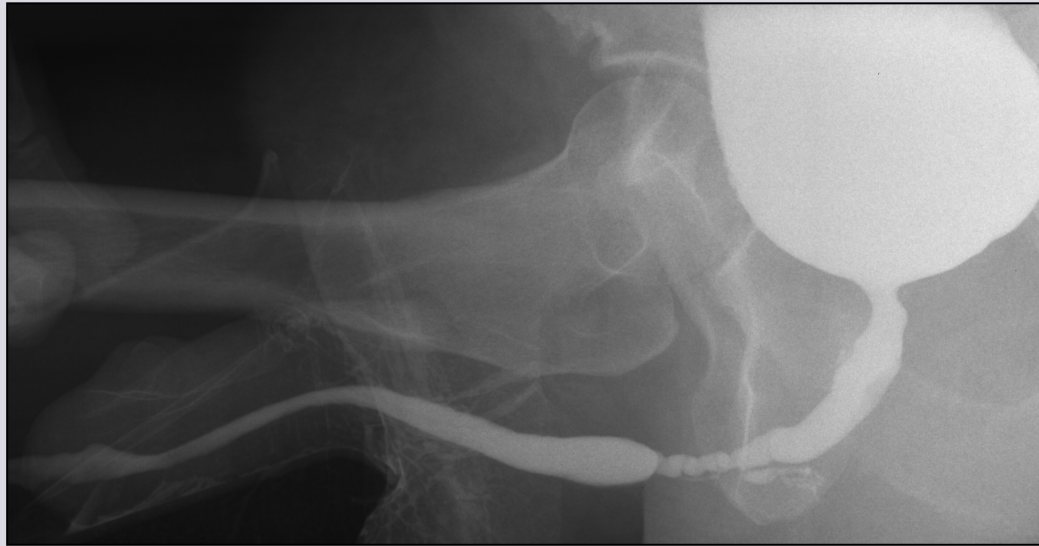


e-mail: info@urethralcenter.it

Websites: www.uretra.it
www.urethralcenter.it

CENTER FOR RECONSTRUCTIVE URETHRAL SURGERY

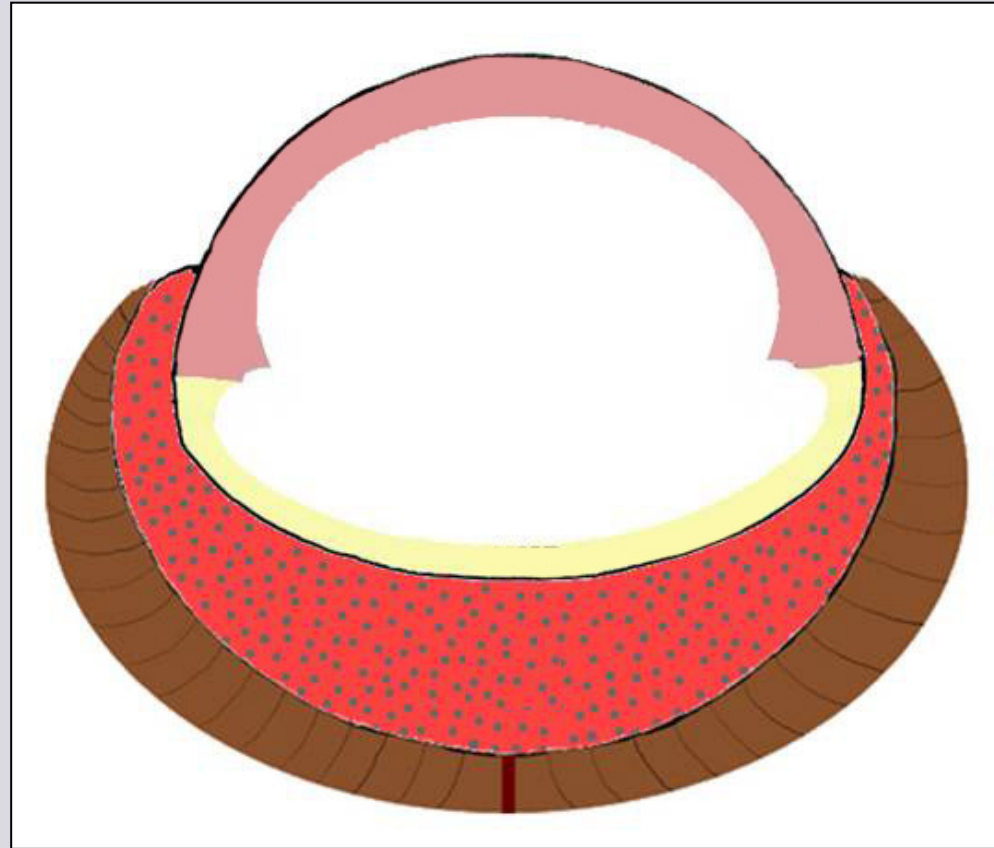




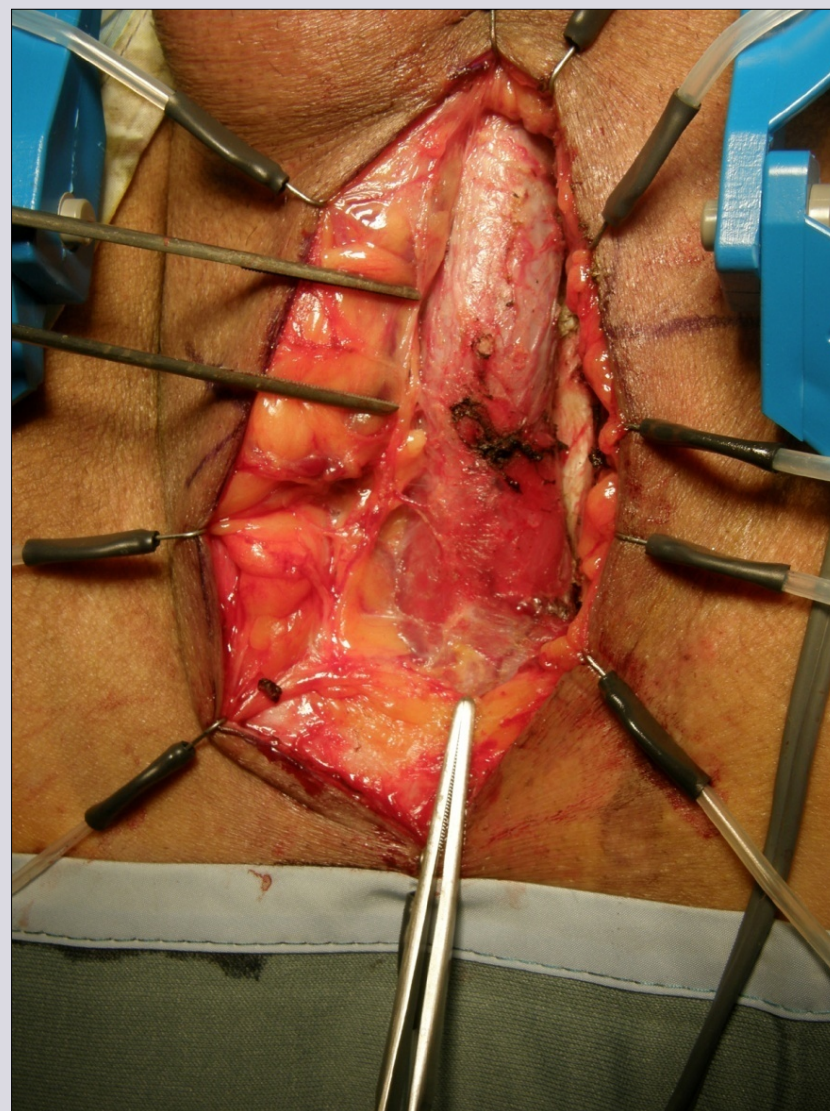
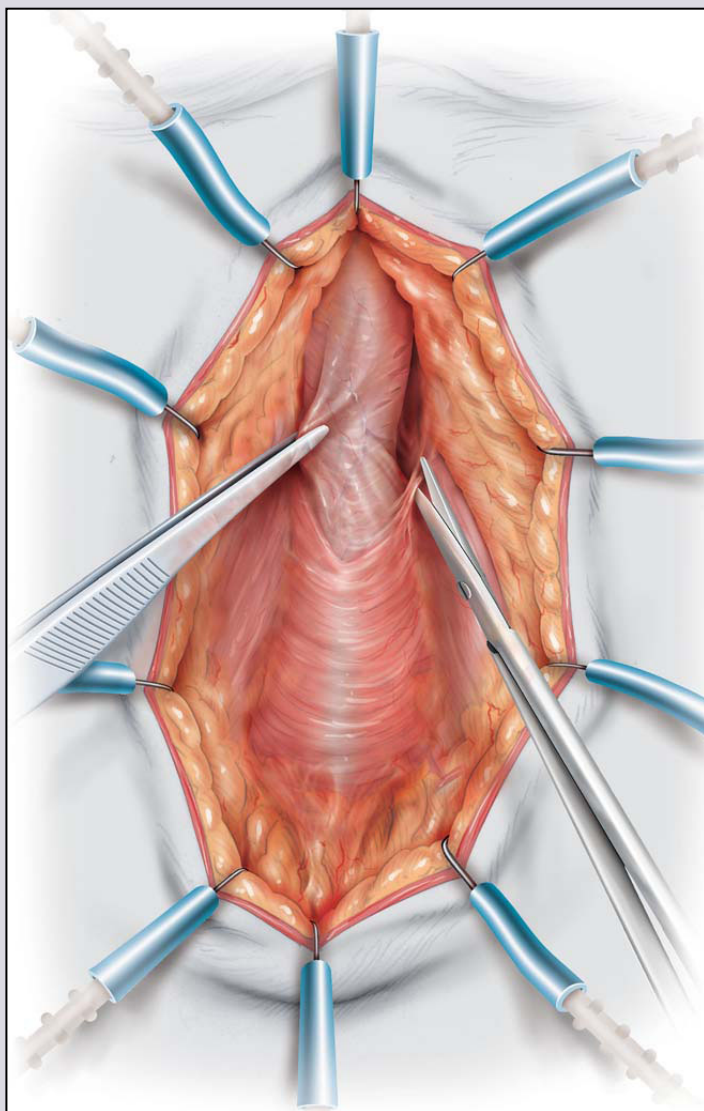
e-mail: info@urethralcenter.it

Websites: www.uretra.it
www.urethralcenter.it

CENTER FOR RECONSTRUCTIVE URETHRAL SURGERY

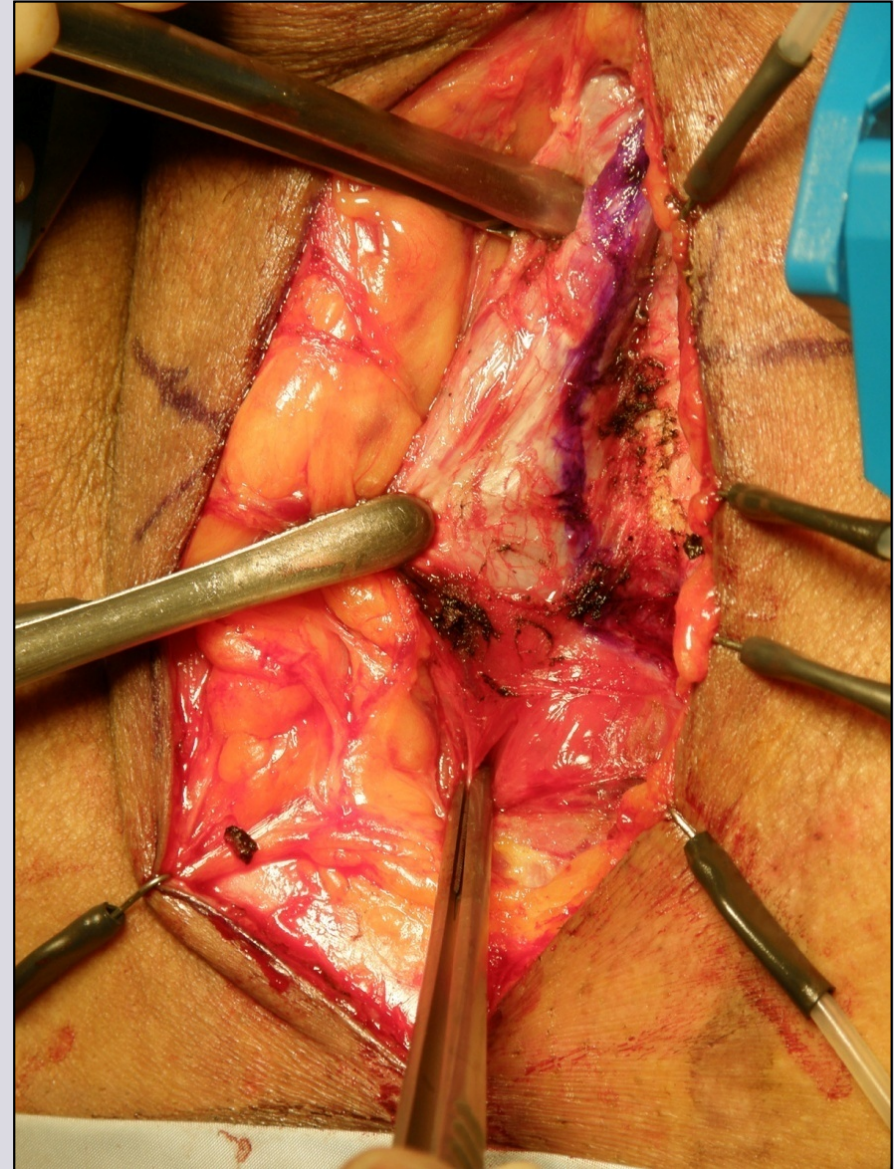
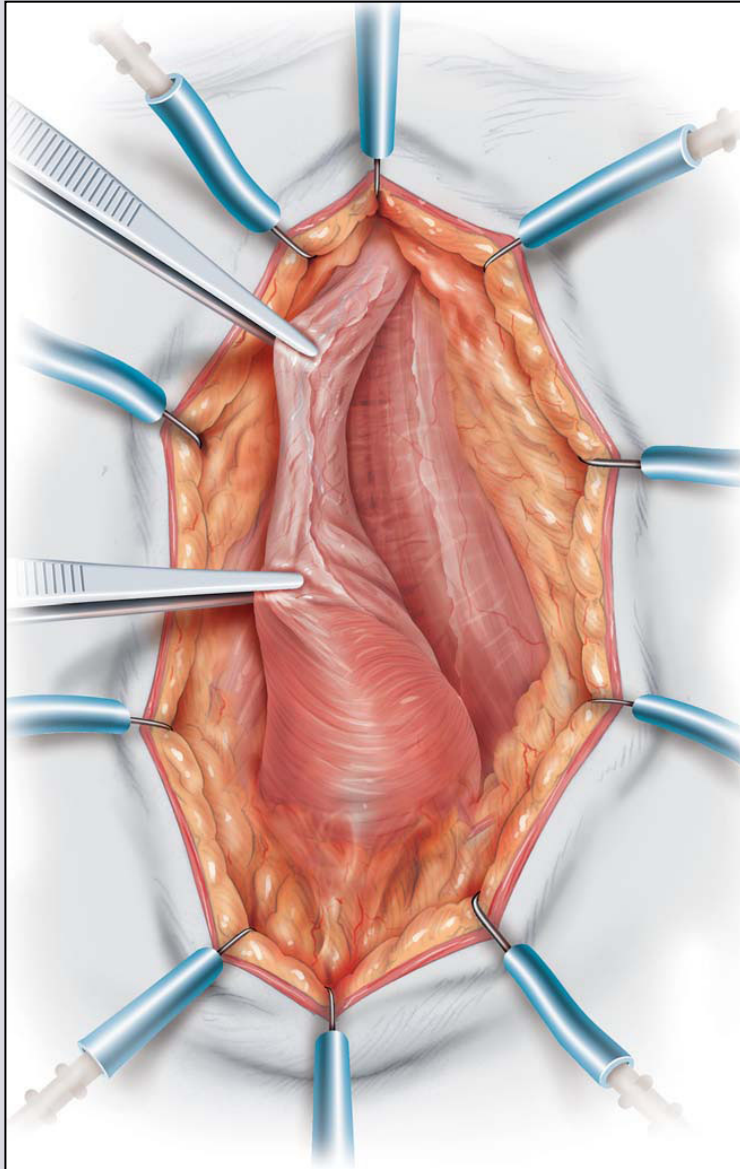


Muscle and nerve-sparing dorsal onlay graft bulbar urethroplasty



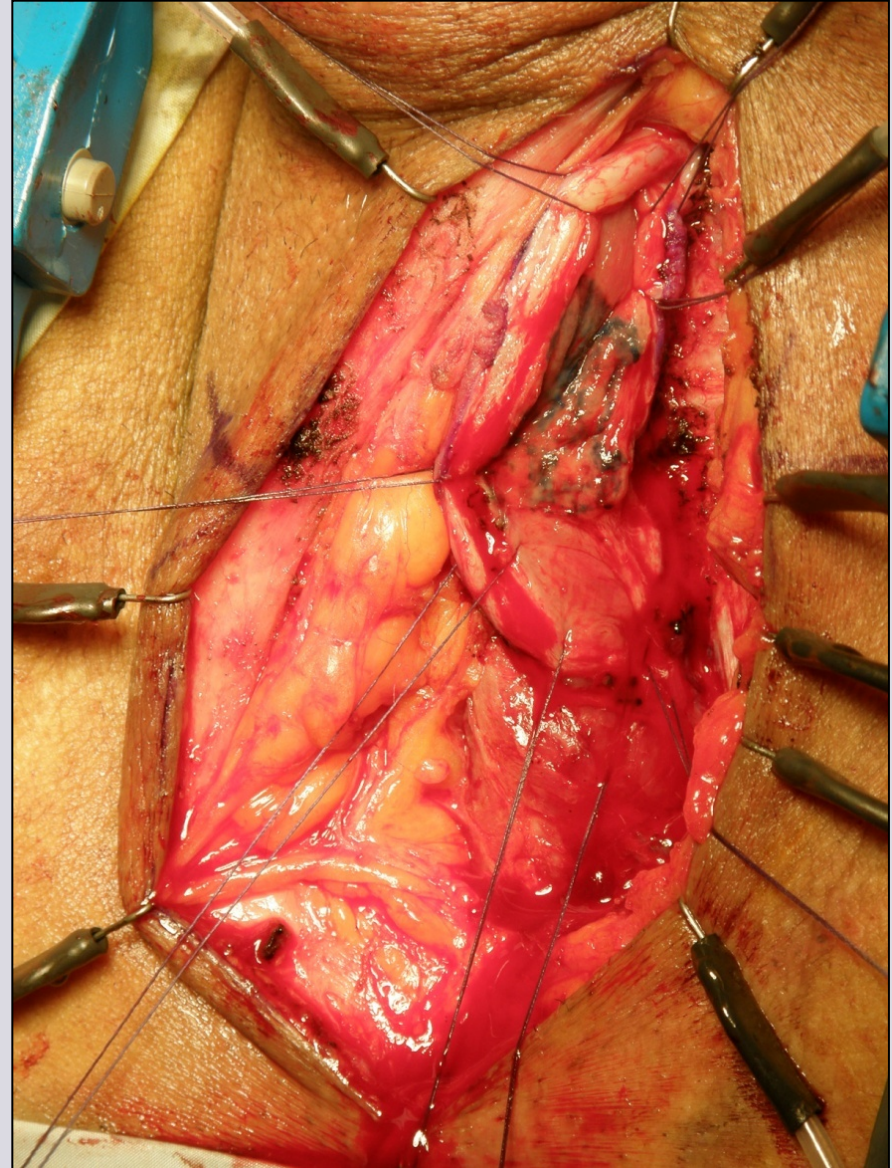
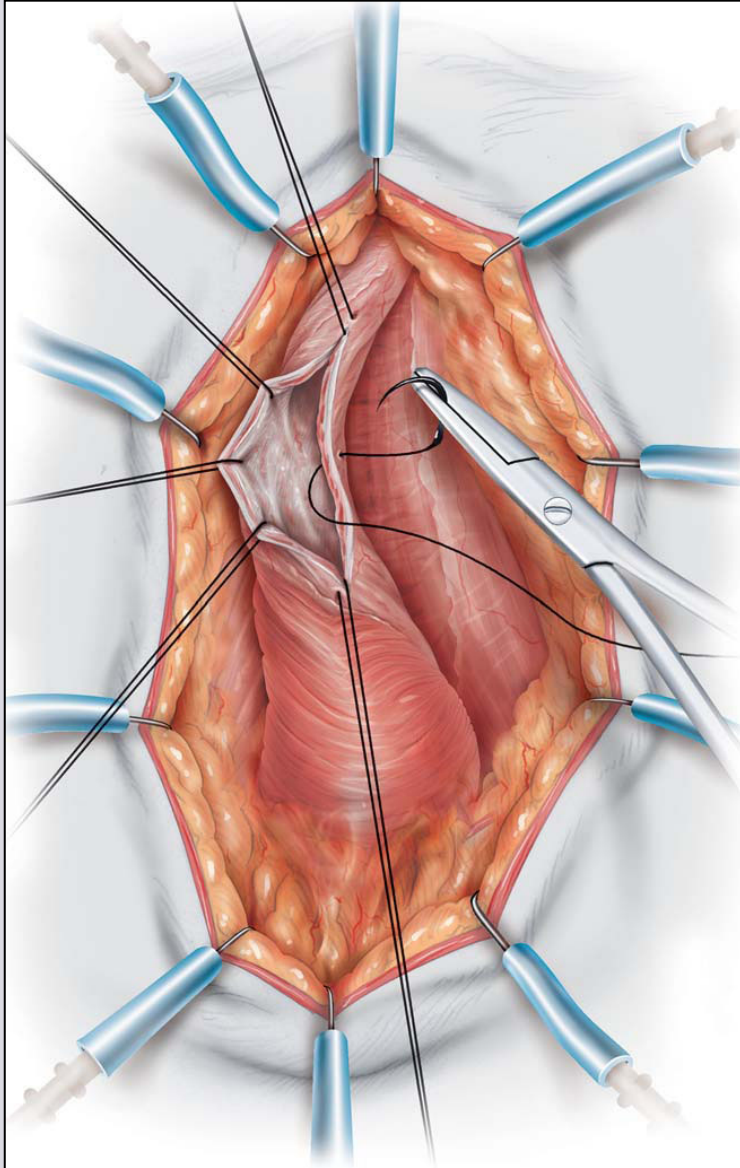
e-mail: info@urethralcenter.it

Websites: www.uretra.it
www.urethralcenter.it



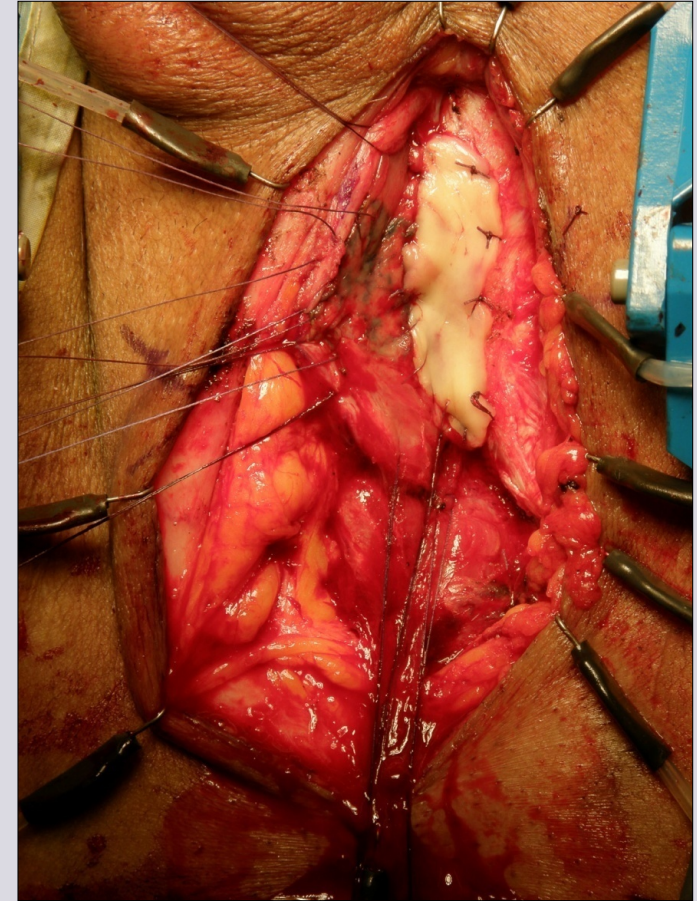
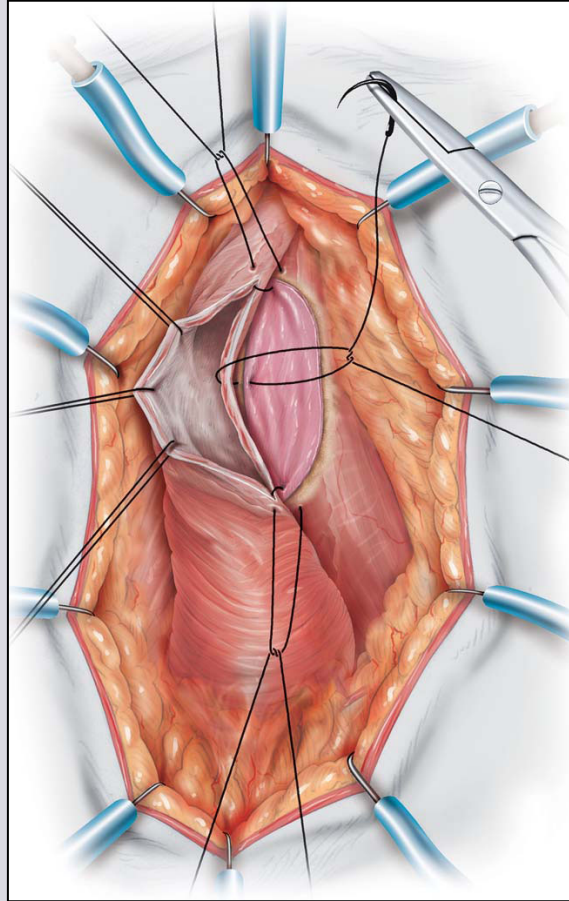
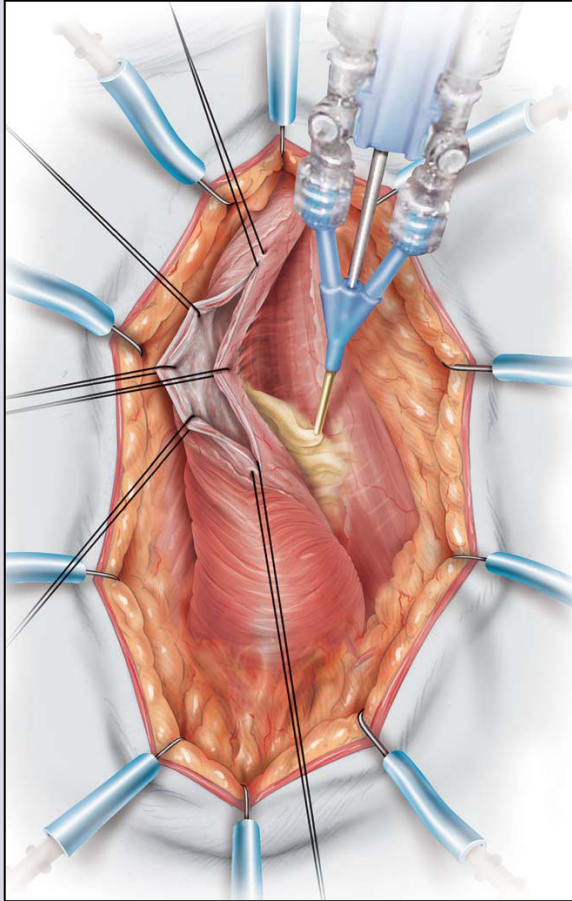
e-mail: info@urethralcenter.it

Websites: www.uretra.it
www.urethralcenter.it



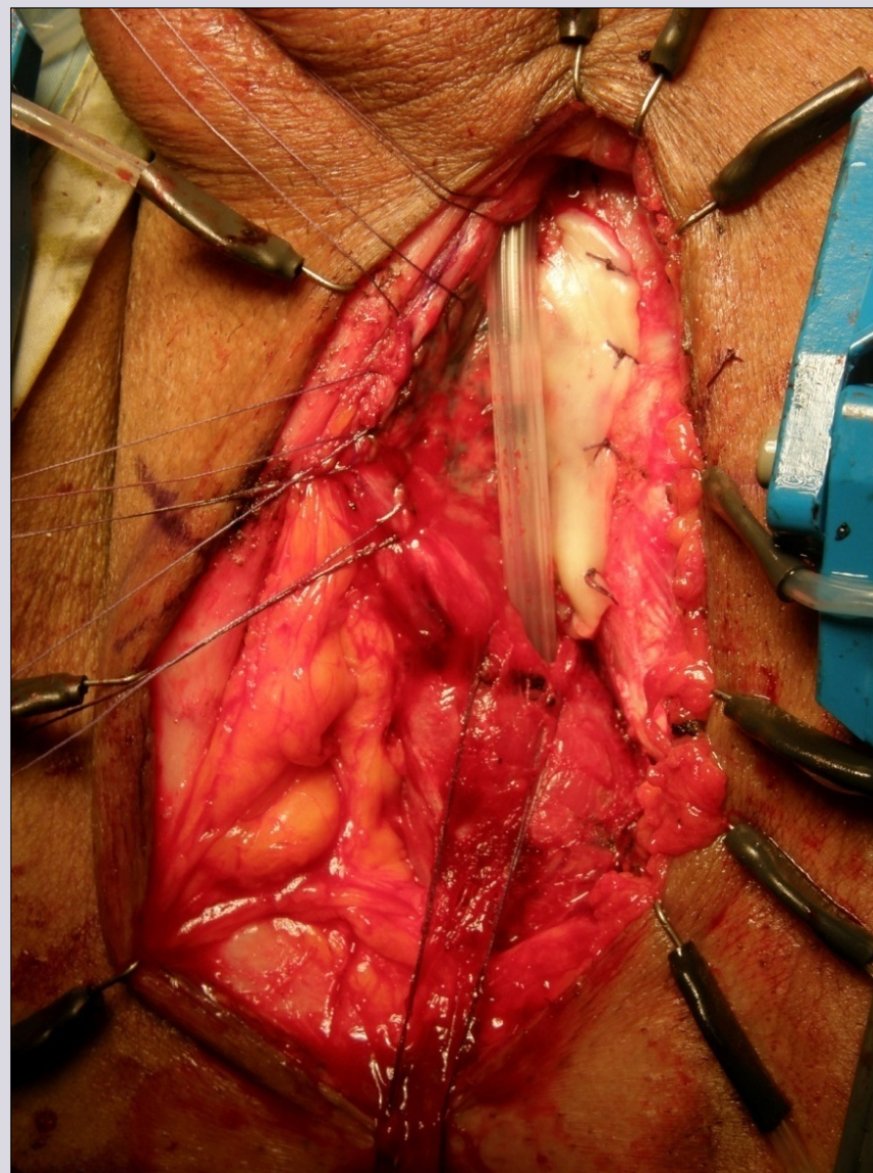
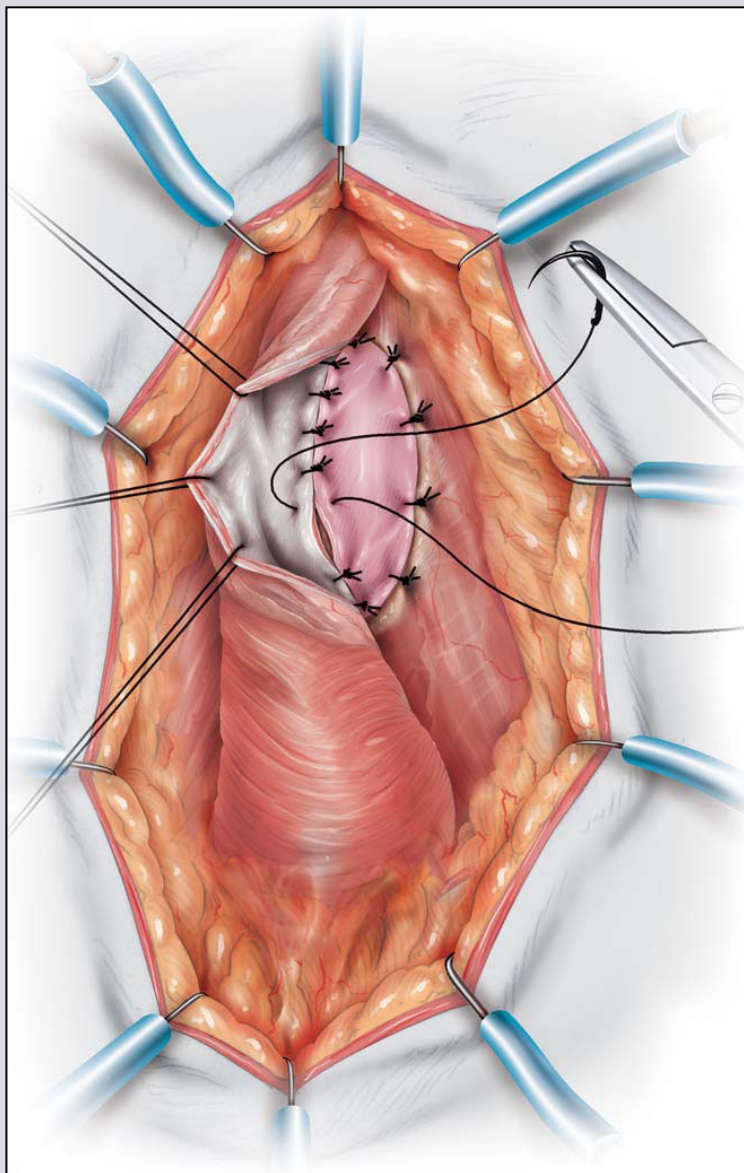
e-mail: info@urethralcenter.it

Websites: www.uretra.it
www.urethralcenter.it



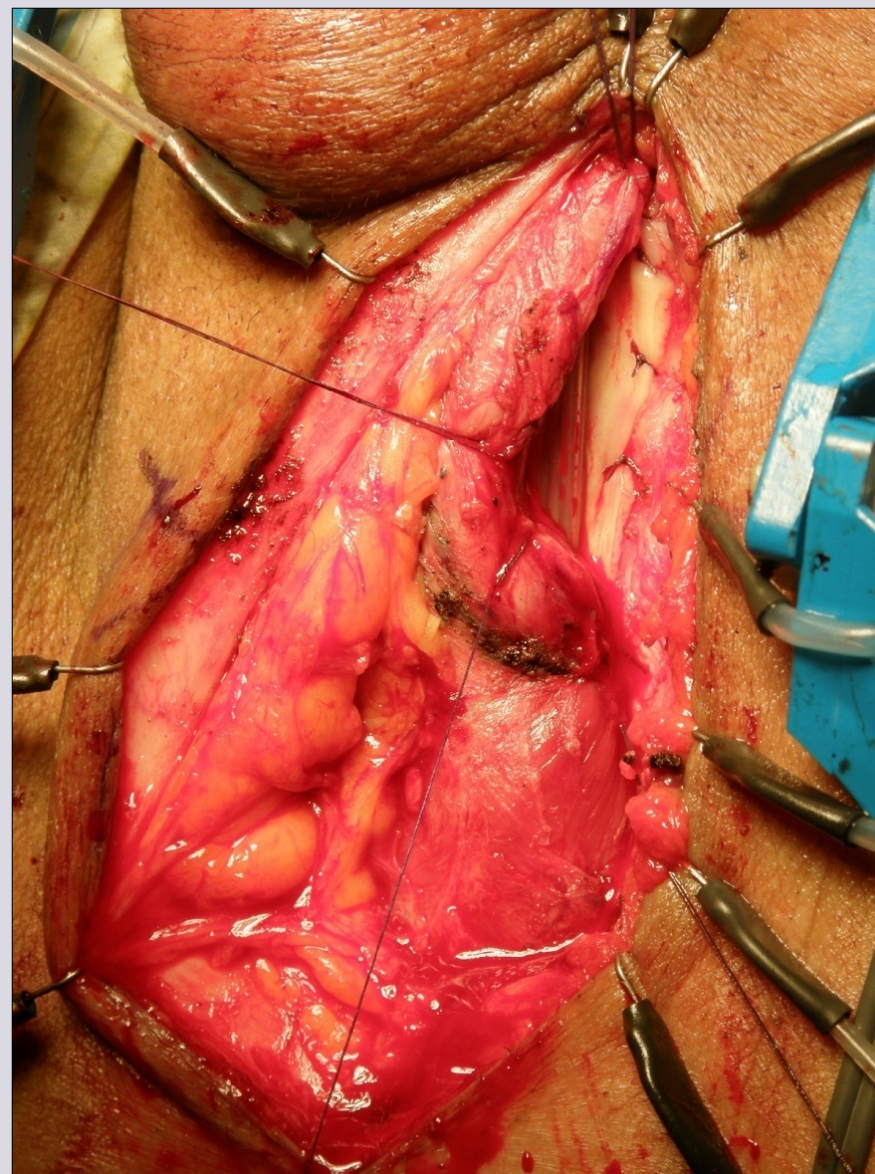
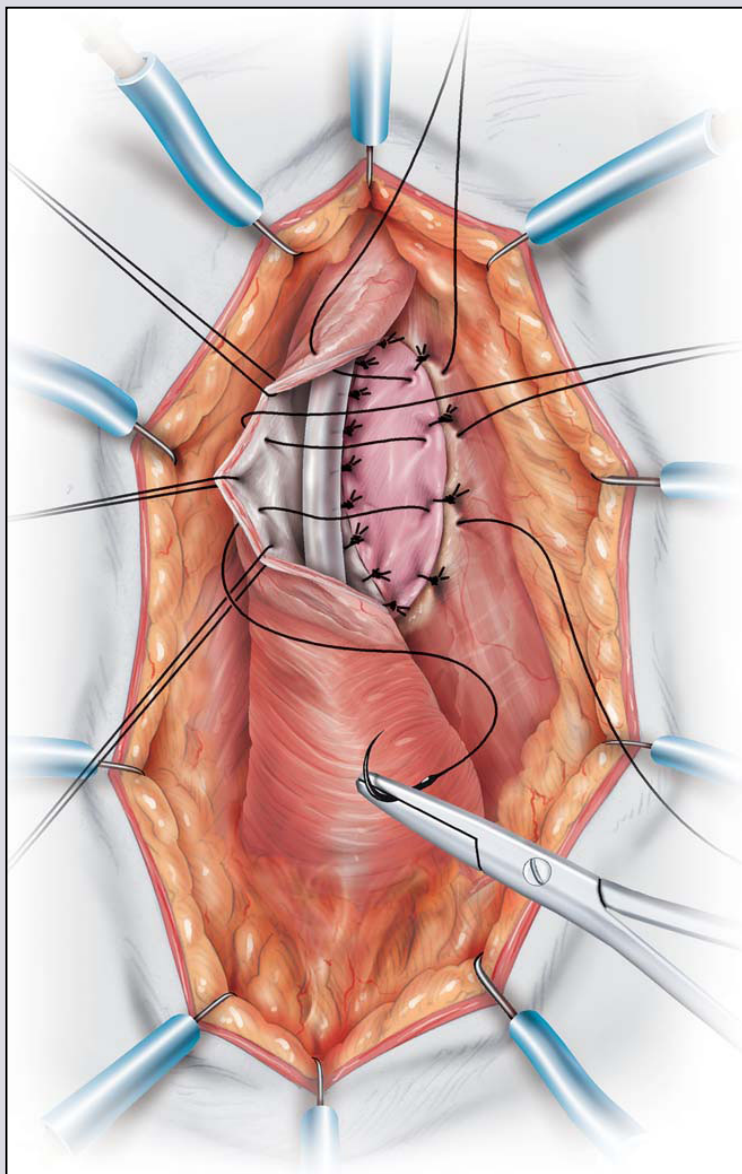
e-mail: info@urethralcenter.it

Websites: www.uretra.it
www.urethralcenter.it



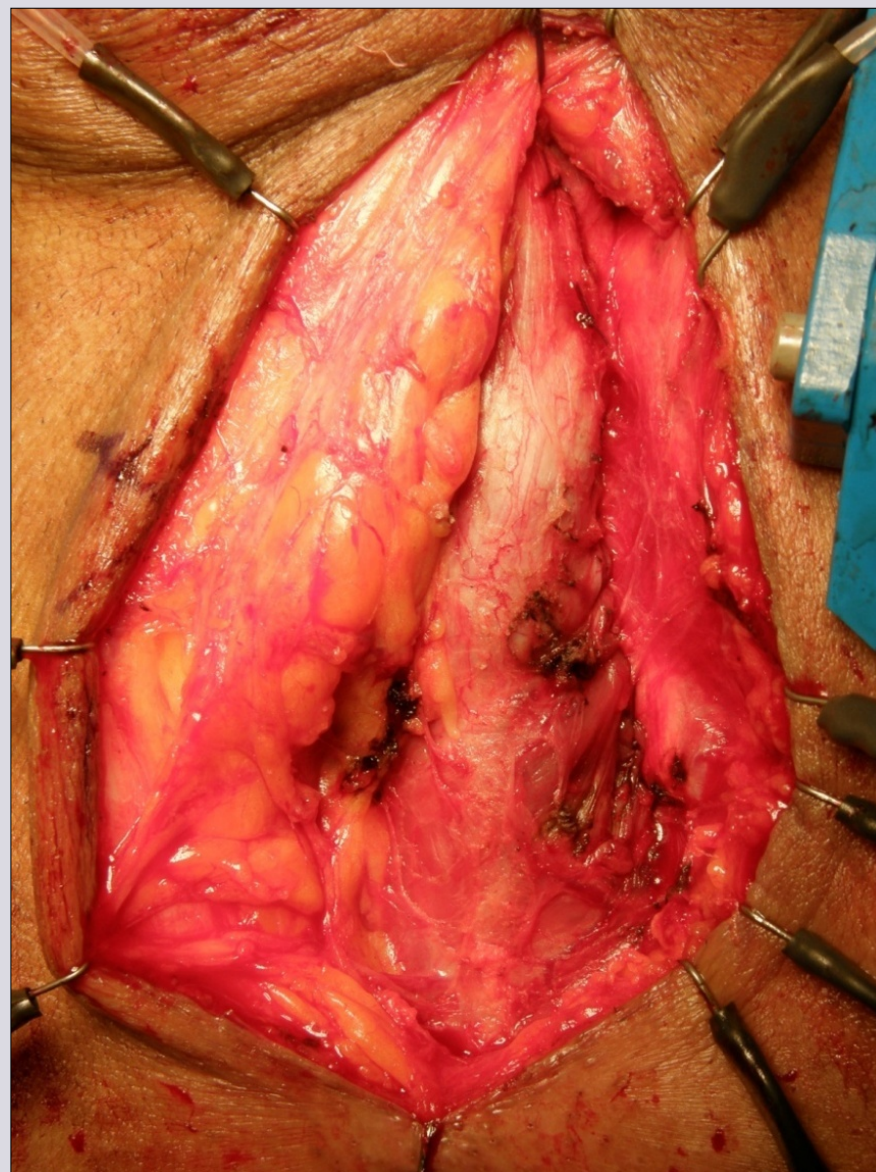
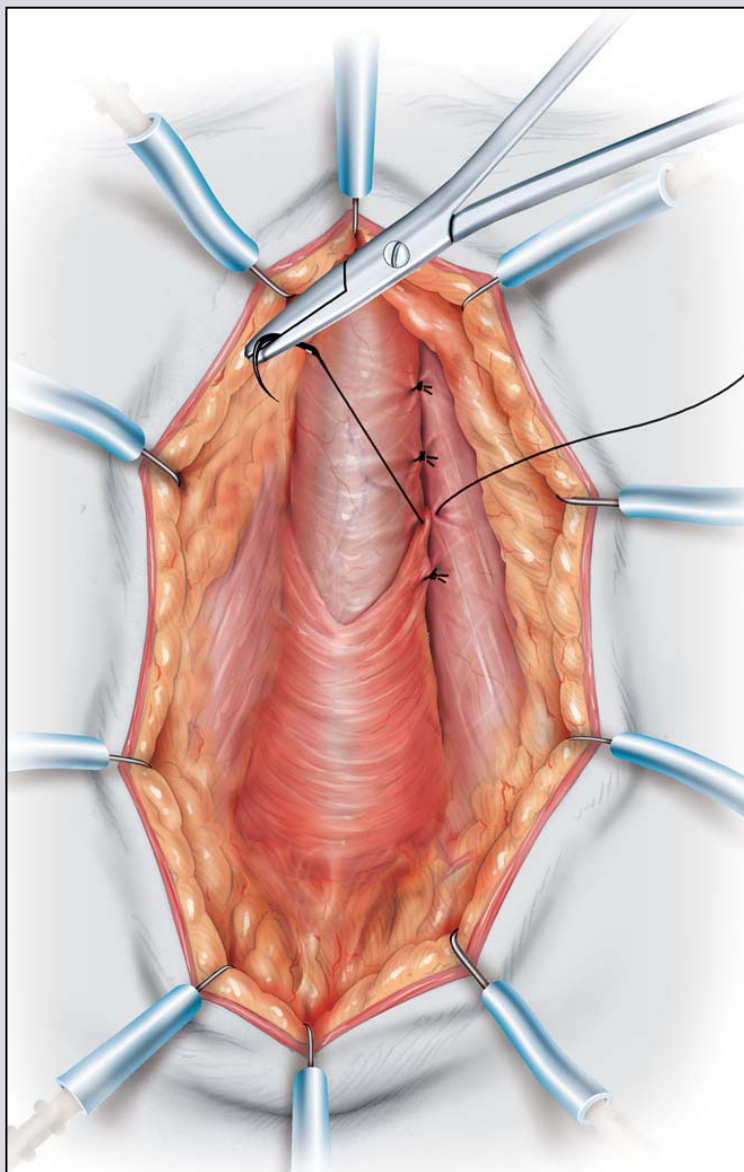
e-mail: info@urethralcenter.it

Websites: www.uretra.it
www.urethralcenter.it



e-mail: info@urethralcenter.it

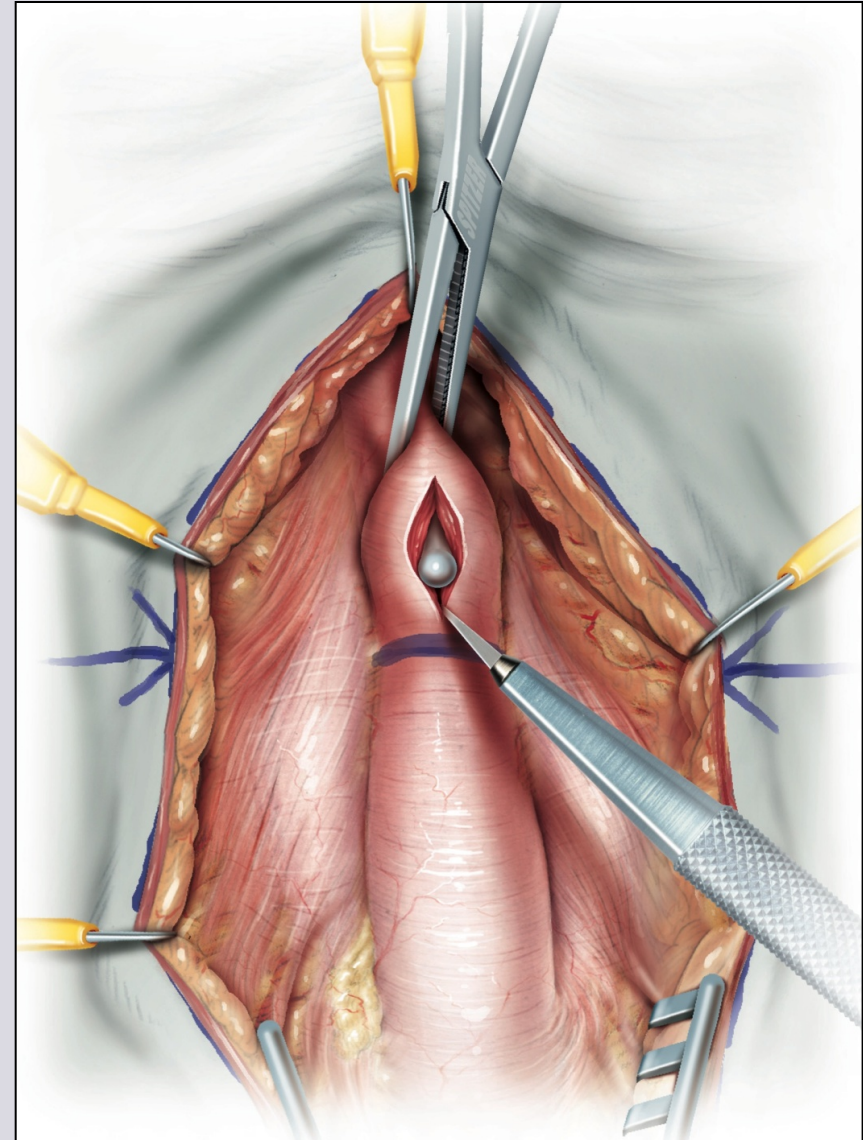
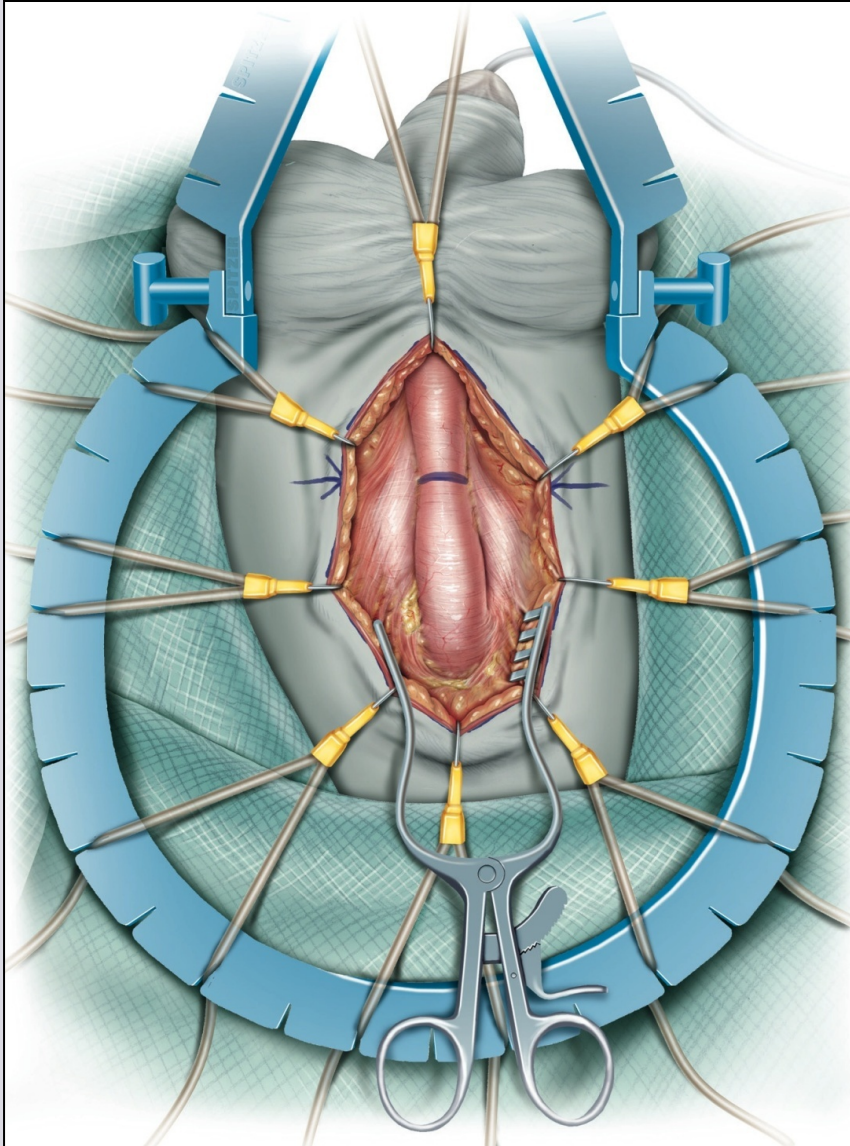
Websites: www.uretra.it
www.urethralcenter.it



e-mail: info@urethralcenter.it

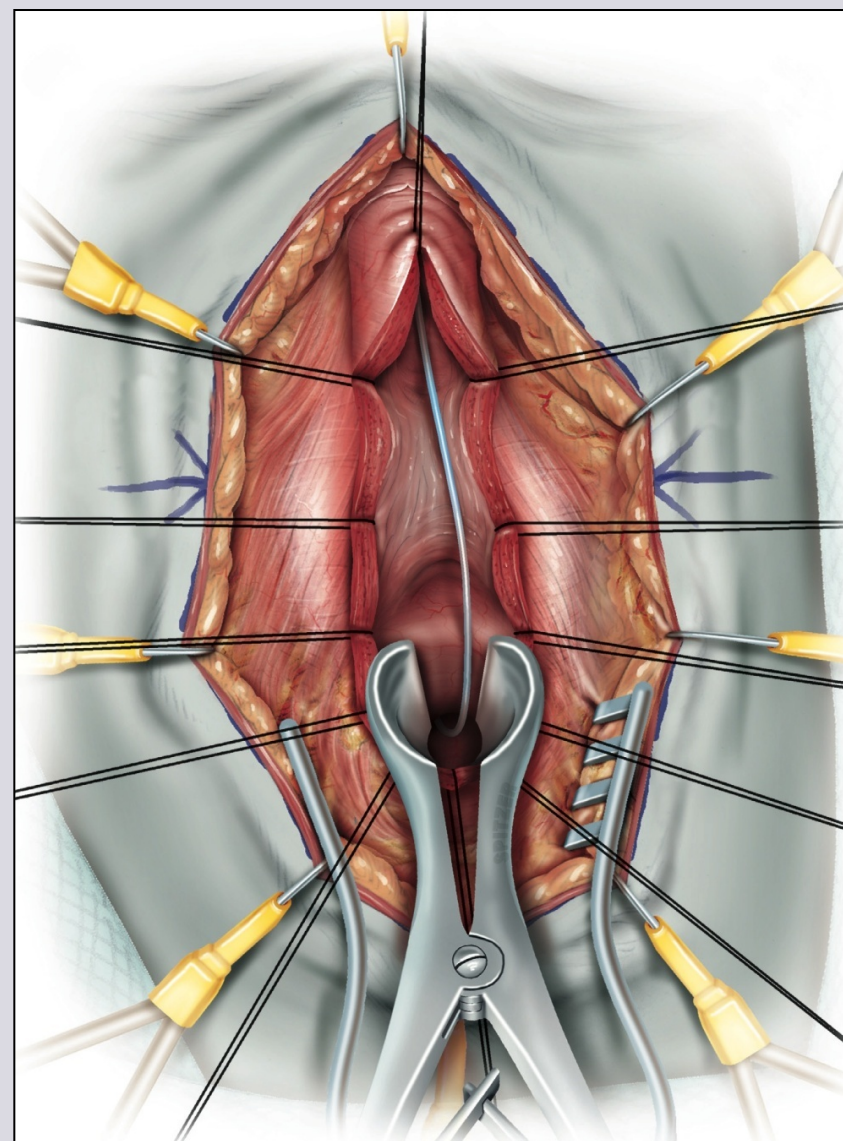
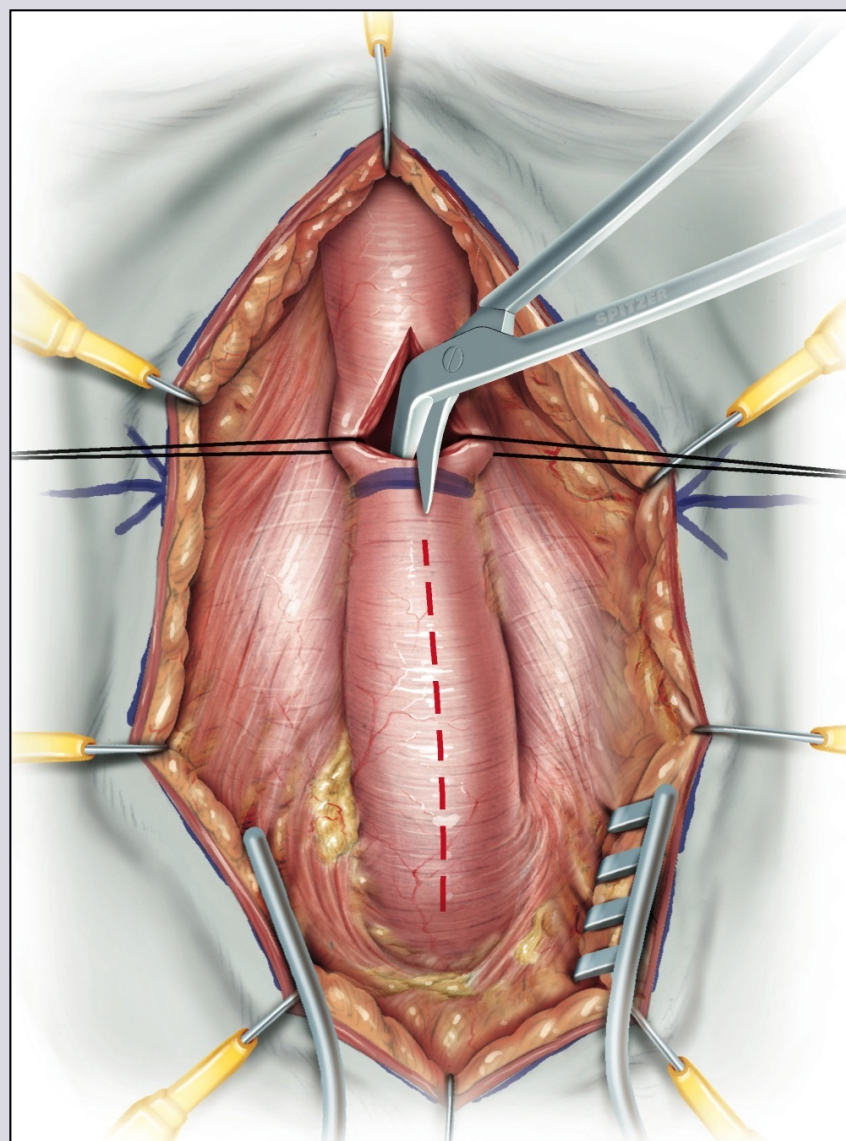
Websites: www.uretra.it
www.urethralcenter.it

**Reconstruction of the
bulbar urethra after
previous failed (dorsal or ventral)
onlay urethroplasty**



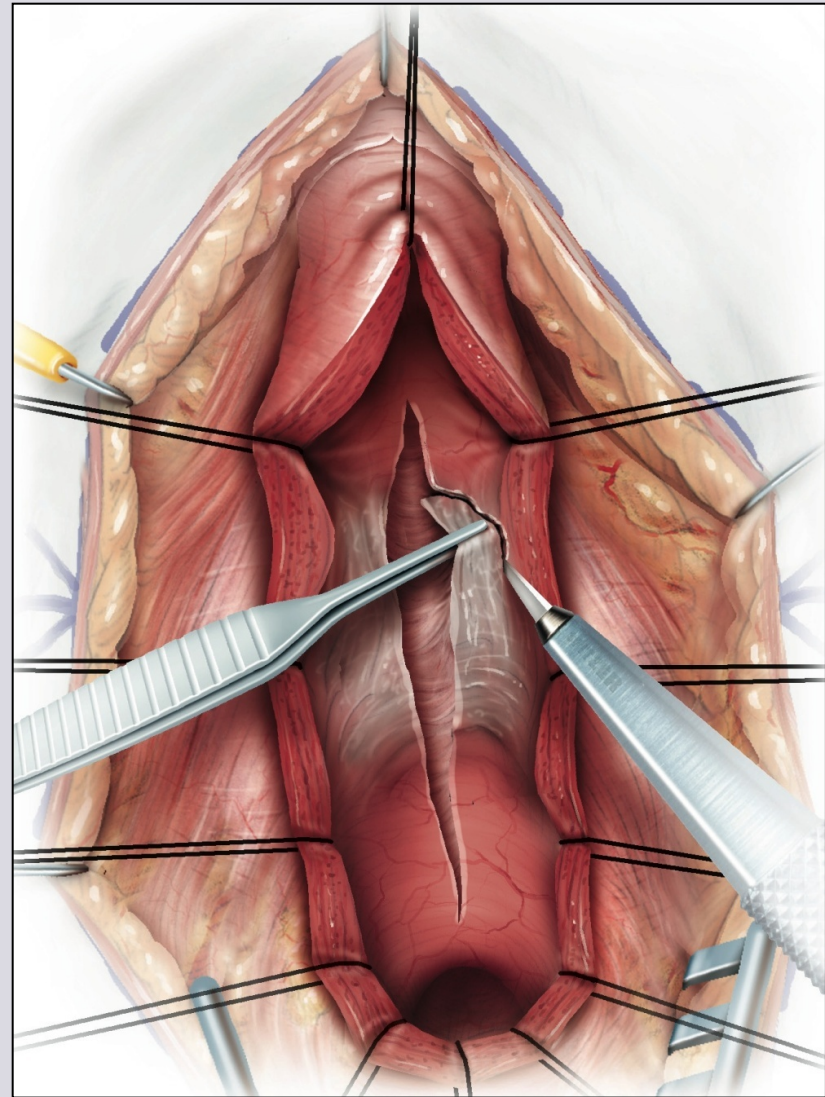
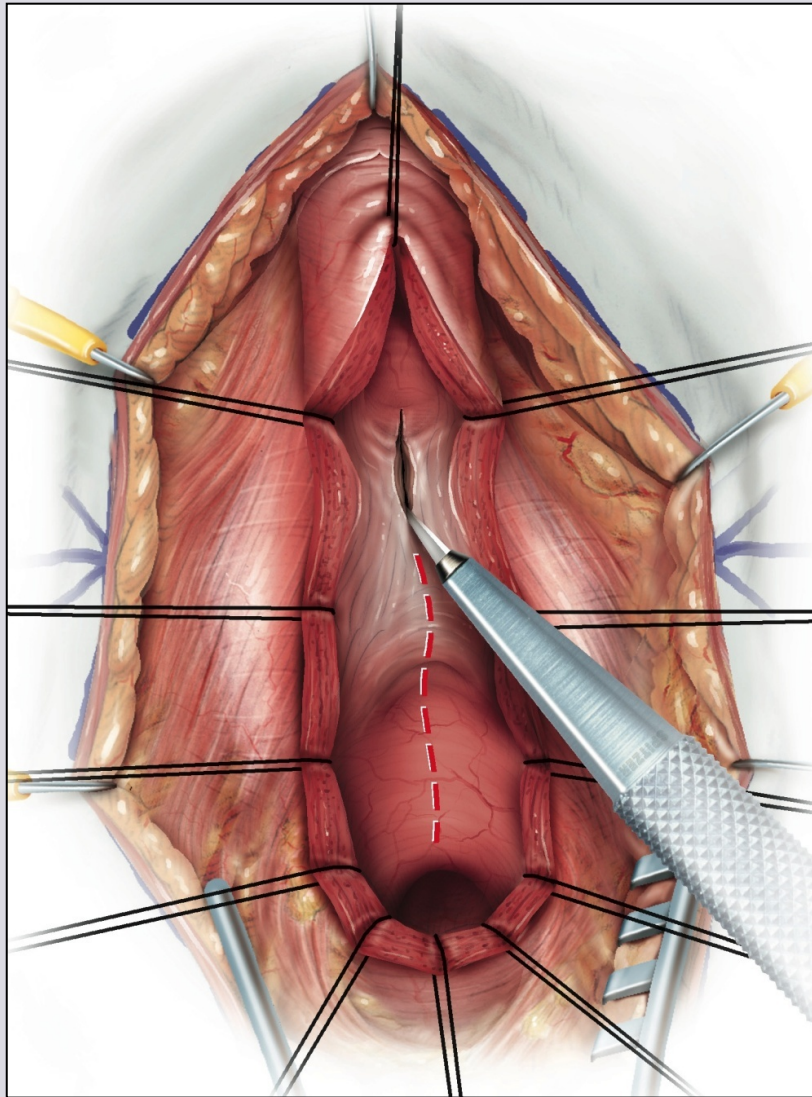
e-mail: info@urethralcenter.it

Websites: www.uretra.it
www.urethralcenter.it



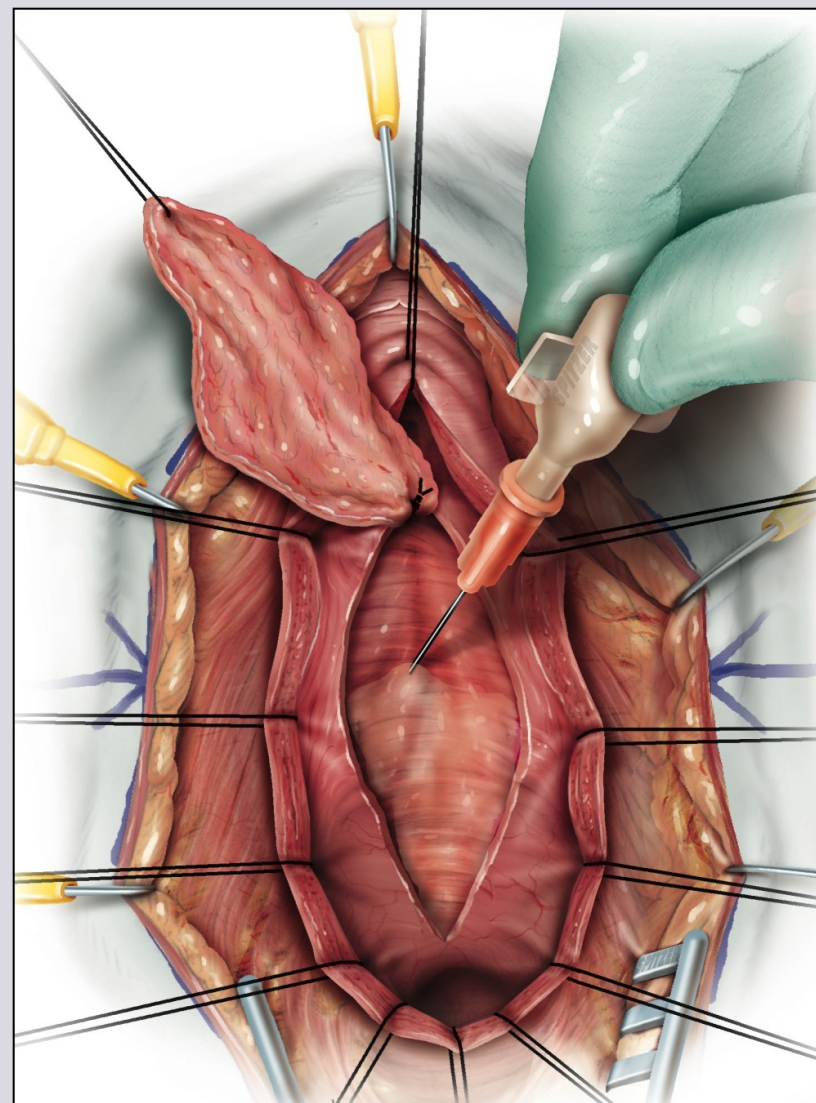
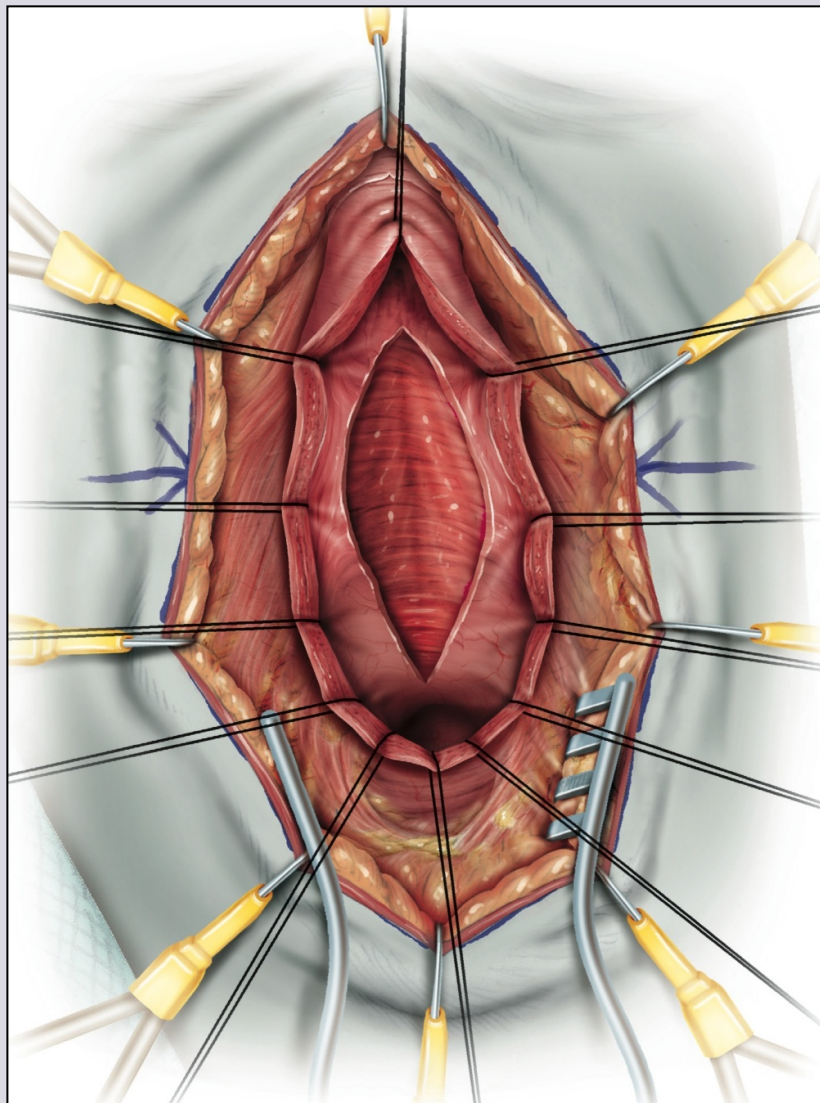
e-mail: info@urethralcenter.it

Websites: www.uretra.it
www.urethralcenter.it



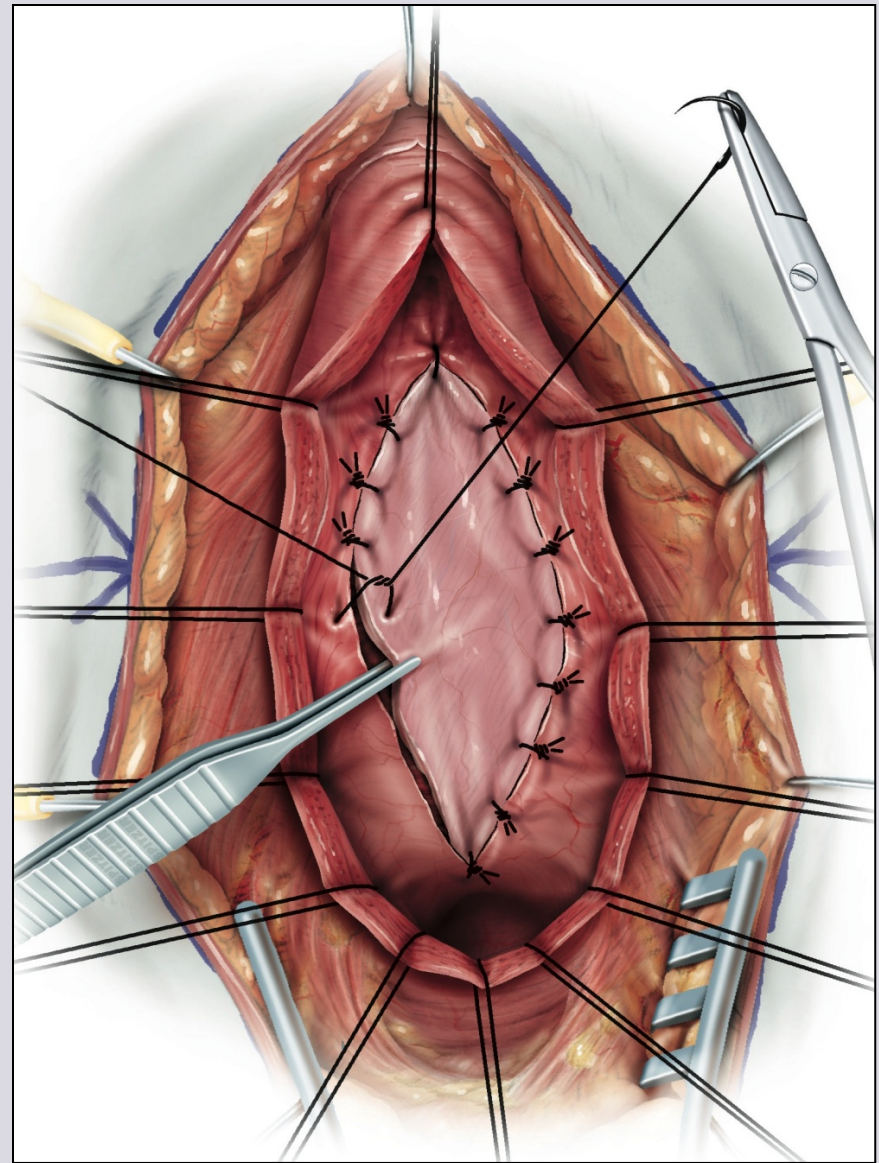
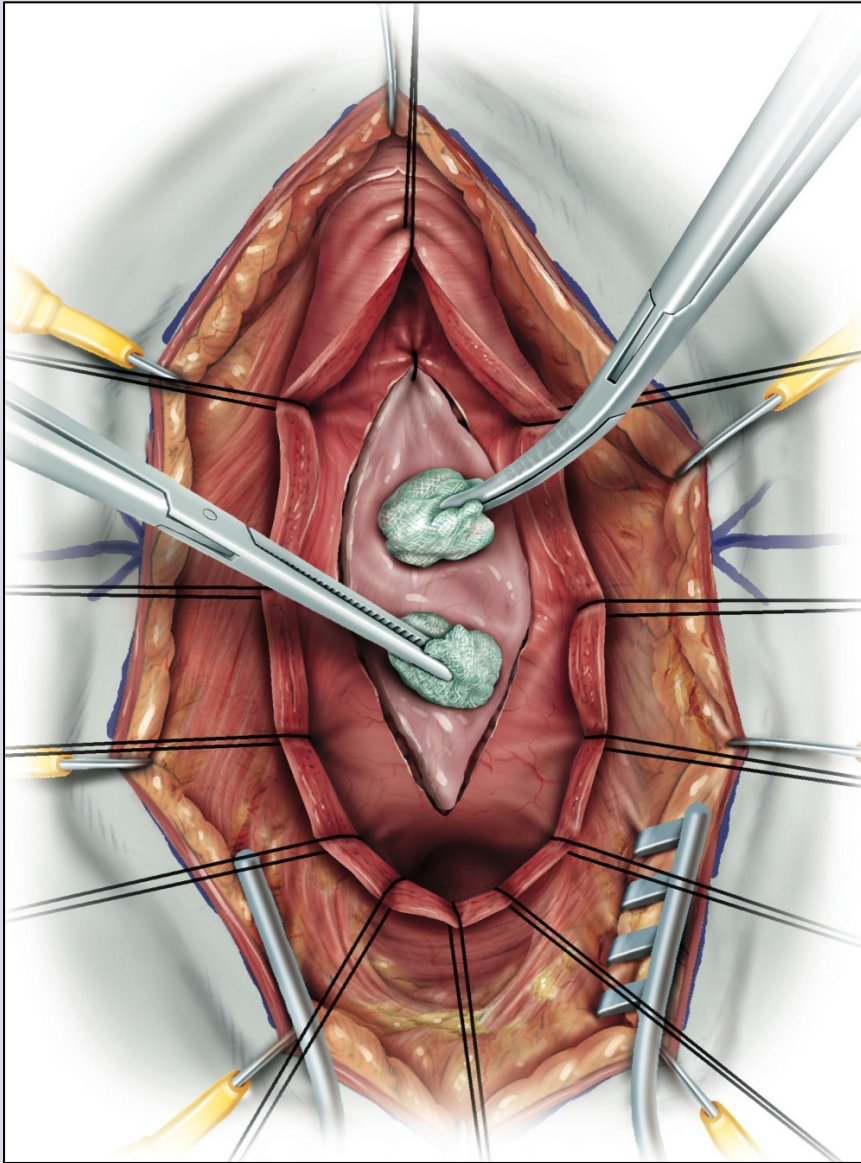
e-mail: info@urethralcenter.it

Websites: www.uretra.it
www.urethralcenter.it



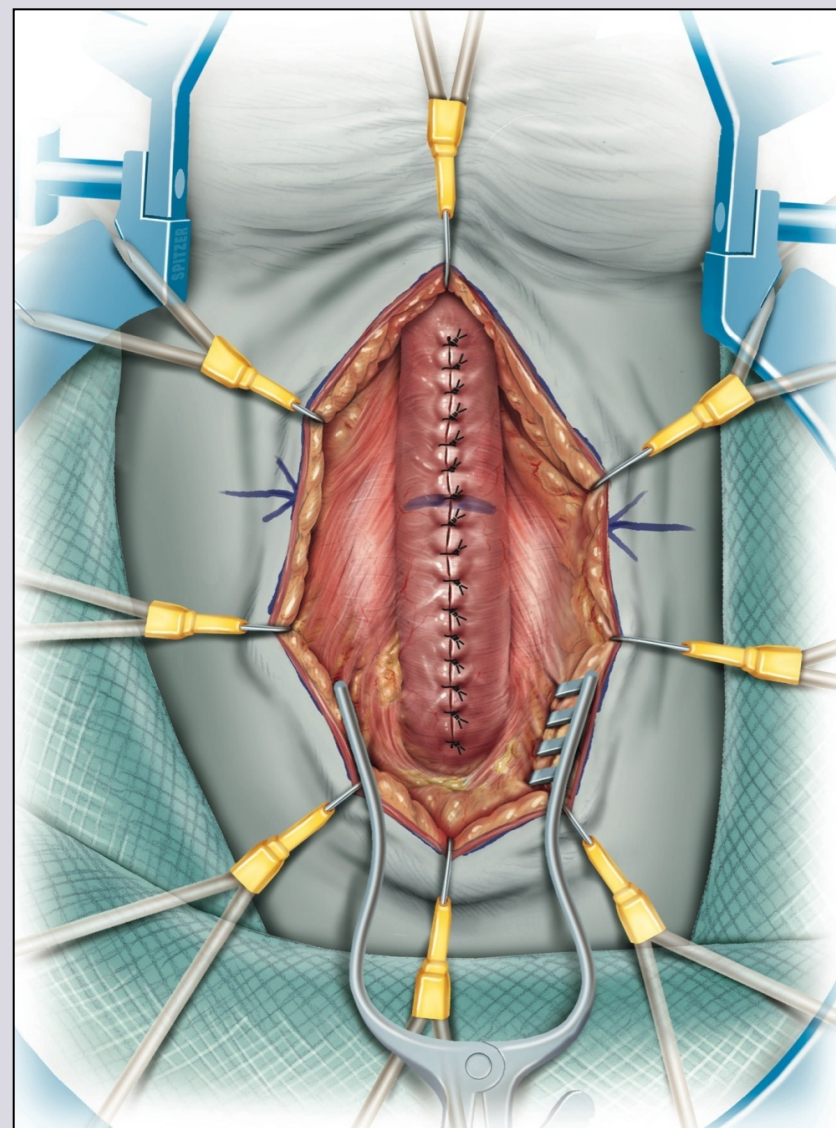
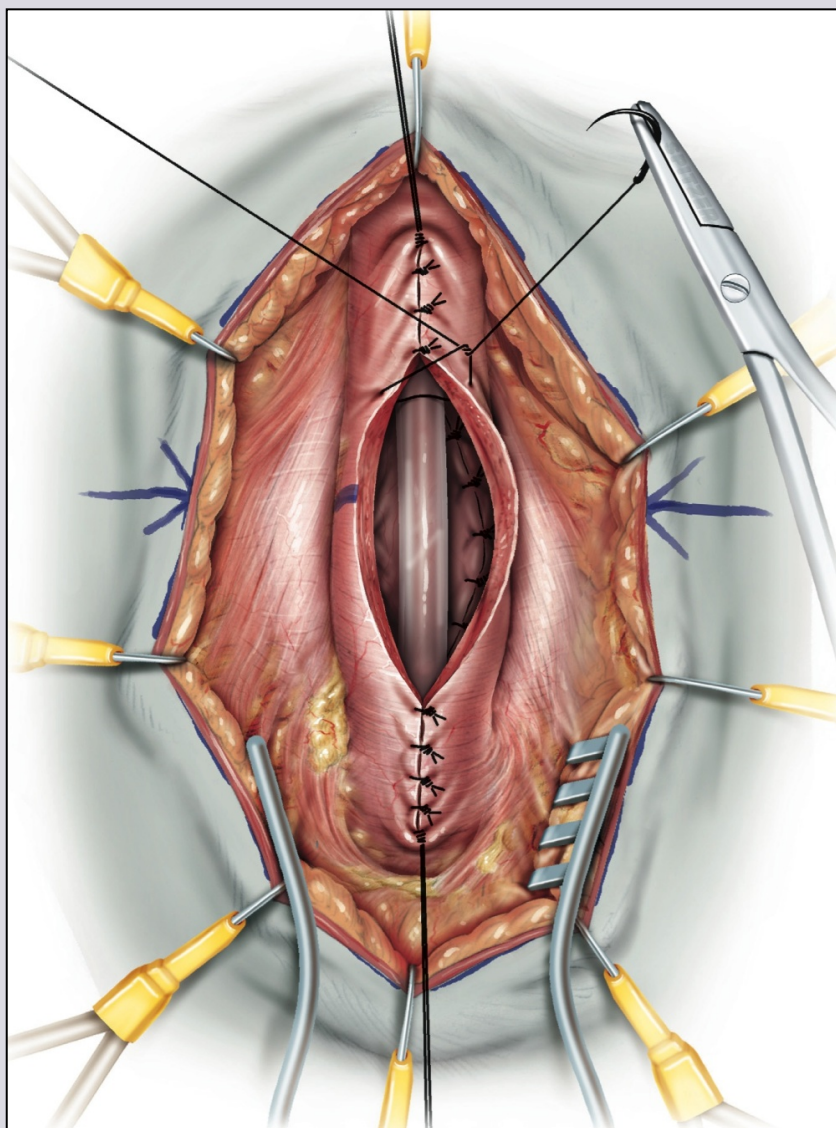
e-mail: info@urethralcenter.it

Websites: www.uretra.it
www.urethralcenter.it



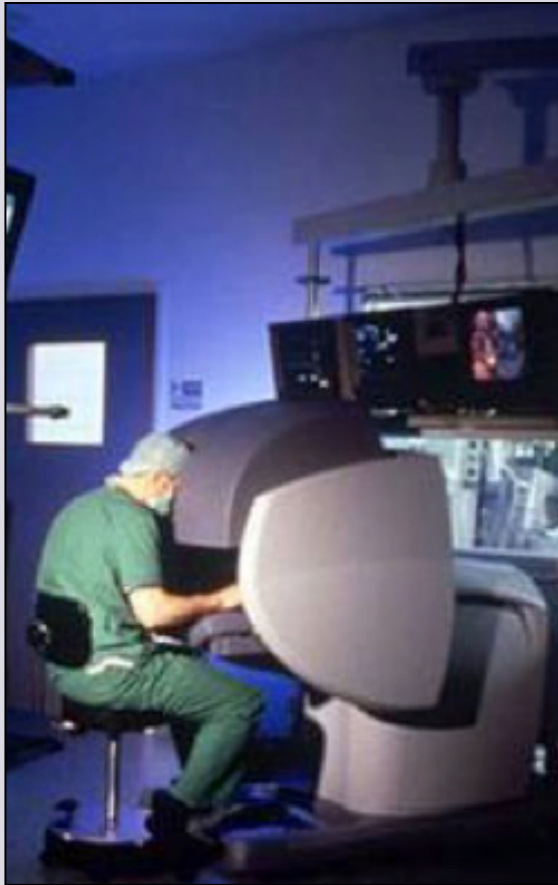e-mail: info@urethralcenter.it

Websites: www.uretra.it
www.urethralcenter.it



e-mail: info@urethralcenter.it

Websites: www.uretra.it
www.urethralcenter.it



Conclusions

In the era of robotic surgery, it is also time to change urethral surgery!

- ❖ Increase the use of minimally invasive techniques in urethroplasty, reducing the incidence of complications and improving patient quality of life.



Register now !

www.webon.uretra.it

e-mail: info@urethralcenter.it

Websites: www.uretra.it
www.urethralcenter.it