CENTER FOR RECONSTRUCTIVE URETHRAL SURGERY

GUIDO BARBAGLI, M.D.

Arezzo - Italy

e-mail: info@urethralcenter.it

Websites: www.uretra.it
www.urethralcenter.it



AUA Course

What's new in urethroplasty

Guido Barbagli, M.D. and Sanjay B. Kulkarni, M.D.

Bulbar urethral stricture

Traumatic

No traumatic

Reconstruction of the bulbar urethra in traumatic stricture

Etiology of bulbar urethral stricture

Trauma



Idiophatic

Instrumentation

Catheter

Infection

Other

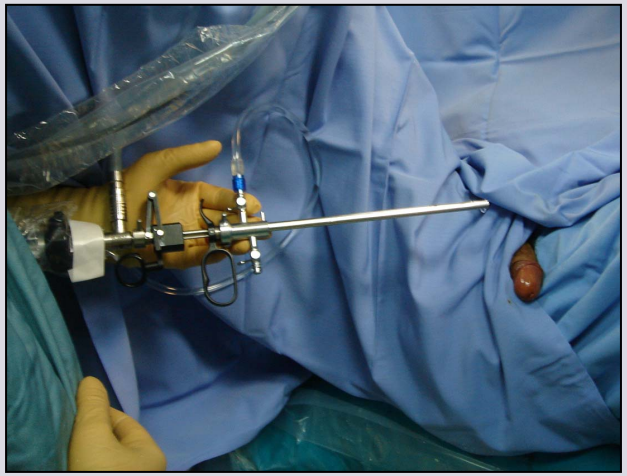

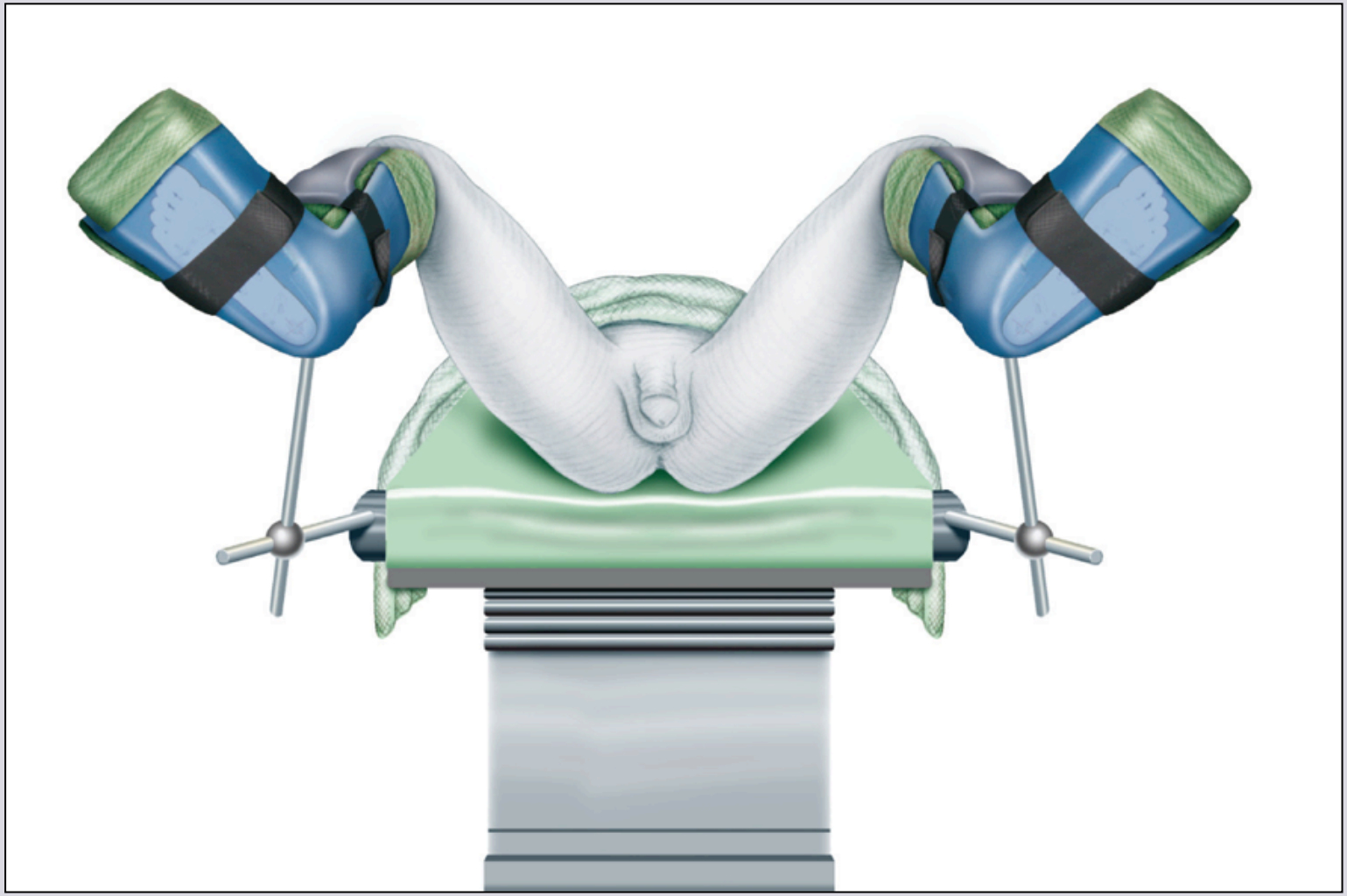

Simple lithotomy position

Allen stirrups

Sequential inflatable compression sleeves

Traumatic bulbar urethral stricture

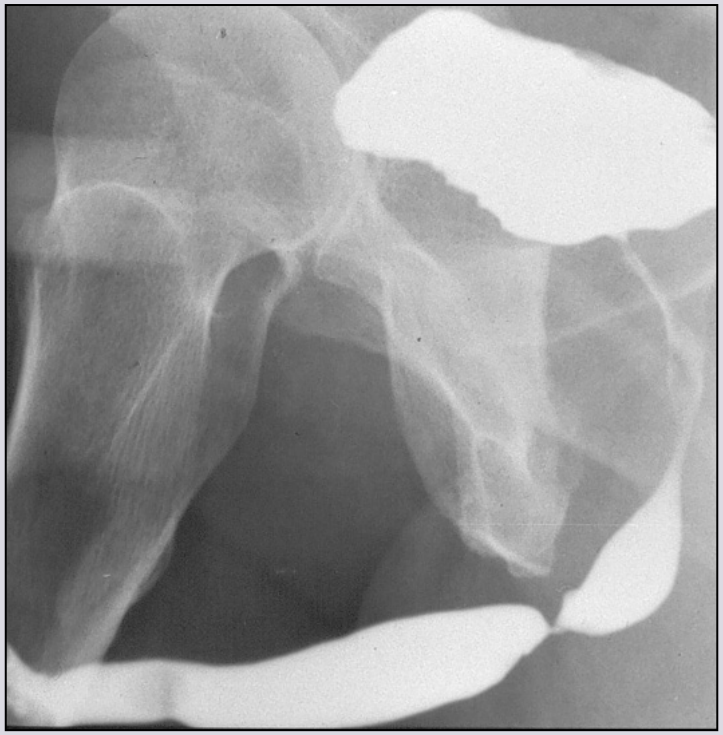

1. Obliterative stricture
2. No practicable urethral plate
3. Scar tissue
4. Short or long fibrous gap

1 - 2 cm traumatic bulbar urethral stricture

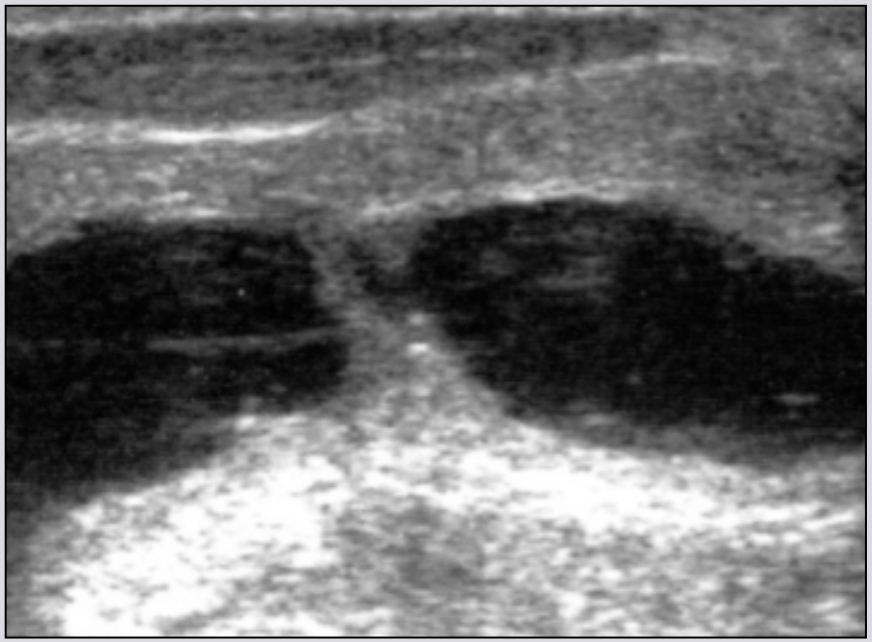

End-to-end anastomosis

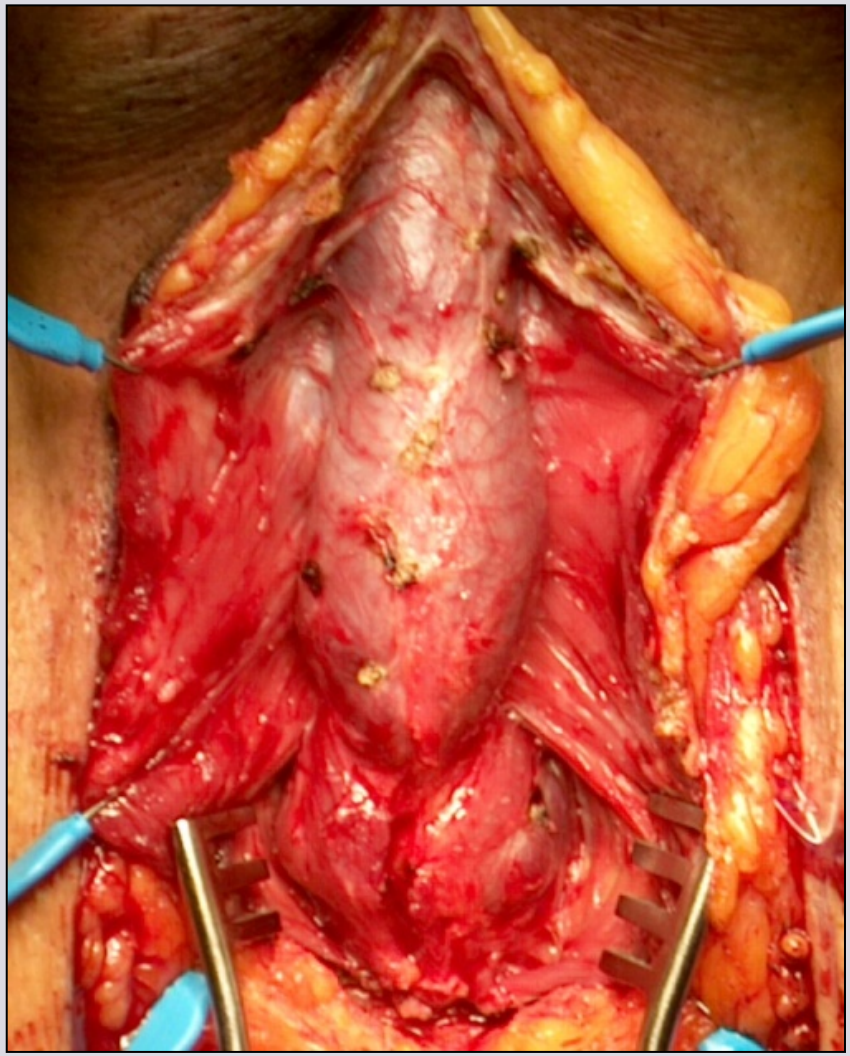

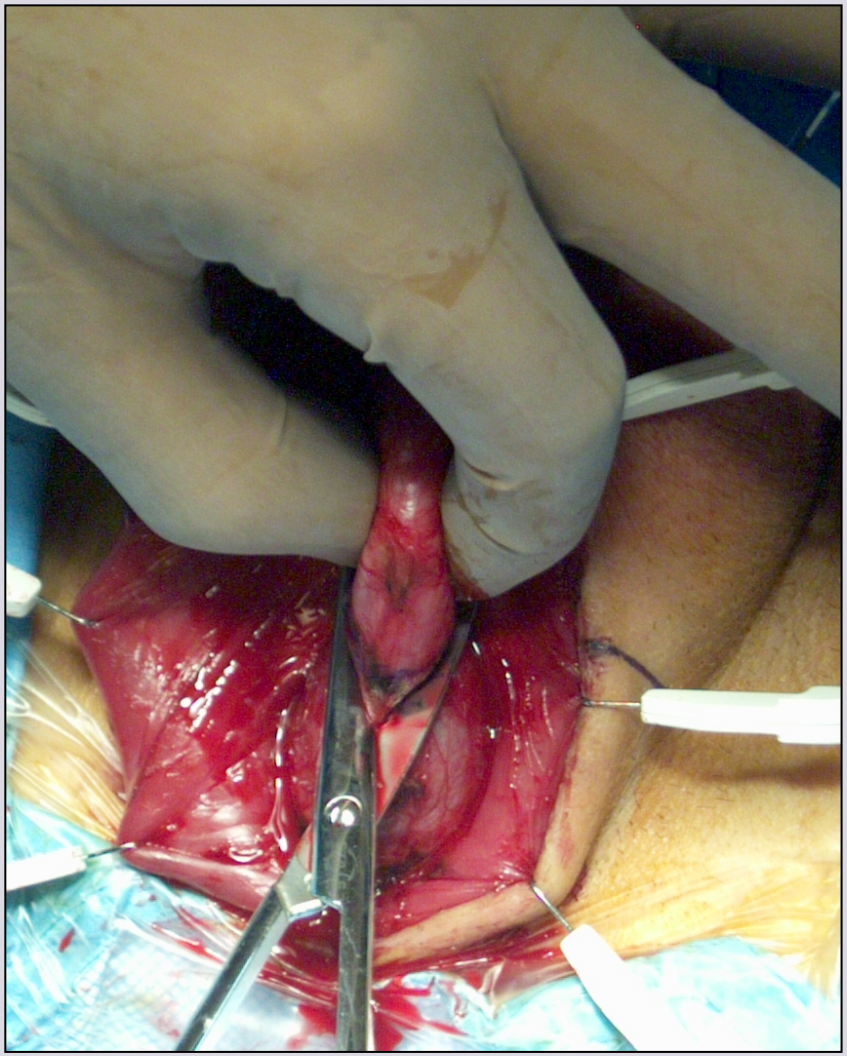

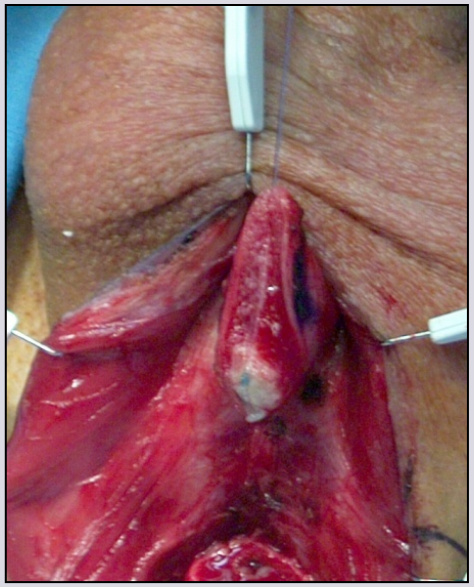

distal end

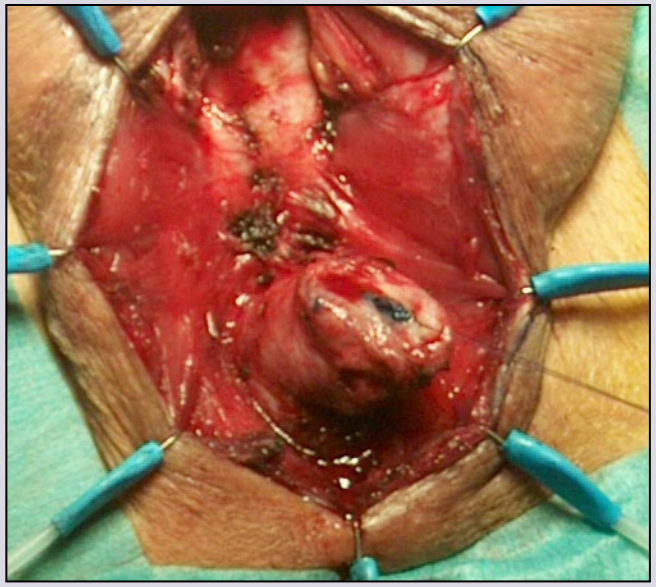

proximal end

e-mail: info@urethralcenter.it

Websites: www.uretra.it
www.urethralcenter.it

CENTER FOR RECONSTRUCTIVE URETHRAL SURGERY

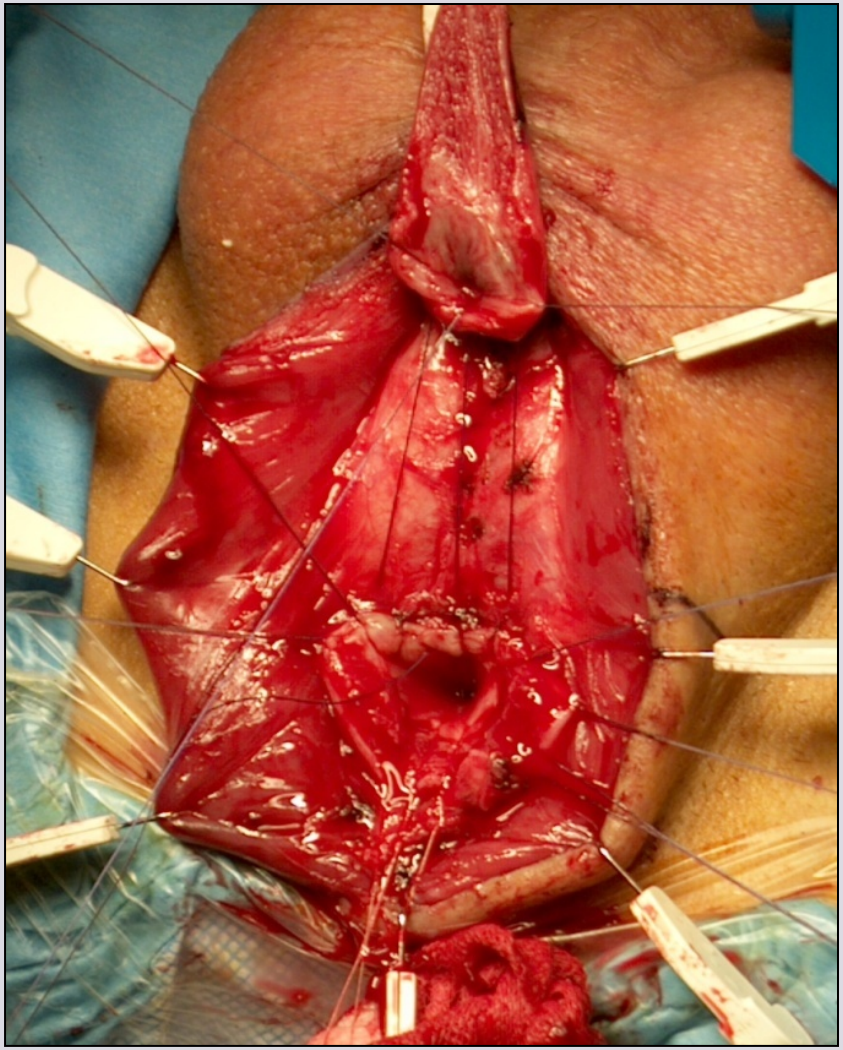

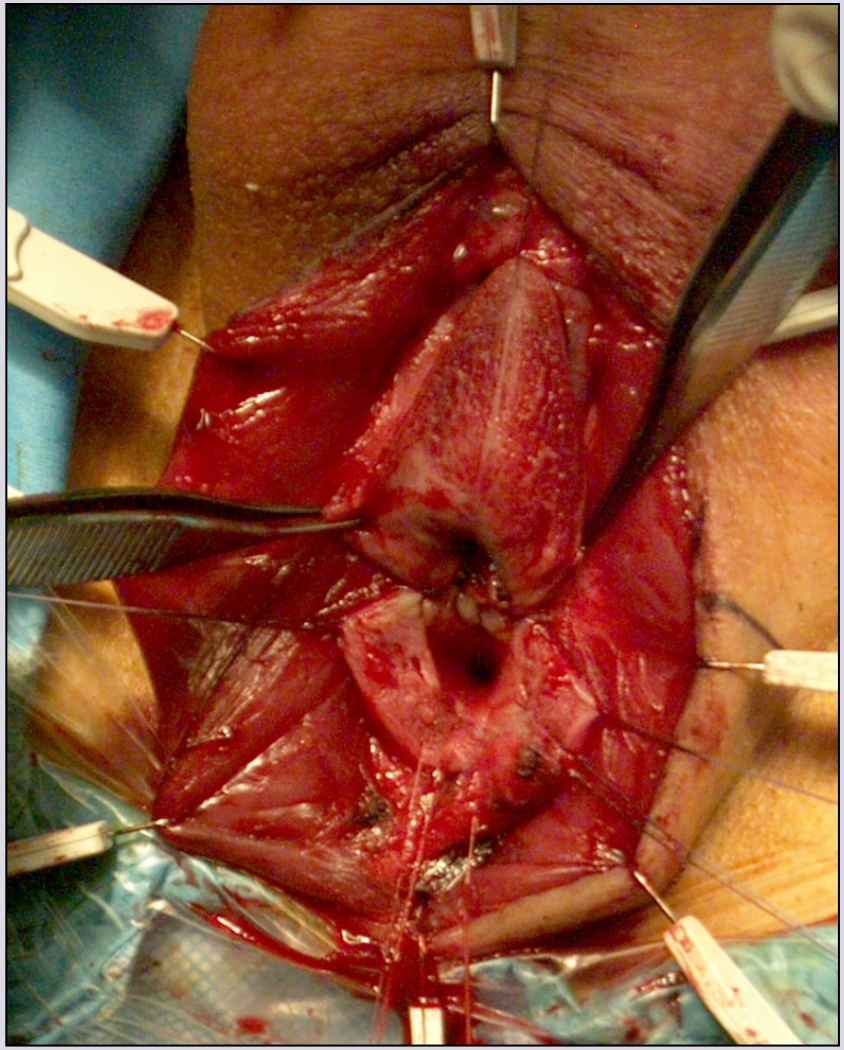

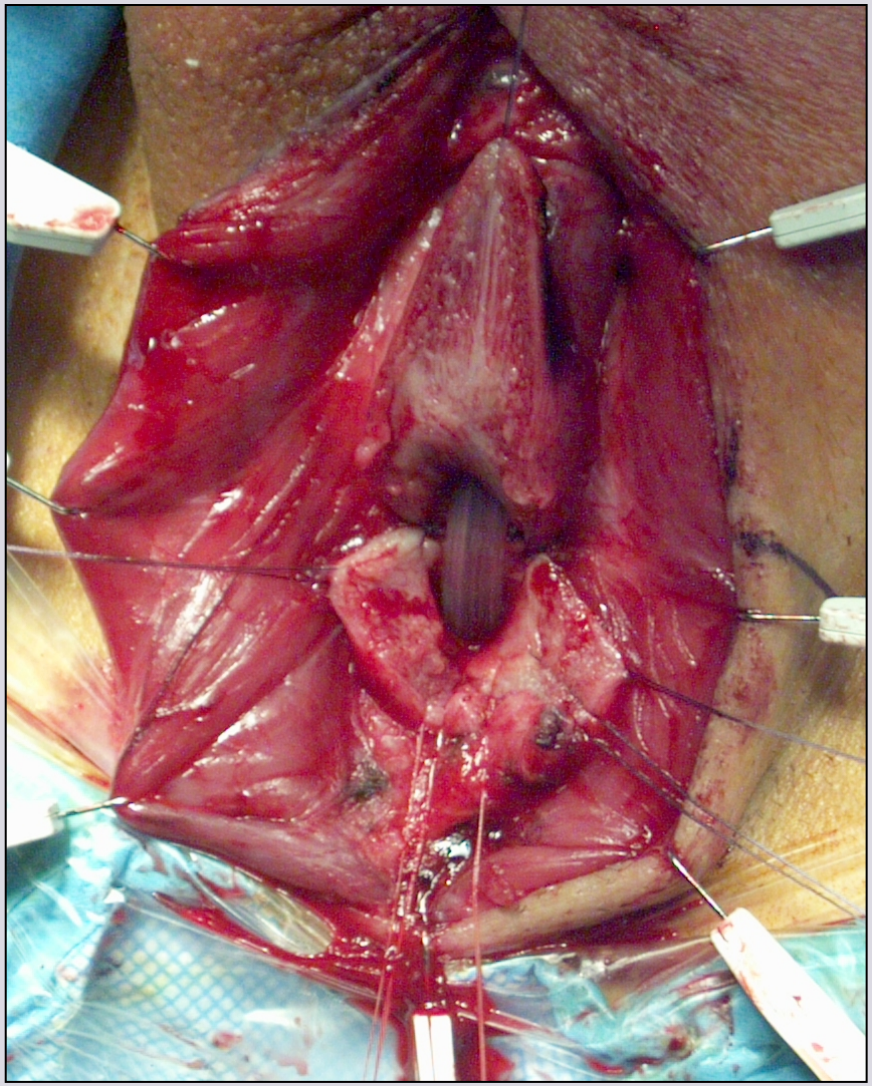

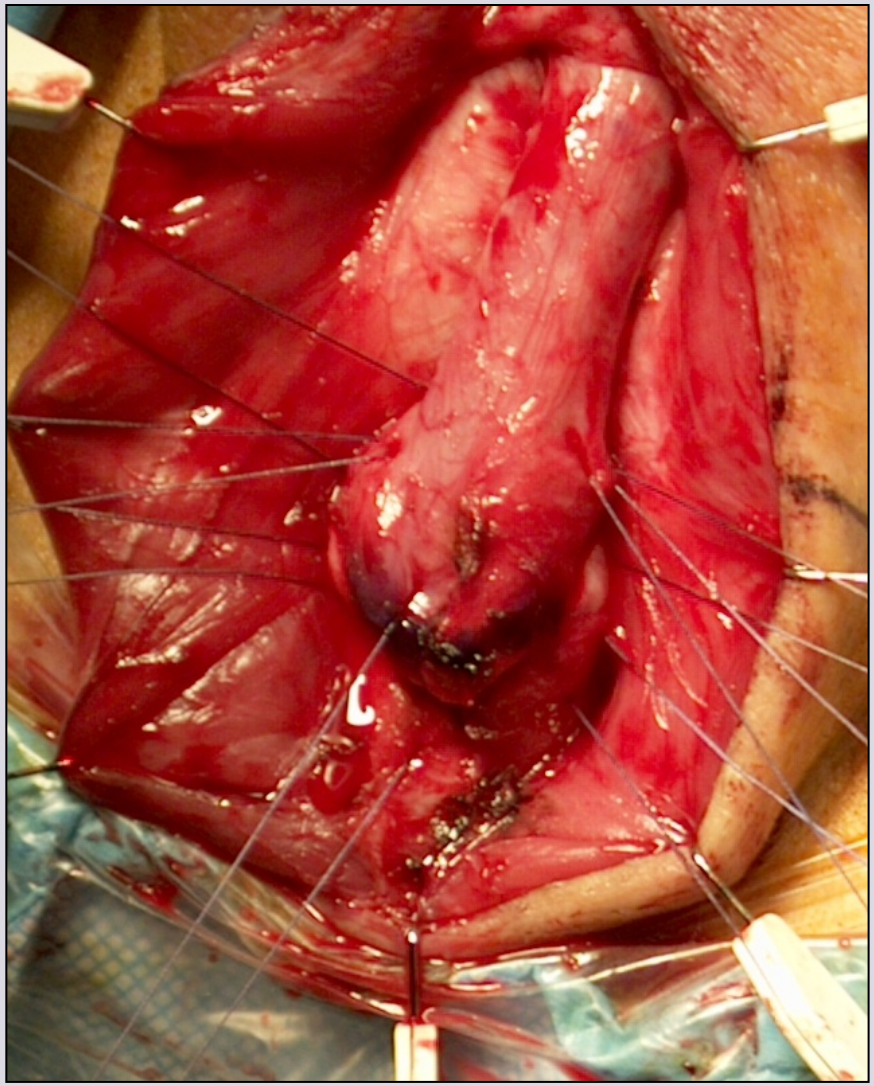

e-mail: info@urethralcenter.it

Websites: www.uretra.it
www.urethralcenter.it

CENTER FOR RECONSTRUCTIVE URETHRAL SURGERY

2 - 4 cm traumatic bulbar urethral stricture

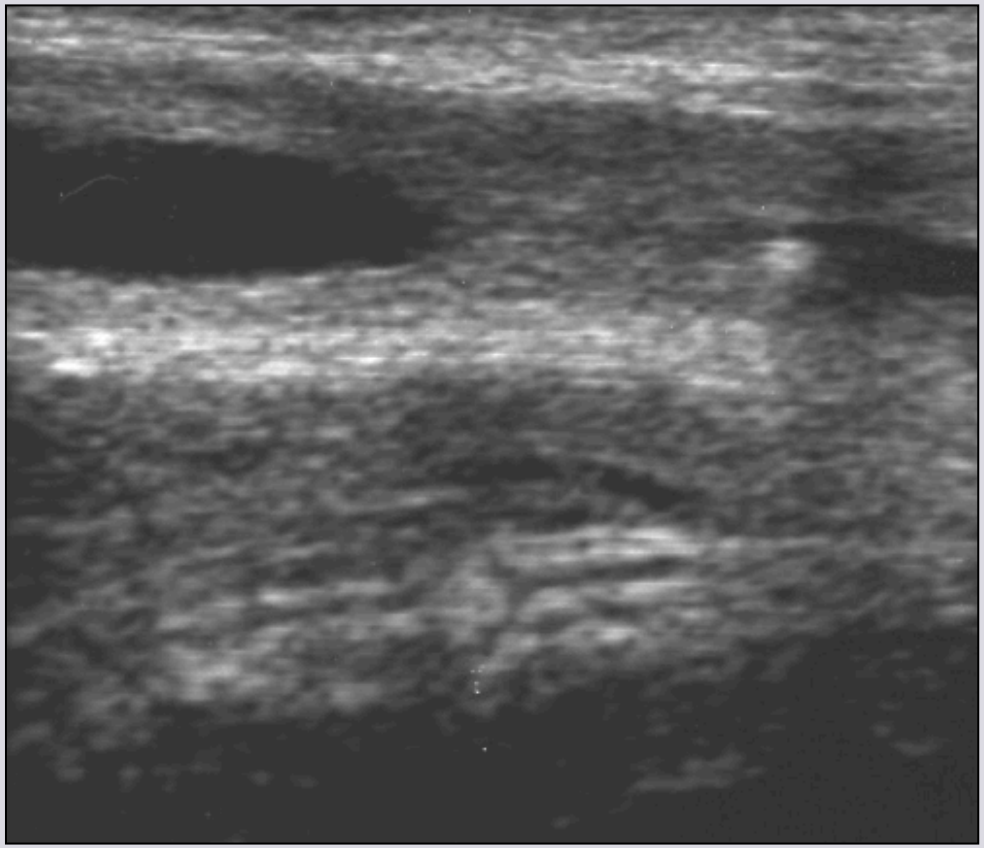

Augmented anastomotic repair

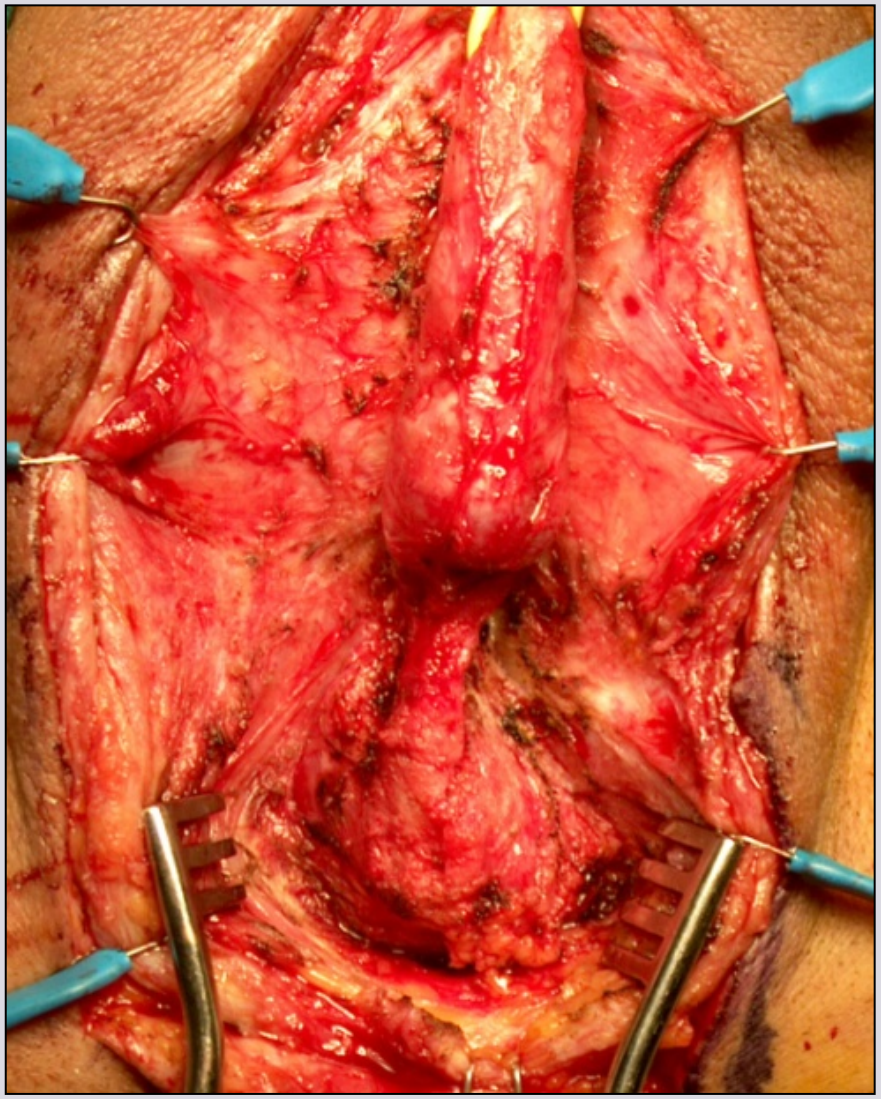

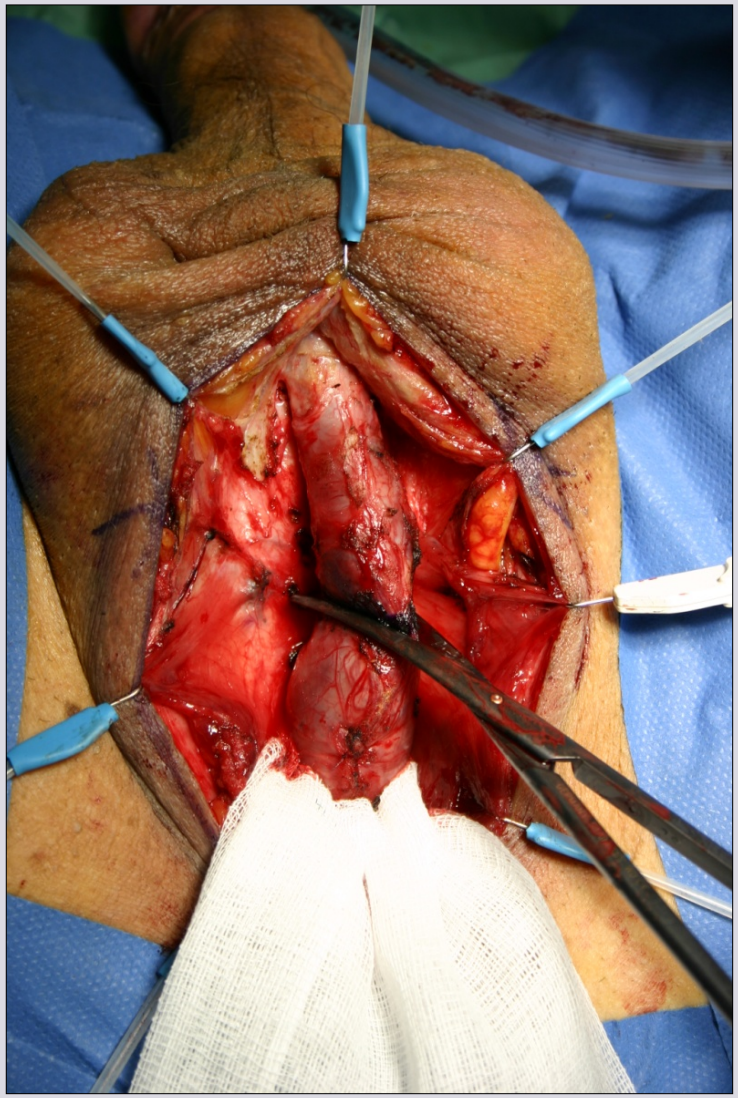

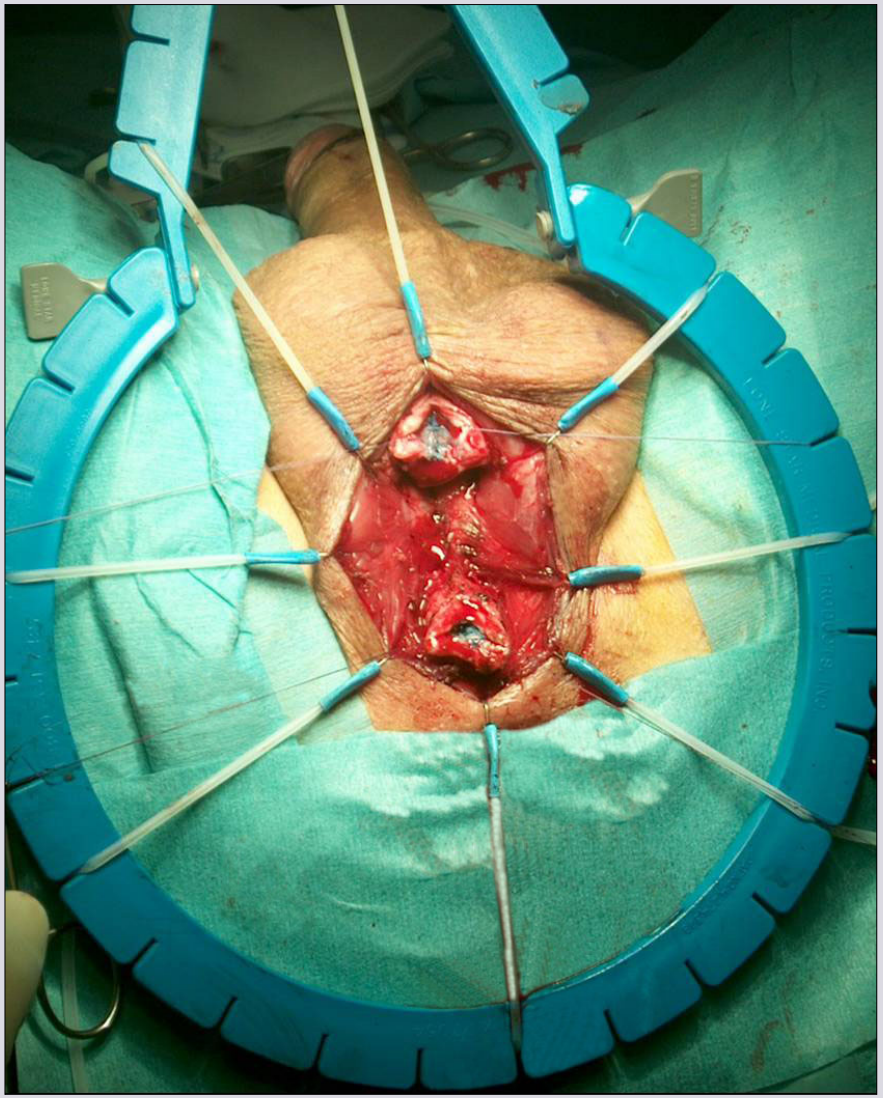

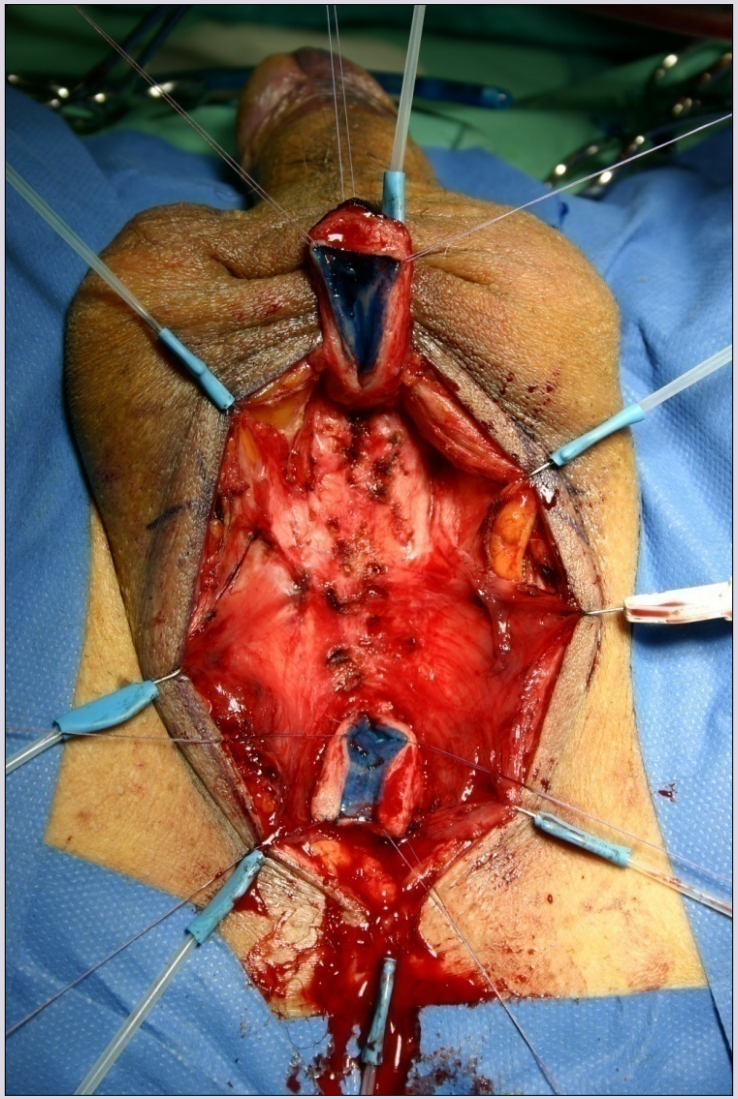

e-mail: info@urethralcenter.it

Websites: www.uretra.it
www.urethralcenter.it

CENTER FOR RECONSTRUCTIVE URETHRAL SURGERY

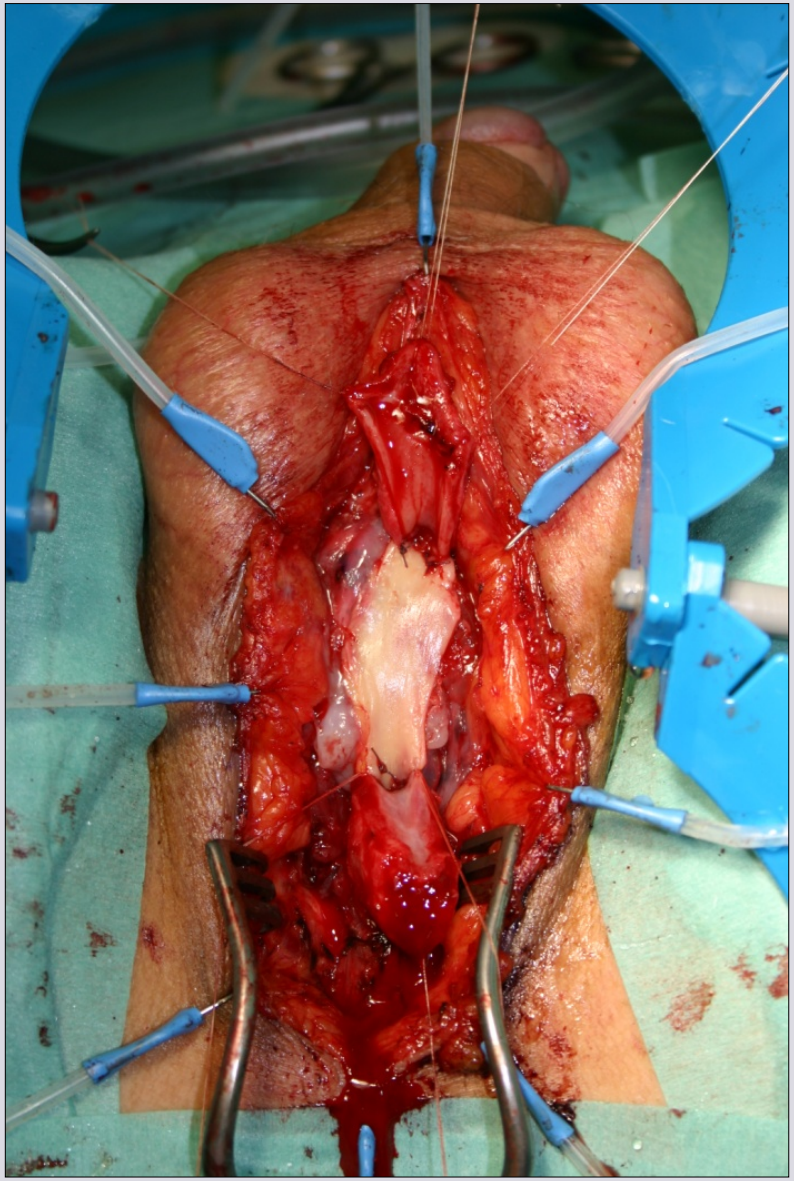

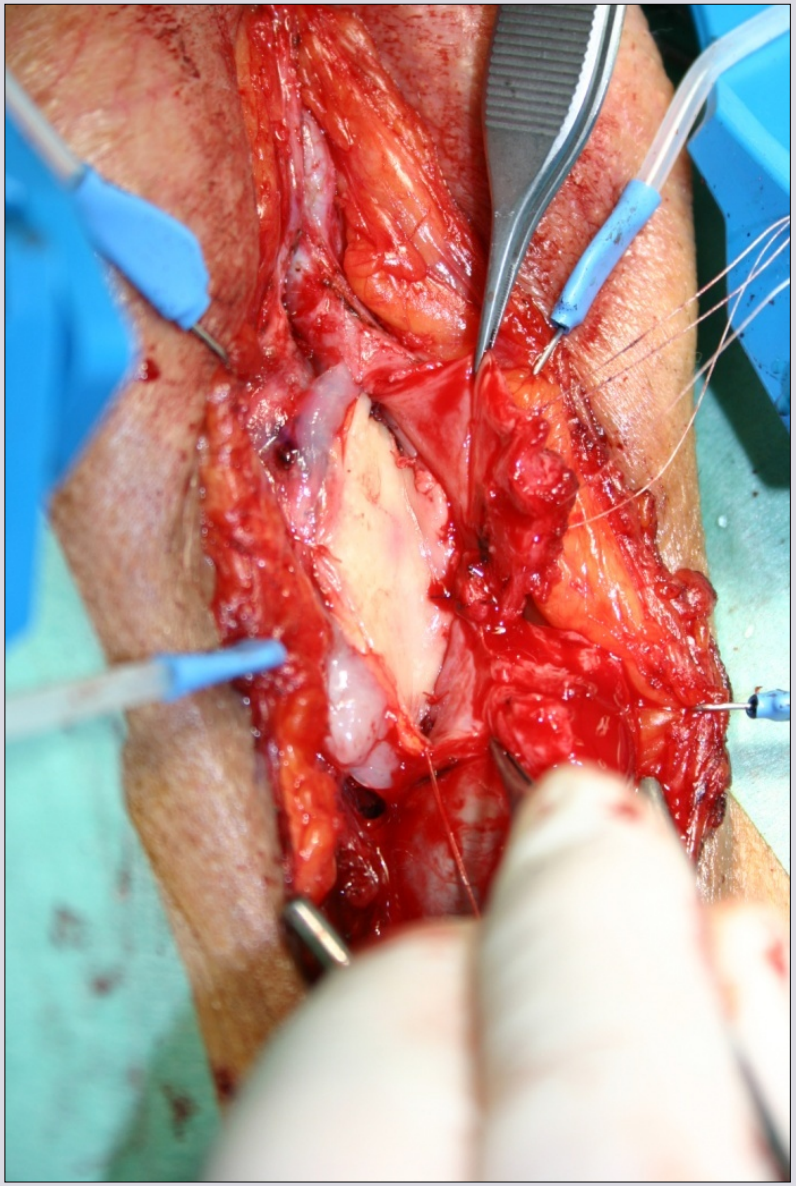

e-mail: info@urethralcenter.it

Websites: www.uretra.it
www.urethralcenter.it

CENTER FOR RECONSTRUCTIVE URETHRAL SURGERY

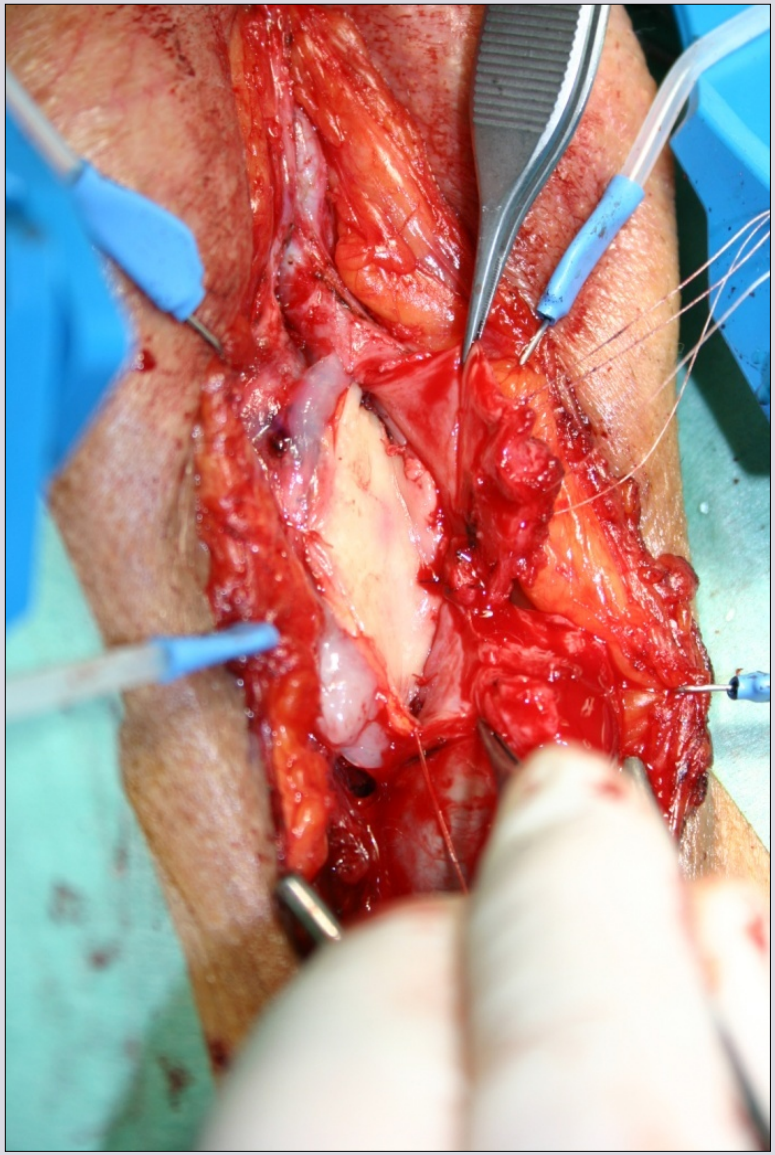

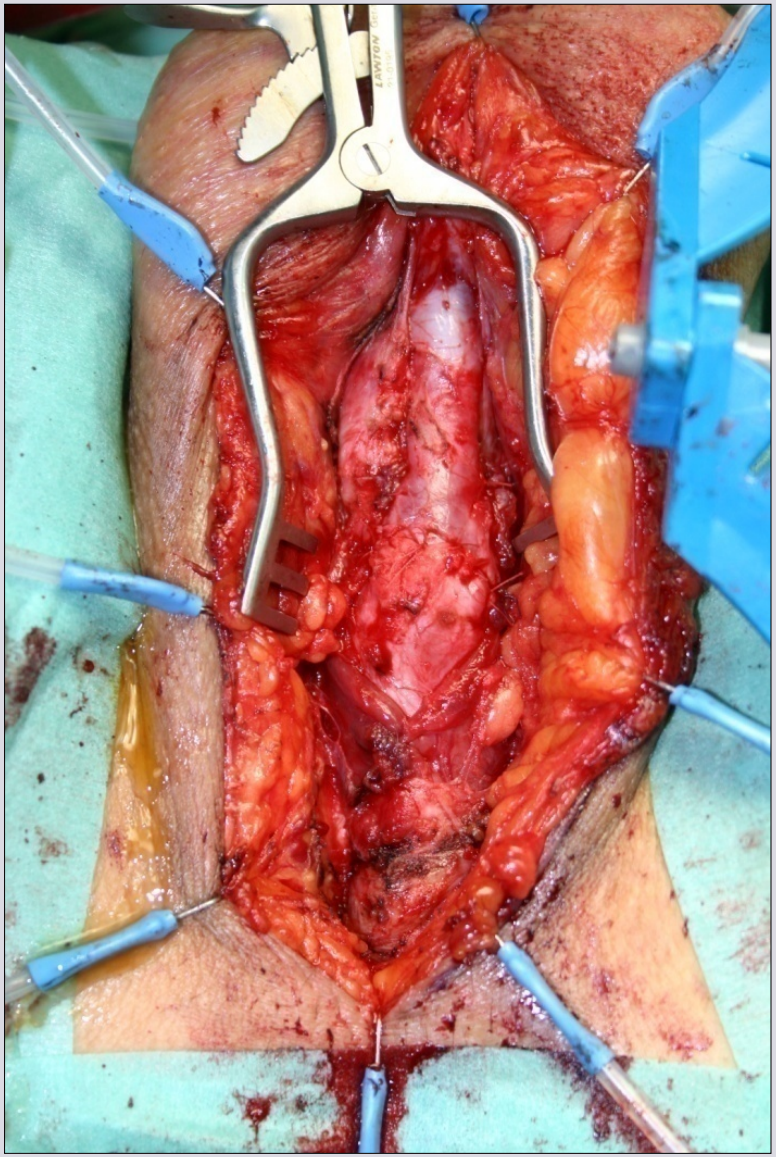

e-mail: info@urethralcenter.it

Websites: www.uretra.it
www.urethralcenter.it

CENTER FOR RECONSTRUCTIVE URETHRAL SURGERY

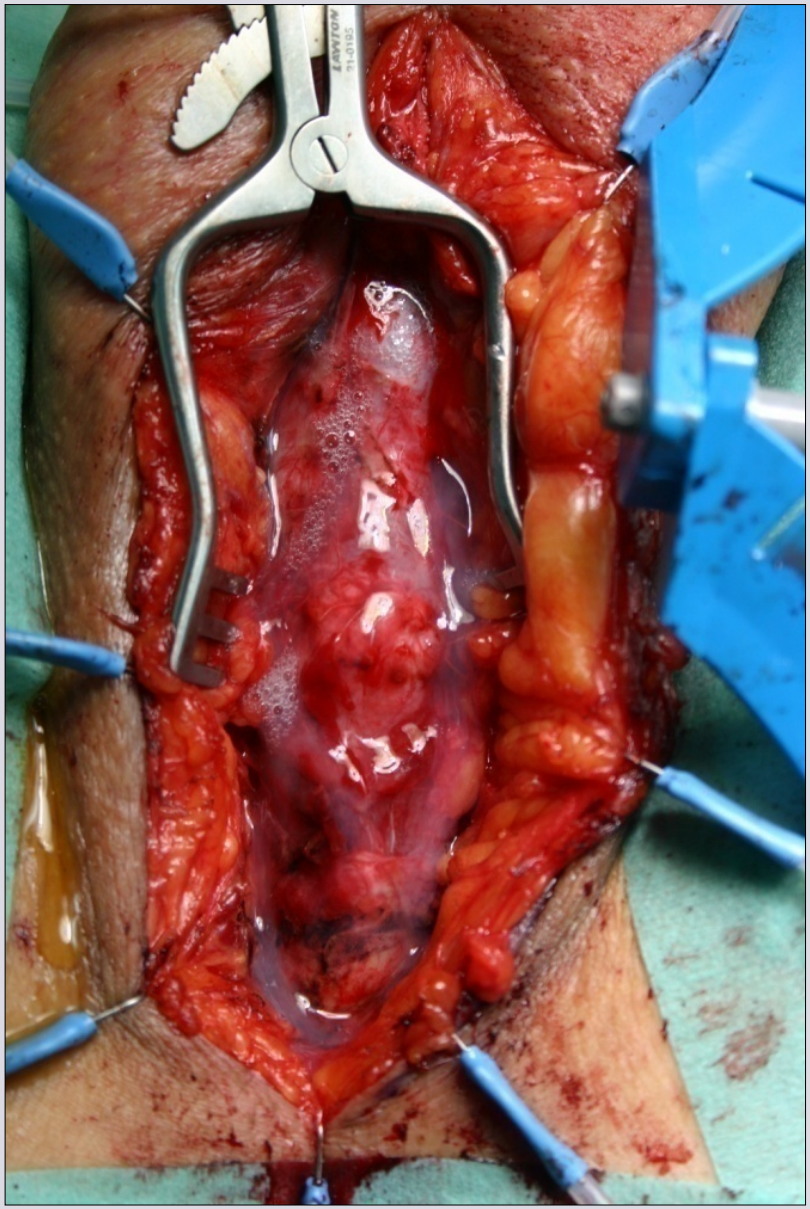

Reconstruction of the bulbar urethra in non-traumatic stricture

Non-traumatic bulbar urethral stricture

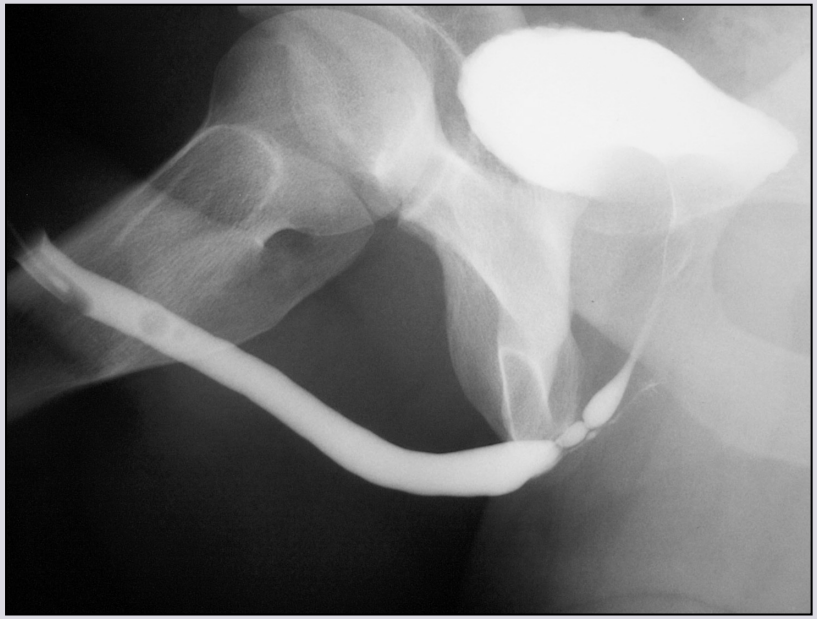

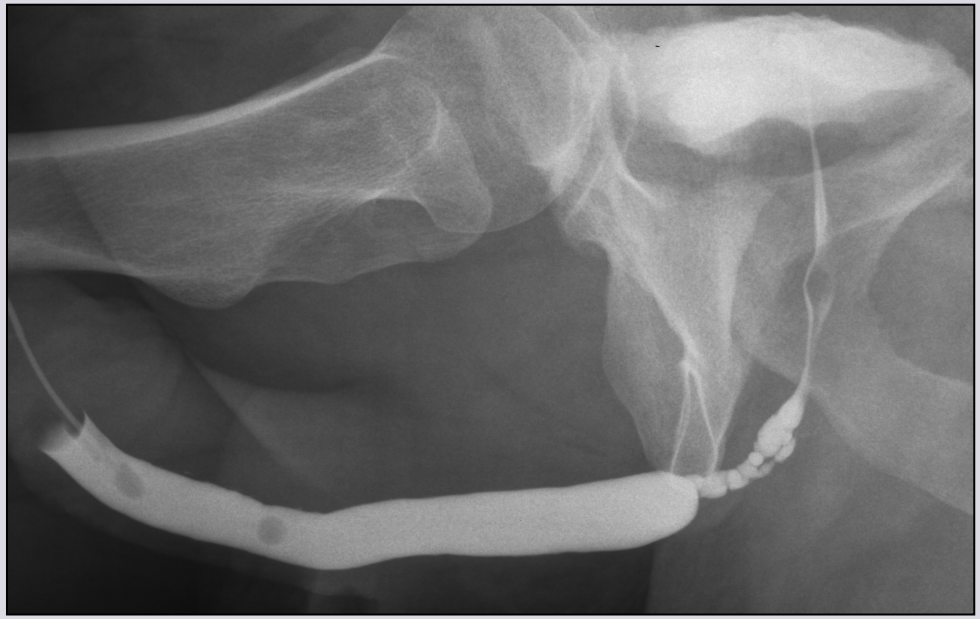

1. Etiology: idiopathic – catheter - instrumentation –infection – other
2. Practicable urethral plate (3 Fr. Sensor guidewire)
3. No fibrous gap

No traumatic bulbar urethral stricture

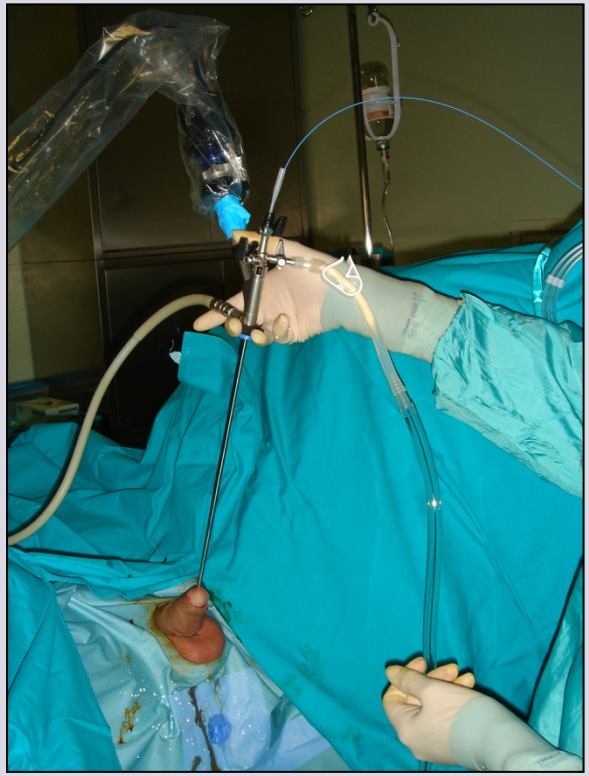

Pre-operative urethroscopy

Insert Sensor 3 Fr. guidewire

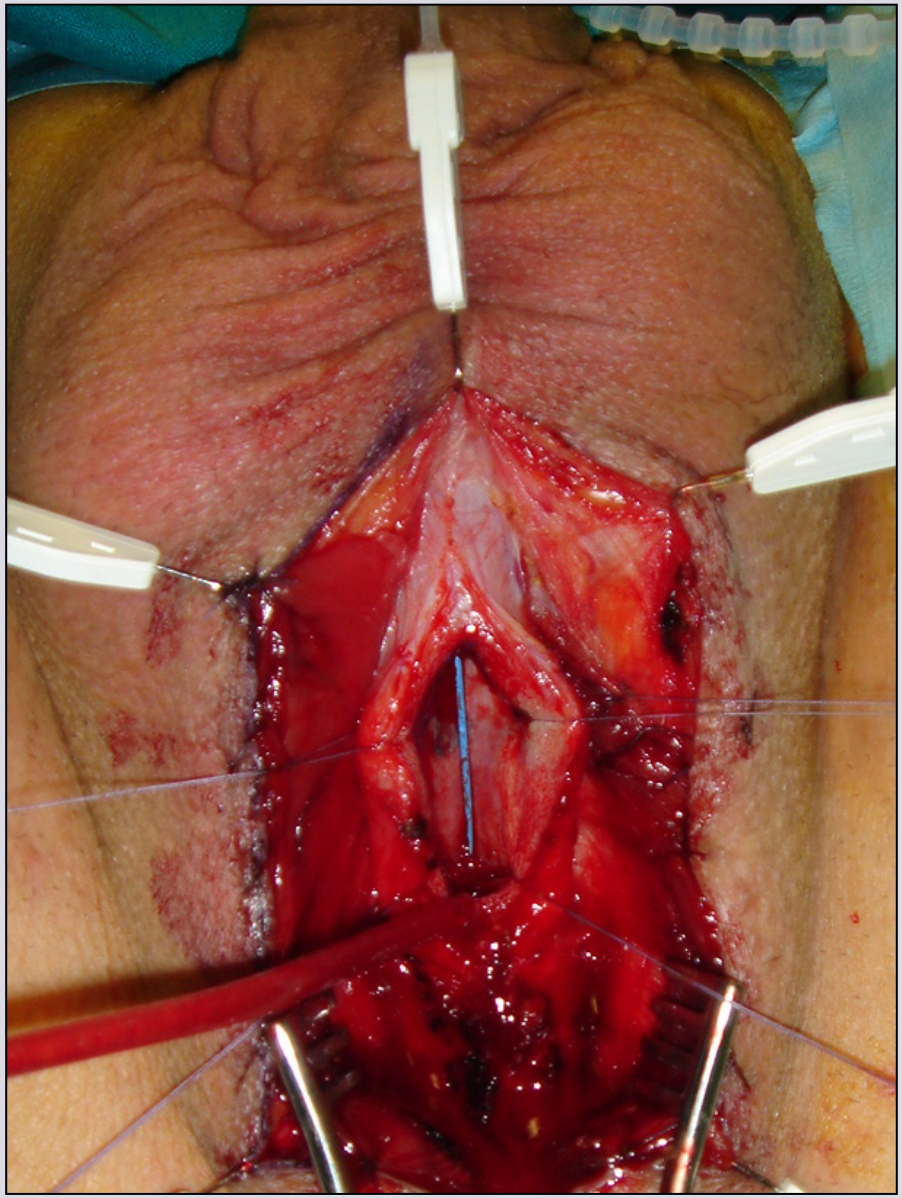

No traumatic bulbar urethral stricture

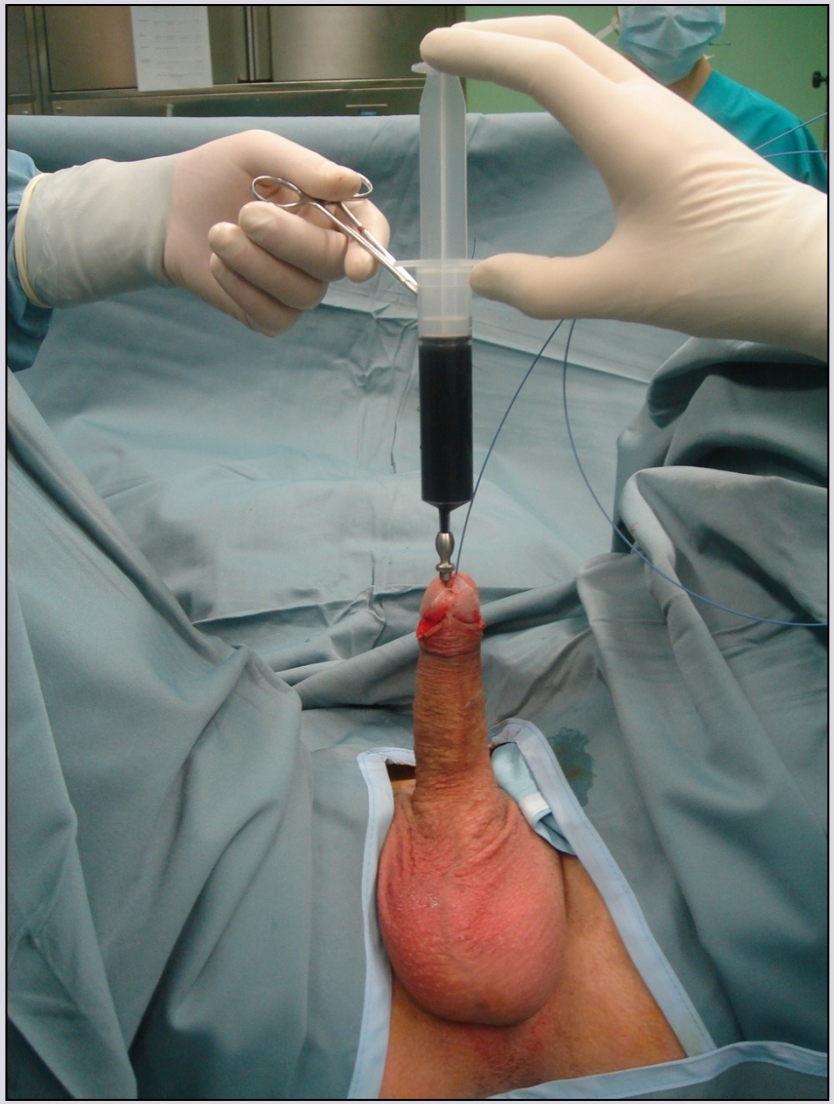

Inject methylene blue inside the urethra

(G. Webster)

No traumatic bulbar urethral stricture

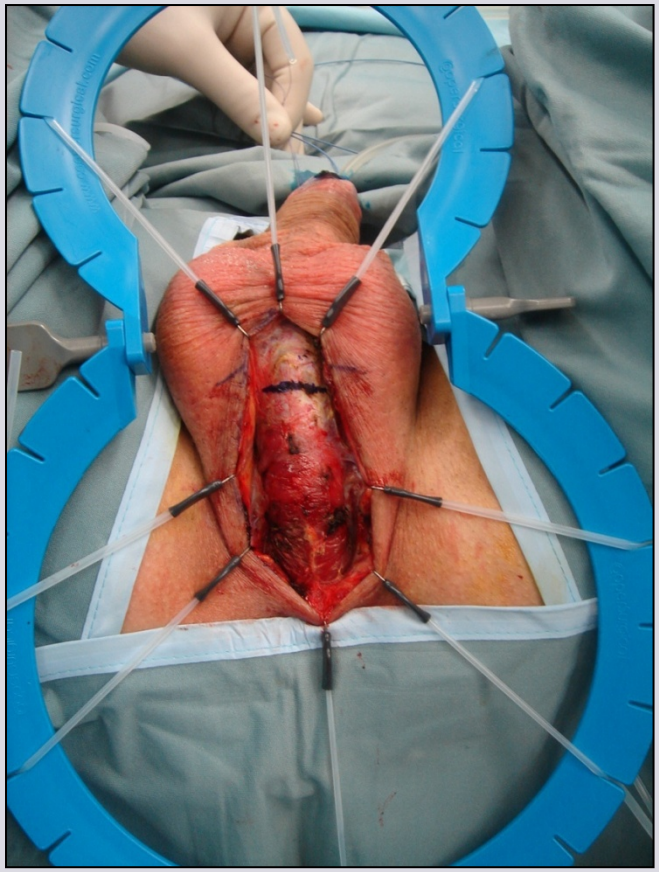

Calibrate the distal urethra and identify the distal stop

No traumatic bulbar urethral stricture

Ventral or dorsal graft?

Ventral or dorsal graft?

Distal

Dorsal onlay

Proximal

Ventral onlay

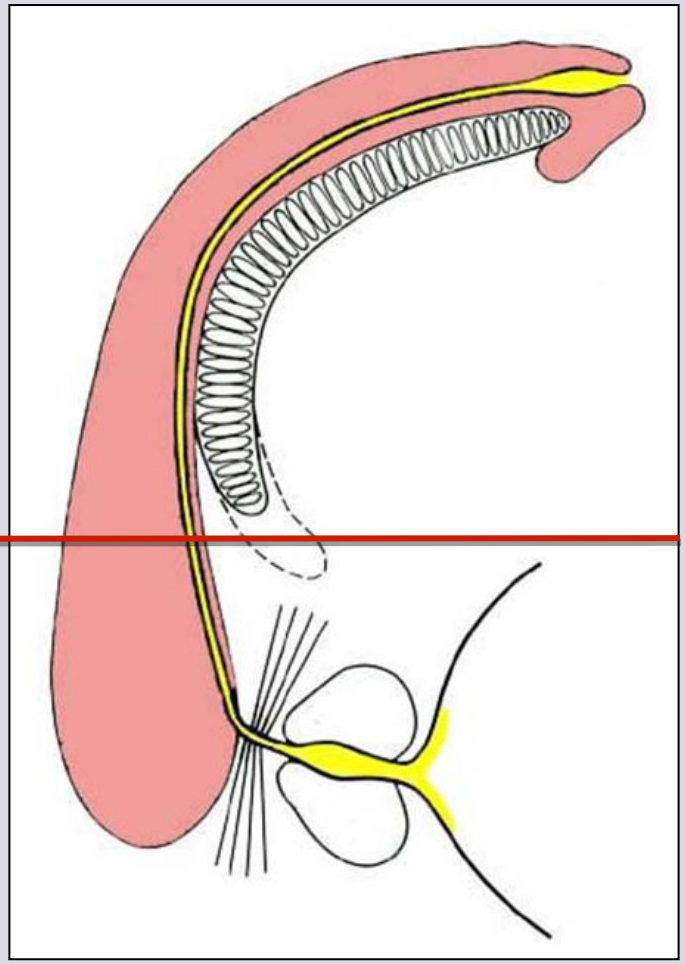

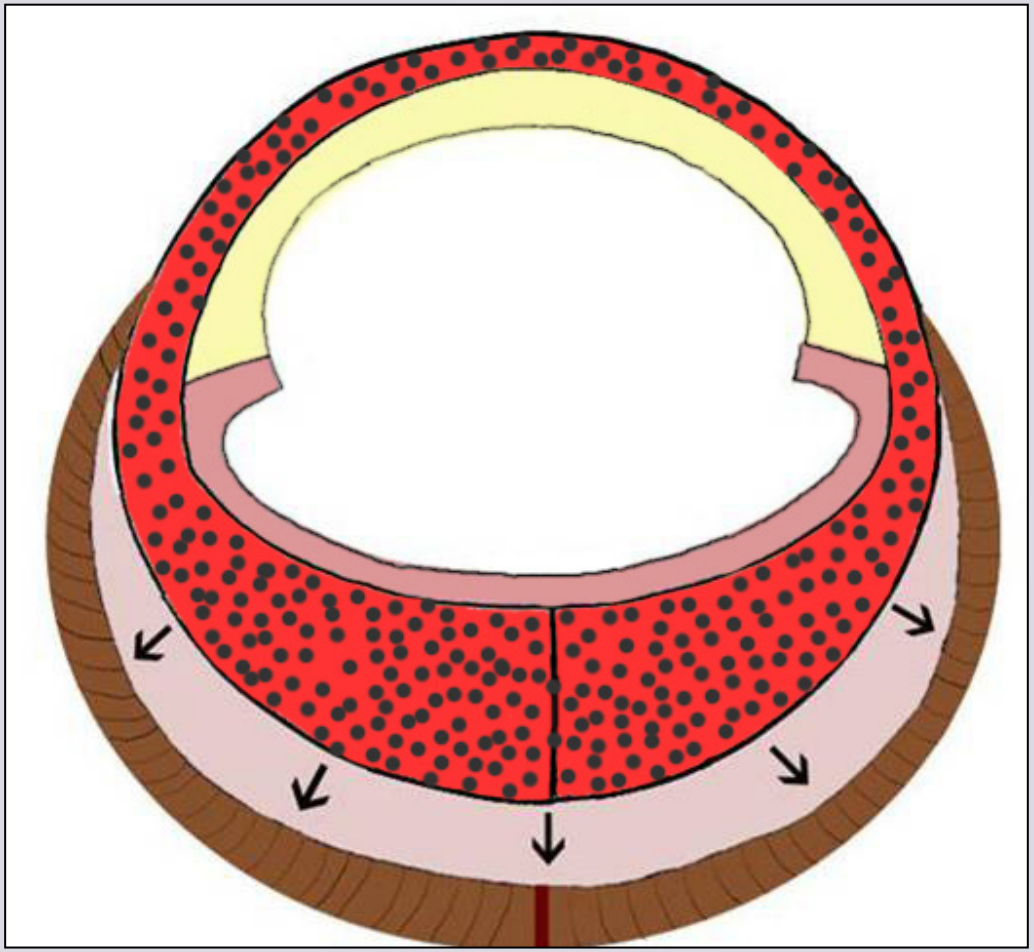

Muscle and nerve-sparing ventral onlay graft bulbar urethroplasty

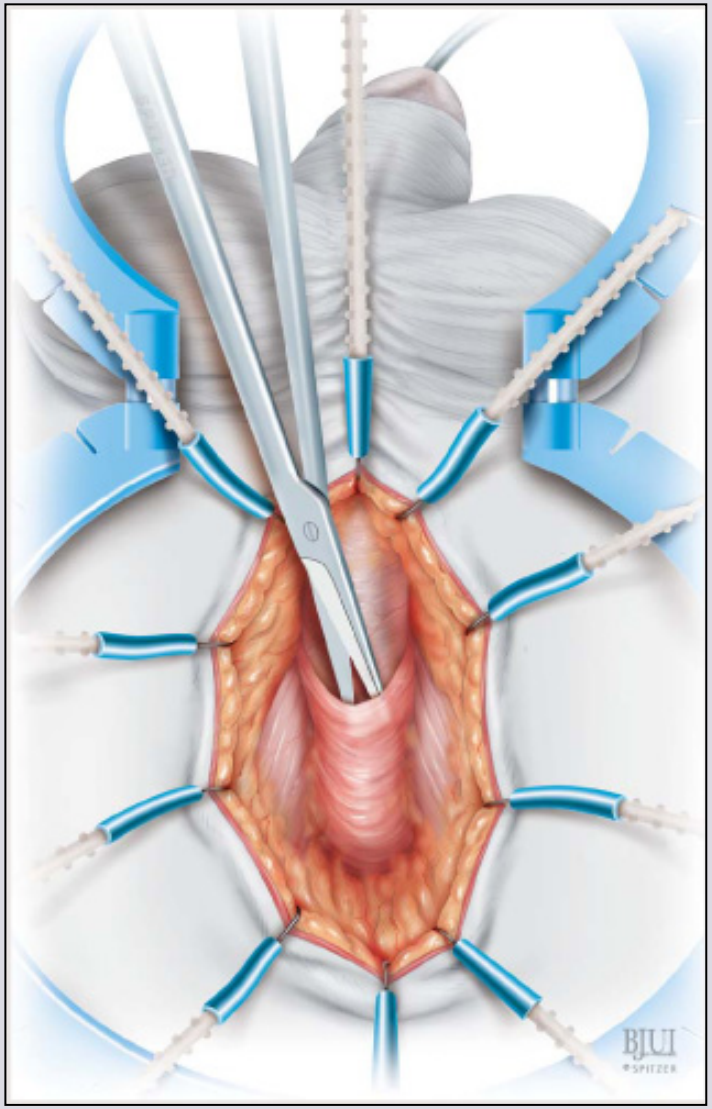

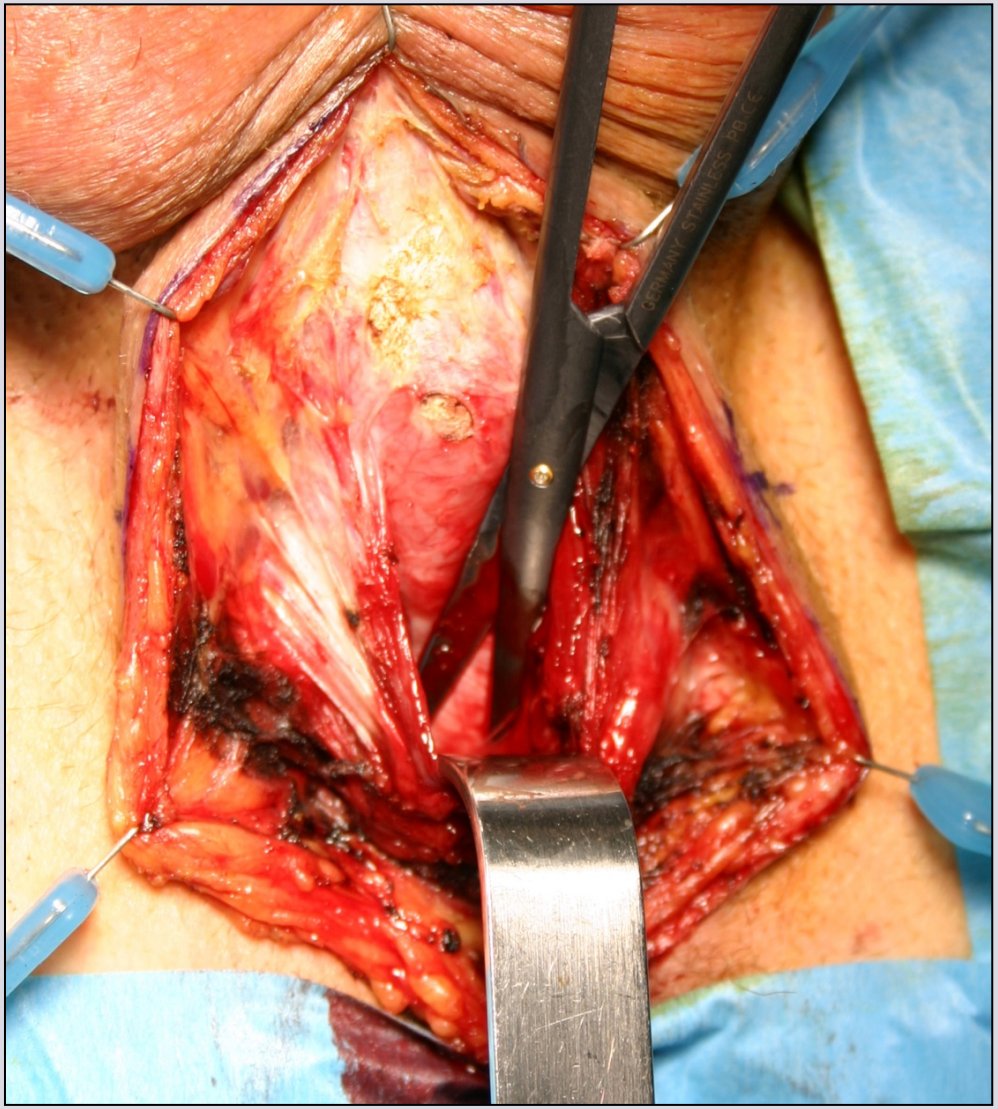

e-mail: info@urethralcenter.it

Websites: www.uretra.it
www.urethralcenter.it

CENTER FOR RECONSTRUCTIVE URETHRAL SURGERY

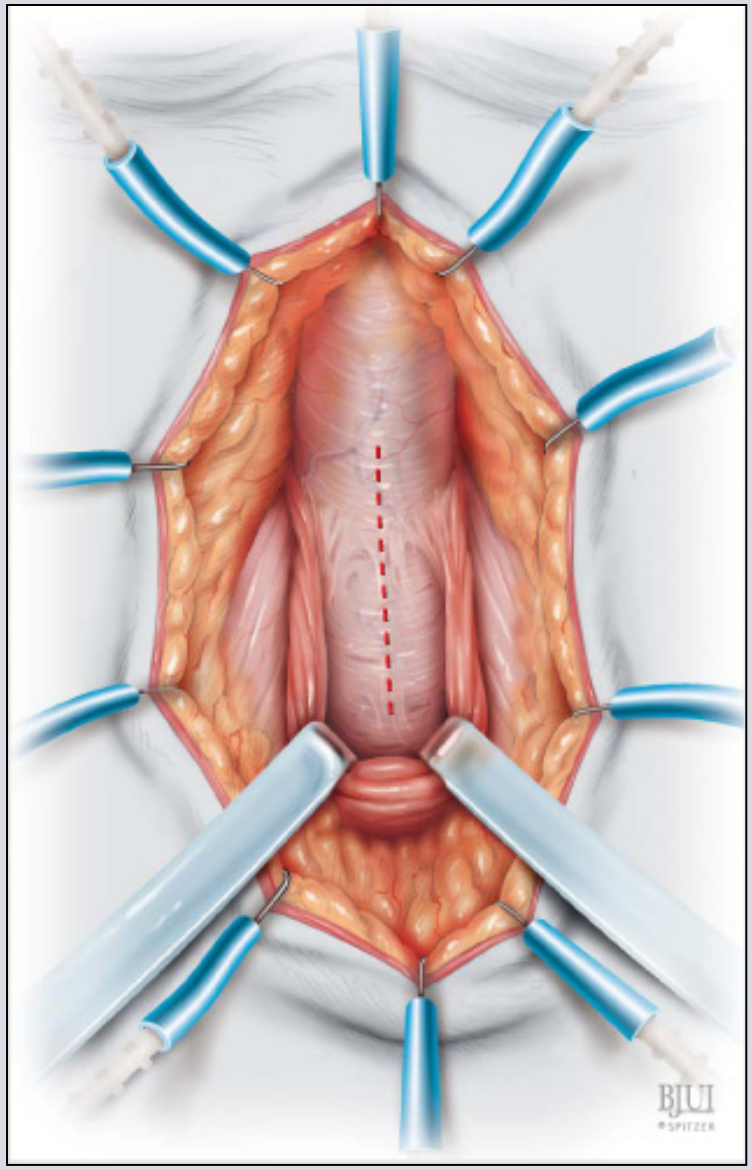

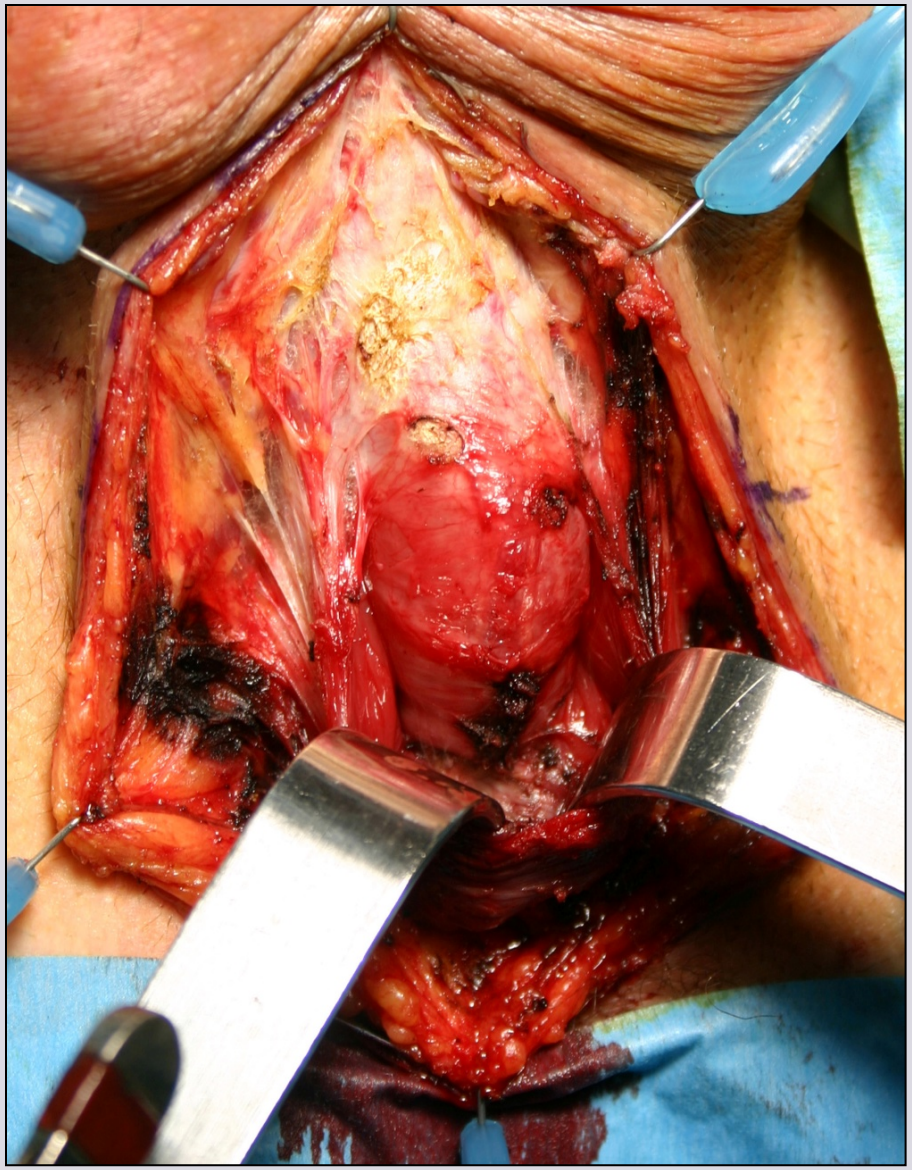

e-mail: info@urethralcenter.it

Websites: www.uretra.it
www.urethralcenter.it

CENTER FOR RECONSTRUCTIVE URETHRAL SURGERY

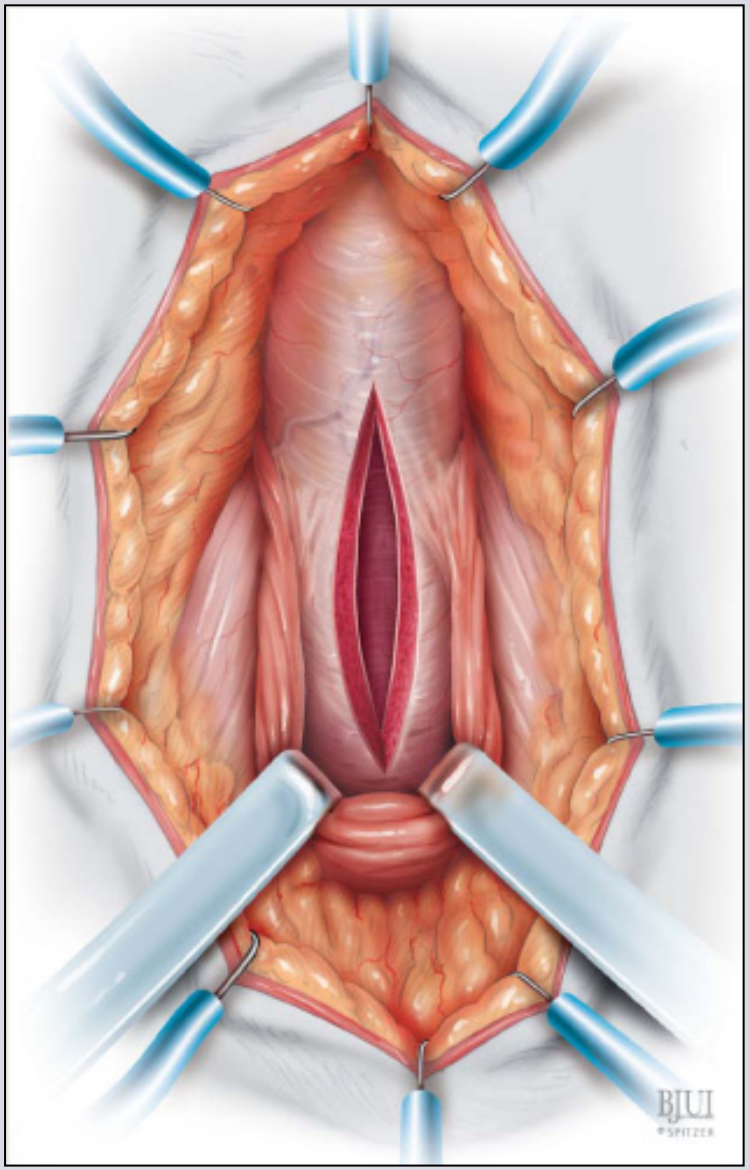

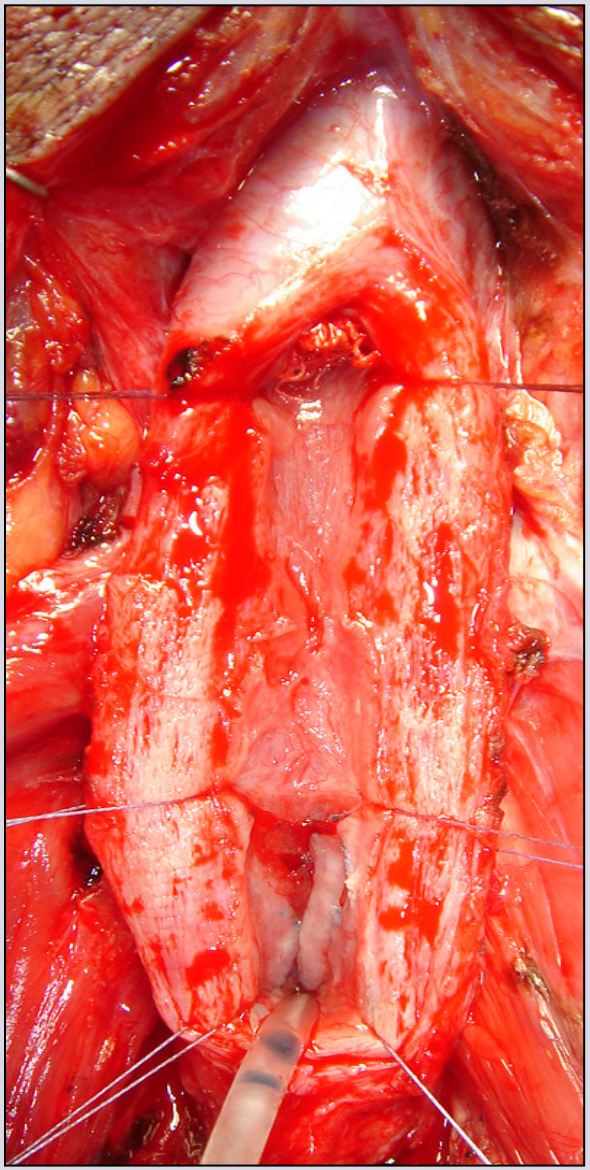

e-mail: info@urethralcenter.it

Websites: www.uretra.it
www.urethralcenter.it

CENTER FOR RECONSTRUCTIVE URETHRAL SURGERY

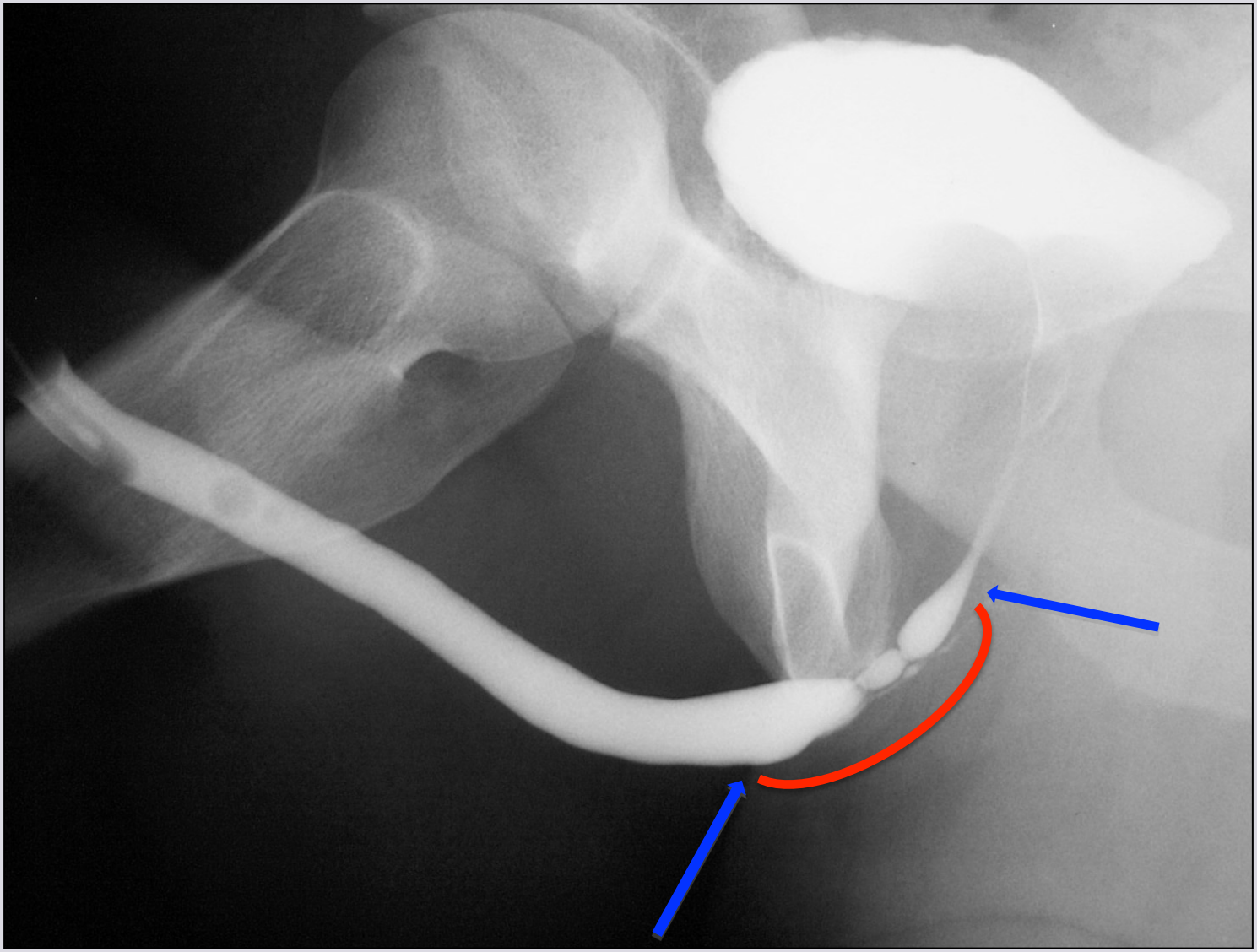

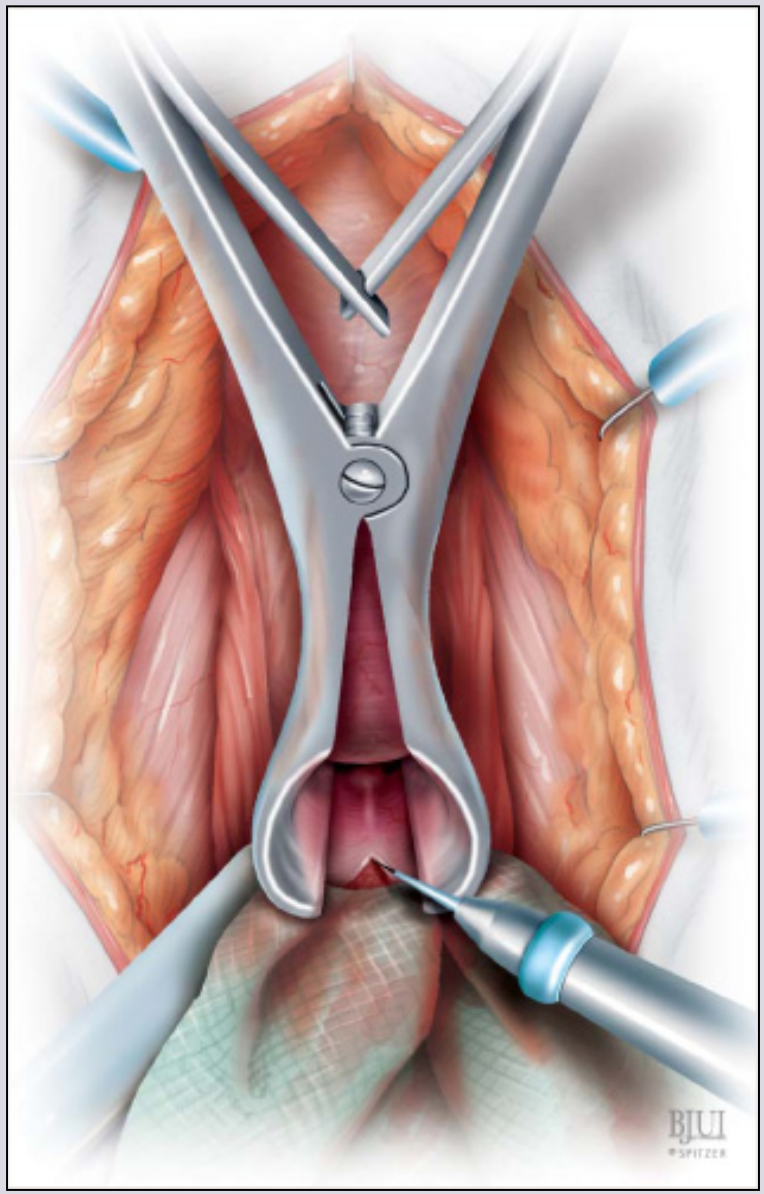

e-mail: info@urethralcenter.it

Websites: www.uretra.it
www.urethralcenter.it



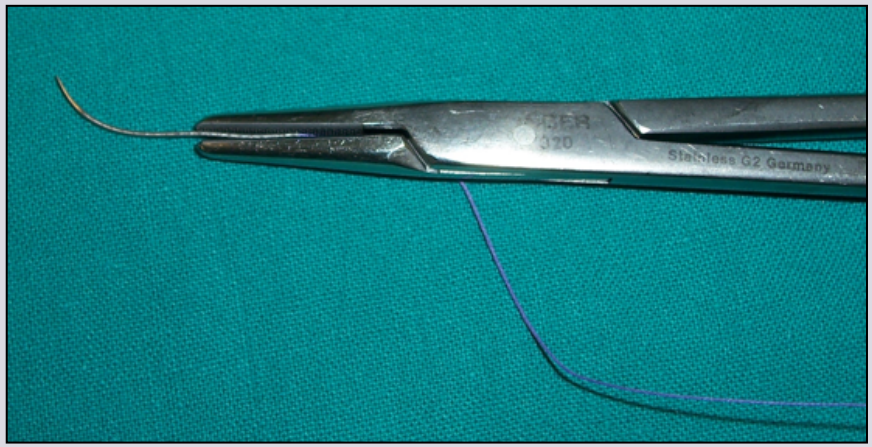

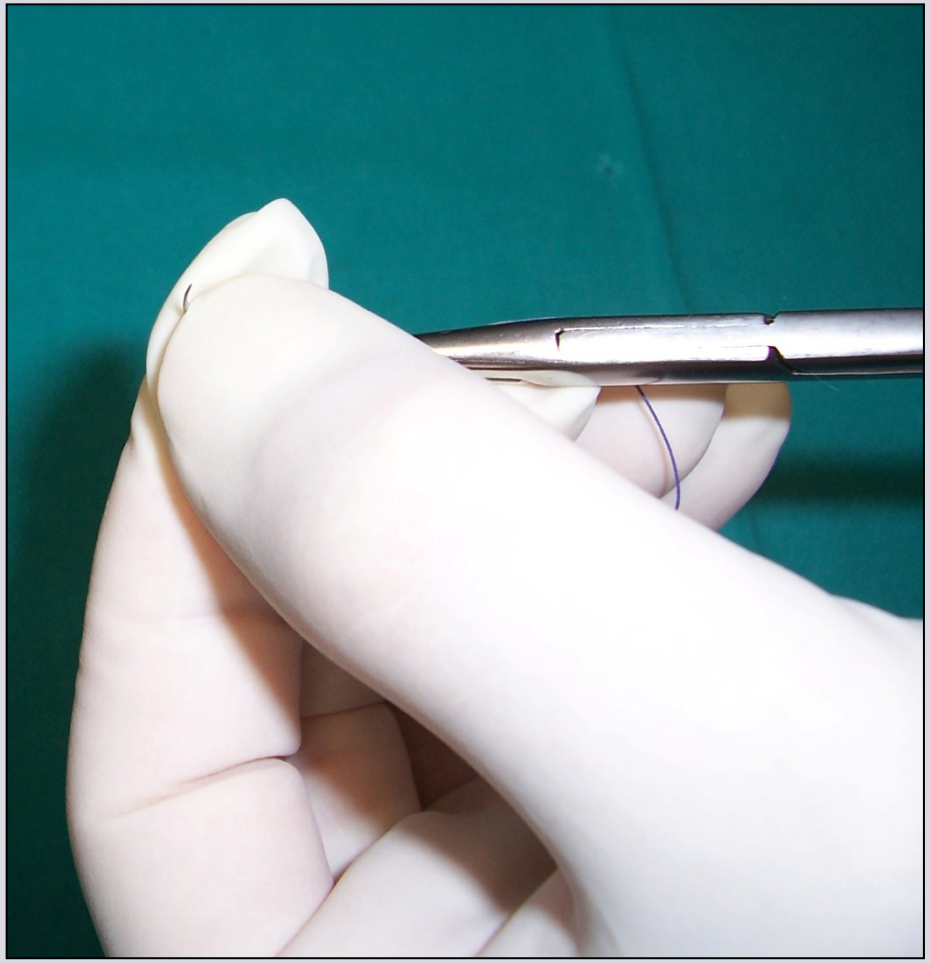

e-mail: info@urethralcenter.it

Websites: www.uretra.it
www.urethralcenter.it

CENTER FOR RECONSTRUCTIVE URETHRAL SURGERY

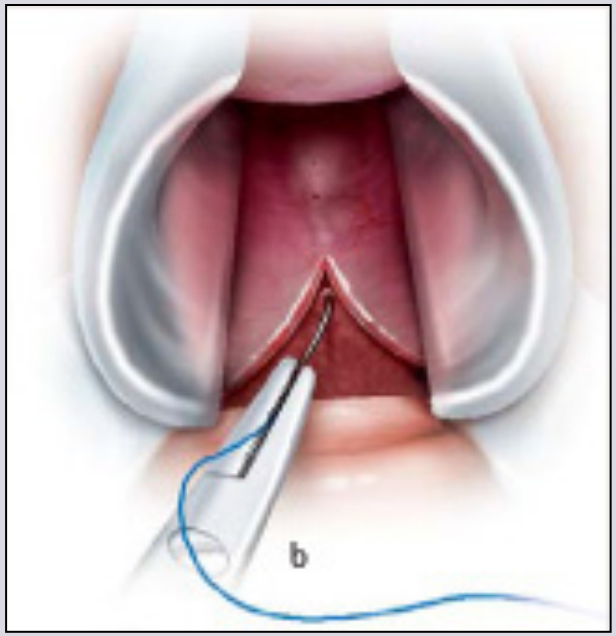

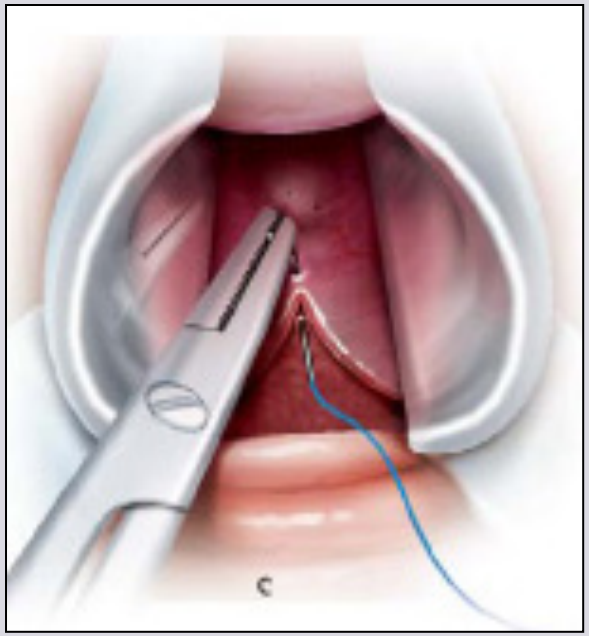

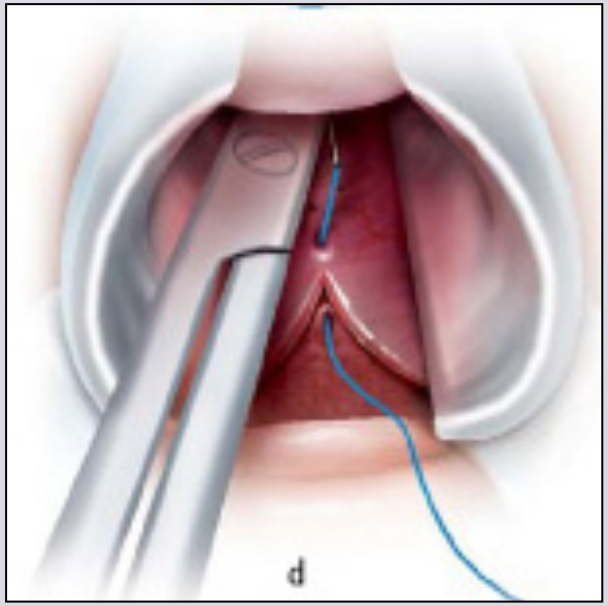

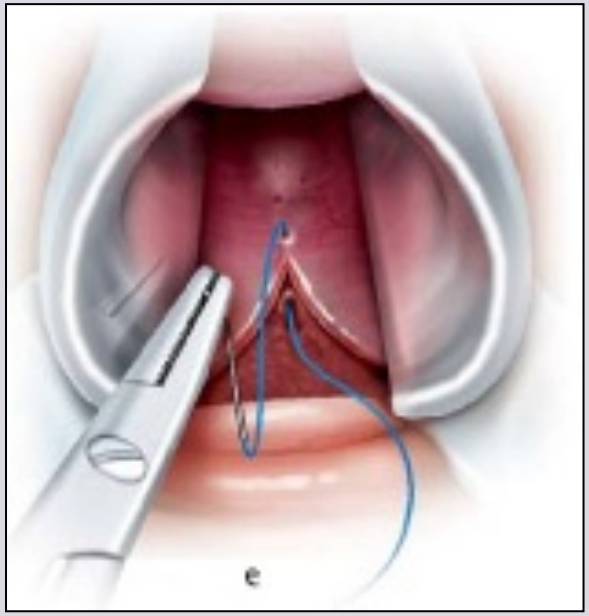

e-mail: info@urethralcenter.it

Websites: www.uretra.it
www.urethralcenter.it

CENTER FOR RECONSTRUCTIVE URETHRAL SURGERY

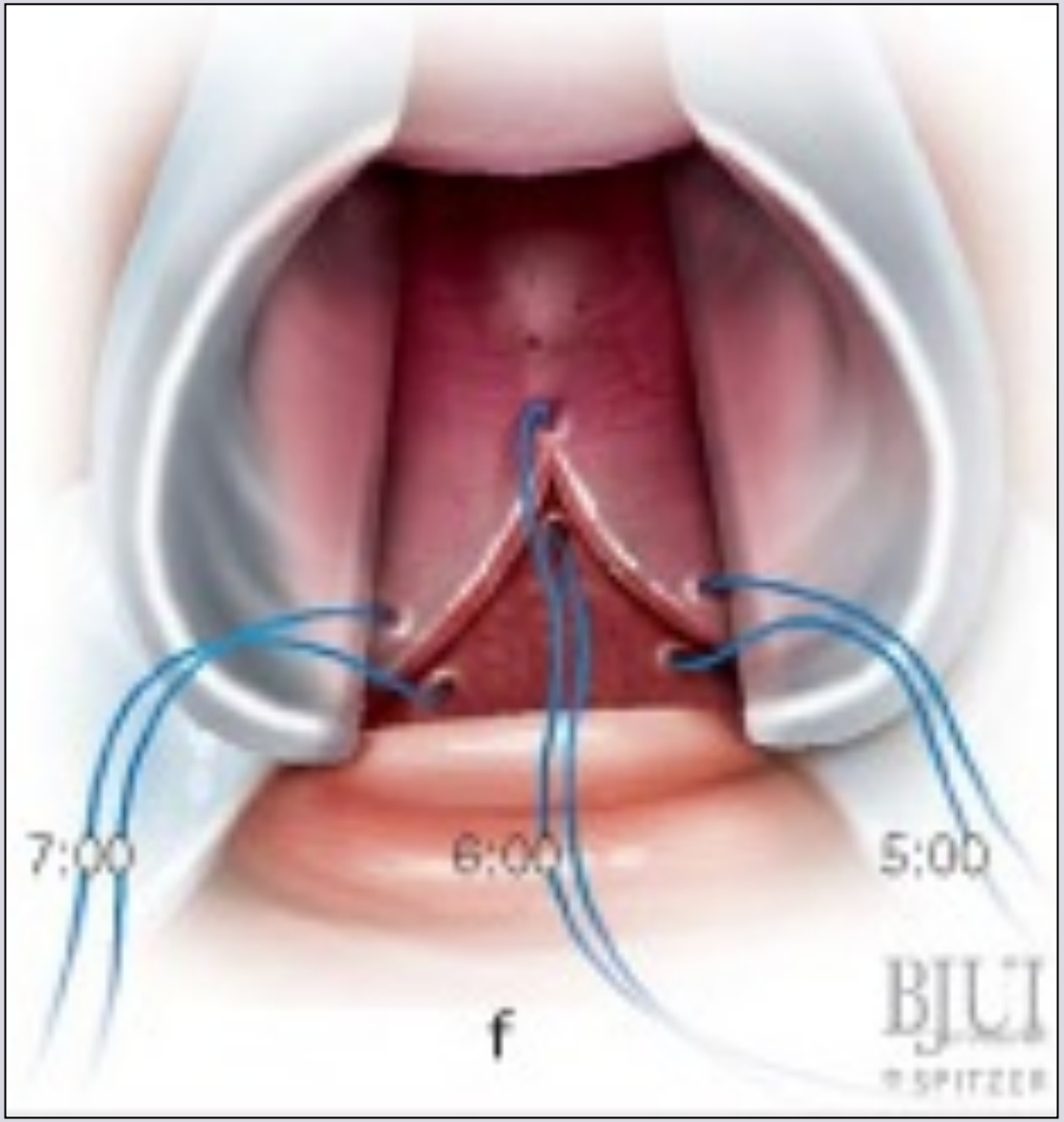

e-mail: info@urethralcenter.it
Websites: www.uretra.it
www.urethralcenter.it
CENTER FOR RECONSTRUCTIVE URETHRAL SURGERY

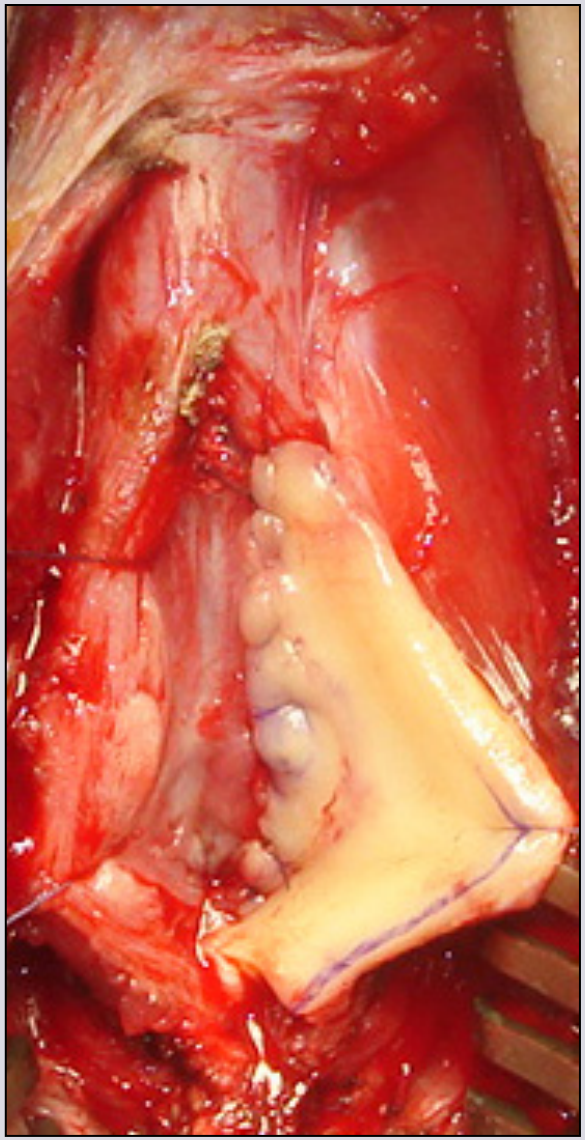

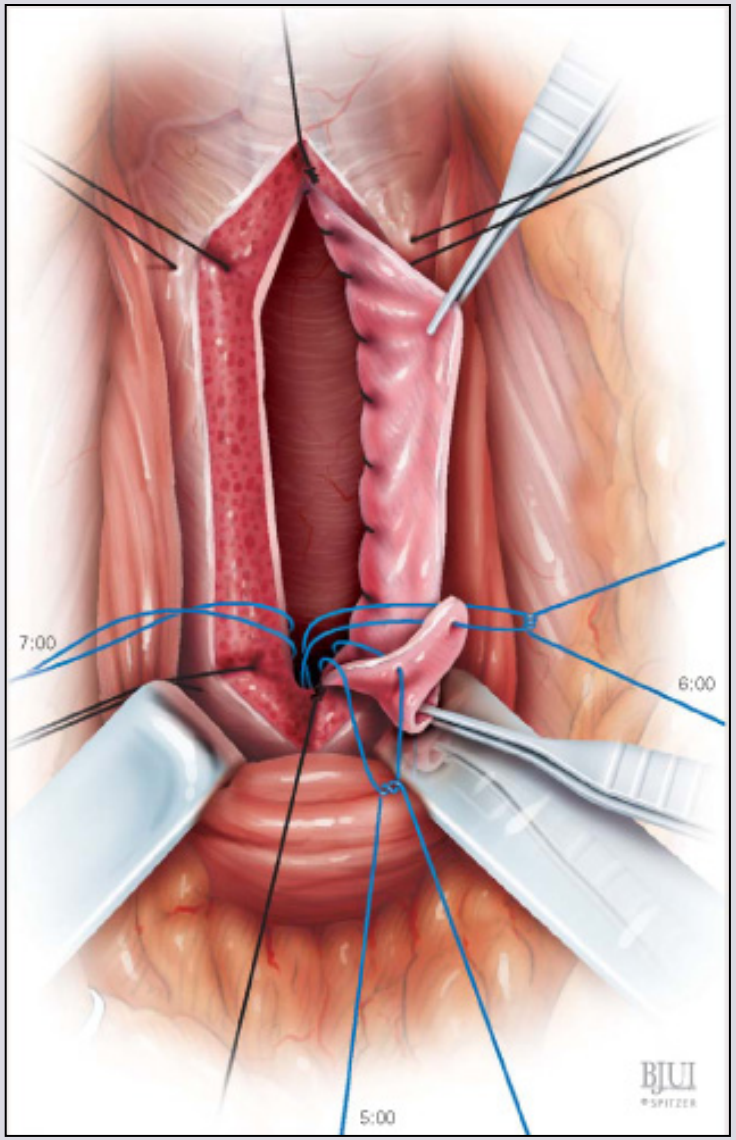

e-mail: info@urethralcenter.it

Websites: www.uretra.it
www.urethralcenter.it

CENTER FOR RECONSTRUCTIVE URETHRAL SURGERY

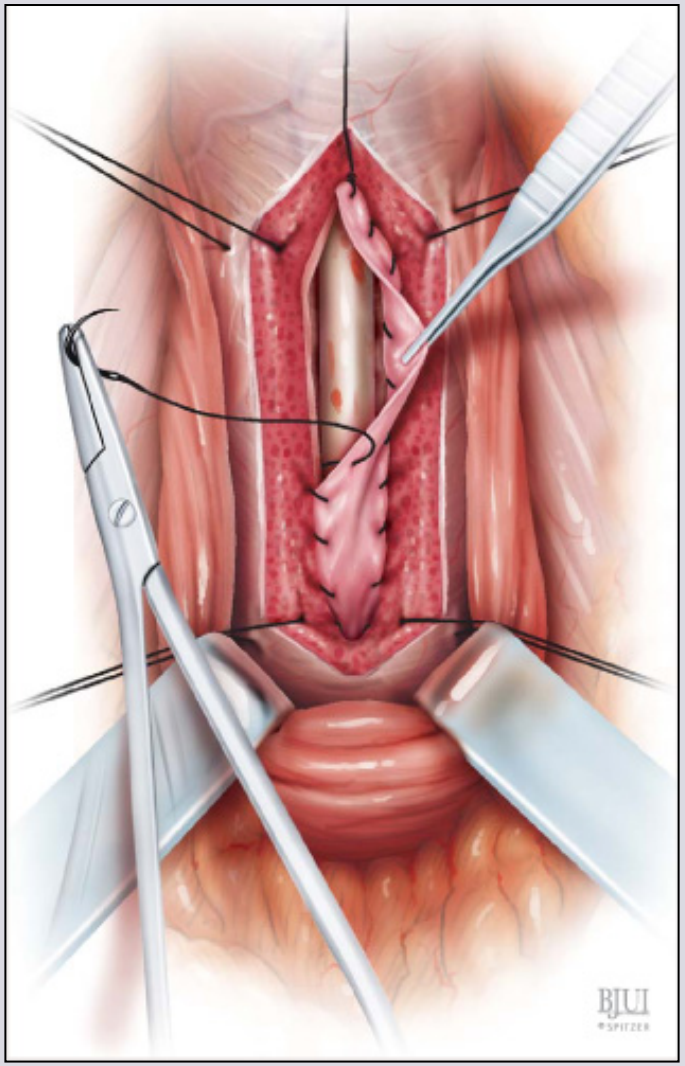

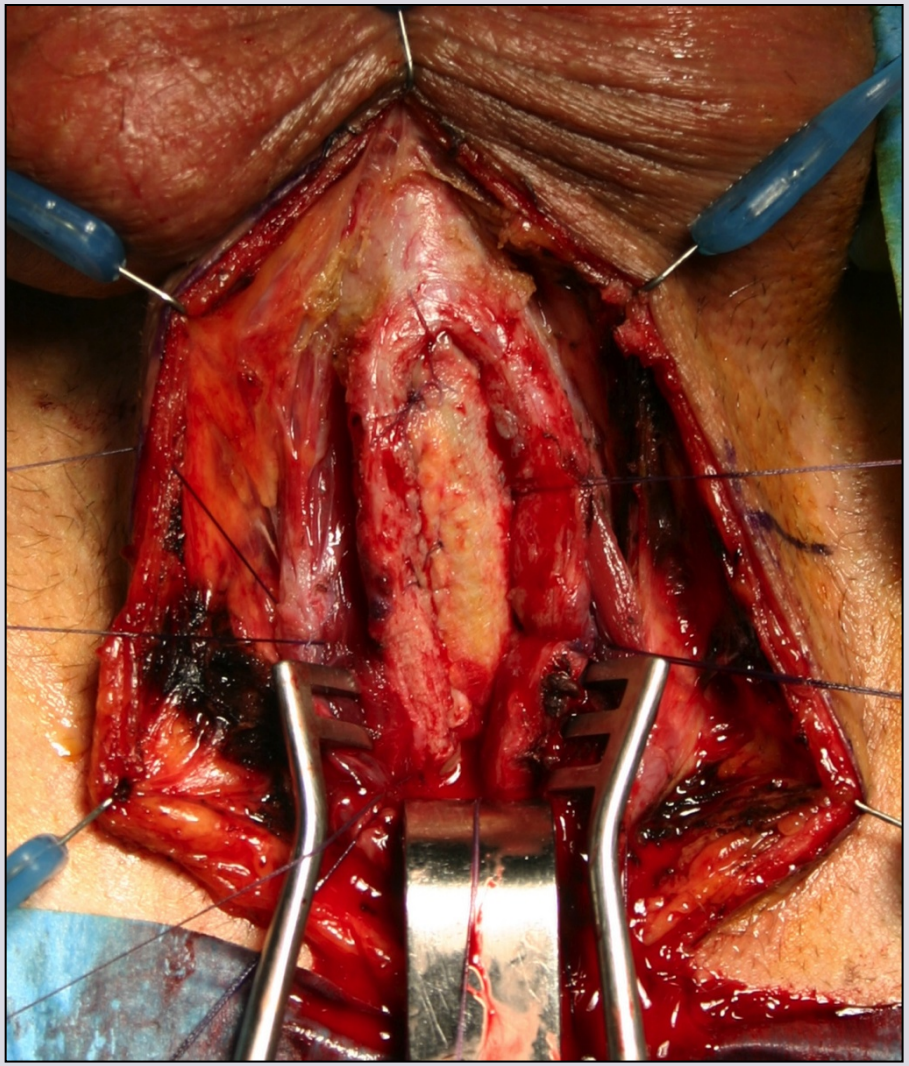

e-mail: info@urethralcenter.it

Websites: www.uretra.it
www.urethralcenter.it

CENTER FOR RECONSTRUCTIVE URETHRAL SURGERY

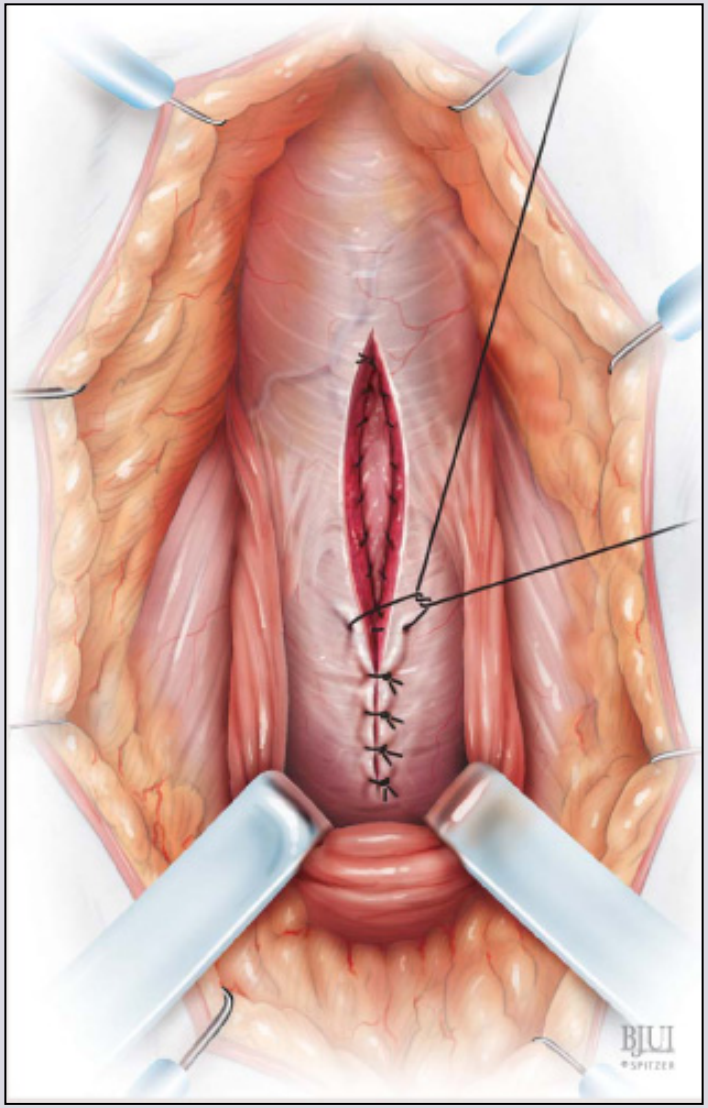

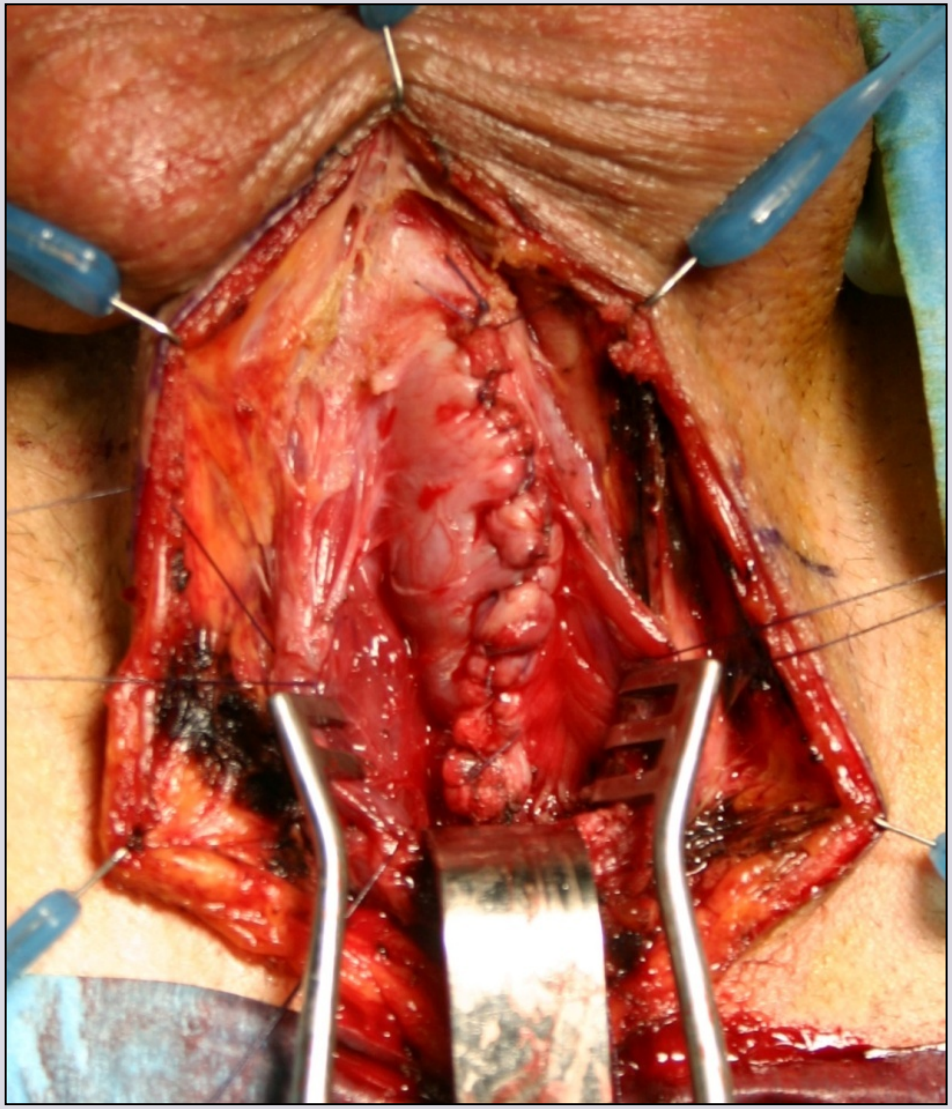

e-mail: info@urethralcenter.it

Websites: www.uretra.it
www.urethralcenter.it

CENTER FOR RECONSTRUCTIVE URETHRAL SURGERY

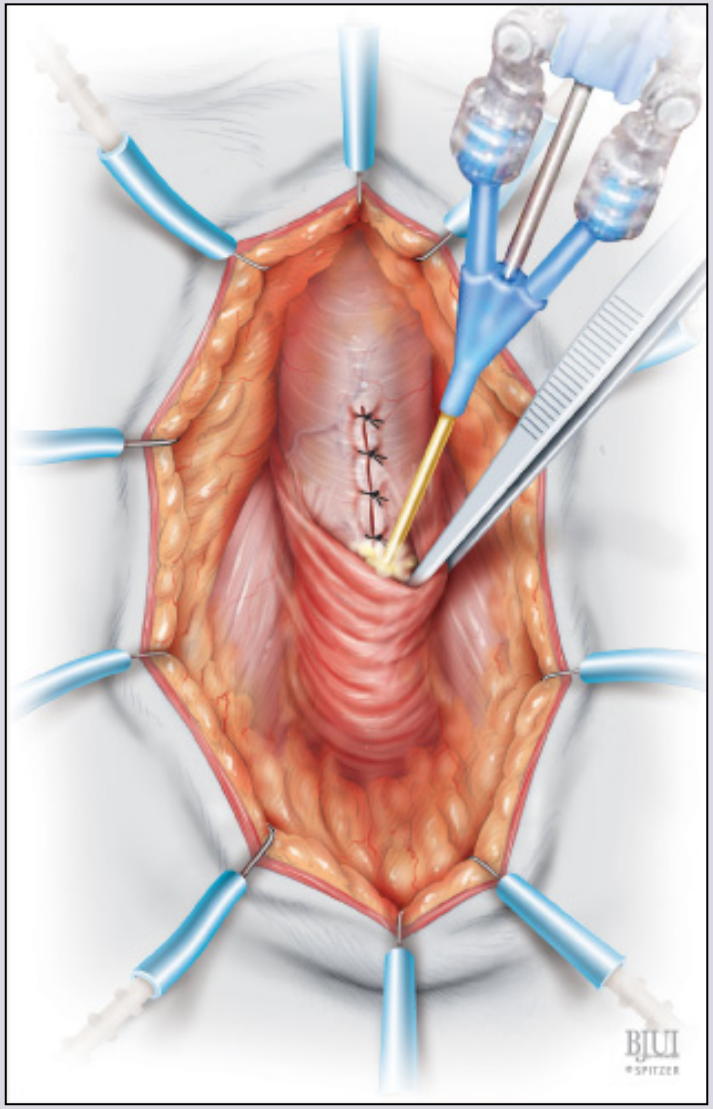

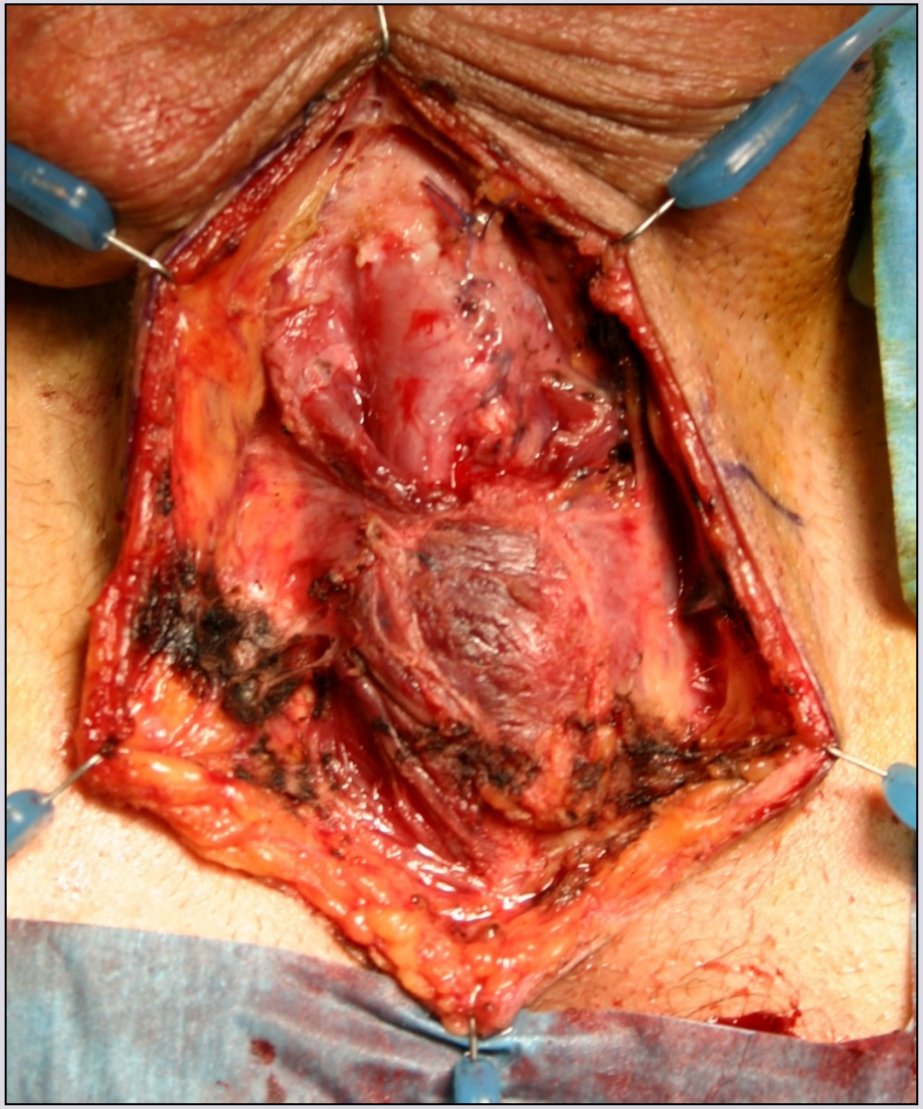

e-mail: info@urethralcenter.it

Websites: www.uretra.it
www.urethralcenter.it

e-mail: info@urethralcenter.it

Websites: www.uretra.it
www.urethralcenter.it

CENTER FOR RECONSTRUCTIVE URETHRAL SURGERY

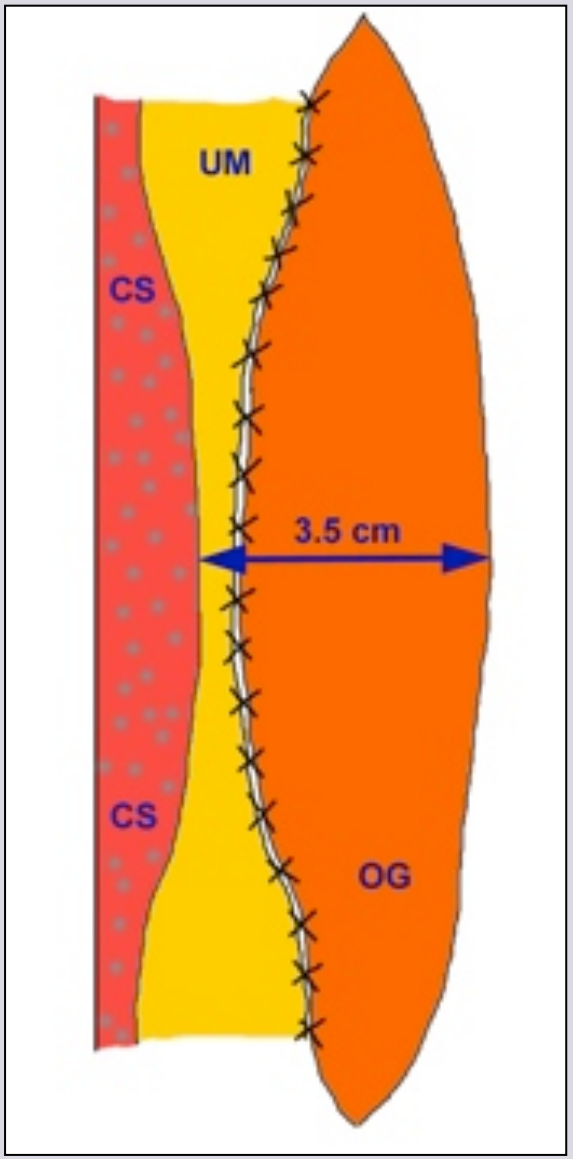
UM
CS
3.5 cm
CS
OG

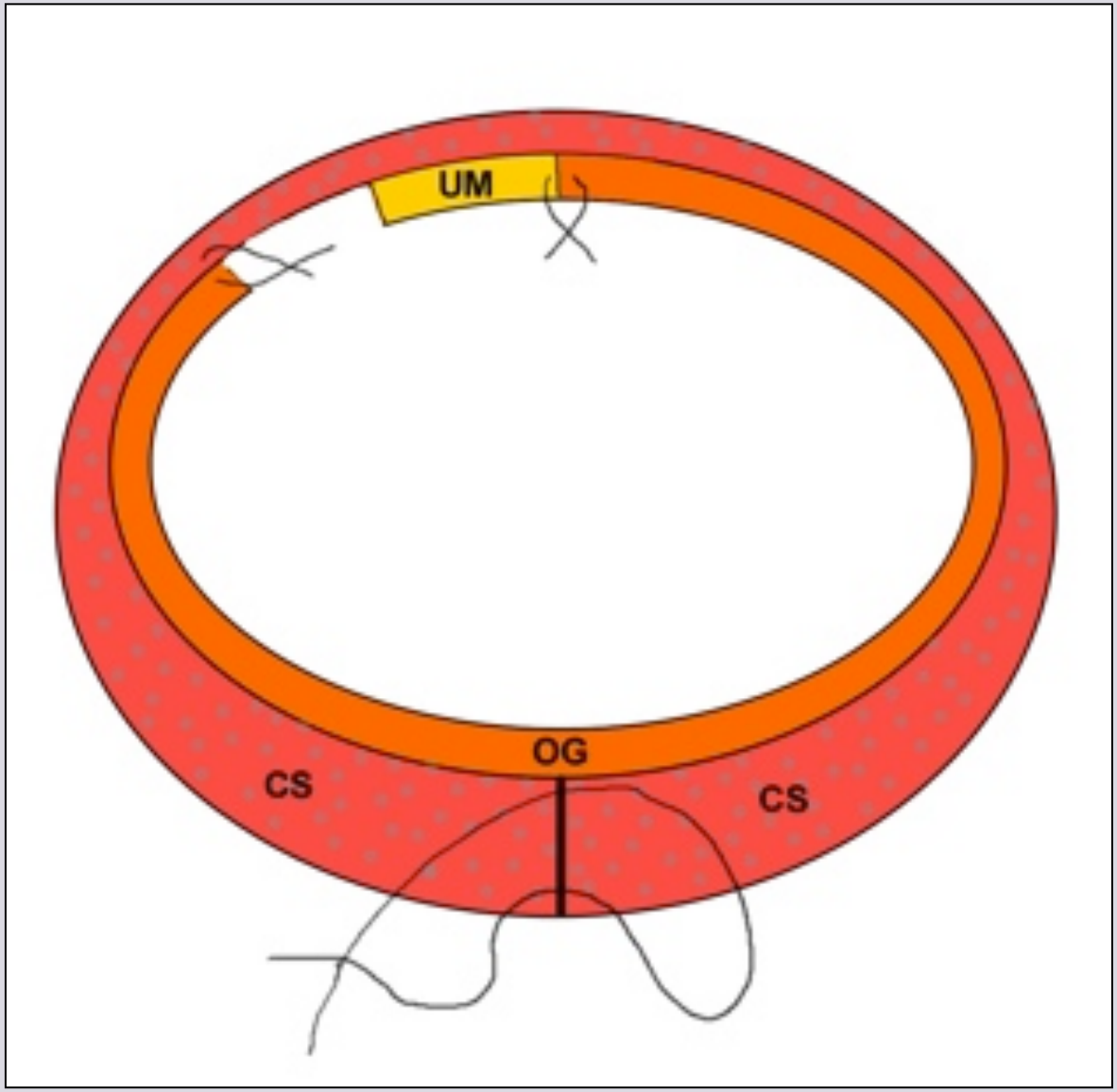
UM
OG
CS
CS

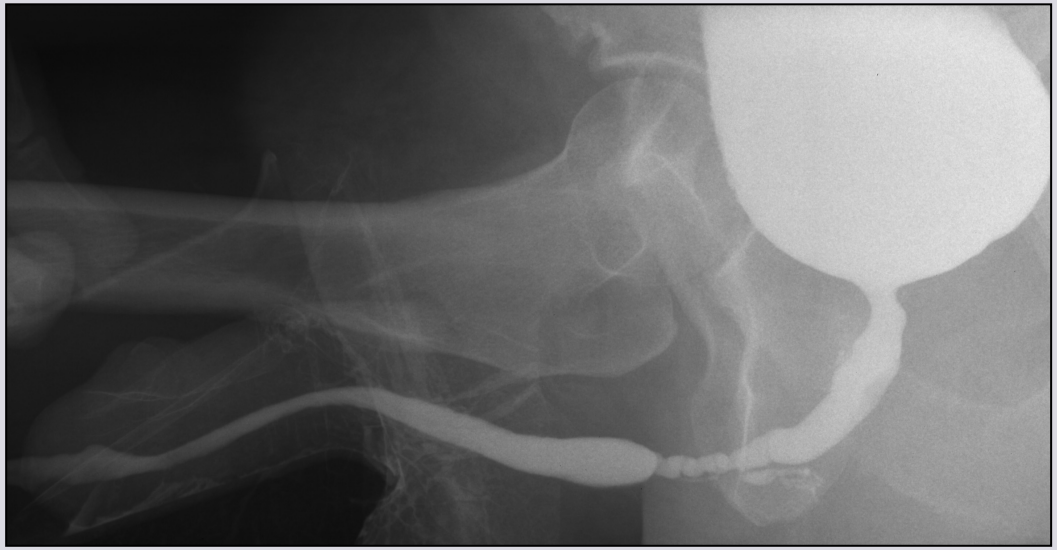

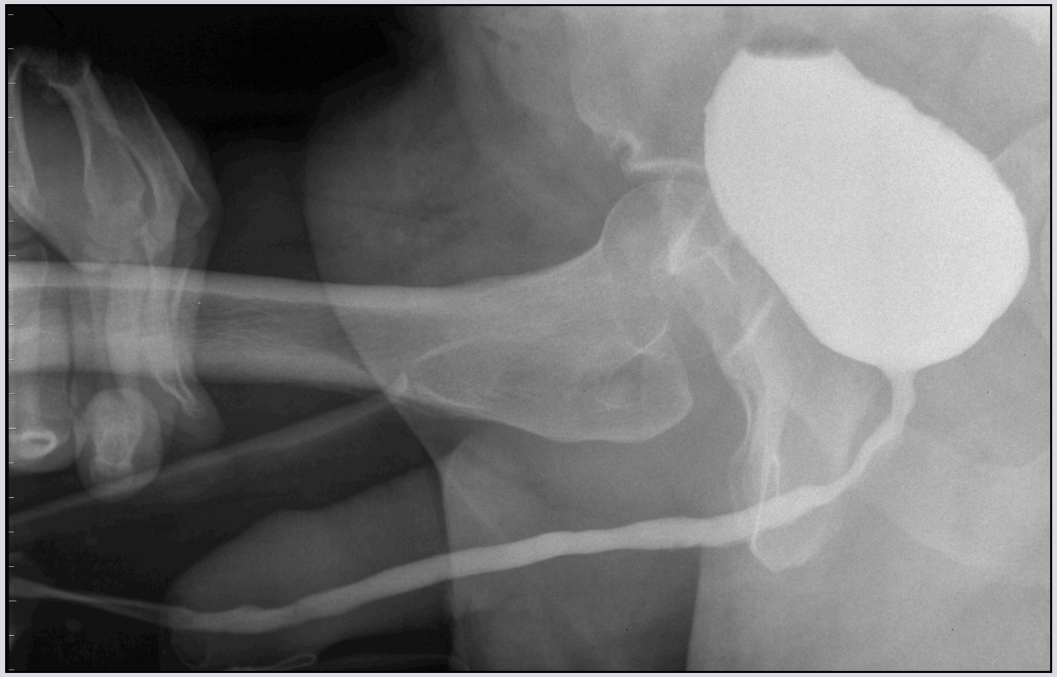

e-mail: info@urethralcenter.it

Websites: www.uretra.it
www.urethralcenter.it

CENTER FOR RECONSTRUCTIVE URETHRAL SURGERY

Oral graft

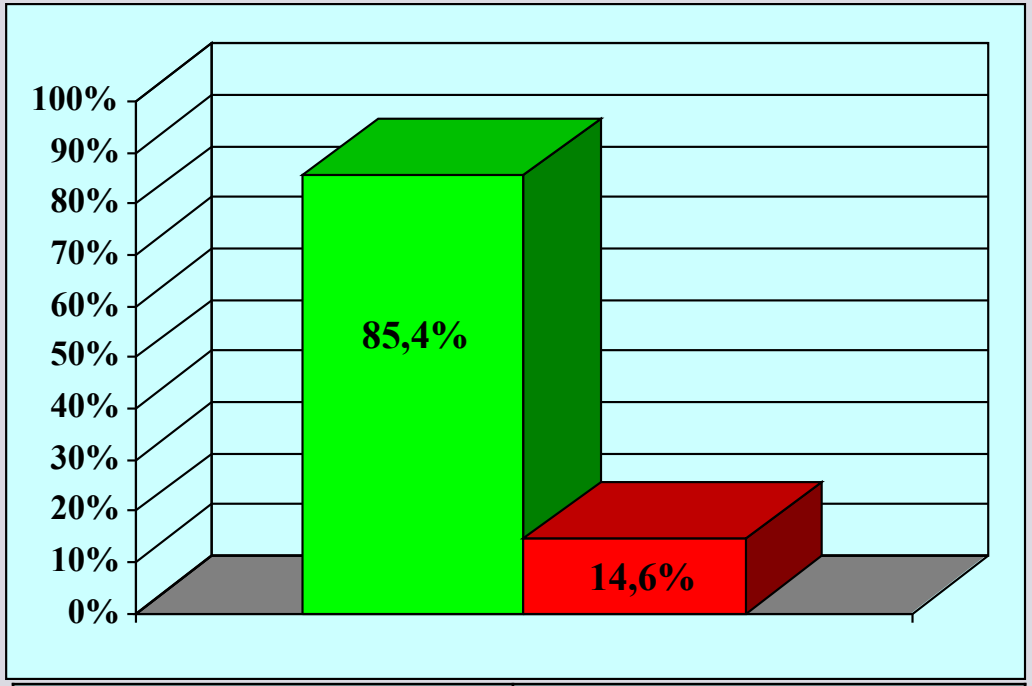

success	211 (85.4%)
failure	36 (14.6%)

	minimum	maximum	mean
Follow-up (months)	6	139	55
Age (years)	14	77	39

247 patients

Updated December 31, 2011

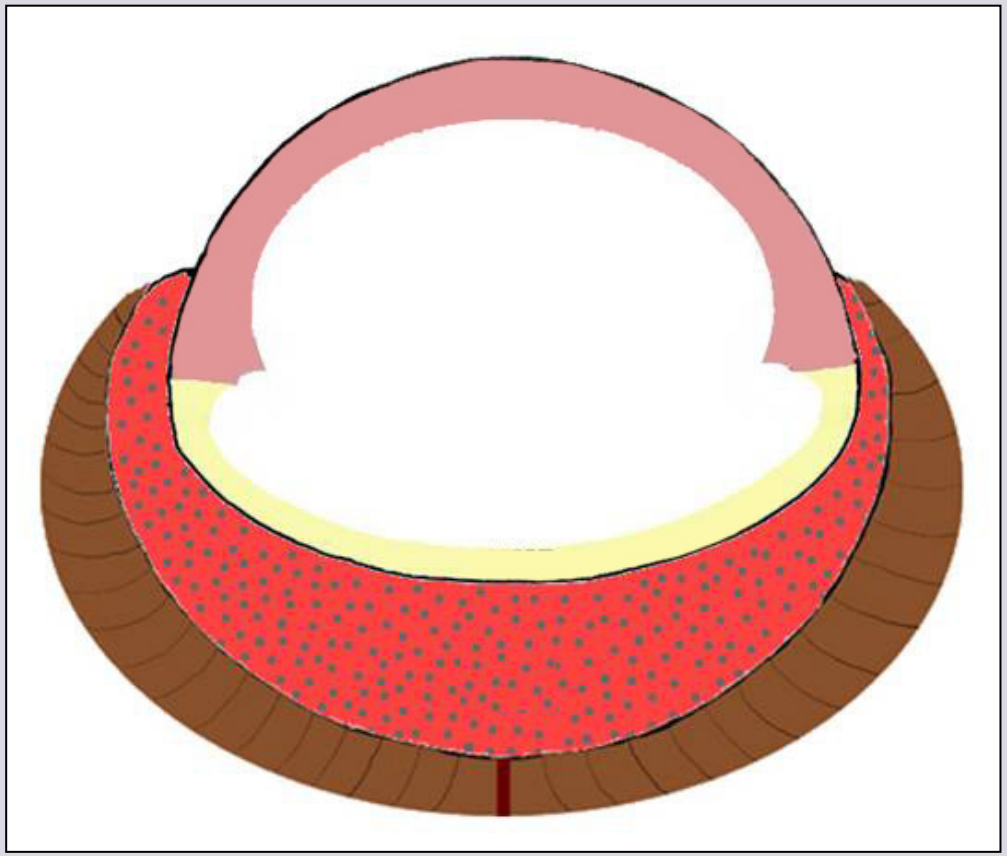

Muscle and nerve-sparing dorsal onlay graft bulbar urethroplasty

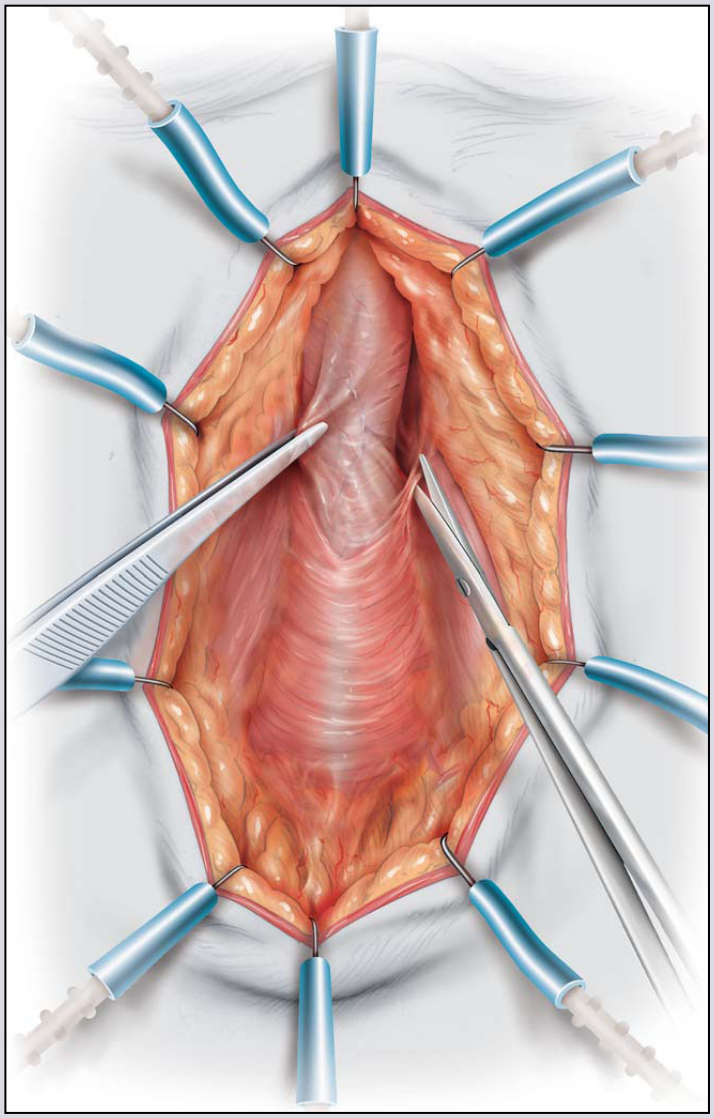

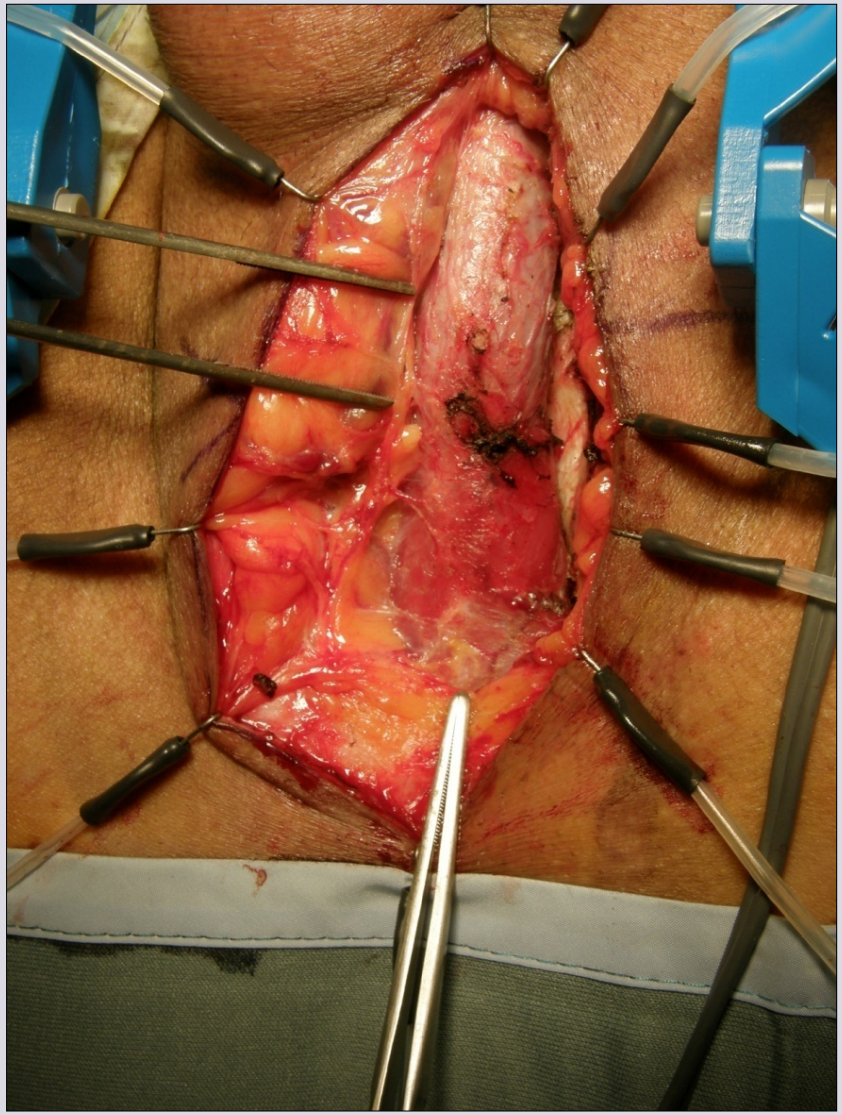

e-mail: info@urethralcenter.it

Websites: www.uretra.it
www.urethralcenter.it

CENTER FOR RECONSTRUCTIVE URETHRAL SURGERY

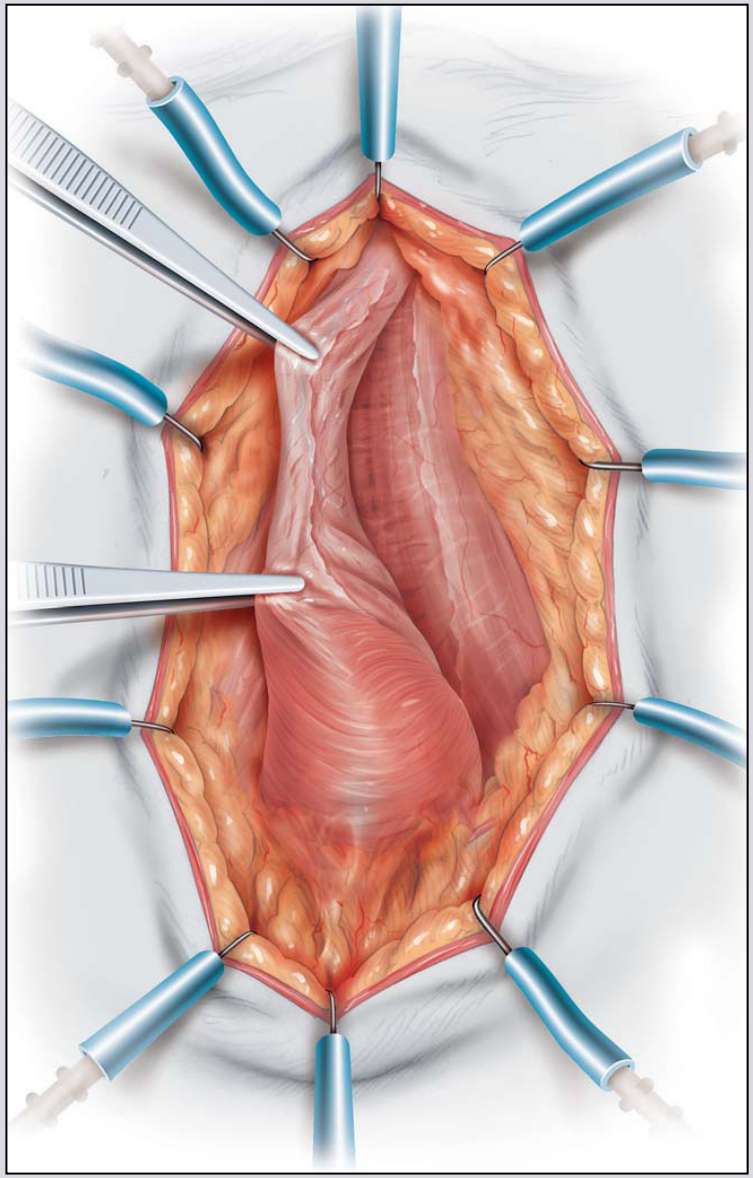

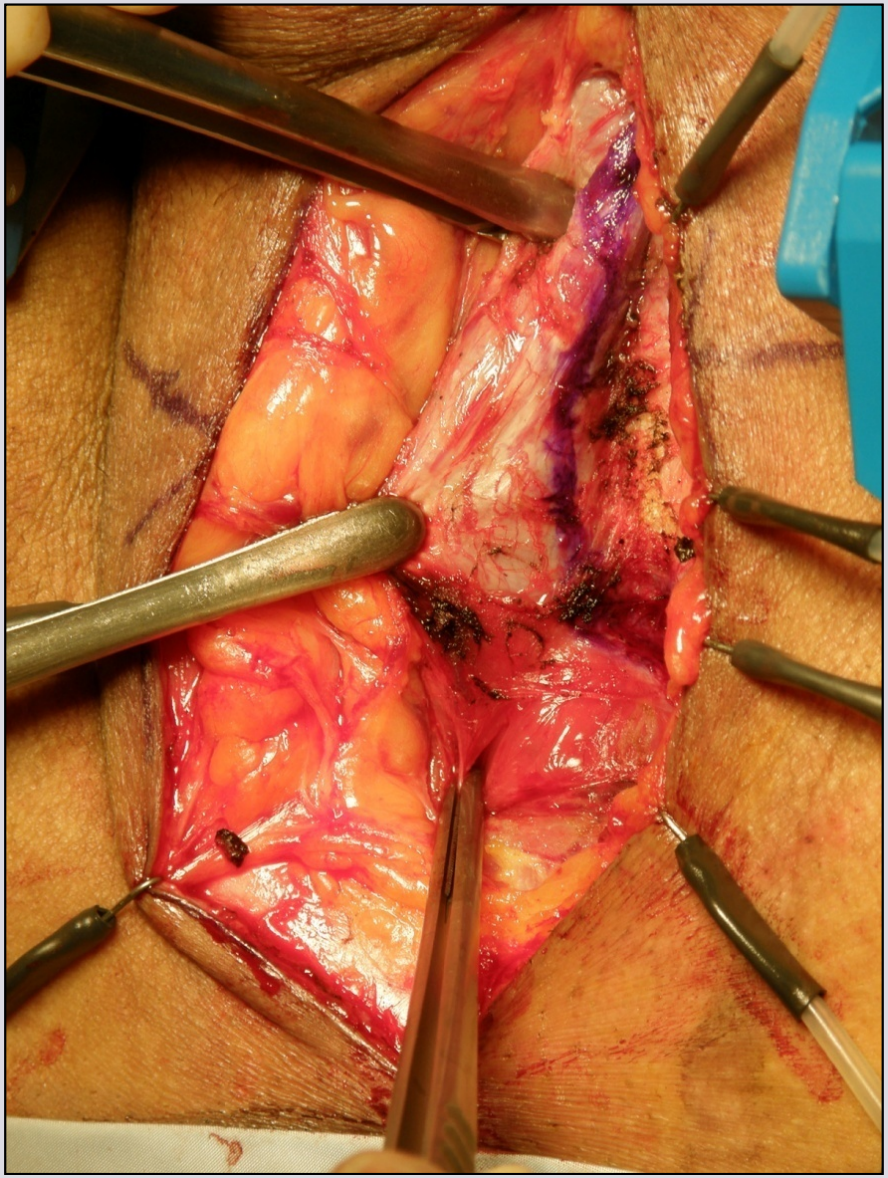

e-mail: info@urethralcenter.it

Websites: www.uretra.it
www.urethralcenter.it

CENTER FOR RECONSTRUCTIVE URETHRAL SURGERY

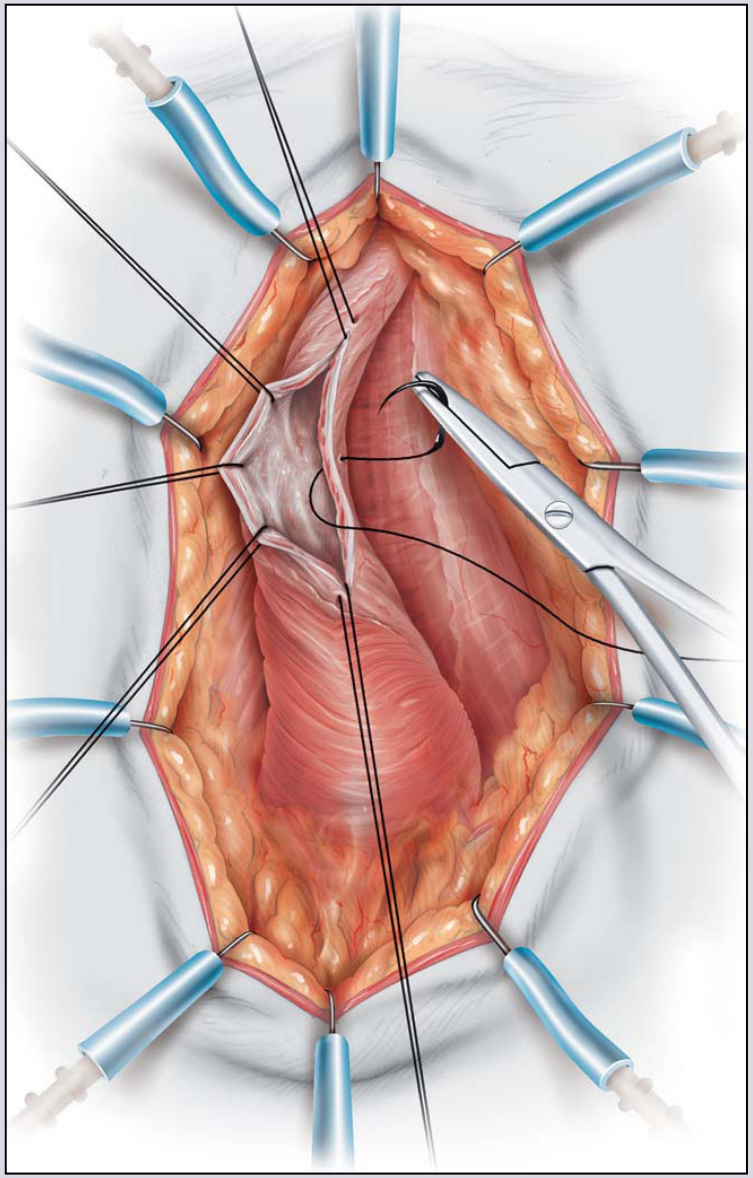

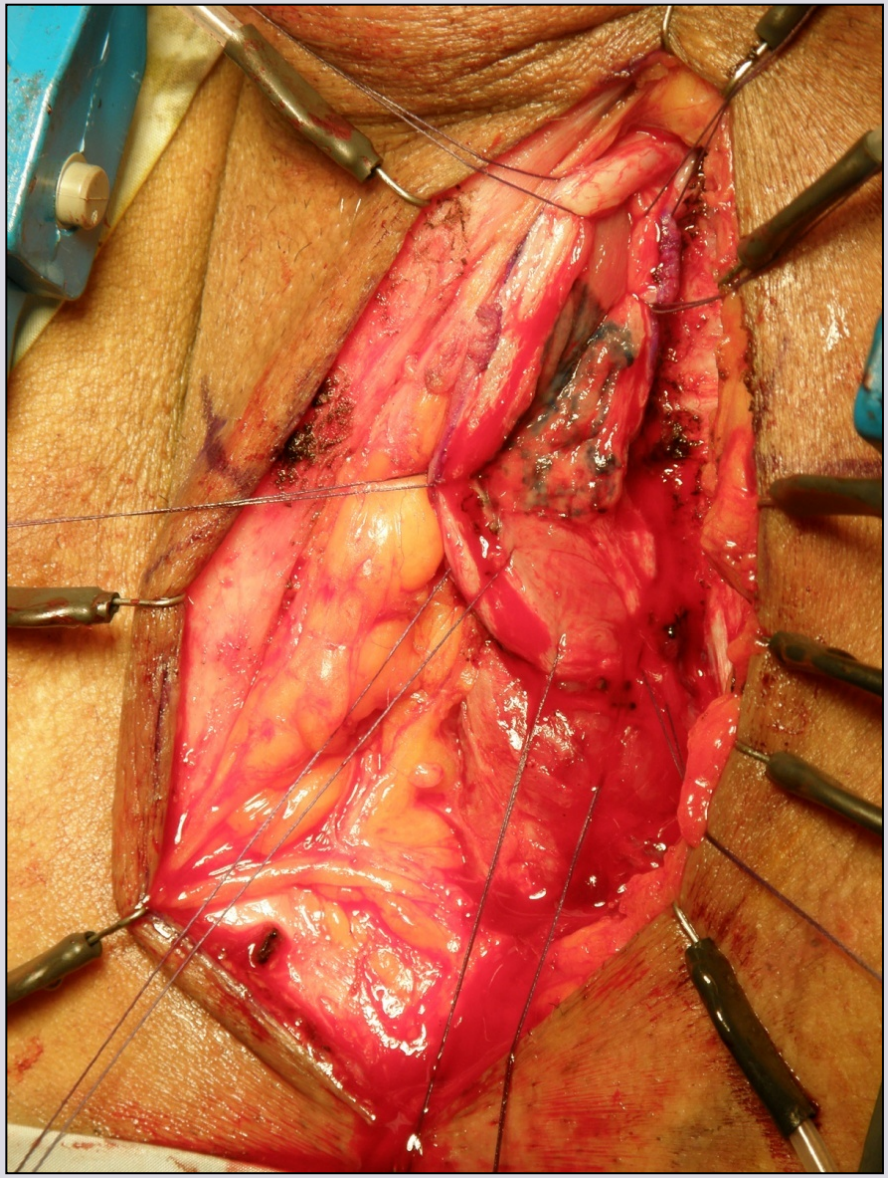

e-mail: info@urethralcenter.it

Websites: www.uretra.it
www.urethralcenter.it

CENTER FOR RECONSTRUCTIVE URETHRAL SURGERY

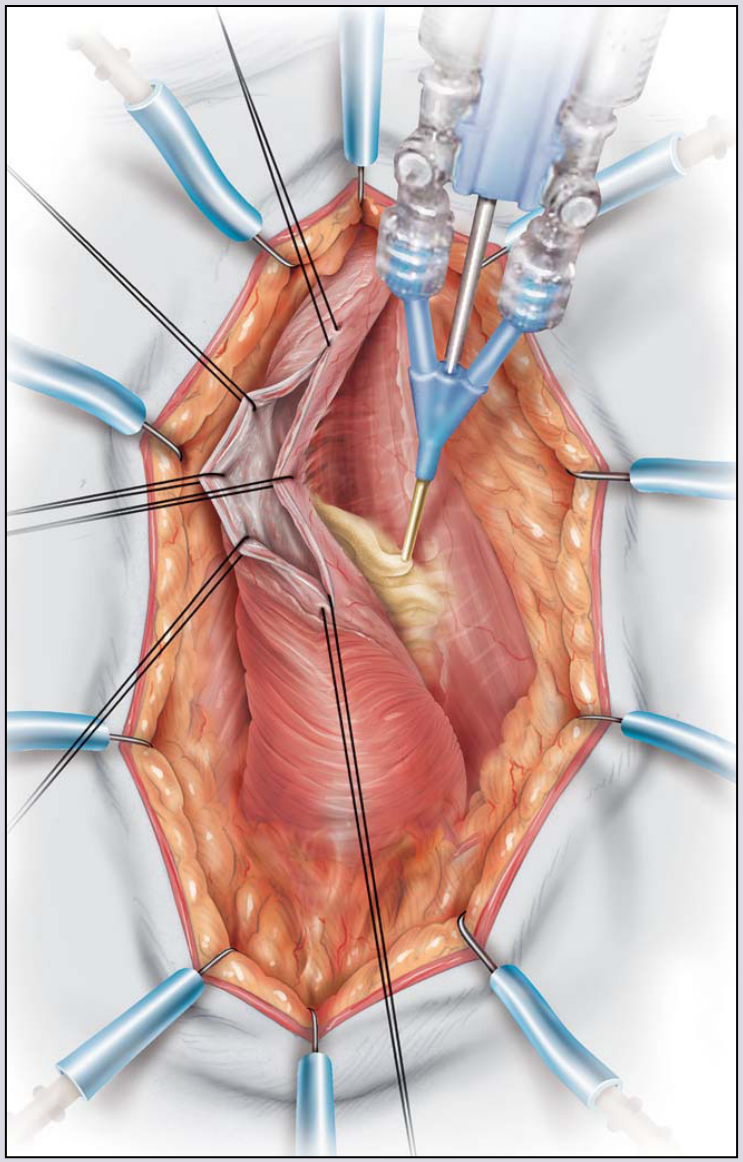

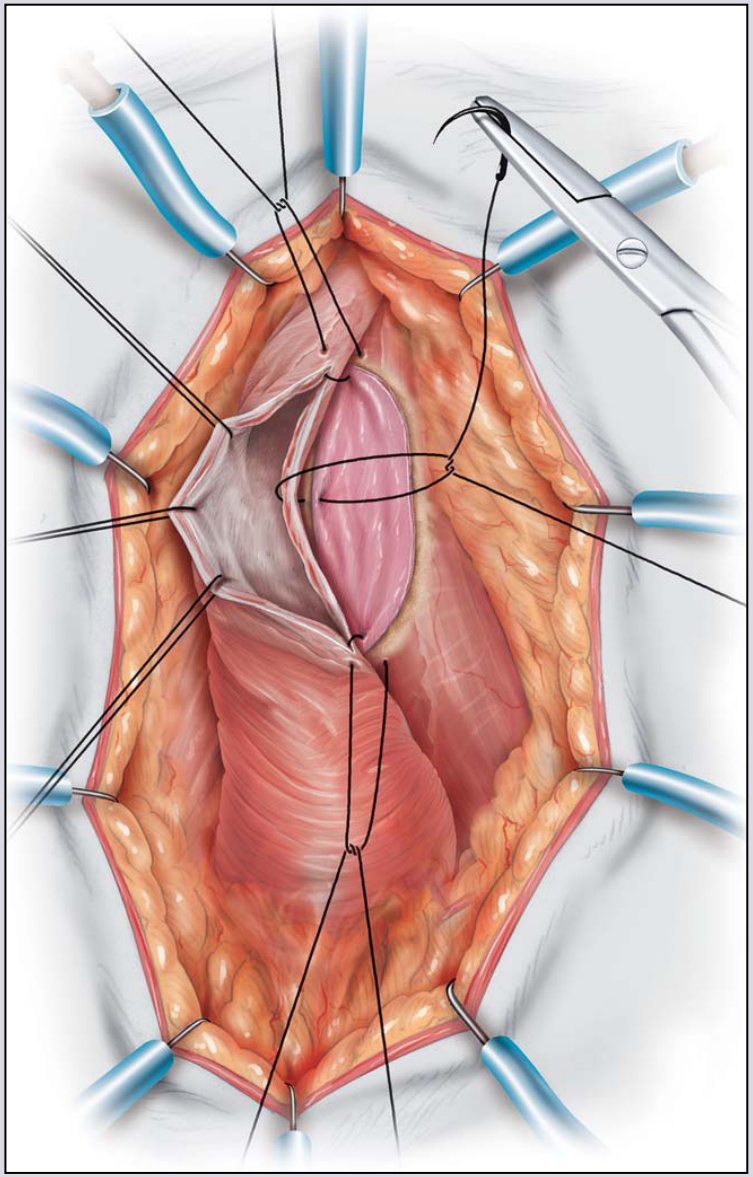

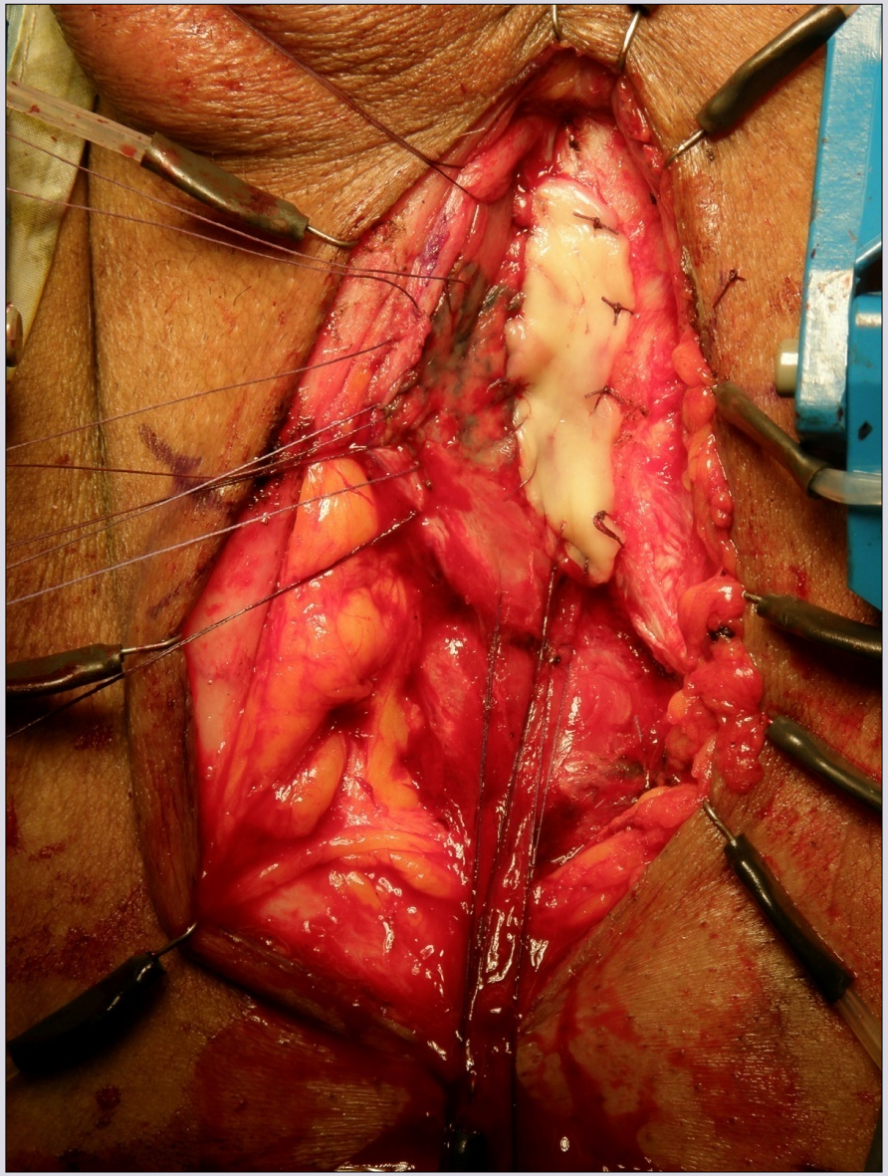

e-mail: info@urethralcenter.it

Websites: www.uretra.it
www.urethralcenter.it

CENTER FOR RECONSTRUCTIVE URETHRAL SURGERY

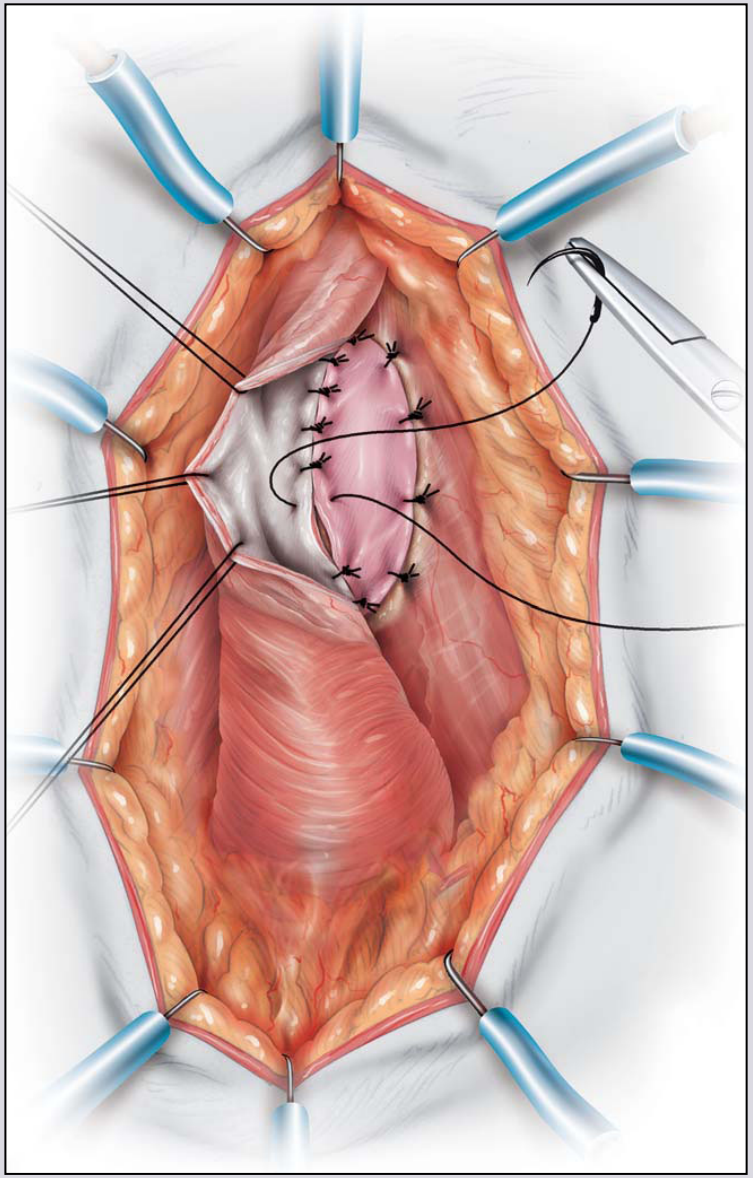

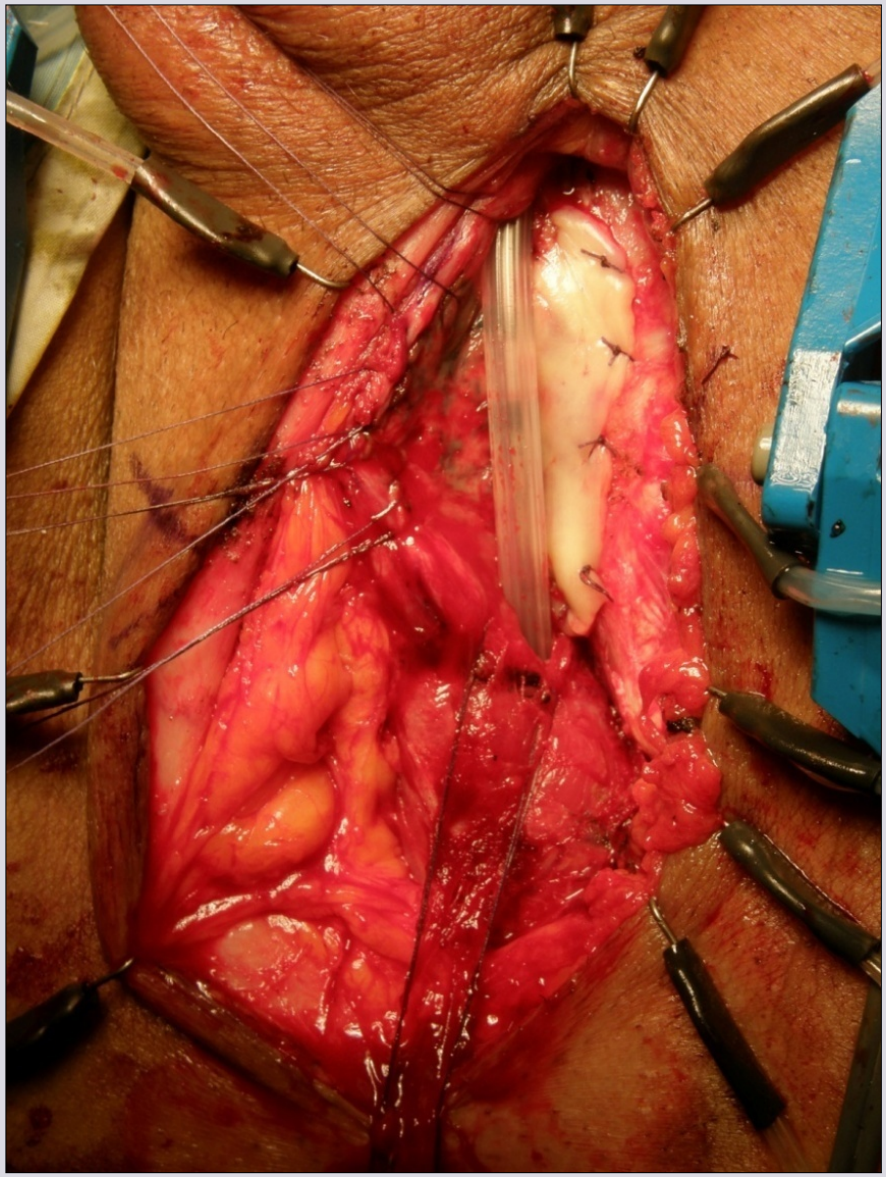

e-mail: info@urethralcenter.it

Websites: www.uretra.it
www.urethralcenter.it

CENTER FOR RECONSTRUCTIVE URETHRAL SURGERY

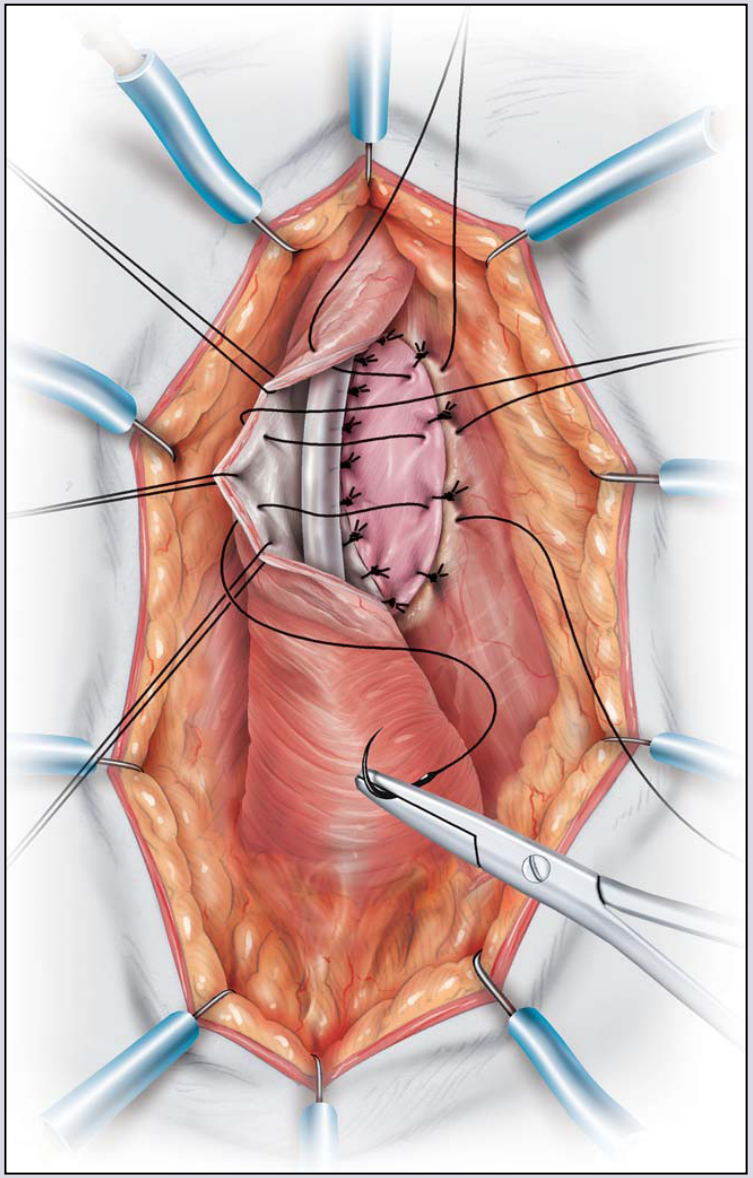

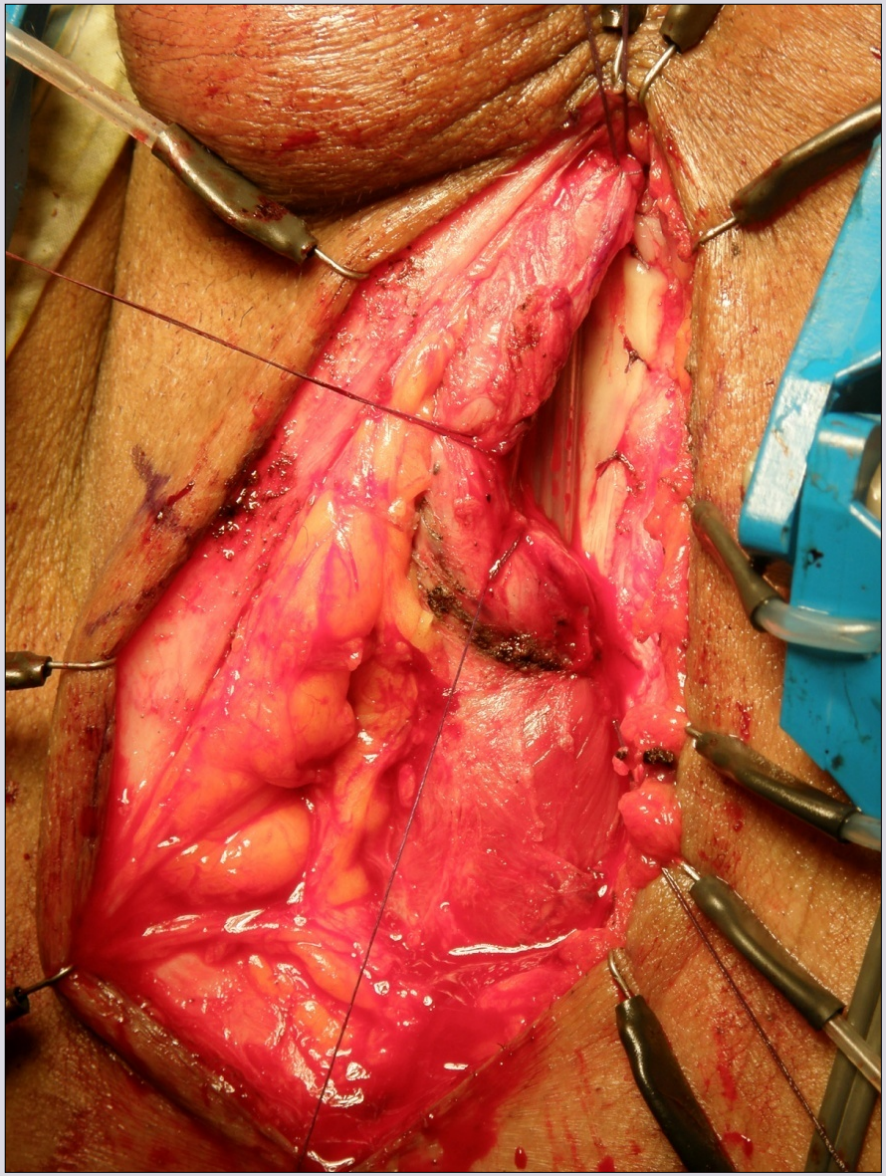

e-mail: info@urethralcenter.it

Websites: www.uretra.it
www.urethralcenter.it

CENTER FOR RECONSTRUCTIVE URETHRAL SURGERY

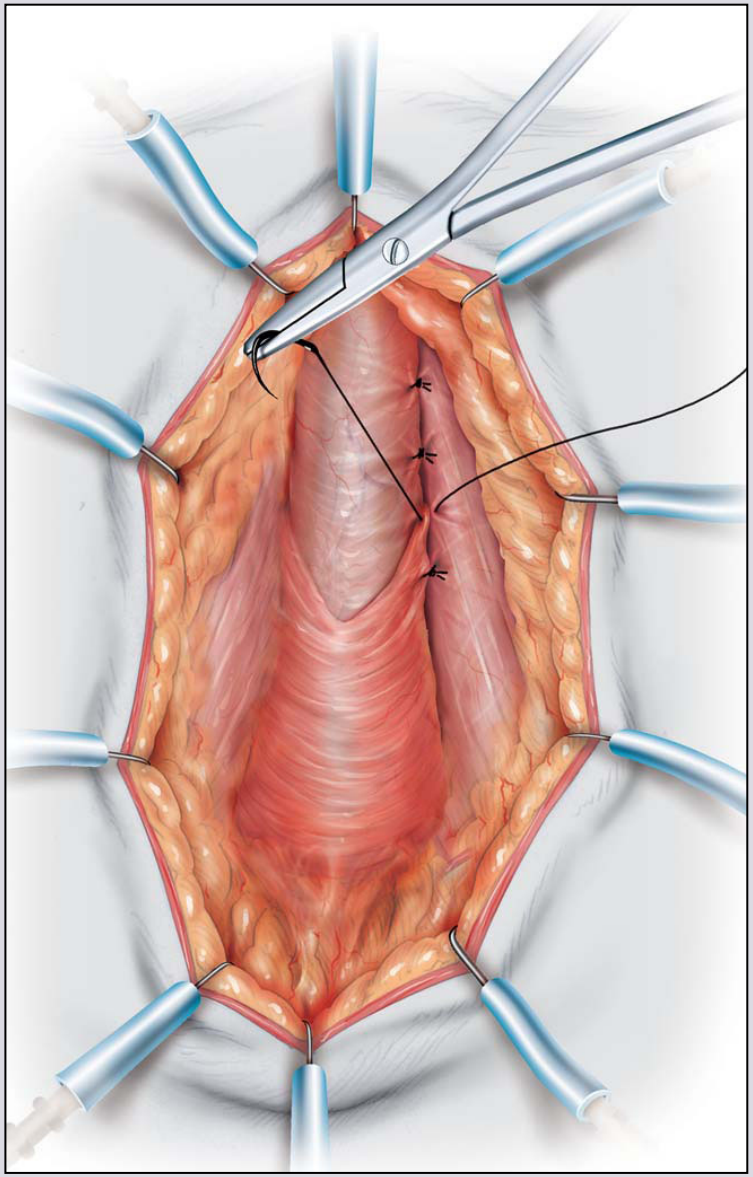

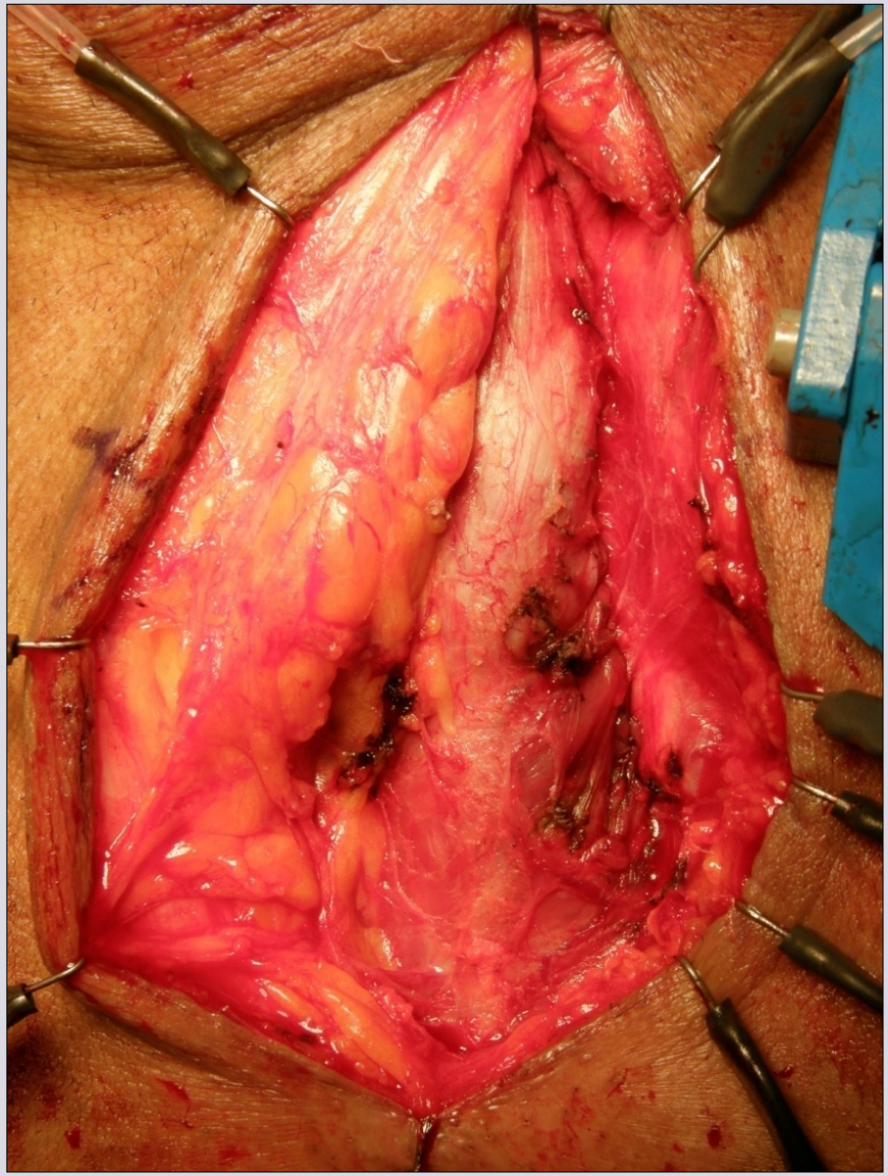

e-mail: info@urethralcenter.it

Websites: www.uretra.it
www.urethralcenter.it

CENTER FOR RECONSTRUCTIVE URETHRAL SURGERY

Oral graft

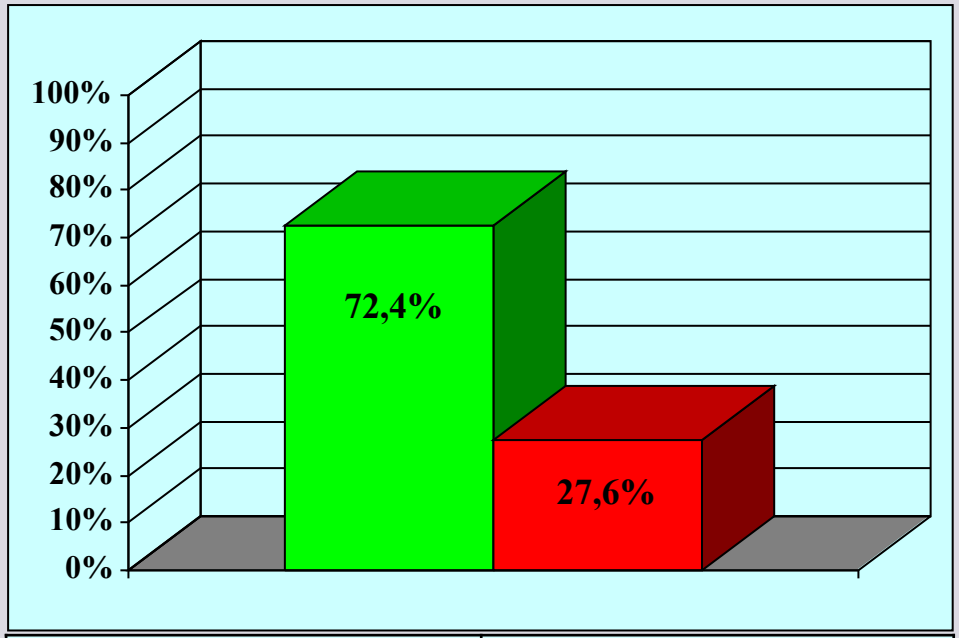

success	21 (72.4%)
failure	8 (27.6%)

	minimum	maximum	mean
Follow-up (months)	7	158	76
Age (years)	24	77	42

29 patients

Updated December 31, 2011

Conclusions

In the era of robotic surgery, it is also time to change urethral surgery!

- **Increase the use of minimally invasive techniques in urethroplasty, reducing the incidence of complications and improving patient quality of life.**

How to learn bulbar urethral surgery?

To be read !

0022-5347/93/1492-0276$03.00/0
THE JOURNAL OF UROLOGY
Copyright © 1993 by AMERICAN UROLOGICAL ASSOCIATION, INC.
Vol. 149, 276–278, February 1993
Printed in U.S.A.

THE USE OF BUCCAL MUCOSA PATCH GRAFT IN THE MANAGEMENT OF ANTERIOR URETHRAL STRICTURES

A. W. EL-KASABY, M. FATH-ALLA, A. M. NOWEIR, M. R. EL-HALABY, W. ZAKARIA AND M. H. EL-BEIALY

From the Department of Urology, Ain-Shams University, Cairo, Egypt

Journal of Urology, 1993; 149: 276 - 278

0022-5347/96/1555-1696$03.00/0
THE JOURNAL OF UROLOGY
Copyright © 1996 by AMERICAN UROLOGICAL ASSOCIATION, INC.
Vol. 155, 1696–1697, May 1996
Printed in U.S.A.

TECHNIQUE OF HARVESTING BUCCAL MUCOSA FOR URETHRAL RECONSTRUCTION

ALLEN F. MOREY AND JACK W. MCANINCH*

From the Department of Urology, University of California School of Medicine and San Francisco General Hospital, San Francisco, California

Journal of Urology, 1996; 155: 1696 - 1697

e-mail: info@urethralcenter.it Websites: www.uretra.it www.urethralcenter.it
CENTER FOR RECONSTRUCTIVE URETHRAL SURGERY



FIG. 1. Steinhäuser mucosa stretcher. Upper blade forms 6 × 4 cm. frame around donor site.

History of urethral surgery

The use of double team

Harvesting the oral graft from the cheek

The use of special mouth retractor

WHEN AND HOW TO USE BUCCAL MUCOSAL GRAFTS IN ADULT BULBAR URETHROPLASTY

ALLEN F. MOREY AND JACK W. McANINCH

Urology, 1996; 48: 194 - 198

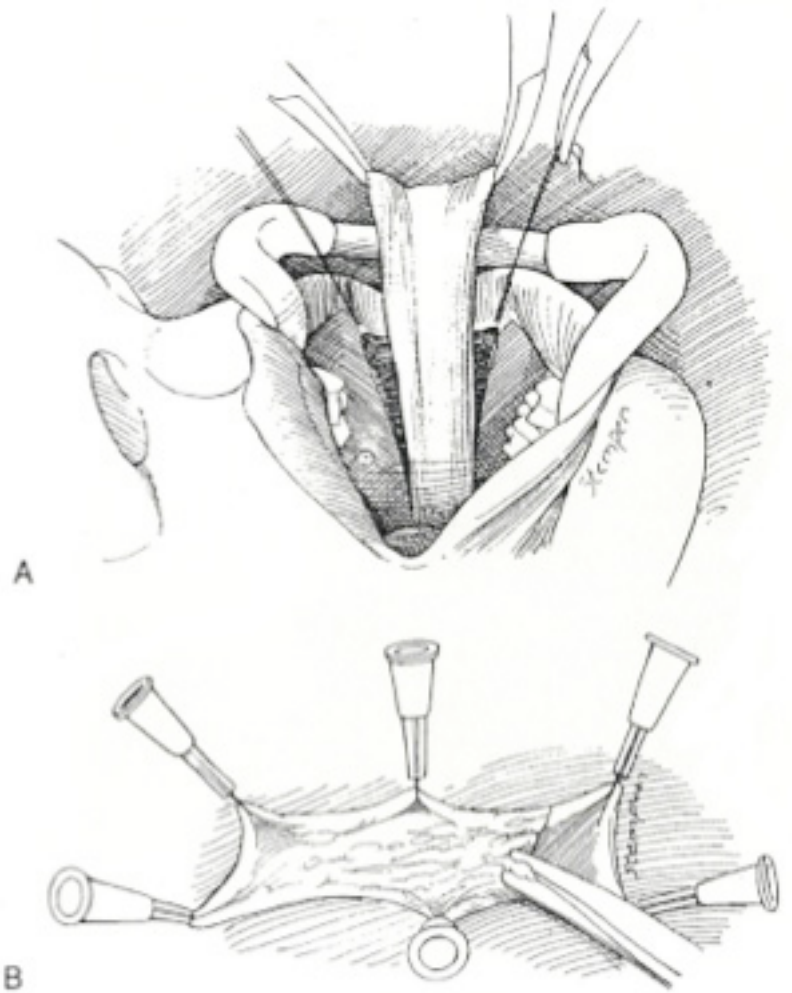

FIGURE 1. *(A) The inner cheek is the preferred site for harvesting buccal mucosal grafts. The graft should be taken from below Stensen's duct, which can be identified in the area of the upper second molar by compressing the parotid gland. (B) The graft is carefully thinned and tailored on a vein board before urethral anastomosis.*

0022-5347/96/1551-0123$03.00/0
THE JOURNAL OF UROLOGY
Copyright © 1996 by AMERICAN UROLOGICAL ASSOCIATION, INC.
Vol. 155, 123–126, January 1996
Printed in U.S.A.

DORSAL FREE GRAFT URETHROPLASTY

GUIDO BARBAGLI, CESARE SELLI, ALDO TOSTO AND ENZO PALMINTERI

From the Department of Urology, University of Florence, Florence, Italy

Journal of Urology, 1996; 155: 123 - 126

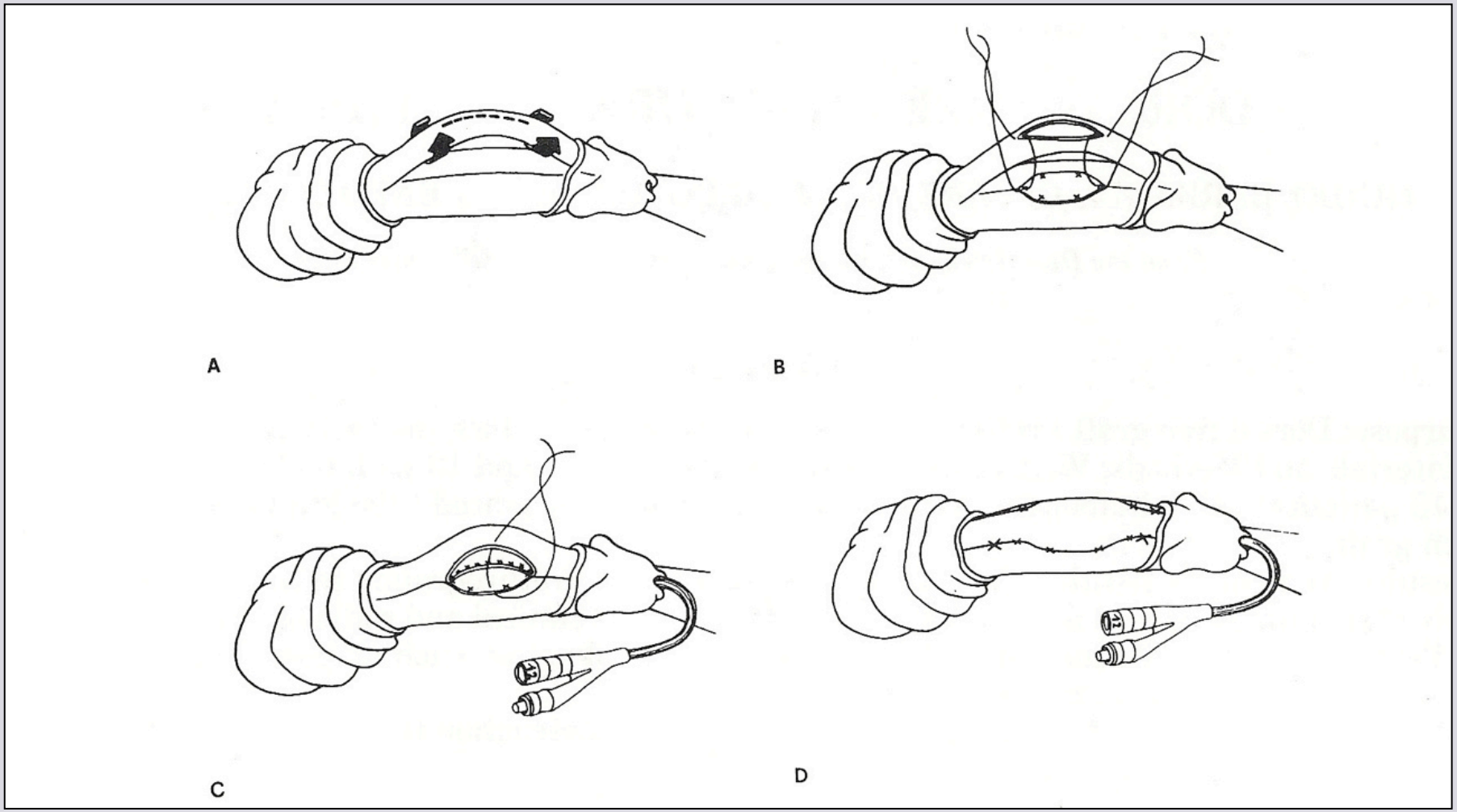
A
B
C
D

British Journal of Urology (1996), **78**, 929–932

A one-stage dorsal free-graft urethroplasty for bulbar urethral strictures

G. BARBAGLI, C. SELLI, V. di CELLO and A. MOTTOLA
Department of Urology, University of Florence, Florence, Italy

British Journal of Urology, 1996; 78: 929 - 932

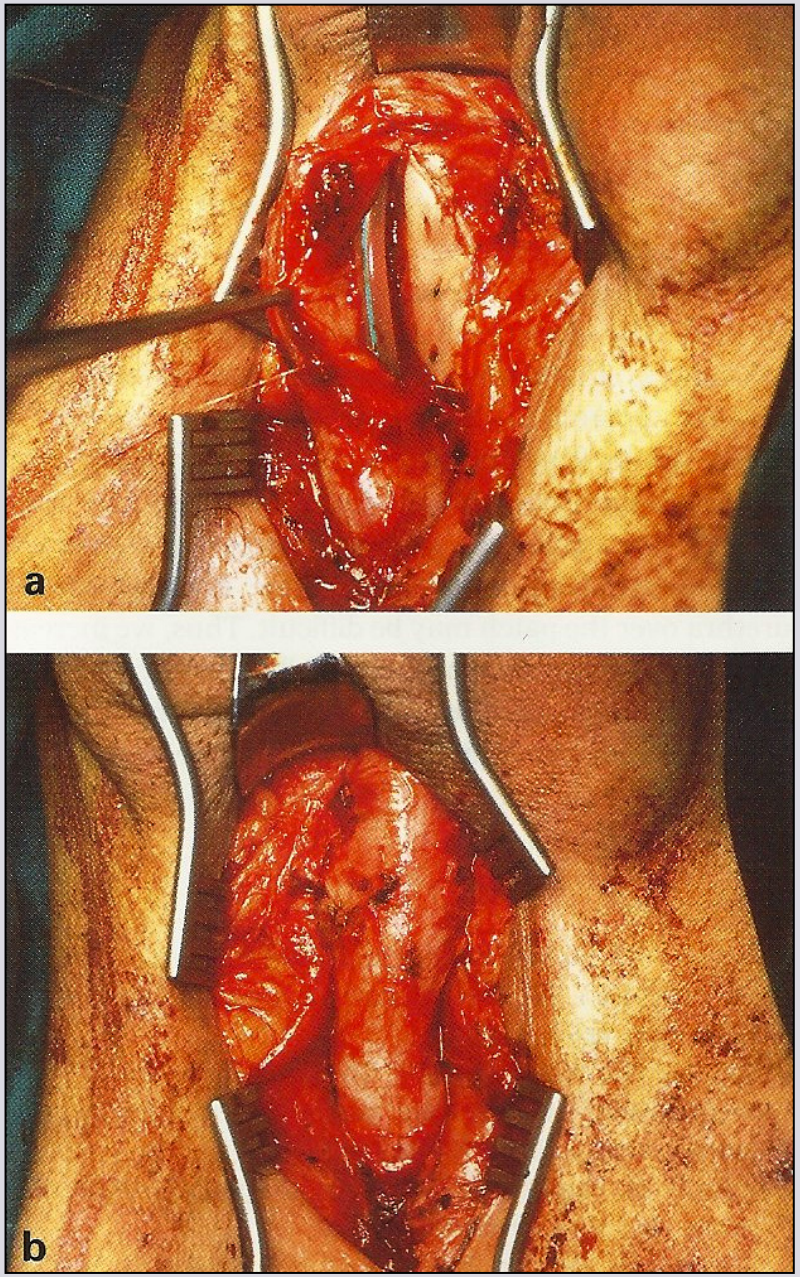
a
b

0022-5347/01/1655-1496/0
THE JOURNAL OF UROLOGY®
Copyright © 2001 by AMERICAN UROLOGICAL ASSOCIATION, INC.®
Vol. 165, 1496–1501, May 2001
Printed in U.S.A.

THE AUGMENTED ANASTOMOTIC URETHROPLASTY: INDICATIONS AND OUTCOME IN 29 PATIENTS

MICHAEL L. GURALNICK* AND GEORGE D. WEBSTER

From the Division of Urologic Surgery, Duke University Medical Center, Durham, North Carolina

Journal of Urology, 2001; 165: 1496 - 1501

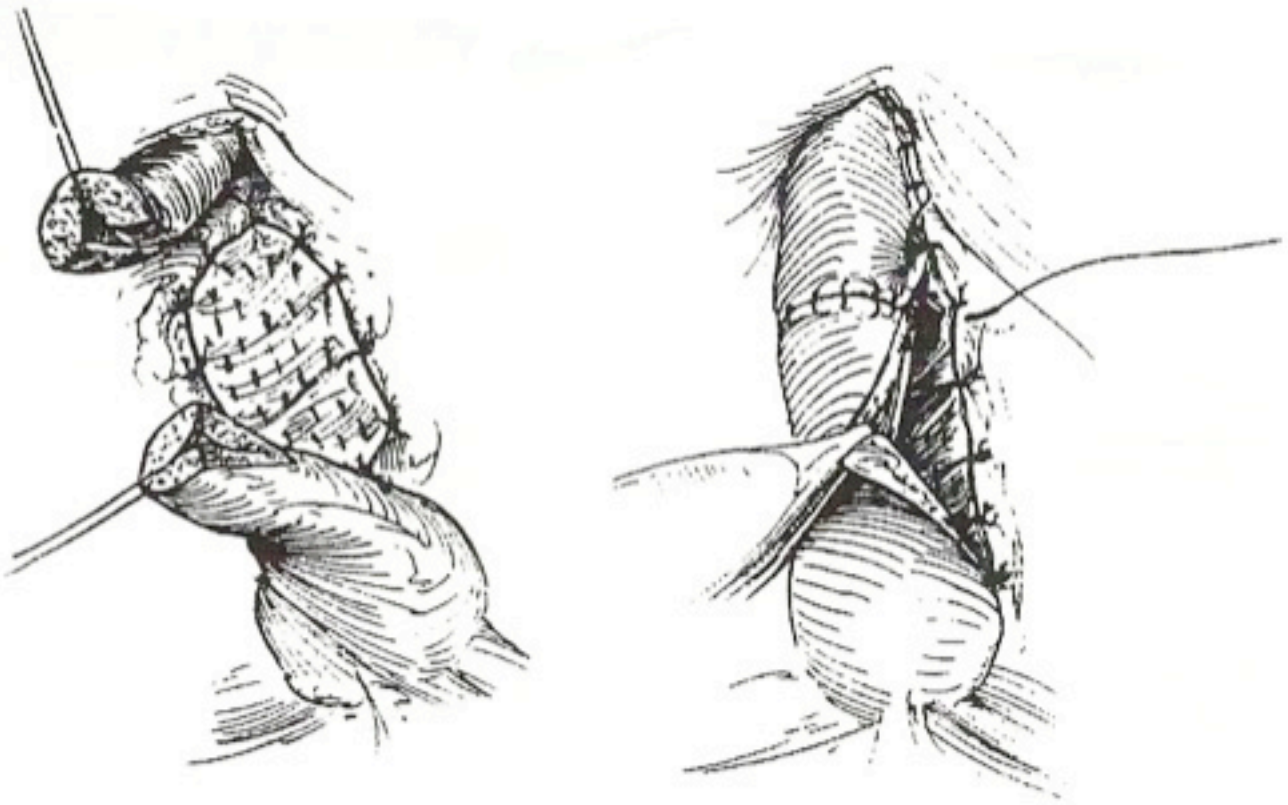

FIG. 1. Floor strip anastomosis with dorsal onlay graft. Graft is spread fixed to corporal bodies and free urethral ends are anastomosed ventrally in floor strip anastomosis after stricture excision and ipsilateral dorsal spatulations into healthy urethra. Urethral margins are then sewn to overlying graft (Iselin, C. E. and Webster, G. D.: Dorsal onlay urethroplasty for urethral stricture repair. World J Urol, **16:** 181, 1996, reprinted with permission).

Register now !

www.webon.uretra.it

www.urethralcenter.it
www.uretra.it

Next month, this lecture will be fully available on our websites

Thank you !