CENTER FOR RECONSTRUCTIVE URETHRAL SURGERY

GUIDO BARBAGLI, M.D.
Arezzo - Italy

e-mail: info@urethralcenter.it

Websites: www.uretra.it
www.urethralcenter.it

Centro Chirurgico Toscano
Arezzo – Italy
www.centrochirurgicotoscano.it

e-mail: info@urethralcenter.it
www.uretra.it
Websites: www.urethralcenter.it

Harvesting the Oral Mucosa: Surgical Tips and Tricks

e-mail: info@urethralcenter.it
www.uretra.it
Websites: www.urethralcenter.it

The Mouth

Harvesting Sites

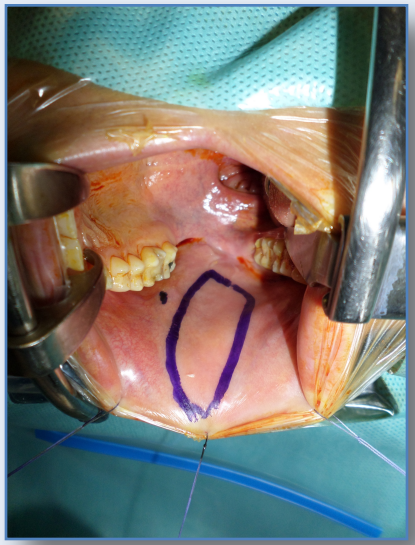

Cheek

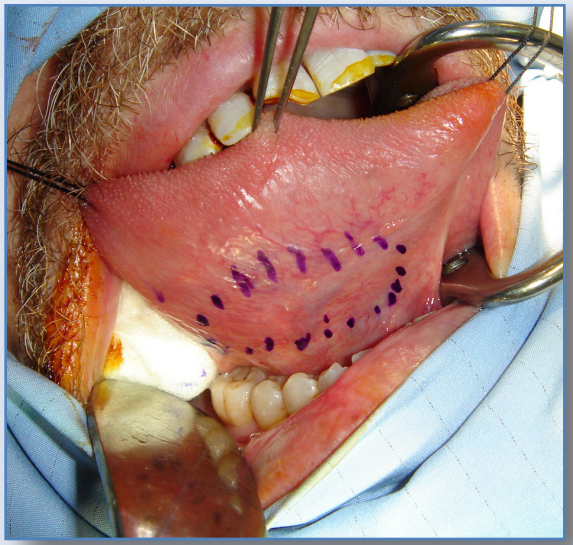

Tongue

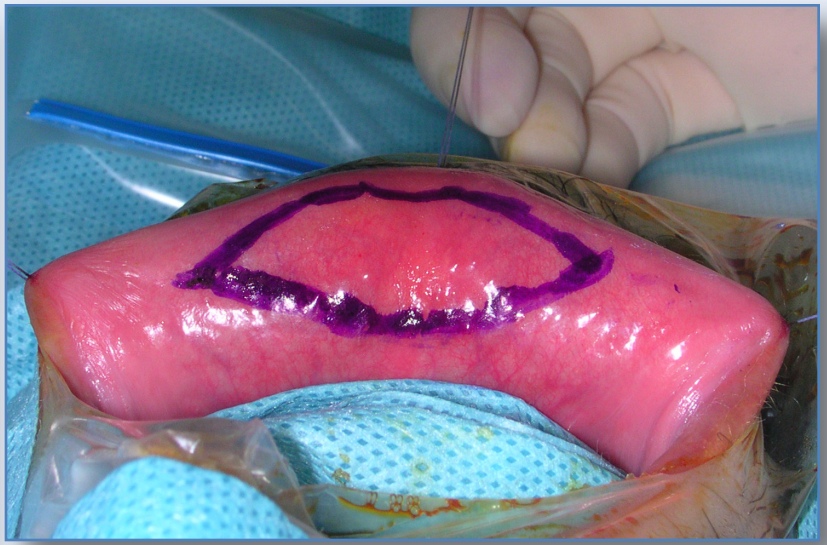

Lip

20 cm

Harvesting Sites

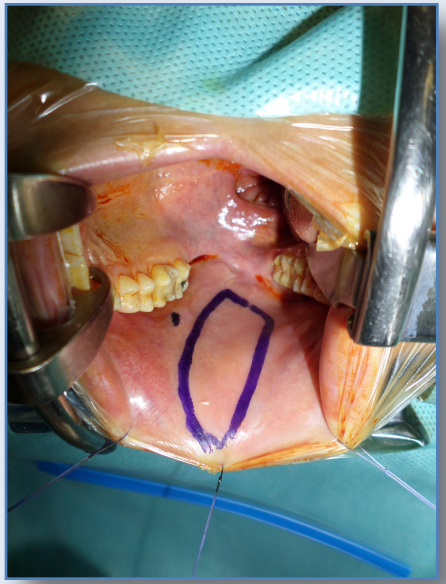

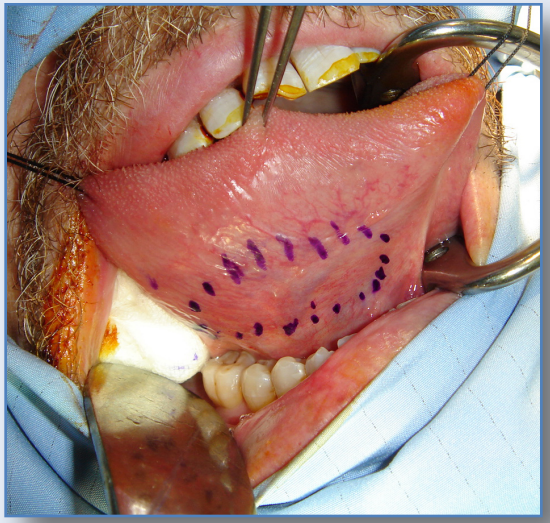

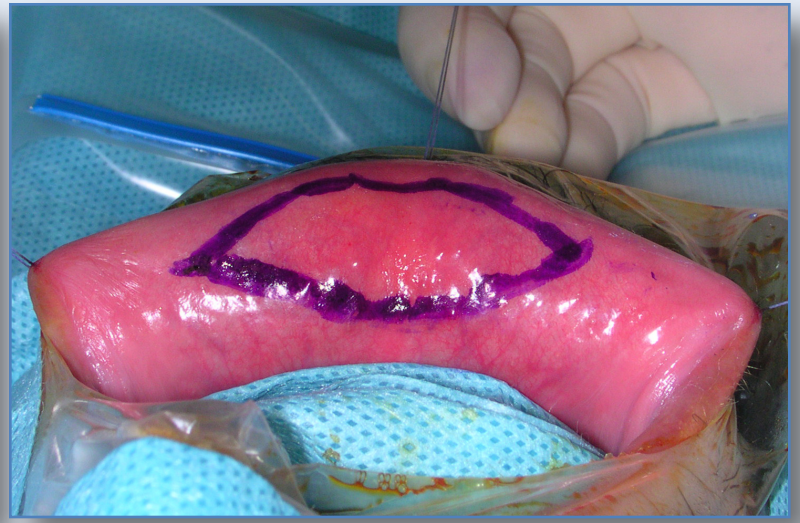

Cheek:

Preferred site
Bilateral harvesting
No complications
Big vs small graft

Tongue:

Alternative site
Smoller graft
Post-operative complications

Lip:

Children
Small and thin graft
Post-operative complications

Harvesting Oral Mucosa from the Cheek

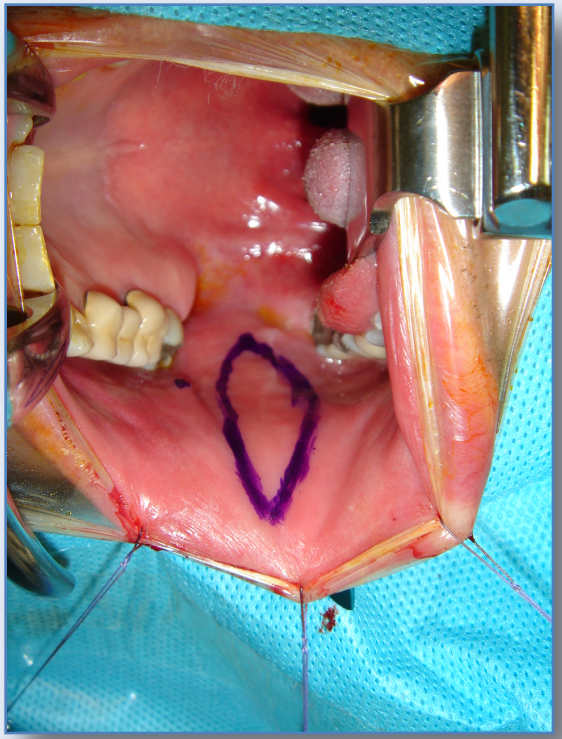

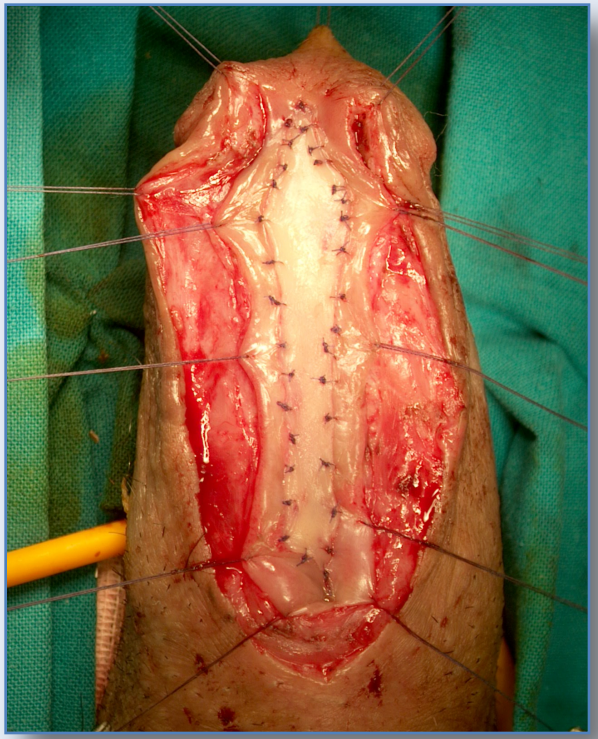

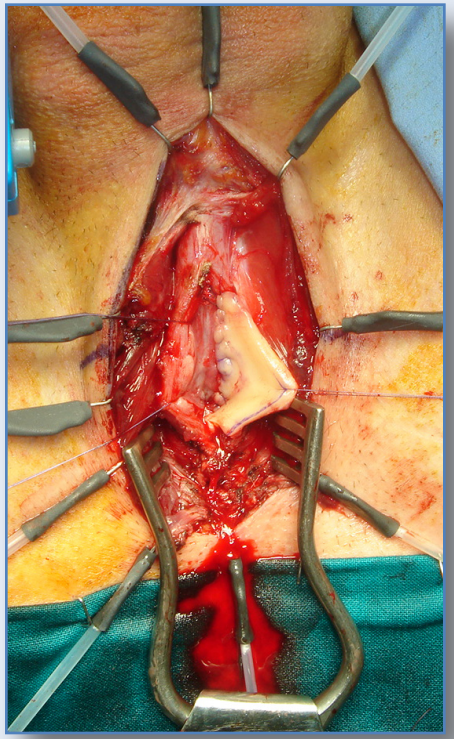

Ovoidal graft 4/5 cm X 2.5 cm for any penile or bulbar one-stage urethroplasty

e-mail: info@urethralcenter.it
www.uretra.it
Websites: www.urethralcenter.it

Harvesting Oral Mucosa from the Cheek

Rectanglular graft 4 X 4 cm for penile two-stage urethroplasty

Closure vs Non-closure of the Harvesting Site

Ovoidal graft

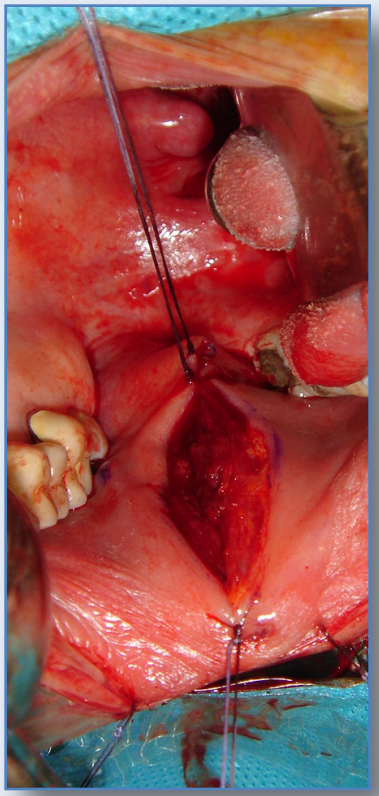

closure

Rectangular graft

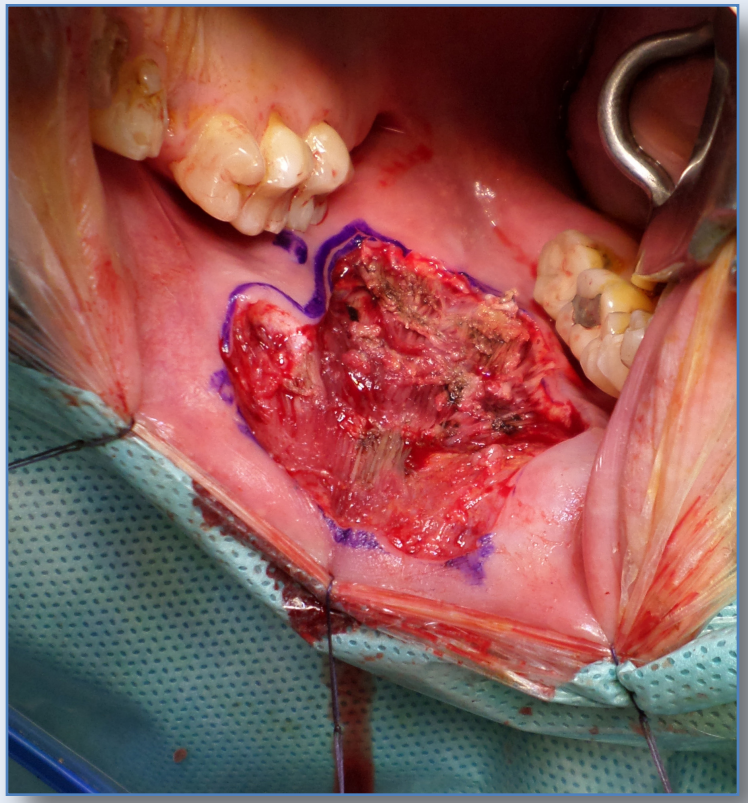

non-closure

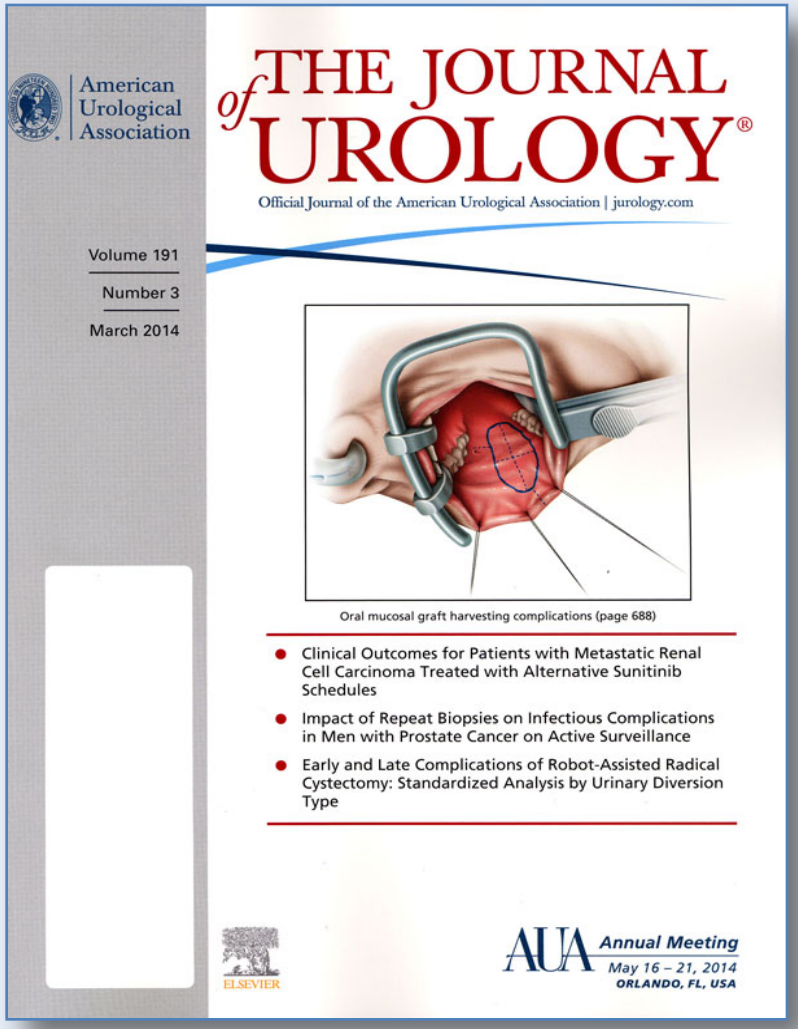

553 patients

J UROL 2014; 191: 688-693

VIDEO 5

How to Harvest Lingual Mucosal Graft

The Tongue as an Alternative Donor Site for Graft Urethroplasty: A Pilot Study

Alchiede Simonato,* Andrea Gregori, Andrea Lissiani, Stefano Galli, Francesco Ottaviani, Roberta Rossi, Anna Zappone and Giorgio Carmignani

From the Department of Urology "Luciano Giuliani," University of Genoa (AS, GC), Genoa and Departments of Urology (AG, AL), Pathology (RR) and Anesthesiology and Intensive Care (AZ), and Otorhinolaryngological Clinic IV (FO), "Luigi Sacco" University Medical Center (SG), Milan, Italy

---

Purpose: Urethroplasty with a buccal mucosal graft provides excellent clinical results but it may also cause oral complications in some cases. The mucosa covering the lateral and under surface of the tongue is identical in structure with that lining the rest of the oral cavity. We evaluated LMGs for urethroplasty.

Materials and Methods: From January 2001 to September 2004, 8 men 34 to 65 years old (mean age 46.1) with urethral strictures 1.5 to 4.5 cm long were selected for 1-stage dorsal onlay urethroplasty. The site of the harvest graft was the lateral mucosal lining of the tongue. Postoperatively all patients were followed with urethrography, uroflowmetry, cystourethrography and flexible urethroscopy after 3 and 12 months. Successful reconstruction criteria were peak flow rate greater than 15 ml per second and no need for postoperative urethral dilation.

Results: Median followup was 18 months (mean 22.1, range 3 to 47). Seven cases were successful. One patient had a partial urethral stricture. In successful cases cystourethrography revealed no significant graft contractures or sacculations and at flexible urethroscopy LMG was almost indistinguishable from native urethra. There were no pain, esthetic or functional complications at the donor site.

Conclusions: Harvesting the LMG is feasible and easy to perform. Compared with the buccal mucosal graft the LMG seems to be associated with less postoperative pain and a minor risk of donor site complications. These preliminary functional and esthetic data are satisfactory.

J Urol 2006; 175: 589-592

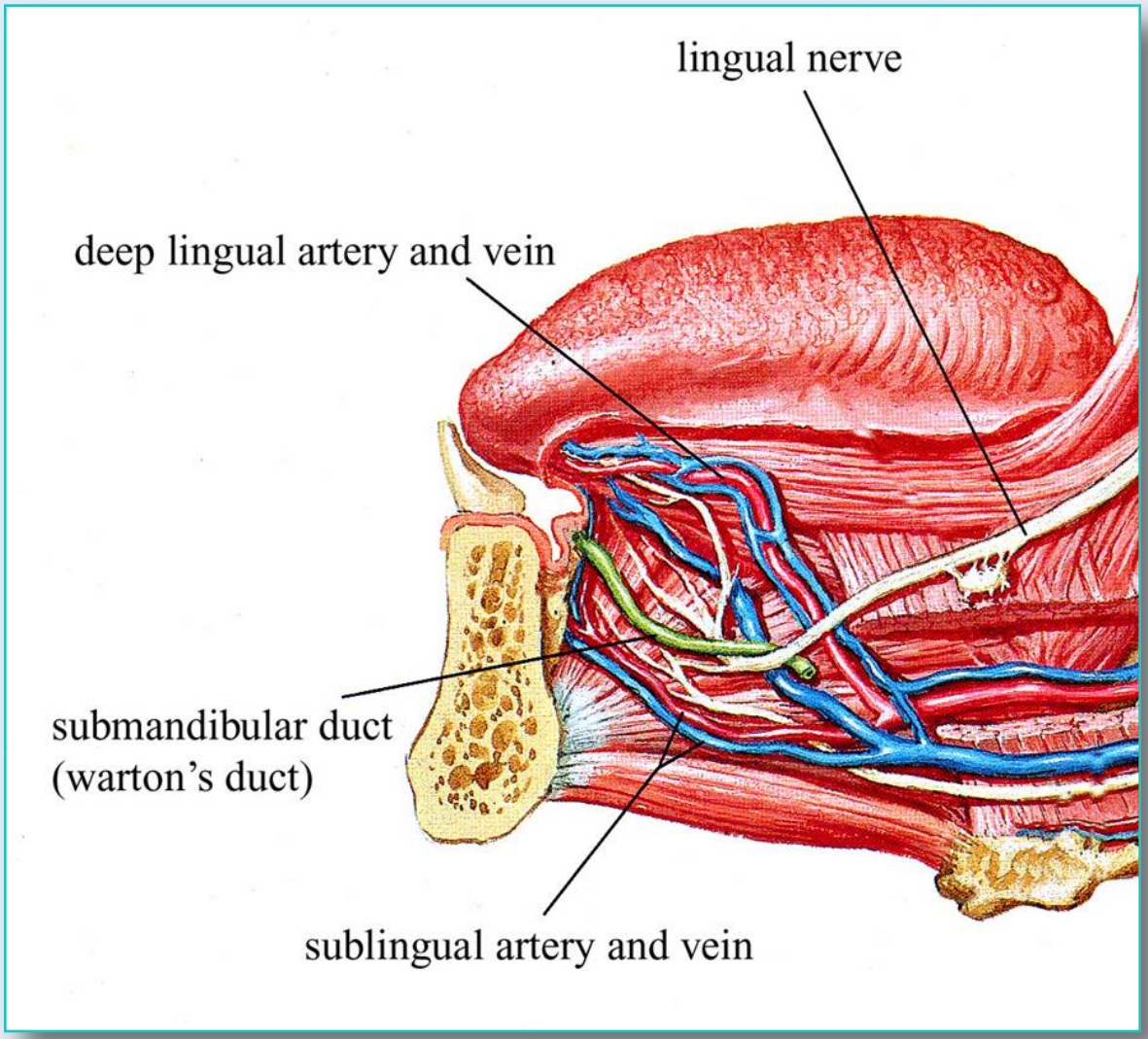
lingual nerve
deep lingual artery and vein
submandibular duct
(warton's duct)
sublingual artery and vein

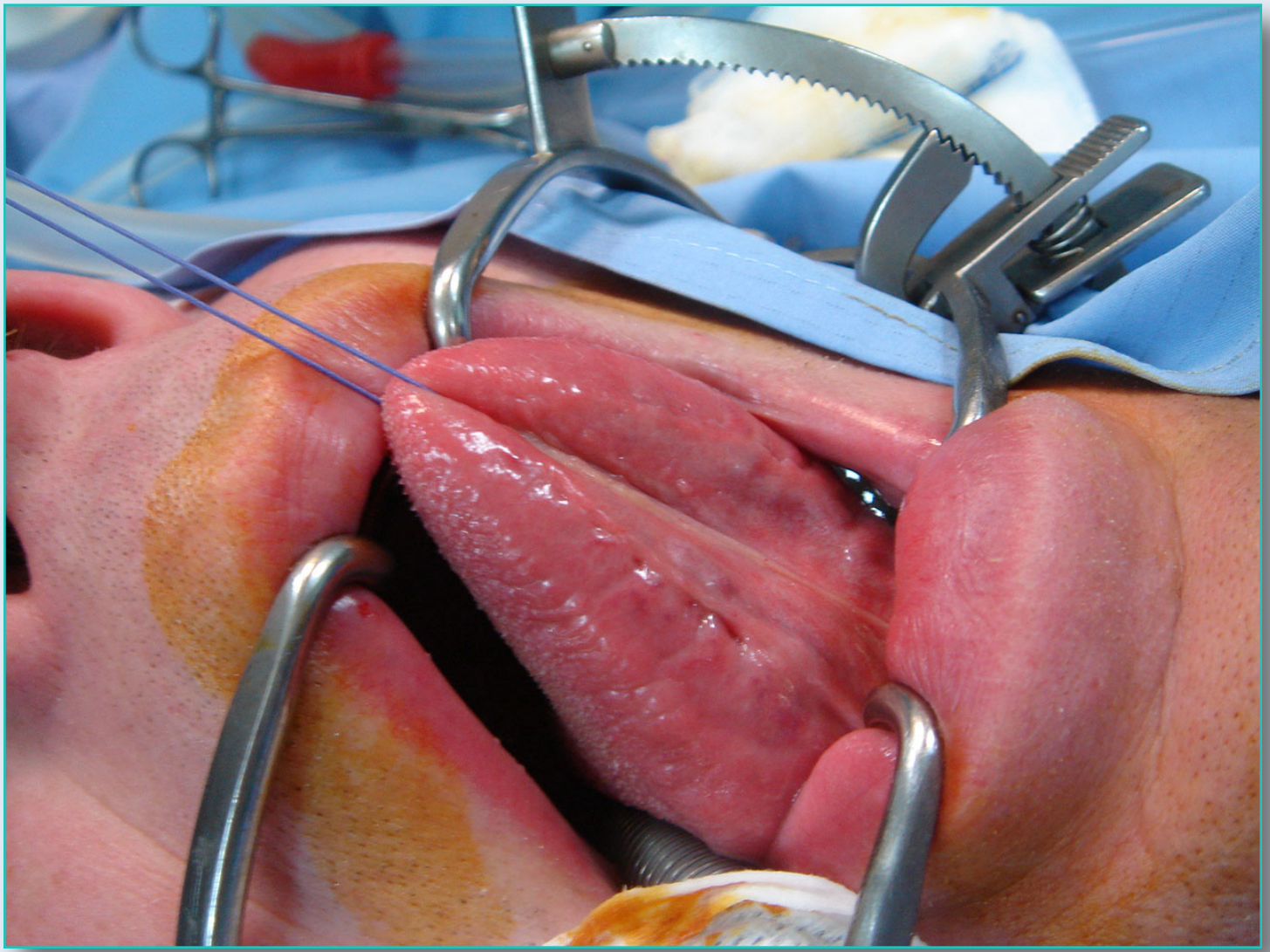

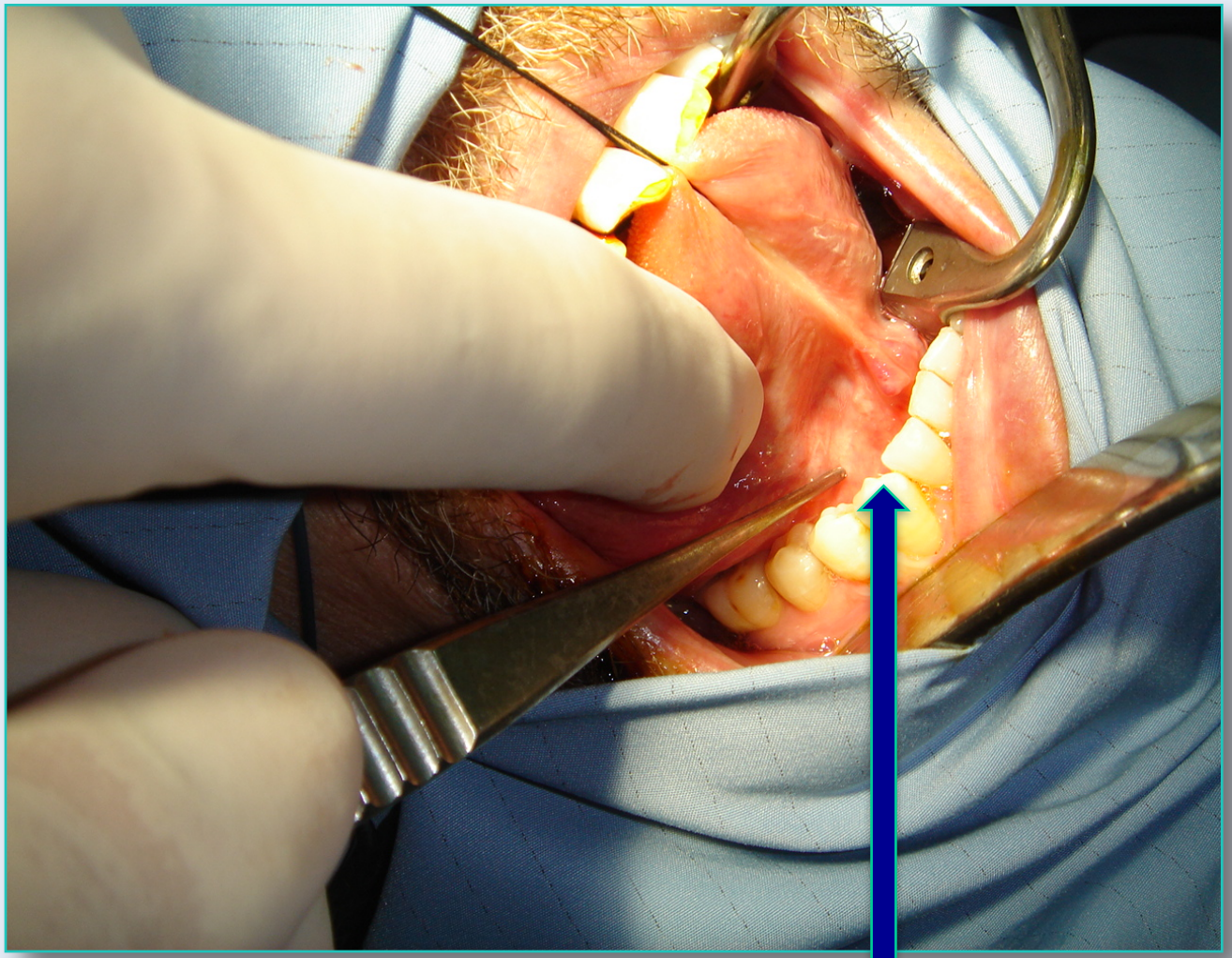

Lingual nerve

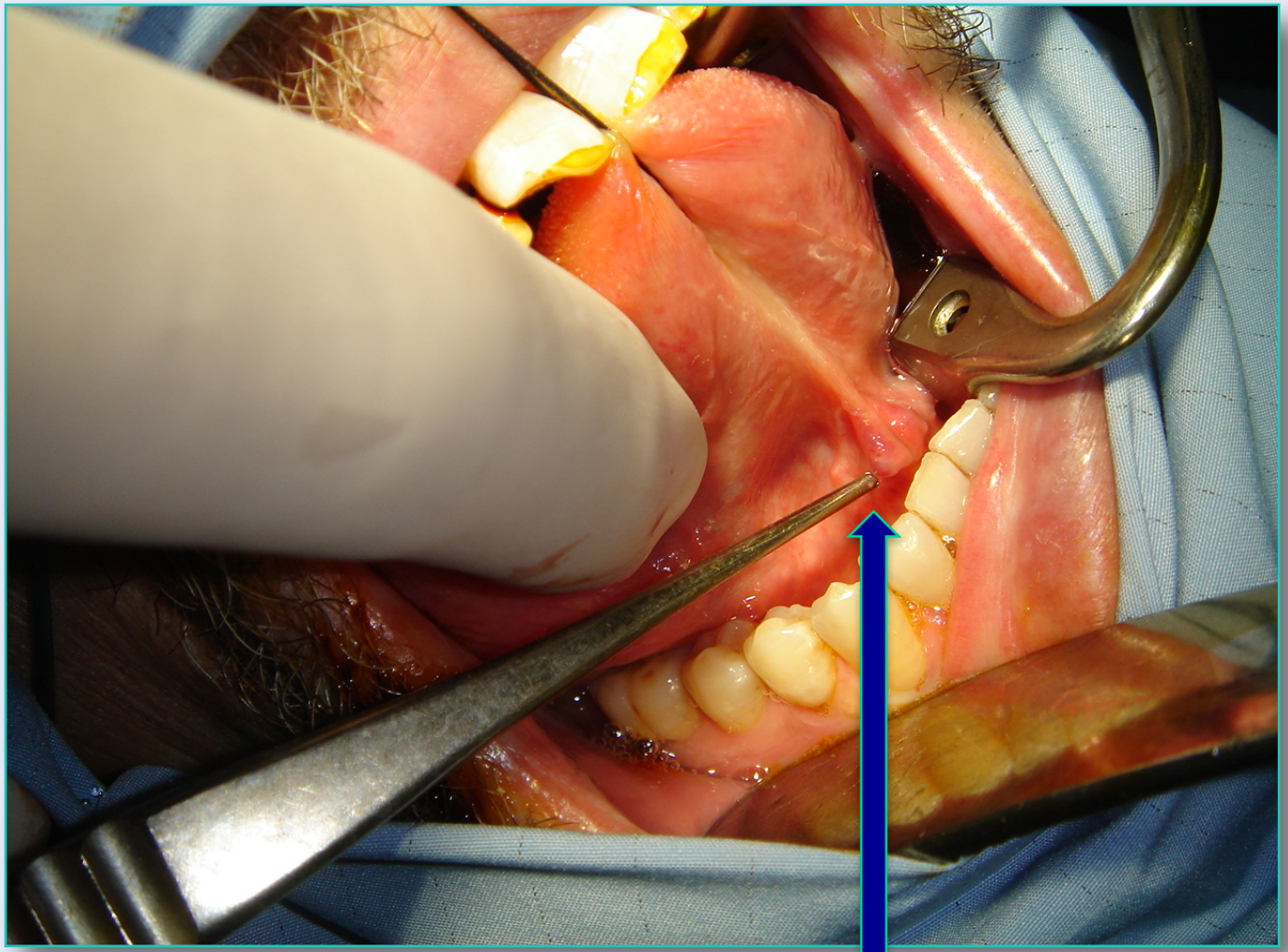

Warton's duct

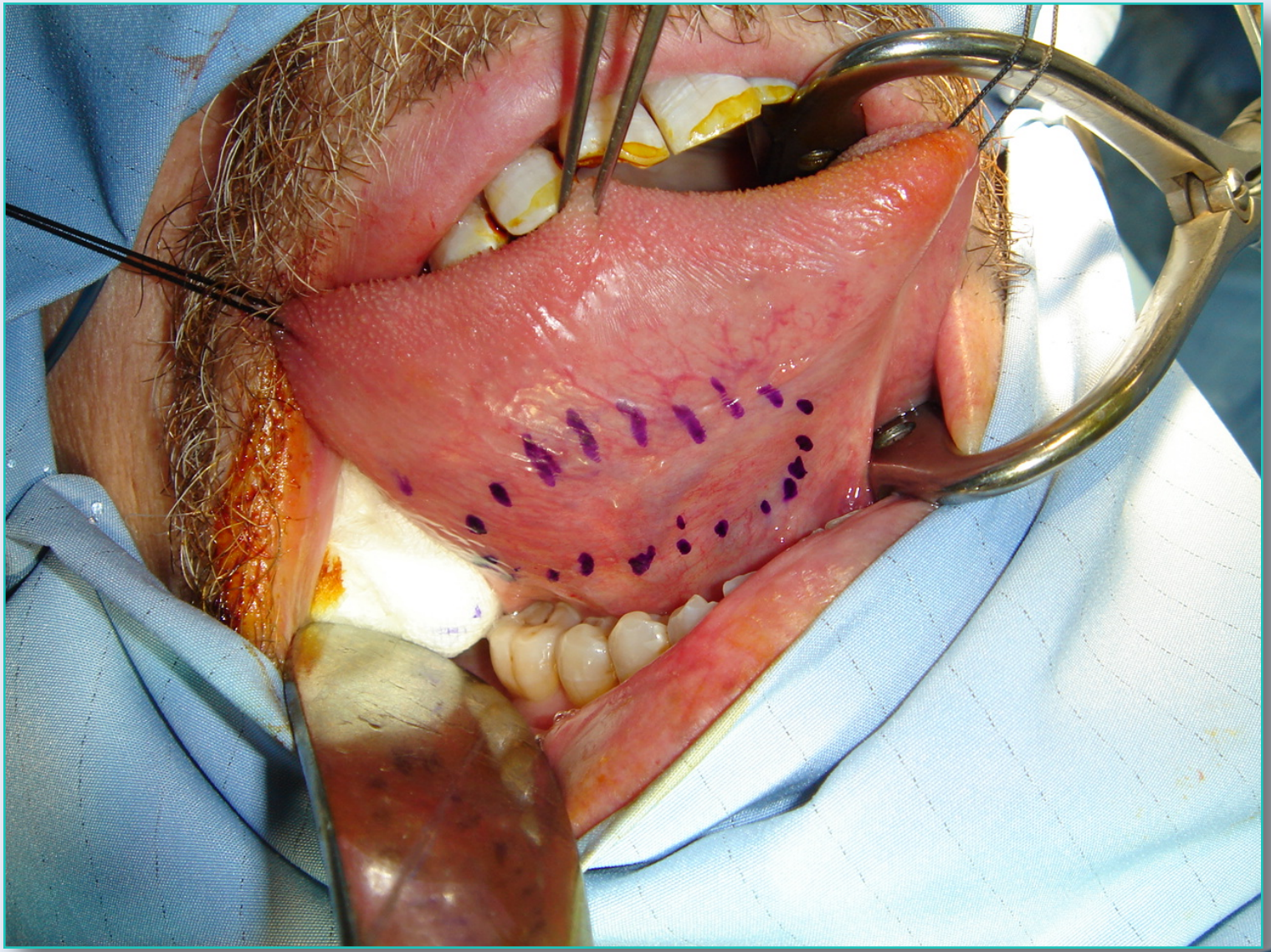

e-mail: info@urethralcenter.it
www.uretra.it
Websites: www.urethralcenter.it

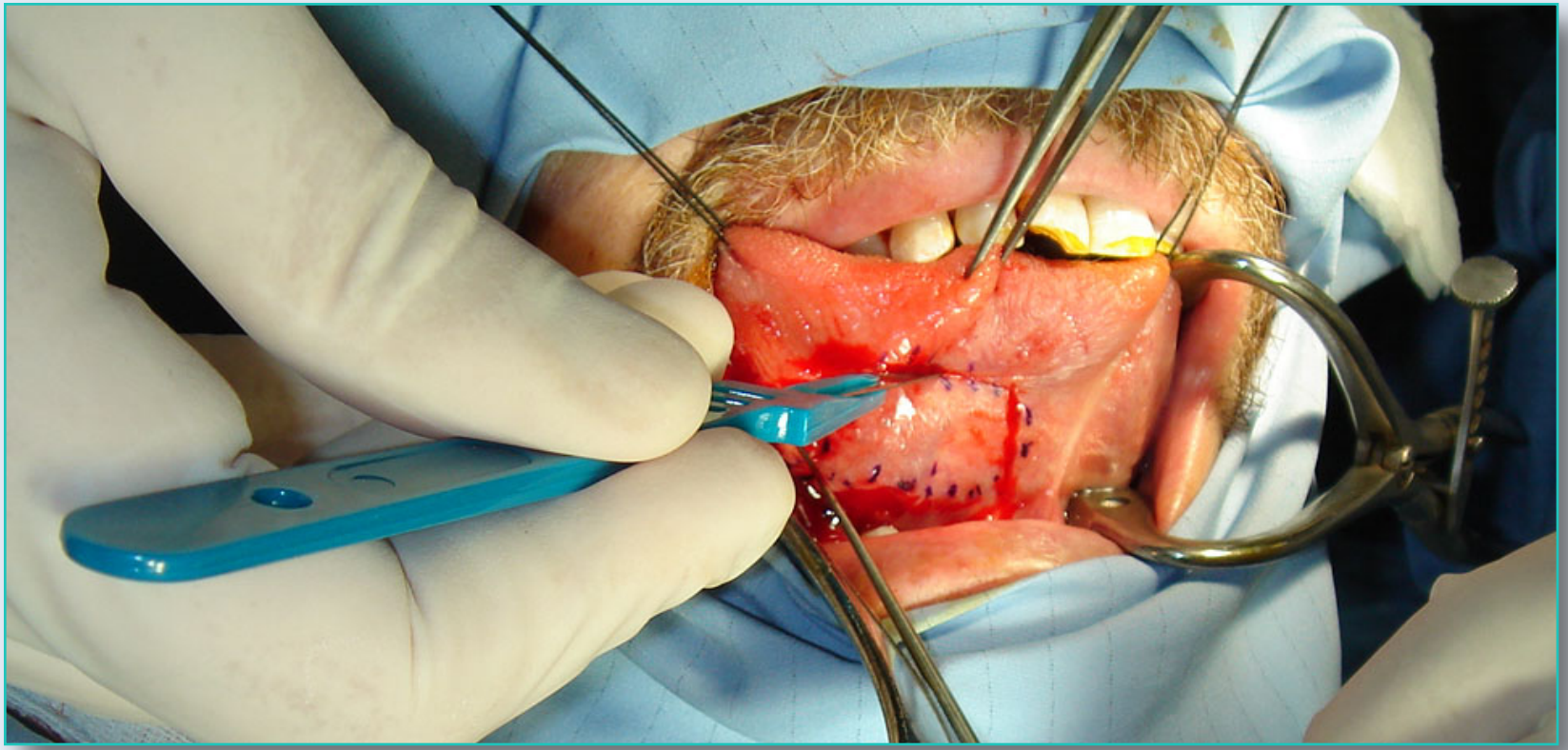

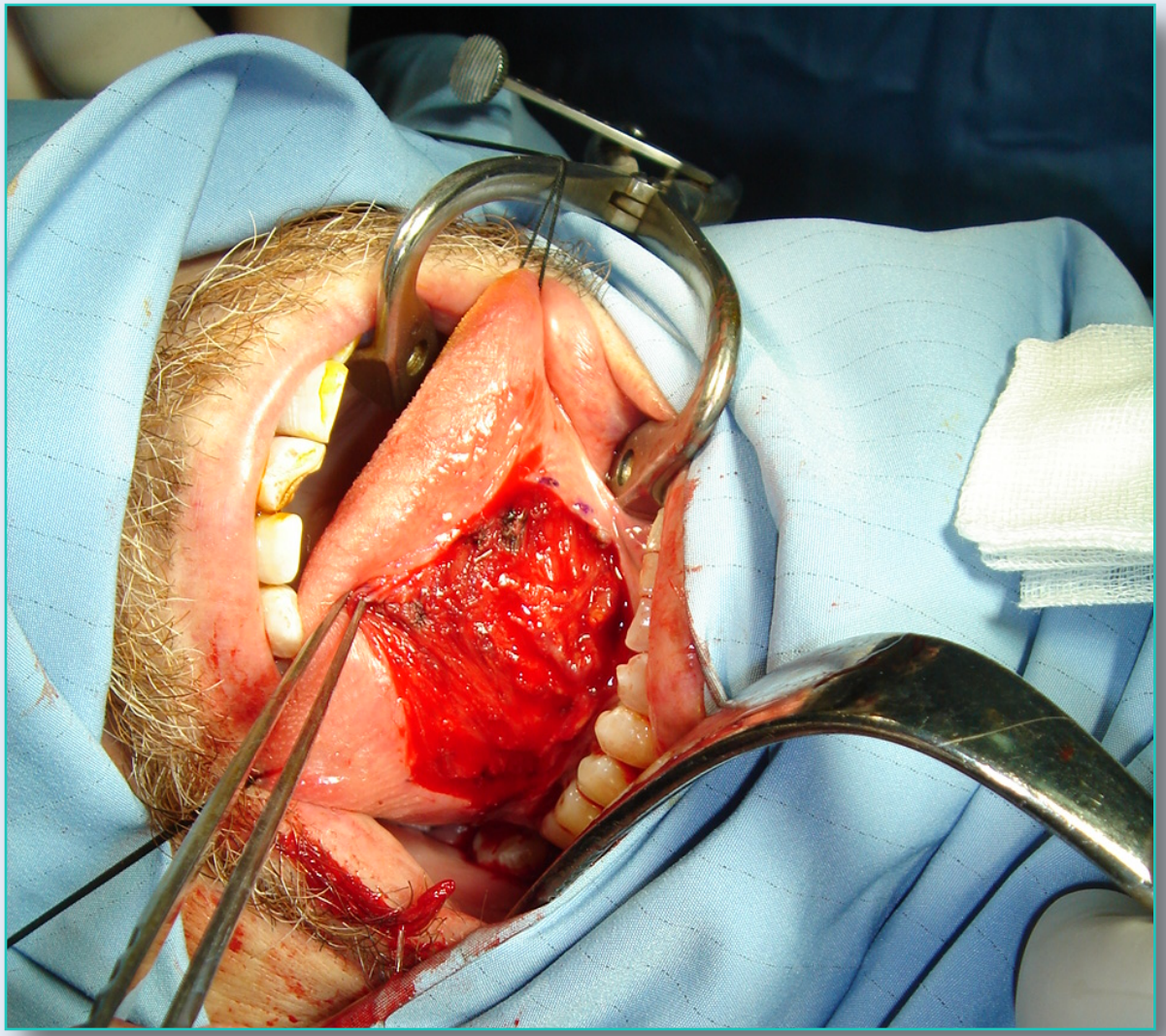

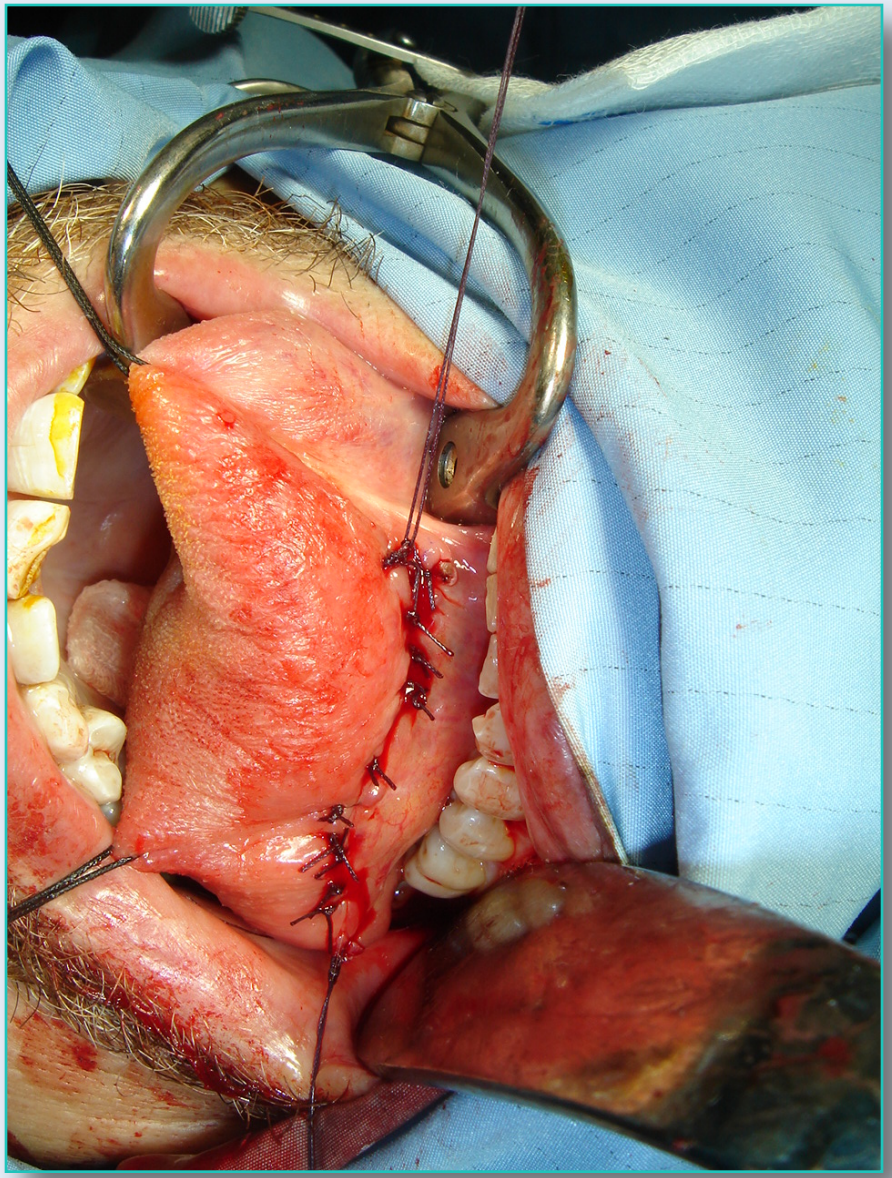

e-mail: info@urethralcenter.it
www.uretra.it
Websites: www.urethralcenter.it

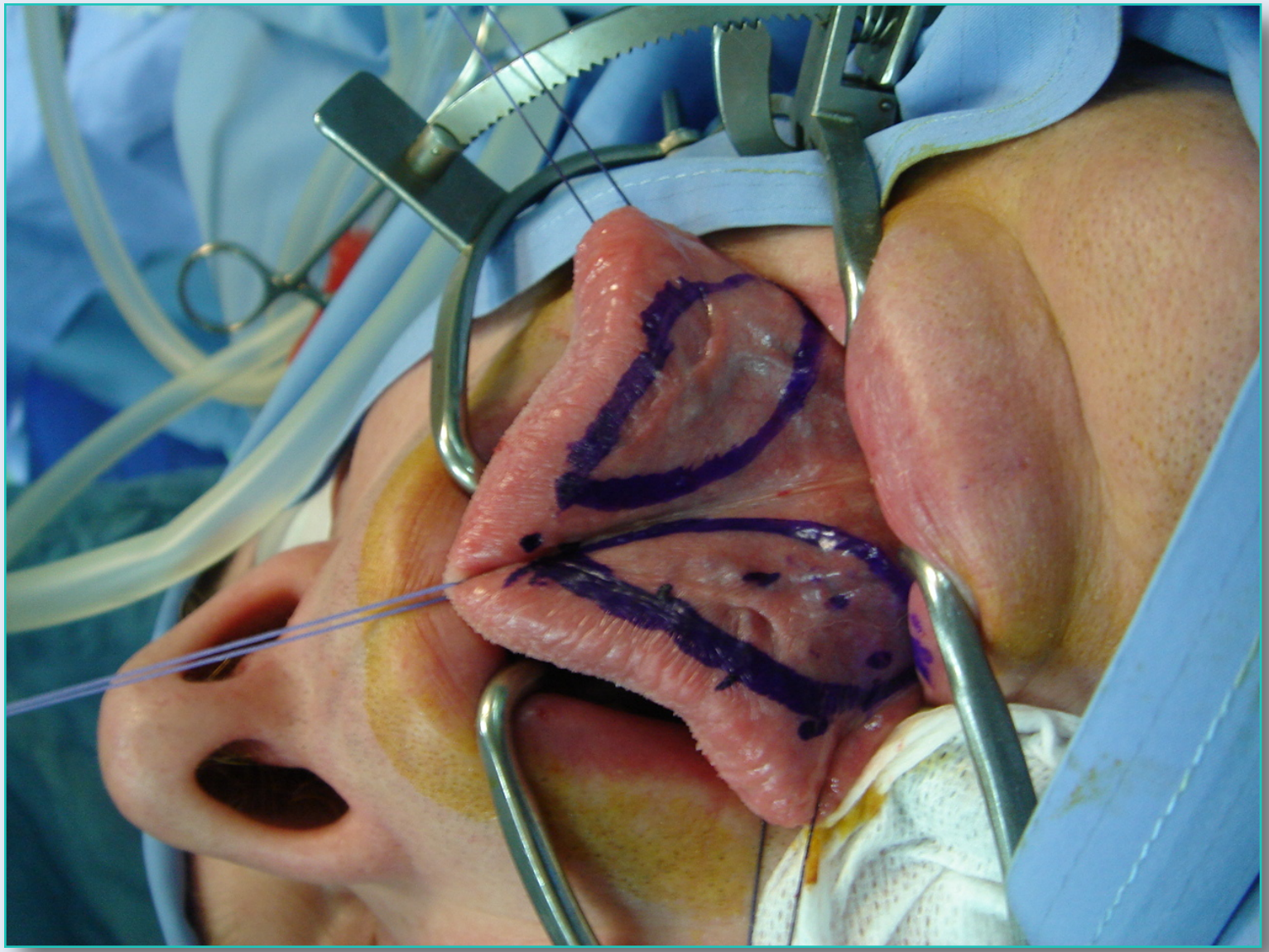

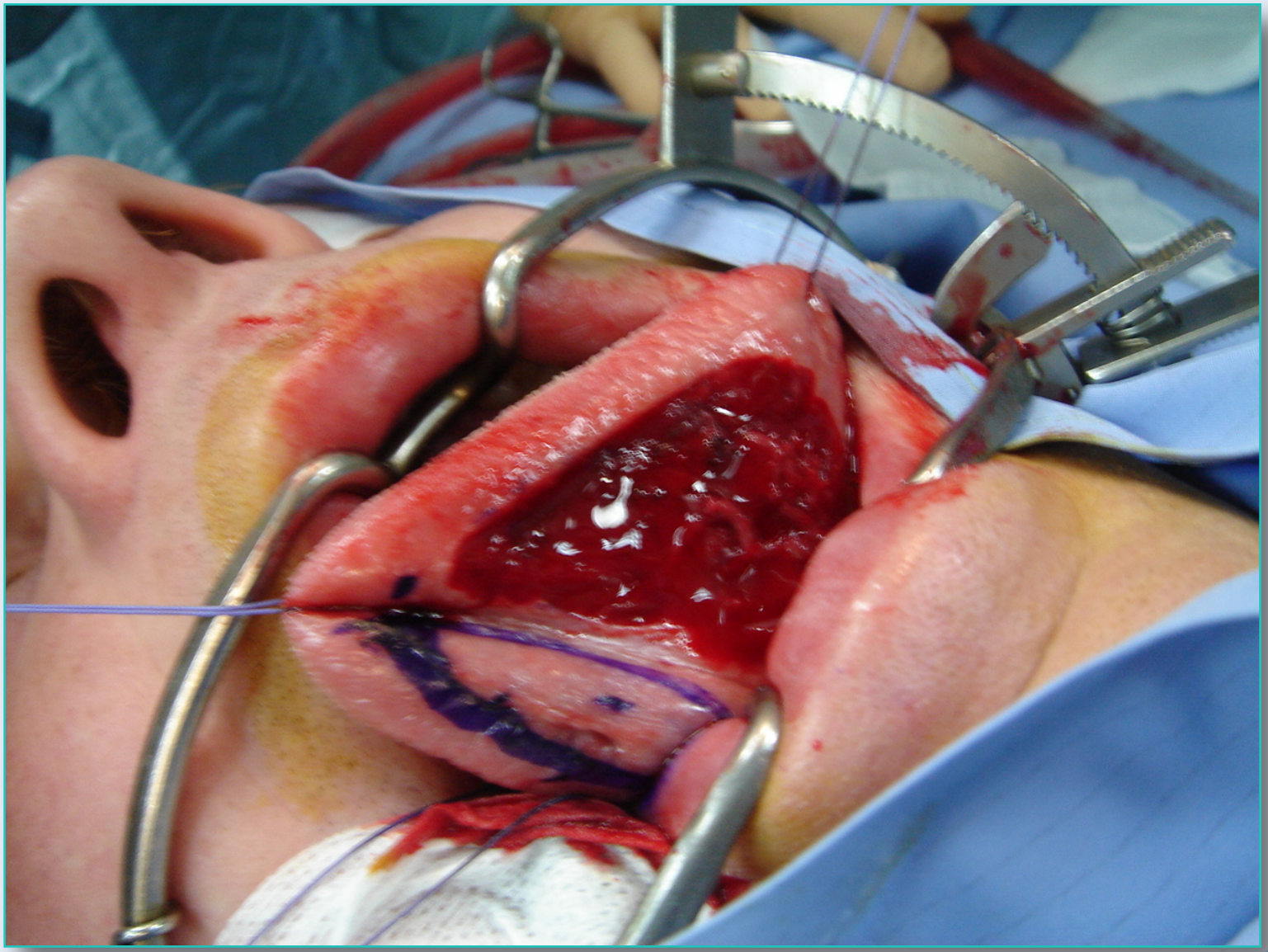

e-mail: info@urethralcenter.it
www.uretra.it
Websites: www.urethralcenter.it

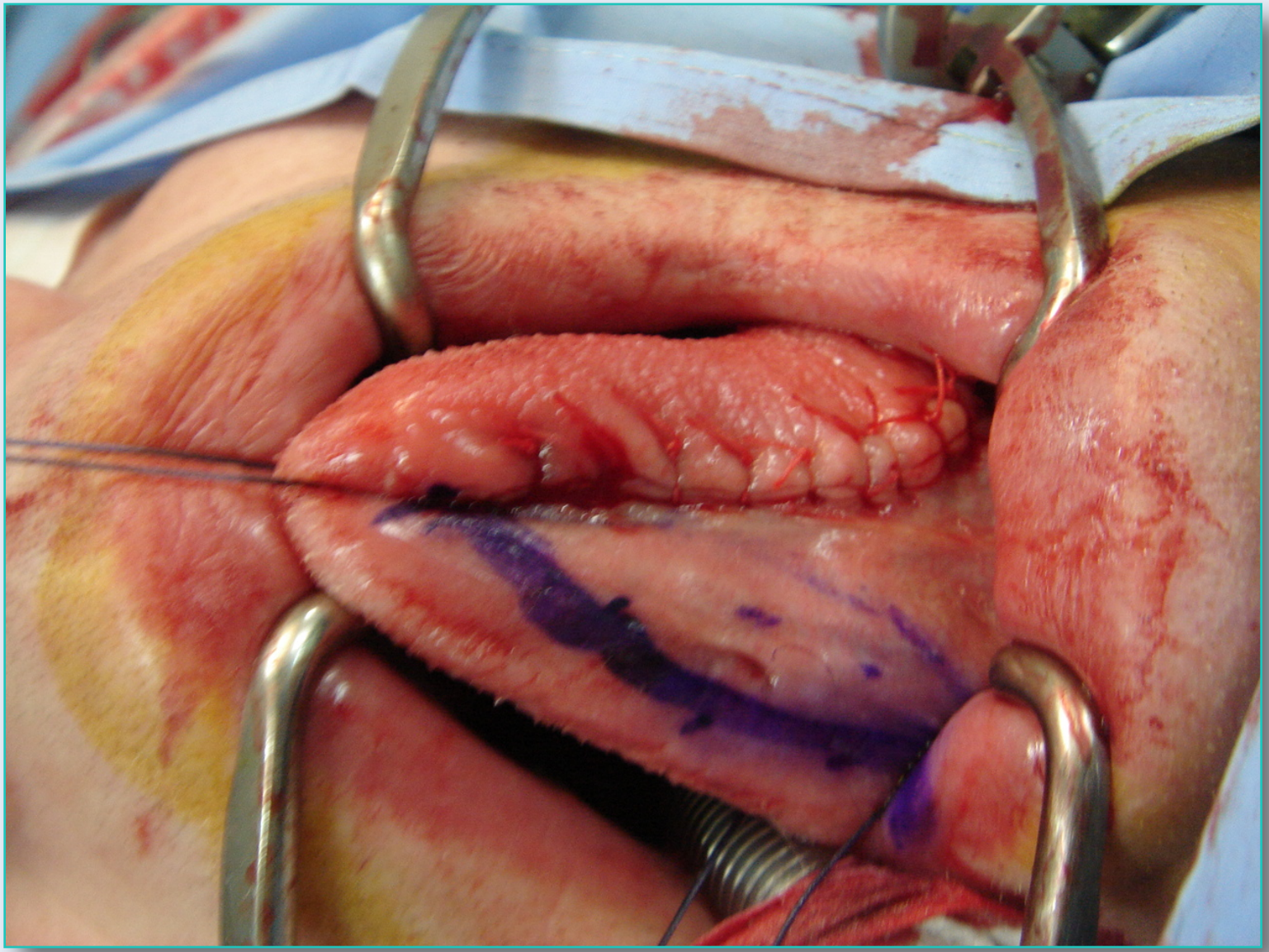

e-mail: info@urethralcenter.it
www.uretra.it
Websites: www.urethralcenter.it

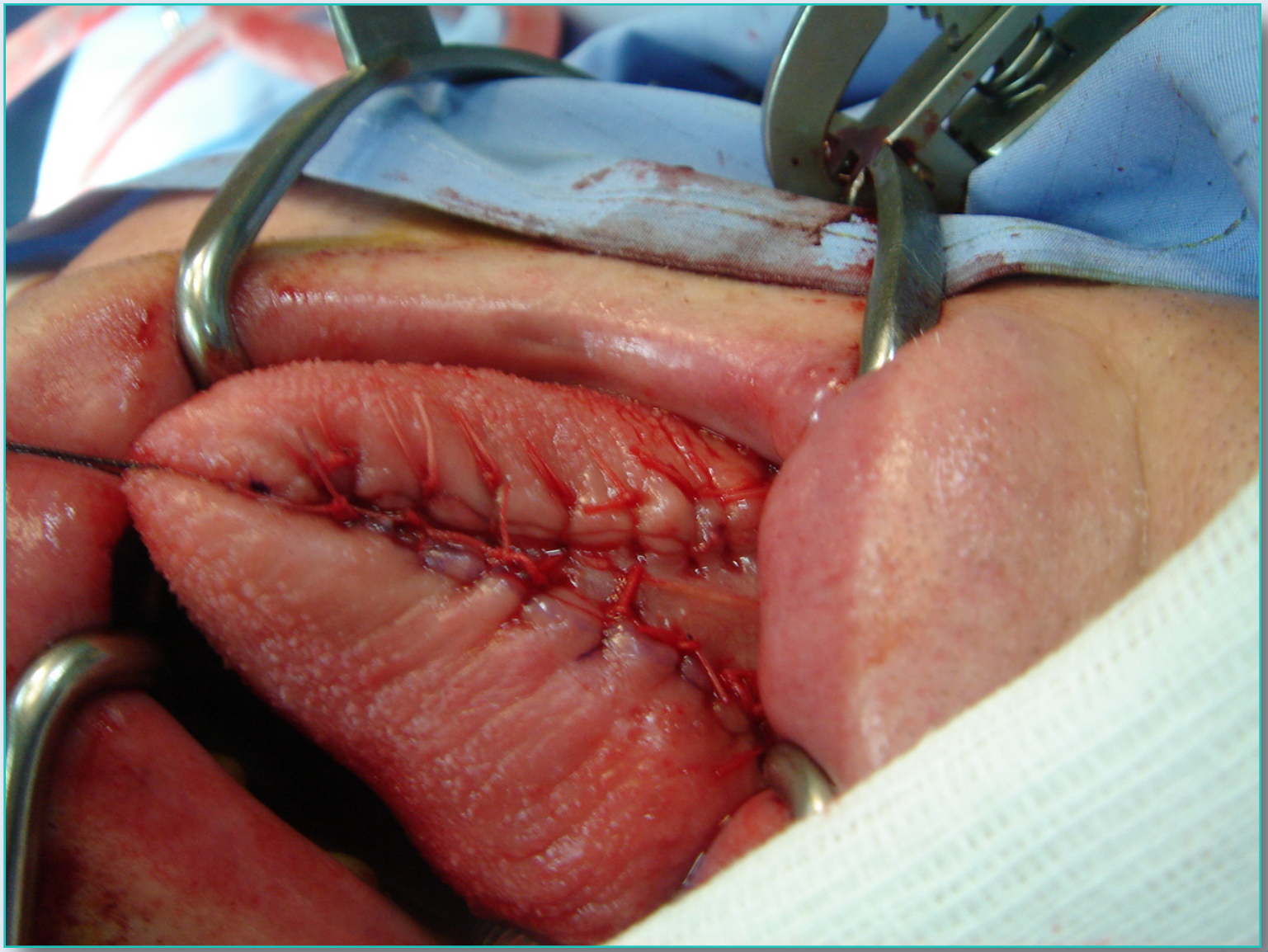

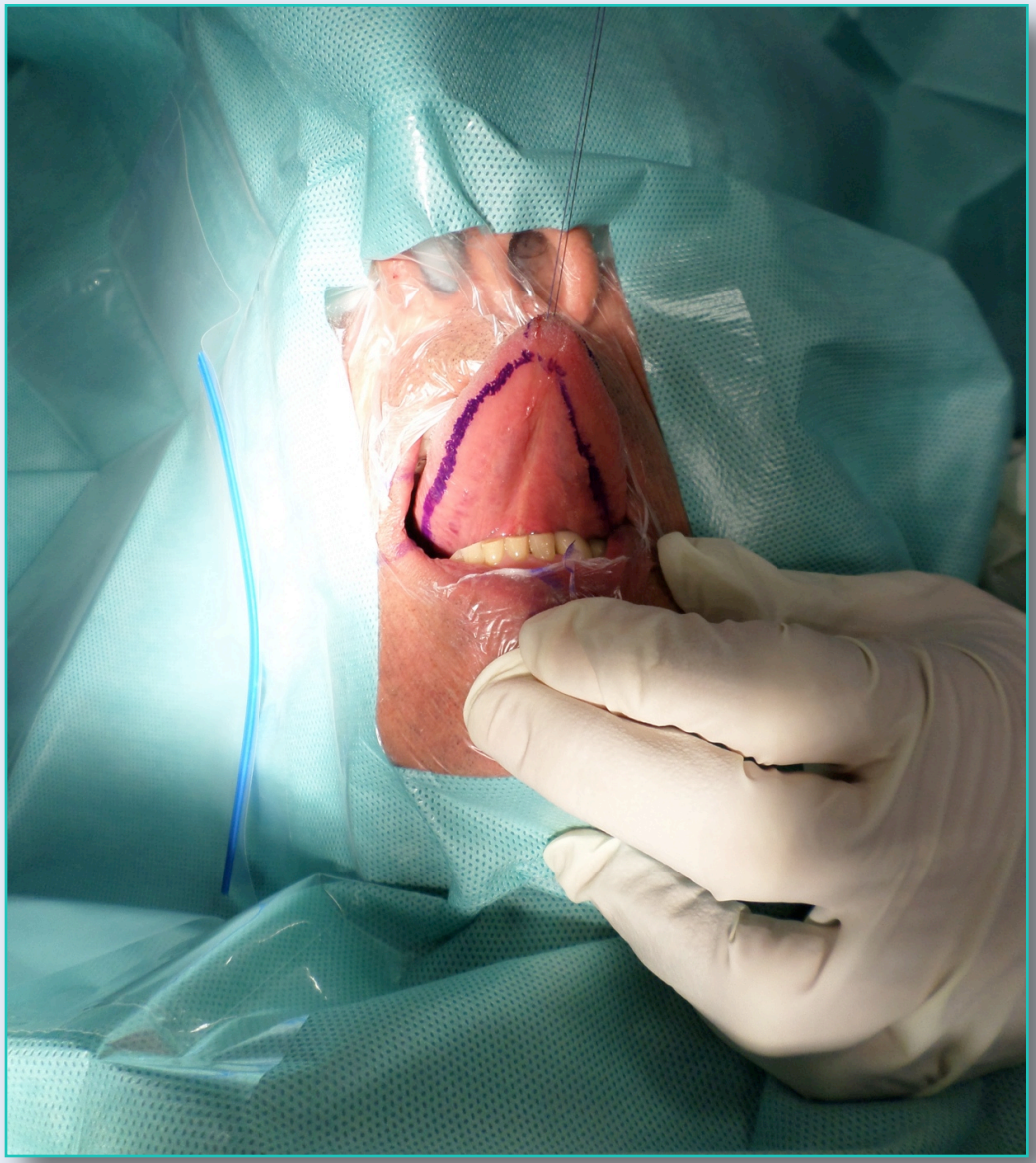

e-mail: info@urethralcenter.it
www.uretra.it
Websites: www.urethralcenter.it

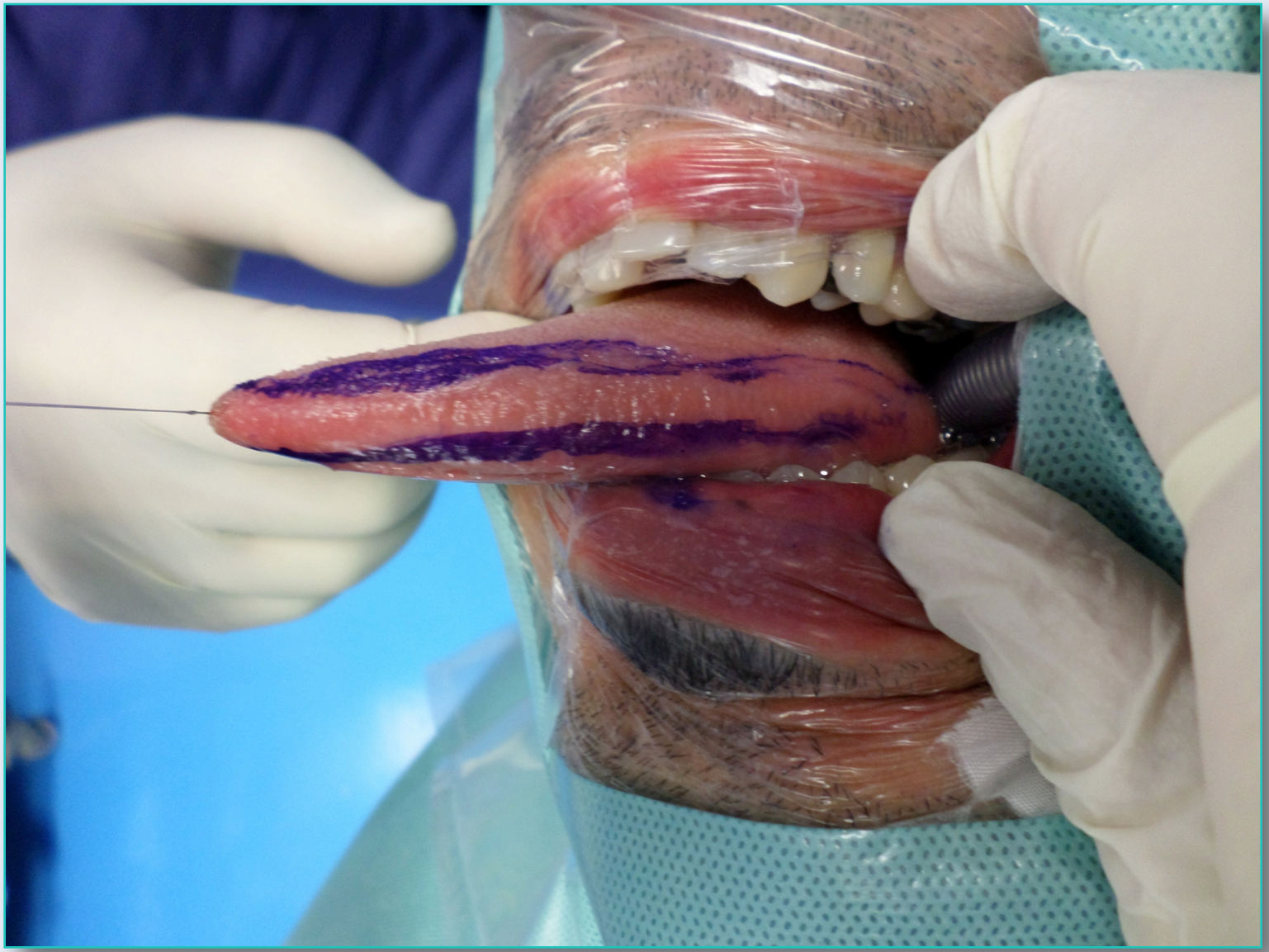

e-mail: info@urethralcenter.it
www.uretra.it
Websites: www.urethralcenter.it

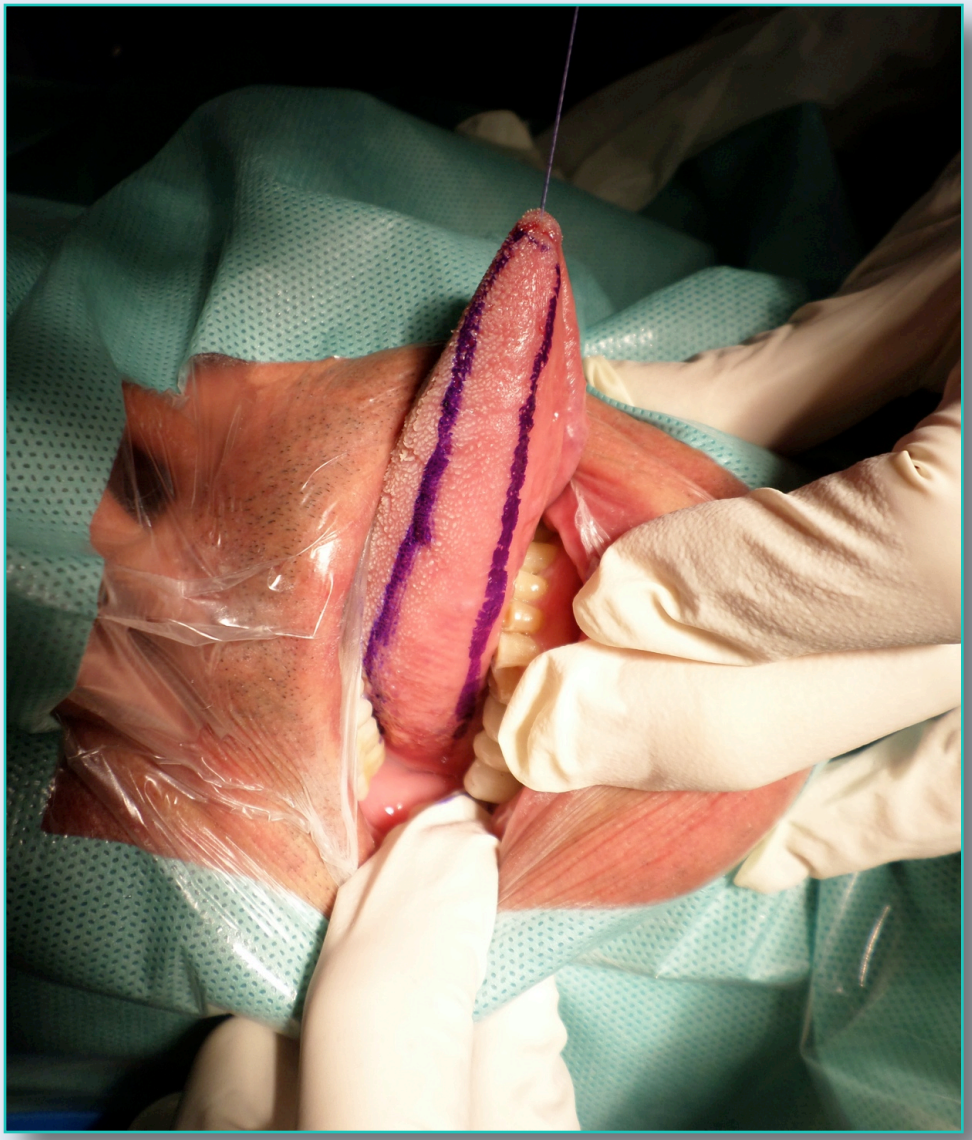

e-mail: info@urethralcenter.it
www.uretra.it
Websites: www.urethralcenter.it

Tongue vs Cheek: Advantages

Harvesting: easier, simpler, faster and no special instruments requested

Graft: thinner

Tongue vs Cheek: Disadvantages

Post-operative course:

- more bothersome
- more painful
- more problems in eating, talking, kissing
- more time for a complete recovery

Tongue vs Cheek: When ?

Patient who undrewent previous bilateral harvesting from the cheeks.

Patient who require thin and small graft.

Patient with panurethral stricture requiring 2 grafts from the both cheeks and 1 more graft from the tongue.

Conclusions

Urethral surgeon shoud be able to harvest and use oral mucosa from any part of the mouth according to the patient and stricture characteristics.

THANK YOU FOR YOUR ATTENTION!

e-mail: info@urethralcenter.it
www.uretra.it
Websites: www.urethralcenter.it